Review Article

Endoscopic management of pancreatic fluid collections with disconnected pancreatic duct syndrome

Zhi-Jie Wang[1,*], Yi-Hang Song[1,*], Shi-Yu Li[1,*], Zi-Xuan He[1,*], Zhao-Shen Li[1], Shu-Ling Wang[1], Yu Bai[1]
[1]Department of Gastroenterology, Changhai Hospital, Second Military Medical University/Naval Medical University, Shanghai, China

ABSTRACT

Disconnected pancreatic duct syndrome (DPDS) is an important and common complication of acute necrotizing pancreatitis. Endoscopic approach has been established as the first-line treatment for pancreatic fluid collections (PFCs) with less invasion and satisfactory outcome. However, the presence of DPDS significantly complicates the management of PFC; besides, there is no standardized treatment for DPDS. The diagnosis of DPDS presents the first step of management, which can be preliminarily established by imaging methods including contrast-enhanced computed tomography, ERCP, magnetic resonance cholangiopancreatography (MRCP), and EUS. Historically, ERCP is considered as the gold standard for the diagnosis of DPDS, and secretin-enhanced MRCP is recommended as an appropriate diagnostic method in existing guidelines. With the development of endoscopic techniques and accessories, the endoscopic approach, mainly including transpapillary and transmural drainage, has been developed as the preferred treatment over percutaneous drainage and surgery for the management of PFC with DPDS. Many studies concerning various endoscopic treatment strategies have been published, especially in the recent 5 years. Nonetheless, existing current literature has reported inconsistent and confusing results. In this article, the latest evidence is summarized to explore the optimal endoscopic management of PFC with DPDS.

Key words: disconnected pancreatic duct syndrome, necrotizing pancreatitis, pancreatic fluid collections, pancreatic pseudocysts, walled-off necrosis

Access this article online

Quick Response Code:

Website: www.eusjournal.com

DOI: 10.4103/EUS-D-21-00272

This is an open access journal, and articles are distributed under the terms of the Creative Commons Attribution-NonCommercial-ShareAlike 4.0 License, which allows others to remix, tweak, and build upon the work non-commercially, as long as appropriate credit is given and the new creations are licensed under the identical terms.

For reprints contact: WKHLRPMedknow_reprints@wolterskluwer.com

How to cite this article: Wang ZJ, Song YH, Li SY, He ZX, Li ZS, Wang SL, *et al*. Endoscopic management of pancreatic fluid collections with disconnected pancreatic duct syndrome. Endosc Ultrasound 2023;12:29-37.

*These authors contributed equally to the manuscript.

Address for correspondence:

Dr. Zhao-Shen Li, Department of Gastroenterology, Changhai Hospital, Second Military Medical University/Naval Medical University, No. 168, Changhai Road, Yangpu District, Shanghai - 200433, China.
E-mail: lizhaoshen0708@sina.com

Dr. Shu-Ling Wang, Department of Gastroenterology, Changhai Hospital, Second Military Medical University/Naval Medical University, No. 168, Changhai Road, Yangpu District, Shanghai - 200433, China.
E-mail: wangshuling0000@126.com

Dr. Yu Bai, Department of Gastroenterology, Changhai Hospital, Second Military Medical University/Naval Medical University, No.168, Changhai Road, Yangpu District, Shanghai - 200433, China.
E-mail: baiyu1998@hotmail.com

Received: 2021-12-15; **Accepted:** 2022-03-01; **Published online:** 2022-06-08

INTRODUCTION

Disconnected pancreatic duct syndrome (DPDS) is an important but frequently neglected complication, which is reported to occur in approximately 20%–40% of patients with acute necrotizing pancreatitis (NP).[1] It is characterized by complete transection of the main pancreatic duct (MPD), resulting in discontinuity between viable upstream secreting pancreatic tissue and the gastrointestinal tract. Most of the DPDS (about 47%) located in the body of the pancreas.[2] DPDS at the neck of pancreas was also common because this region has a precarious blood supply.[3] The disconnected pancreatic gland remains functional and the leakage of pancreatic fluid causes several problems, such as pancreatic fluid collection (PFC), external pancreatic fistula, and pancreatic ascites.[4]

What's more, new-onset diabetes could occur in 16%–52% patients with DPDS during long-term follow-up,[5] and chronic pancreatitis with exocrine or endocrine insufficiency may be seen due to the atrophy of the disconnected pancreatic gland.[6] Among them, PFC is the most common presentation accounting for 83.2% of all complications.[2] Although endoscopic approach has been established as the first-line treatment for PFC with less invasion and satisfactory outcome,[7-9] there are no standardized guidelines for the treatment of DPDS for the time being.[1,10] The presence of DPDS obviously complicates PFC and the management is currently at the discretion of the treating clinician. Conservative managements, including antibiotics and nutritional supportive therapy, are important for patients with DPDS, especially in the early stage of disease. In some cases, the disconnected pancreatic gland is atrophic and the PFC eventually resolves, but conservative management may not result in the resolution of PFC in a majority of patients.[11] Besides, there is no evidence supporting the positive role of octreotide in pancreatic duct (PD) leaks.[12] Historically, DPDS is managed surgically, and the standard surgical procedure includes either resection of the disconnected pancreas or internal drainage. However, resection of the viable distal pancreatic tissue can contribute to exocrine and endocrine insufficiency. Besides, surgery in the setting of NP is challenging because the severe inflammation in the abdomen and extensive venous collateral formation. The incidence rate of postoperative complications, including infections, organ failure, external pancreatic fistula, and bleeding, is high.[13,14] Percutaneous drainage has been considered effective and less invasive in the treatment of PFC, but it carries an inherent risk of iatrogenic external pancreatic fistula formation when applied to PFC with DPDS.[15] Thus, percutaneous drainage alone is going out of vogue. Endoscopic management of PFC with DPDS was firstly described three decades ago by Kozarek *et al*.[16] However, endoscopic transpapillary therapy for DPDS in early practice fails to demonstrate satisfactory outcome,[17] and endoscopic method is usually performed among patients with poor physical status who are not candidates for surgery. Nowadays, the development of endoscopic techniques and accessories, especially the interventional EUS, has paved an exciting new way toward the management of DPDS. In two recent meta-analyses, the success rates are demonstrated to be up to 92% for the endoscopic treatment of disrupted and disconnected PD, comparable to that of surgical interventions.[2,18]

Although various treatment strategies have been developed, it remains challenging to manage PFC in the subset of patients with associated DPDS, and consensus has not been reached so far. Therefore, this work aims to summarize the latest evidence for the diagnosis and endoscopic management of PFC with DPDS.

DIAGNOSIS

Firstly, it is important to figure out the key concepts and terminology of DPDS. A disconnected duct is defined as a circumferential interruption of the duct integrity, whereas a disrupted duct is defined as a partial interruption of the duct.[19] DPDS refers to a clinical condition caused by the symptomatic production of pancreatic juice due to ductal discontinuity between viable pancreatic tissue and the duodenum.[20] The correct differentiation between them contributes to different management decision-making.[20] It is unnecessary to aggressively look for PD disruptions or disconnections because whether a patient with NP will develop DPDS or not is generally unclear in the first 2 weeks.[11] Furthermore, the initial treatment of NP focuses on other aspects. In general, the PD integrity should be evaluated at 2 weeks after onset or when invasive intervention is considered (usually at 4 weeks after onset).[21]

The diagnosis of DPDS is the first step for management, which is fundamentally confirmed by imaging methods such as contrast-enhanced computed

tomography (CE-CT), ERCP, magnetic resonance cholangiopancreatography (MRCP), and EUS.

The conventional criteria for the diagnosis of DPDS proposed by Sandrasegaran *et al.*[22] are as follows:

A. Pancreatic necrosis of at least 2 cm; pancreatic necrosis of <2 cm often leads to healing with stricture formation of the MPD and incomplete disconnection
B. Viable upstream distal pancreatic tissue from the site of necrosis
C. Free extravasation or total cutoff of contrast agent injected into the MPD during ERCP [Figure 1].

Another diagnostic criterion, which includes the presence of extravasation or cutoff of MPD when contrast agent is injected and the demonstration of the viable upstream pancreas on imaging, is actually accepted by more researchers.[2]

COMPUTED TOMOGRAPHY

CE-CT is the most common cross-sectional imaging technique used in patients with NP, which is suggested by the European Society of Gastrointestinal Endoscopy (ESGE) as the first-line imaging modality for NP from the onset to the 4th week if there is no contraindication.[21] CE-CT can assess the necrotic area of the gland and PFC and identify the viable part of the pancreas in the upstream tail. New progresses in CT technology, such as the application of thinner collimation and multirow detector computed tomography (MDCT) with multiplanar reformations, have achieved satisfying visualization of the MPD in 75%–100% of patients.[23,24] Anderson and Soto[25] demonstrated that portal venous phase 64 MDCT images were moderately accurate for detecting communication between PDs and PFC, which were used to correctly identify the communication in all the nine cases. In another study, sensitivity of helical CT for PD disruption was 75% (12/16), and the site of MPD disruption was determined in 50% (8/16) patients.[26] In clinical practice, the combination of CT with ERCP or MRCP is usually required to confirm DPDS, especially for partial disruption of the duct as it is hard for CECT to identify it directly. Even so, CT is a promising noninvasive imaging modality [Figure 2]. However, more multicenter studies with larger sample size are expected eagerly in the future considering the low quality of the aforementioned studies.

MAGNETIC RESONANCE

MRCP is a noninvasive and precise approach used to evaluate the morphology of pancreatic parenchyma and PD. Previous studies have demonstrated the usefulness of MRCP in detecting PD disruptions.[27,28] Drake *et al.*[27] reported that they performed MRCP in 31 patients with suspected PD disruption within 7 days after ERCP onset. PD disruption was found in 74% (23/31) of patients during ERCP and MRCP confirmed 91% (21/23) of these patients. In addition, MRCP correctly detected all the eight patients with intact PD, as confirmed by ERCP. Another study compared the results between CT and MRCP in evaluating PD disruption among children with blunt pancreatic injury. They found that the duct was more often visualized on MRCP than CT (48% *vs.* 5%, $P < 0.05$). However, conventional MRCP has limitations. It may not diagnose PD disruption where transpapillary stenting is highly successful. Besides, MRCP was not superior to CT in identifying PD integrity (62% *vs.* 38%, $P = 0.28$) and the authors

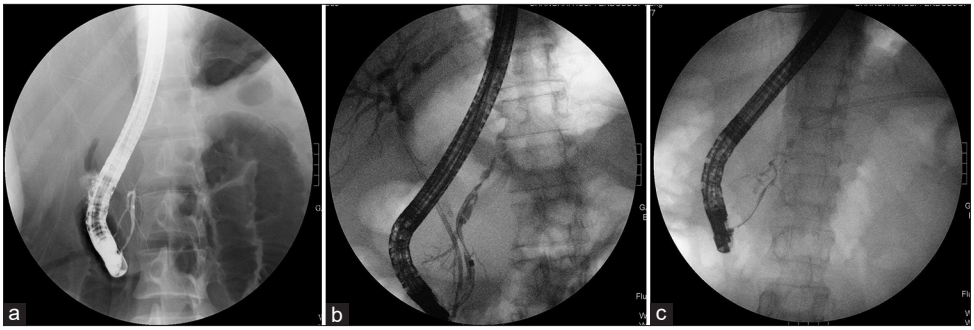

Figure 1: ERCP images of disconnected pancreatic duct syndrome. (a) Complete pancreatic duct disruption in a patient with traumatic pancreatic injury: ERCP reveals total cutoff of proximal main pancreatic duct with opacification of Santorini duct. (b) Complete pancreatic duct disruption in a patient with acute necrotizing pancreatitis: ERCP reveals total cutoff at the body of the pancreas, without visualization of the pancreatic tail. (c) Complete pancreatic duct disruption in a patient with severe acute pancreatitis: ERCP reveals contrast extravasation from proximal main pancreatic duct, without visualization of the main pancreatic duct at the body or tail

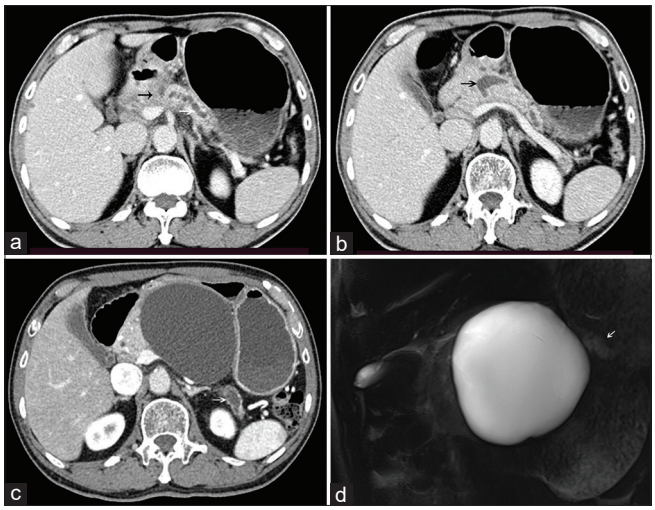

Figure 2: Contrast-enhanced computed tomography scans and magnetic resonance cholangiopancreatography of disconnected pancreatic duct syndrome in a patient with acute necrotizing pancreatitis. (a) Contrast-enhanced computed tomography done after the resolution of walled-off pancreatic necrosis reveals dilated distal pancreatic duct (white arrow) and abrupt cutoff at the neck of the pancreas (black arrow). (b) Contrast-enhanced computed tomography also reveals a necrotic area (black arrow) at the neck of the pancreas at the same time. (c) Follow-up contrast-enhanced computed tomography 4 months later reveals a recurrent huge pseudocyst, with viable and atrophic but disconnected upstream pancreatic tissue (white arrow). (d) Follow-up magnetic resonance cholangiopancreatography reveals the huge pseudocyst and dilated distal pancreatic duct (white arrow)

recommend ERCP for the confirmation of duct disruption instead.[29] What's more, it is impossible to visualize the PD filling and extravasation in real time for conventional MRCP until the application of secretin-enhanced MRCP. The changes in the duodenal and jejunal fluid contents and the size or signal intensity of PFC can be evaluated after secretin administration.[30,31] The injection of secretin improves the sensitivity of MPD integrity from 47.1% to 66.4% and secretin-enhanced MRCP has been considered as the best diagnostic method for MPD disruption in the current guideline.[21,27,31,32] In a recent international expert survey involving 56 pancreatologists, most experts agreed that MRCP was the preferred diagnostic modality to evaluate PD integrity, but almost half of them never performed secretin-enhanced MRCP.[10] Actually, it is a problem beyond neglect that obstacles restricting its wide application, such as limited access to secretin and/or higher costs should be eliminated.[10]

ERCP

ERCP is historically considered as the gold standard for the diagnosis of DPDS by directly delineating PD anatomy, which can further differentiate between partial and complete PD disruption.[30] However, it is an invasive procedure that is associated with a potential risk of complications, such as infection of sterile pancreatic collections and postprocedure pancreatitis. It could not assess upstream duct and viable parenchyma. Moreover, duodenal edema in patients with NP usually makes ERCP challenging.[15] Thus, ERCP should be performed in patients who plan to undergo drainage of PFC or those who have other therapeutic intention, besides, diagnostic ERCP alone should be avoided, except in rare case when the information may fundamentally change the patient's treatment strategy.[5,15] Importantly, clear and strict indications should be established.

EUS

There is limited research focused on EUS assessment of DPDS. A prospective study described the imaging features of EUS for DPDS as the presence of a well-defined PFC along the course of MPD, with the upstream pancreatic tissue and duct terminating into the PFC. All the 21 patients with DPDS were confirmed by EUS and the authors concluded that there was 100% correlation between EUS characterization with CT and pancreatography or surgical pathology in patient with DPDS.[33] However, about one-third of patients had a suboptimal examination of the upstream pancreas and they were excluded in their study. The study also suggests some limitations of EUS. For example, EUS was effective only for assessing PFC and MPD disruptions in the neck-body-tail regions of the pancreas. The optimal examination of the upstream pancreas with EUS may not be possible in all patients with PFC and NP. Besides, the experience of endoscopists may affect the visualization of the PD during EUS.[10] Although more studies are required to assess the role of EUS in the diagnosis of DPDS, EUS can be a promising method, especially for PFC patients with DPDS because it is accurate in assessing the content of PFC[21] and makes it possible to complete diagnostic and therapeutic (transmural drainage) procedure in one time.[5]

Furthermore, in a recent systematic review on imaging modalities for diagnosing disrupted or disconnected PD in patients with acute pancreatitis, 142 patients were included from eight studies and five different diagnostic modalities evaluated. It was reported that the sensitivities of EUS and ERCP

were 100%, while the sensitivity and specificity of MRCP (with or without secretin) were 83% and 100%, respectively. For a combined cohort of MRCP and secretin-enhanced MRCP, the sensitivity was 92%. Meanwhile, the sensitivity and specificity for amylase measurements in the drained fluid were 100% and 50%, respectively. Thus, the authors recommended MRCP or secretin-enhanced MRCP as the preferred diagnostic modality.[34]

ENDOSCOPIC TREATMENT

PFCs can be categorized in four types according to their content and wall maturity, including acute peripancreatic collections, pancreatic pseudocysts (PCs), acute necrotic collection, and walled-off pancreatic necrosis (WON).[35] It is reported that early intervention is associated with increased morbidity and mortality.[36] Similarly, a recent study reported that early drainage in patients with infected NP results in more invasive interventions than postponed drainage.[37] Therefore, it is currently recommended that the drainage of PFC is performed until a mature wall has formed (usually 4 weeks after the onset).[38] Moreover, the term "PFC" in this review generally refers to PC or WON. There is no doubt that endoscopic drainage of PFC is preferred over the other methods as a first-line treatment.[7,39] However, it is reported that DPDS has a significant impact on the endoscopic treatment of PFC. A study including 361 patients with PFC (167 of them had concurrent DPDS) demonstrated that more patients with DPDS required hybrid treatment, re-interventions, rescue-surgery, and a longer length of hospital stay.[40] Recently, a meta-analysis was performed to compare the outcomes of EUS-guided treatment for PFC between DPDS and non-DPDS groups. As a result, no significant difference was observed between the two groups with regard to technical success, adverse events, or mortality. However, the authors discovered that DPDS was highly associated with the risk of PFC recurrence (pooled odds ratio [OR] 6.72; 95% confidence interval [CI] 2.72–16.6).[41] Obviously, the endoscopic treatment strategies for PFC with concomitant DPDS should be tailored based on the current evidence available.

TRANSPAPILLARY DRAINAGE

It is attractive that transpapillary drainage is physiologic, which does not need to create an alternative nonanatomical route of drainage as in transmural drainage. When the flow is impeded by the sphincter of Oddi or PD strictures/calculi in the downstream duct, inserting a stent into the PD facilitates drainage of pancreatic secretions through the papillary. Moreover, PD stent bridging the disrupted part of the duct may also stop pancreatic leakage and promote healing. In general, transpapillary drainage is adoptable and effective when the PFC is in communication with PD.[30] It has been proven that successful resolution of PFC and PD disruption depends on the type of disruption. In other words, it depends on whether the PD stent can bridge the disrupted duct successfully or not. The success rate of transpapillary pancreatic stenting for partial PD disruption is much higher than that for complete PD disruption, and thus transpapillary drainage is more effective in patients with partial PD disruption.[17,42] However, a few studies have reported the successful resolution of PFC with DPDS despite failure to bridge the disruption.[17,43,44] Experience from our center also demonstrates the effectiveness of transpapillary drainage. In our study, 31 patients with DPDS were identified and transpapillary stent was inserted in 15 of them. Although the site of disruption was not bridged in any patient, most patients (13/15) who underwent transpapillary drainage achieved clinical success over a median follow-up of 38 months.[45]

Conventionally, we believe that the limited size of pancreatic stent will result in inadequate drainage of PFC with solid debris and subsequently causes more complications than PC.[46,47] However, a recent study also reported satisfactory outcomes of transpapillary drainage for WON with partial or complete disruption of MPD. Active endoscopic transpapillary drainage, which included transpapillary nasal drainage and later insertion of the pancreatic stent, was performed in 22 patients with symptomatic WON and disruption of MPD. Long-term success was achieved in 16 of 22 patients.[48]

Actually, transpapillary drainage has been regarded as an adjunctive therapy of transmural drainage in some centers.[9] However, recent studies including a meta-analysis suggested that transpapillary drainage had no added benefit over transmural drainage in the management of PFC.[49-51] It is speculated that the addition of transpapillary drainage may hinder the patency and maturation of the cyst-enterostomy fistula created by transmural drainage, consequently affecting the resolution of PFC.[49]

Due to the poor technical success rate of PD stenting along with the potential adverse events of ERCP and the absence of definitive improved outcomes, the combined drainage approach is not recommended for patients with pseudocysts.[50] Of note, additional PD stenting for bridging is worth trying in specific patients with partial duct disruptions confirmed preoperatively, which has been proven to result in better outcomes.[52-54]

To sum up, we think that transpapillary drainage can be actively attempted when the PFC is in communication with a partial duct disruption or associated with obstructive chronic pancreatitis. When there is no condition to perform transmural drainage (the distance between the GI wall and PFC exceeding 1 cm), transpapillary drainage is an alternative option before other more invasive procedures. Apart from the well-recognized complication such as introducing infection into sterile pancreatic collections and postprocedure pancreatitis, transpapillary drainage also increases the risk of stent-induced ductal and parenchymal changes resembling chronic pancreatitis.[55] Obviously, prospective, randomized trials with larger sample sizes are warranted in the future to identify the role of transpapillary drainage.

TRANSMURAL DRAINAGE

Transmural drainage has been increasingly performed with the development of endoscopic techniques/accessories and EUS-guided transmural drainage has currently been regarded as the first-line treatment for PFC.[4,7,9,39] In patients with DPDS, transmural drainage alone is sufficient and preferable because it is presumed that the collapse of PFC cavity will contribute to the healing of PD disruption. However, the risk of recurrence of PFC remains high after stent removal or early migration, which can be ascribed to the uncorrected physiological abnormality of disconnected pancreas.[56,57] A common practice is to place indwelling plastic stents (PS) *in-situ* to maintain an iatrogenic internal fistula. In a recent study, 141 patients receiving EUS-guided drainage and DPDS was present in 57. Of them, placement of the permanent transmural PS is more likely to treat patients with DPDS (OR 6.4; 95% CI [2.5–16.5], $P < 0.001$). Although DPDS was not associated with a lower clinical success rate, it was associated with PFC recurrence after stent removal (OR 8.0; 95% CI [1.2–381.8], $P = 0.04$).[56]

In the beginning, PS is the only choice of PFC drainage. Moreover, the placement is time-consuming and even challenging when multiple stents are required. The invention of the lumen-apposing metal stents (LAMSs) has greatly simplified the procedure, and the large diameter not only facilitates the drain of PFC with solid debris but also creates a passage for direct endoscopic necrosectomy [Figure 3]. Currently, LAMS has been accepted as a preferable stent type for transmural drainage. However, long-term (over 4 weeks) placement of LAMS should be avoided due to the worrisome rate of LAMS-related adverse events (50%; 6/12) reported in a randomized controlled trial study.[58] The ESGE recommends that LAMS should be replaced by indwelling PS in patients with suspected DPDS.[21] Although leaving transmural PS *in situ* permanently has been proven to be safe and effective on preventing PFC recurrence in many studies,[40,56,59,60] some report discordant results. For instance, a study involving 274 homogenous patients with WON undergoing EUS-guided drainage showed that recurrent PFC developed in 34/256 (13.2%) patients. A majority (33/34) of the patients who developed recurrent PFC had DPDS. One half of patients with recurrent PFC were asymptomatic and did not require re-intervention. In the study, the authors did not replace metal stents with PS and the overall rate of recurrent PFC is acceptably low.[61] Another prospective study did not replace metal stent with PS, and it reported recurrence rate of 13.2%, most of whom did not require therapy.[62] Etiology, site of disruption, volume of pancreatic juice from disconnected gland,

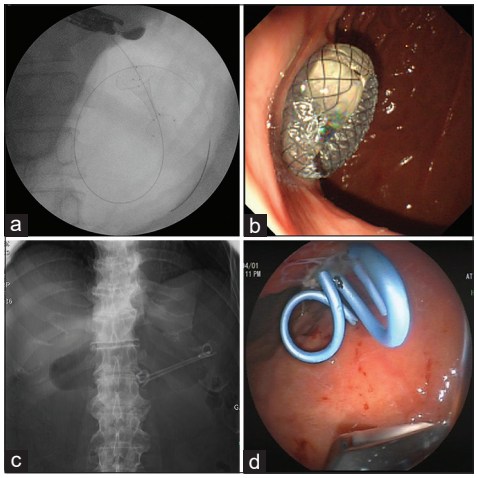

Figure 3: Transmural drainage performed in patients of pancreatic fluid collections with disconnected pancreatic duct syndrome. (a) Fluoroscopic image showing lumen-apposing metal stents was placed across transmural tract. (b) Endoscopic views showing lumen-apposing metal stents deployment in the stomach. (c) Fluoroscopic image showing two double-pigtail plastic stents were placed. (d) Endoscopic views showing two transmural plastic stents deployment in the stomach

and response of body to the pancreatic outflow may affect the outcome of DPDS to varying degrees, thus leading to these inconsistent results.[63] What's more, a study reported on the safety of PS placement among 36 patients suggested that long-term (over one year) placement of the indwelling transmural PS for PFC raised a risk of intestinal perforation. In their study, colon perforation occurred in three patients because of PS.[64] Therefore, more efforts should be made to solve the current clinical dilemma, and larger-scale, randomized study with stratification to the aforementioned factors is warranted in future.

OTHER APPROACHES

Ross *et al.*[65] reported the use of a combined percutaneous and transmural approach for the treatment of WON, and good short-term outcomes were achieved. In their study, the percutaneous approach allowed for irrigation and aspiration of WON. Meanwhile, the presence of transmural stents might prevent external pancreatic fistula formation, which was highly associated with percutaneous drainage. A total of 103/117 patients completed treatment and all the percutaneous drains were removed successfully without external pancreatic fistula formation. We speculate that patients with severe systemic compromise and organ failure who need percutaneous drainage as the first early intervention may also be the suitable candidates for this combined method. As for some patients with DPDS who have no conditions for standard endoscopic techniques (transmural or transpapillary drainage), several EUS-guided techniques including creation of an artificial PFC, outside-in transluminal puncture, and EUS-guided pancreatic (duct) drainage, can be attempted before surgery.[5] Nonetheless, above-mentioned procedures are technically challenging along with potential serious complications and their effectiveness has not been well defined.

CONCLUSION

Although reliable data are scarce, the partial and complete disruption of the MPD are reported to be as high as 50.49% and 30.89% in patients with WON.[54] More emphasis should be placed on our awareness of DPDS during the treatment of PFC as it may greatly affect the outcome. Despite the great advancements in endoscopic techniques, surgeries are still inevitable in many patients with PFC complicated with DPDS. We focus on the endoscopic management of PFC with DPDS in this study from an endoscopist perspective, but in fact a multidisciplinary approach involving interventional endoscopist, surgeon, and radiologist is absolutely desirable. Clearly, much work should be done to explore the optimal endoscopic management of PFC with DPDS.

Financial support and sponsorship

Dr. Yu Bai is supported by the National Natural Science Foundation of China (No. 82170567, 81873546), the "Shu Guang" project of Shanghai Municipal Education Commission and Shanghai Education Development Foundation (No. 19SG30, China) and 234 Discipline Climbing Plan of Changhai Hospital, Naval Medical University (No. 2019YXK004, China).

Conflicts of interest

Zhao-Shen Li is an Honorary Editor-in-Chief of the journal. This article was subject to the journal's standard procedures, with peer review handled independently of this editor and his research group.

REFERENCES

1. Boxhoorn L, Voermans RP, Bouwense SA, *et al.* Acute pancreatitis. *Lancet* 2020;396:726-34.
2. Chong E, Ratnayake CB, Saikia S, *et al.* Endoscopic transmural drainage is associated with improved outcomes in disconnected pancreatic duct syndrome: A systematic review and meta-analysis. *BMC Gastroenterol* 2021;21:87.
3. Pelaez-Luna M, Vege SS, Petersen BT, *et al.* Disconnected pancreatic duct syndrome in severe acute pancreatitis: Clinical and imaging characteristics and outcomes in a cohort of 31 cases. *Gastrointest Endosc* 2008;68:91-7.
4. Trikudanathan G, Wolbrink DR, van Santvoort HC, *et al.* Current concepts in severe acute and necrotizing pancreatitis: An evidence-based approach. *Gastroenterology* 2019;156:1994-2007.e3.
5. Verma S, Rana SS. Disconnected pancreatic duct syndrome: Updated review on clinical implications and management. *Pancreatology* 2020;20:1035-44.
6. Téllez-Aviña FI, Casasola-Sánchez LE, Ramírez-Luna MÁ, *et al.* Permanent indwelling transmural stents for endoscopic treatment of patients with disconnected pancreatic duct syndrome: Long-term results. *J Clin Gastroenterol* 2018;52:85-90.
7. van Brunschot S, van Grinsven J, van Santvoort HC, *et al.* Endoscopic or surgical step-up approach for infected necrotising pancreatitis: A multicentre randomised trial. *Lancet* 2018;391:51-8.
8. Bakker OJ, van Santvoort HC, van Brunschot S, *et al.* Endoscopic transgastric vs. surgical necrosectomy for infected necrotizing pancreatitis: A randomized trial. *JAMA* 2012;307:1053-61.
9. Elmunzer BJ. Endoscopic drainage of pancreatic fluid collections. *Clin Gastroenterol Hepatol* 2018;16:1851-63.e3.
10. Boxhoorn L, Timmerhuis HC, Verdonk RC, *et al.* Diagnosis and treatment of pancreatic duct disruption or disconnection: An international expert survey and case vignette study. *HPB (Oxford)* 2021;23:1201-8.
11. Larsen M, Kozarek RA. Management of disconnected pancreatic duct syndrome. *Curr Treat Options Gastroenterol* 2016;14:348-59.
12. Gans SL, van Westreenen HL, Kiewiet JJ, *et al.* Systematic review and meta-analysis of somatostatin analogues for the treatment of pancreatic

fistula. *Br J Surg* 2012;99:754-60.
13. Maatman TK, Roch AM, Lewellen KA, *et al*. Disconnected pancreatic duct syndrome: Spectrum of operative management. *J Surg Res* 2020;247:297-303.
14. Fischer TD, Gutman DS, Hughes SJ, *et al*. Disconnected pancreatic duct syndrome: Disease classification and management strategies. *J Am Coll Surg* 2014;219:704-12.
15. Nadkarni NA, Kotwal V, Sarr MG, *et al*. Disconnected pancreatic duct syndrome: Endoscopic stent or surgeon's knife? *Pancreas* 2015;44:16-22.
16. Kozarek RA, Ball TJ, Patterson DJ, *et al*. Endoscopic transpapillary therapy for disrupted pancreatic duct and peripancreatic fluid collections. *Gastroenterology* 1991;100:1362-70.
17. Varadarajulu S, Noone TC, Tutuian R, *et al*. Predictors of outcome in pancreatic duct disruption managed by endoscopic transpapillary stent placement. *Gastrointest Endosc* 2005;61:568-75.
18. van Dijk SM, Timmerhuis HC, Verdonk RC, *et al.* Treatment of disrupted and disconnected pancreatic duct in necrotizing pancreatitis: A systematic review and meta-analysis. *Pancreatology* 2019;19:905-15.
19. Nealon WH, Bhutani M, Riall TS, *et al*. A unifying concept: Pancreatic ductal anatomy both predicts and determines the major complications resulting from pancreatitis. *J Am Coll Surg* 2009;208:790-9.
20. Vanek P, Trikudanathan G, Freeman ML. Diagnosing disconnected pancreatic duct syndrome: Many disconnects, few answers. *Dig Dis Sci* 2021;66:1380-2.
21. Arvanitakis M, Dumonceau JM, Albert J, *et al.* Endoscopic management of acute necrotizing pancreatitis: European Society of Gastrointestinal Endoscopy (ESGE) evidence-based multidisciplinary guidelines. *Endoscopy* 2018;50:524-46.
22. Sandrasegaran K, Tann M, Jennings SG, *et al.* Disconnection of the pancreatic duct: An important but overlooked complication of severe acute pancreatitis. *Radiographics* 2007;27:1389-400.
23. Wong YC, Wang LJ, Fang JF, *et al*. Multidetector-row computed tomography (CT) of blunt pancreatic injuries: Can contrast-enhanced multiphasic CT detect pancreatic duct injuries? *J Trauma* 2008;64:666-72.
24. Itoh S, Ikeda M, Ota T, *et al*. Assessment of the pancreatic and intrapancreatic bile ducts using 0.5-mm collimation and multiplanar reformatted images in multislice CT. *Eur Radiol* 2003;13:277-85.
25. Anderson SW, Soto JA. Pancreatic duct evaluation: Accuracy of portal venous phase 64 MDCT. *Abdom Imaging* 2009;34:55-63.
26. O'Toole D, Vullierme MP, Ponsot P, *et al.* Diagnosis and management of pancreatic fistulae resulting in pancreatic ascites or pleural effusions in the era of helical CT and magnetic resonance imaging. *Gastroenterol Clin Biol* 2007;31:686-93.
27. Drake LM, Anis M, Lawrence C. Accuracy of magnetic resonance cholangiopancreatography in identifying pancreatic duct disruption. *J Clin Gastroenterol* 2012;46:696-9.
28. Soto JA, Alvarez O, Múnera F, *et al*. Traumatic disruption of the pancreatic duct: Diagnosis with MR pancreatography. *AJR Am J Roentgenol* 2001;176:175-8.
29. Rosenfeld EH, Vogel A, Russell RT, *et al*. Comparison of diagnostic imaging modalities for the evaluation of pancreatic duct injury in children: A multi-institutional analysis from the Pancreatic Trauma Study Group. *Pediatr Surg Int* 2018;34:961-6.
30. Varadarajulu S, Rana SS, Bhasin DK. Endoscopic therapy for pancreatic duct leaks and disruptions. *Gastrointest Endosc Clin N Am* 2013;23:863-92.
31. Gillams AR, Kurzawinski T, Lees WR. Diagnosis of duct disruption and assessment of pancreatic leak with dynamic secretin-stimulated MR cholangiopancreatography. *AJR Am J Roentgenol* 2006;186:499-506.
32. Sherman S, Freeman ML, Tarnasky PR, *et al*. Administration of secretin (RG1068) increases the sensitivity of detection of duct abnormalities by magnetic resonance cholangiopancreatography in patients with pancreatitis. *Gastroenterology* 2014;147:646-54.e2.
33. Bang JY, Navaneethan U, Hasan MK, *et al.* EUS correlates of disconnected pancreatic duct syndrome in walled-off necrosis. *Endosc Int Open* 2016;4:E883-9.
34. Timmerhuis HC, van Dijk SM, Verdonk RC, *et al.* Various modalities accurate in diagnosing a disrupted or disconnected pancreatic duct in acute pancreatitis: A systematic review. *Dig Dis Sci* 2021;66:1415-24.
35. Banks PA, Bollen TL, Dervenis C, *et al*. Classification of acute pancreatitis-2012: Revision of the Atlanta classification and definitions by international consensus. *Gut* 2013;62:102-11.
36. van Santvoort HC, Bakker OJ, Bollen TL, *et al.* A conservative and minimally invasive approach to necrotizing pancreatitis improves outcome. *Gastroenterology* 2011;141:1254-63.
37. Boxhoorn L, van Dijk SM, van Grinsven J, *et al.* Immediate versus postponed intervention for infected necrotizing pancreatitis. *N Engl J Med* 2021;385:1372-81.
38. Teoh AY, Dhir V, Kida M, *et al.* Consensus guidelines on the optimal management in interventional EUS procedures: Results from the Asian EUS group RAND/UCLA expert panel. *Gut* 2018;67:1209-28.
39. ASGE Standards of Practice Committee; Muthusamy VR, Chandrasekhara V, Acosta RD, *et al.* The role of endoscopy in the diagnosis and treatment of inflammatory pancreatic fluid collections. *Gastrointest Endosc* 2016;83:481-8.
40. Bang JY, Wilcox CM, Navaneethan U, *et al.* Impact of disconnected pancreatic duct syndrome on the endoscopic management of pancreatic fluid collections. *Ann Surg* 2018;267:561-8.
41. Hamada T, Iwashita T, Saito T, *et al.* Disconnected pancreatic duct syndrome and outcomes of endoscopic ultrasound-guided treatment of pancreatic fluid collections: Systematic review and meta-analysis. *Dig Endosc* 2021. doi:10.1111/den.14142. Online ahead of print.
42. Jang JW, Kim MH, Oh D, *et al.* Factors and outcomes associated with pancreatic duct disruption in patients with acute necrotizing pancreatitis. *Pancreatology* 2016;16:958-65.
43. Lawrence C, Howell DA, Stefan AM, *et al.* Disconnected pancreatic tail syndrome: Potential for endoscopic therapy and results of long-term follow-up. *Gastrointest Endosc* 2008;67:673-9.
44. Devière J, Bueso H, Baize M, *et al*. Complete disruption of the main pancreatic duct: Endoscopic management. *Gastrointest Endosc* 1995;42:445-51.
45. Chen Y, Jiang Y, Qian W, *et al.* Endoscopic transpapillary drainage in disconnected pancreatic duct syndrome after acute pancreatitis and trauma: Long-term outcomes in 31 patients. *BMC Gastroenterol* 2019;19:54.
46. Schutz SM, Leung JW. Pancreatic endotherapy for pseudocysts and fluid collections. *Gastrointest Endosc* 2002;56:150-2.
47. Baron TH. Endoscopic drainage of pancreatic fluid collections and pancreatic necrosis. *Gastrointest Endosc Clin N Am* 2003;13:743-64.
48. Smoczyński M, Jagielski M, Jabłońska A, *et al*. Transpapillary drainage of walled-off pancreatic necrosis – A single center experience. *Wideochir Inne Tech Maloinwazyjne* 2016;10:527-33.
49. Hookey LC, Debroux S, Delhaye M, *et al*. Endoscopic drainage of pancreatic-fluid collections in 116 patients: A comparison of etiologies, drainage techniques, and outcomes. *Gastrointest Endosc* 2006;63:635-43.
50. Yang D, Amin S, Gonzalez S, *et al.* Transpapillary drainage has no added benefit on treatment outcomes in patients undergoing EUS-guided transmural drainage of pancreatic pseudocysts: A large multicenter study. *Gastrointest Endosc* 2016;83:720-9.
51. Amin S, Yang DJ, Lucas AL, *et al.* There is no advantage to transpapillary pancreatic duct stenting for the transmural endoscopic drainage of pancreatic fluid collections: A meta-analysis. *Clin Endosc* 2017;50:388-94.
52. Shrode CW, Macdonough P, Gaidhane M, *et al.* Multimodality endoscopic treatment of pancreatic duct disruption with stenting and pseudocyst drainage: How efficacious is it? *Dig Liver Dis* 2013;45:129-33.
53. Trevino JM, Tamhane A, Varadarajulu S. Successful stenting in ductal disruption favorably impacts treatment outcomes in patients undergoing transmural drainage of peripancreatic fluid collections. *J Gastroenterol Hepatol* 2010;25:526-31.
54. Jagielski M, Smoczyński M, Adrych K. The role of endoscopic treatment of pancreatic duct disruption in patients with walled-off pancreatic necrosis. *Surg Endosc* 2018;32:4939-52.
55. Sherman S, Hawes RH, Savides TJ, *et al.* Stent-induced pancreatic ductal and parenchymal changes: Correlation of endoscopic ultrasound with ERCP. *Gastrointest Endosc* 1996;44:276-82.
56. Wang L, Elhanafi S, Storm AC, *et al.* Impact of disconnected pancreatic

duct syndrome on endoscopic ultrasound-guided drainage of pancreatic fluid collections. *Endoscopy* 2021;53:603-10.
57. Gkolfakis P, Bourguignon A, Arvanitakis M, *et al.* Indwelling double-pigtail plastic stents for treating disconnected pancreatic duct syndrome-associated peripancreatic fluid collections: Long-term safety and efficacy. *Endoscopy* 2021;53:1141-9.
58. Bang JY, Hasan M, Navaneethan U, *et al*. Lumen-apposing metal stents (LAMS) for pancreatic fluid collection (PFC) drainage: May not be business as usual. *Gut* 2017;66:2054-6.
59. Rana SS, Bhasin DK, Rao C, *et al*. Consequences of long term indwelling transmural stents in patients with walled off pancreatic necrosis & disconnected pancreatic duct syndrome. *Pancreatology* 2013;13:486-90.
60. Rana SS, Shah J, Sharma RK, *et al*. Clinical and morphological consequences of permanent indwelling transmural plastic stents in disconnected pancreatic duct syndrome. *Endosc Ultrasound* 2020;9:130-7.
61. Basha J, Lakhtakia S, Nabi Z, *et al.* Impact of disconnected pancreatic duct on recurrence of fluid collections and new-onset diabetes: Do we finally have an answer? *Gut* 2021;70:447-9.
62. Dhir V, Adler DG, Dalal A, *et al*. Early removal of biflanged metal stents in the management of pancreatic walled-off necrosis: A prospective study. *Endoscopy* 2018;50:597-605.
63. Rana SS, Gupta R. Walled of necrosis, disconnected pancreatic duct and metal stents: The debate continues! *Gut* 2021;70:2007.
64. Yamauchi H, Iwai T, Kida M, *et al.* Complications of long-term indwelling transmural double pigtail stent placement for symptomatic peripancreatic fluid collections. *Dig Dis Sci* 2019;64:1976-84.
65. Ross AS, Irani S, Gan SI, *et al.* Dual-modality drainage of infected and symptomatic walled-off pancreatic necrosis: Long-term clinical outcomes. *Gastrointest Endosc* 2014;79:929-35.