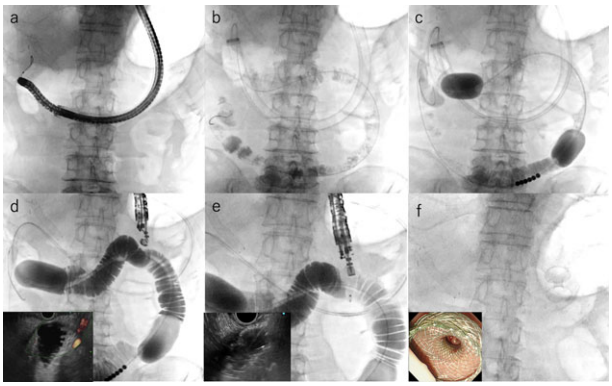

Figure 2 Fluoroscopy and endoscopic ultrasonography (EUS) image of endoscopic ultrasonography-guided double-balloon-occluded gastrojejunostomy bypass procedure. (a) A standard upper gastrointestinal endoscope is inserted in front of the duodenal stenosis, and a guide wire (GW) is inserted using an endoscopic retrograde cholangiopancreatography catheter. (b) The GW was advanced far enough proximal to the jejunum and we removed the endoscope (recently we have used an over tube to insert the enteric tube easily). (c) A double-balloon tube is advanced across the stomach over the wire and the balloons are inflated. (d) Fluoroscopic image shows distended jejunum using saline with contrast medium between two balloons observed by EUS. EUS image shows distended jejunum and we confirmed that no blood vessel was present (lower left). (e) The distal flange is deployed in the jejunum. EUS image shows deployed distal flange (lower left). (f) Fluoroscopic image shows well-deployed lumen-apposing metal stent. Endoscopic image shows nicely opened proximal flange in the stomach (lower left).

CONFLICTS OF INTEREST

AUTHORS DECLARE NO conflicts of interest for this article.

Takayoshi Tsuchiya, Atsushi Sofuni and Takao Itoi
Department of Gastroenterology and Hepatology, Tokyo Medical University, Tokyo, Japan
doi: 10.1111/den.13360

REFERENCES

1 Itoi T, Ishii K, Ikeuchi N *et al.* Prospective evaluation of endoscopic ultrasonography-guided double-balloon-occluded gastrojejunostomy bypass (EPASS) for malignant gastric outlet obstruction. *Gut* 2016; **65**: 193–5.
2 Itoi T, Baron TH, Khashab MA *et al.* Technical review of endoscopic ultrasonography-guided gastroenterostomy in 2017. *Dig. Endosc.* 2017; **29**: 495–502.
3 Chen YI, Kunda R, Storm AC *et al.* EUS-guided gastroenterostomy: a multicenter study comparing the direct and balloon-assisted techniques. *Gastrointest. Endosc.* 2018; **87**: 1215–21.
4 Perez-Miranda M, Tyberg A, Poletto D *et al.* EUS-guided gastrojejunostomy versus laparoscopic gastrojejunostomy: an international collaborative study. *J. Clin. Gastroenterol.* 2017; **51**: 896–9.

Current problems and clinical results of endoscopic necrosectomy for walled-off pancreatic necrosis

Pancreatic necrosis affects approximately 20% of all patients with acute pancreatitis. Infected pancreatic necrosis is a major risk factor for sepsis-related multiple organ failure.[1] The development of walled-off necrosis (WON) is a late complication of acute severe necrotizing pancreatitis, and endoscopic necrosectomy (EN) has become an effective treatment for infected WON. A multicenter study[2–4] of EN in WON revealed clinical success rates from 75% to 91%. However, high mortality and morbidity rates of 6.7–11% and 14–33%, respectively, were found.

Figure 1 shows treatment results for WON cases at our institution between 2002 and 2017. Twenty-three patients with infected WON underwent endoscopic drainage as an initial treatment. Of these, 13 showed complete resolution without EN. Of the 10 patients who underwent EN, nine showed complete resolution following a median of four EN sessions; however, one patient with incomplete resolution died due to multiple organ dysfunction. The clinical success

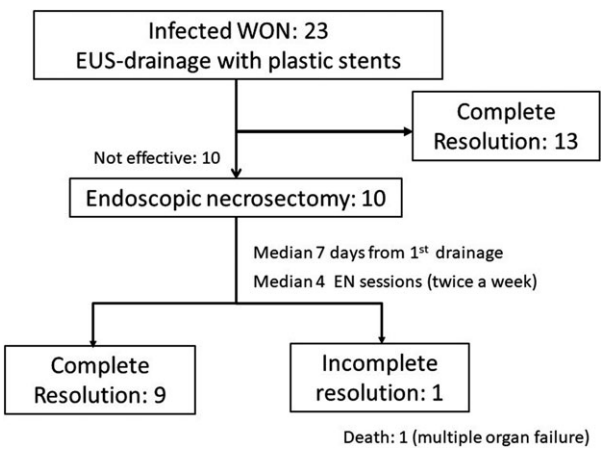

Figure 1 Clinical results of patients with infected walled-off pancreatic necrosis (WON) with endoscopic drainage. EN, endoscopic necrosectomy; EUS, endoscopic ultrasound

© 2019 Japan Gastroenterological Endoscopy Society

DEN Digestive Endoscopy For Gastroenterologists and Endoscopic Surgeons

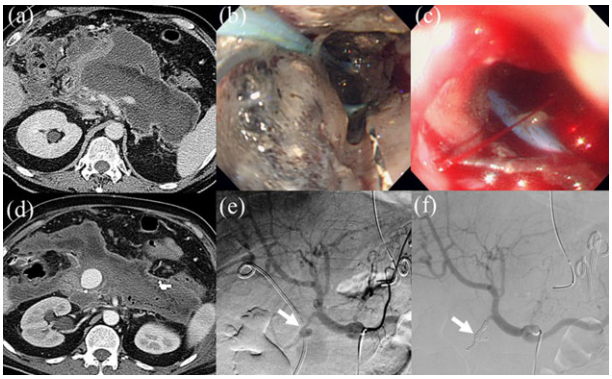

Figure 2 (a) A contrast-enhanced computed tomography (CE–CT) image showing walled-off pancreatic necrosis (WON). (b) Endoscopic image during endoscopic necrosectomy (EN). (c) Pulsatile bleeding from the cavity wall occurred during EN. (d) A CE–CT image revealed a pseudoaneurysm at the cavity wall. (e) An interventional radiological image showing an extravasation of contrast medium from the gastric duodenal artery (arrow). (f) We stopped the bleeding by coil embolization under interventional radiological guidance (arrow).

rate was 90%, and mortality and morbidity rates were 10% and 50%, respectively. The lost patient was a 44-year-old man with alcoholic pancreatitis. He was not an alcohol abuser and it was his first event of acute pancreatitis. The severity at 48 h was a new Japanese severity score of 4 with a computed tomography grade of 3. EN was performed eight times and the volume of necrotic cavity was reduced; however, the patient died after 136 hospital days. Details of complications included bleeding in two cases (one each from a fistula and the cavity wall), perforation in two cases and aspiration pneumonia in one case. All patients were managed without having to undergo surgery (Fig. 2).

More recently, several reports have described the use of a bi-flanged metal stent (BFMS) for WON with successful outcomes that reduced the need for EN.[5] However, long-term data on the use of BFMS for this disease is limited.

CONFLICTS OF INTEREST

AUTHORS DECLARE NO conflicts of interest for this article.

Kazuyuki Matsumoto, Hironari Kato and Hiroyuki Okada
Department of Gastroenterology and Hepatology, Okayama University Graduate School of Medicine, Dentistry and Pharmaceutical Sciences, Okayama, Japan
doi: 10.1111/den.13358

REFERENCES

1 van Santvoort HC, Bakker OJ, Bollen TL *et al.* A conservative and minimally invasive approach to necrotizing pancreatitis improves outcome. *Gastroenterology* 2011; **141**: 1254–63.
2 Yasuda I, Nakashima M, Iwai T *et al.* Japanese multicenter experience of endoscopic necrosectomy for infected walled-off pancreatic necrosis: the JENIPaN study. *Endoscopy* 2013; **45**: 627–34.
3 Seifert H, Biermer M, Schmitt W *et al.* Transluminal endoscopic necrosectomy after acute pancreatitis: a multicenter study with long-term follow-up (the GEPARD Study). *Gut* 2009; **58**: 1260–6.
4 Gardner TB, Coelho-Prabhu N, Gordon SR *et al.* Direct endoscopic necrosectomy for the treatment of walled-off pancreatic necrosis: results from a multicenter US series. *Gastrointest. Endosc.* 2011; **73**: 718–26.
5 Lakhtakia S, Basha J, Talukdar R *et al.* Endoscopic "step-up approach" using a dedicated biflanged metal stent reduces the need for direct necrosectomy in walled-off necrosis (with videos). *Gastrointest. Endosc.* 2017; **85**: 1243–52.

© 2019 Japan Gastroenterological Endoscopy Society

14431661, 2019, S1, Downloaded from https://onlinelibrary.wiley.com/doi/10.1111/den.13358 by Columbia University Libraries, Wiley Online Library on [21/02/2026]. See the Terms and Conditions (https://onlinelibrary.wiley.com/terms-and-conditions) on Wiley Online Library for rules of use; OA articles are governed by the applicable Creative Commons License