

International Vaccine Institute, Seoul 08826, South Korea (JI, RB, HJJ, FM); Princeton University, Princeton, NJ, USA (RB); Bali Health Laboratory of Health Office, Denpasar, Indonesia (NWy); Paediatric Department, Medical Faculty, Udayana University and Sanglah General Hospital, Denpasar, Indonesia (IGNS); Provincial Health Office, Denpasar, Indonesia (ARA); WHO, Indonesia Country Office, Jakarta, Indonesia (VB); International Centre for Diarrheal Disease Research, Bangladesh, Dhaka, Bangladesh (JDC); University of California, Fielding School of Public Health, Los Angeles, CA, USA (JDC); School of Medicine, Korea University, Seoul, South Korea (JDC); and Department of Medicine, University of Cambridge, Cambridge CB2 0QQ, UK (FM)

- 1 WHO. Japanese encephalitis. 2015. <http://www.who.int/mediacentre/factsheets/fs386/en> (accessed Jan 15, 2018).
- 2 Wang H, Liang G. Epidemiology of Japanese encephalitis: past, present, and future prospects. *Ther Clin Risk Manag* 2015; **11**: 435–48.
- 3 Lim YA, Kim HH, Joung US, et al. The development of a national surveillance system for monitoring blood use and inventory levels at sentinel hospitals in South Korea. *Transfus Med* 2010; **20**: 104–12.
- 4 Arai S, Matsunaga Y, Takasaki T, et al. Japanese encephalitis: surveillance and elimination effort in Japan from 1982 to 2004. *Jpn J Infect Dis* 2008; **61**: 333–38.
- 5 Macdonald WB, Tink AR, Ouvrier RA, et al. Japanese encephalitis after a two-week holiday in Bali. *Med J Aust* 1989; **150**: 334–36, 339.
- 6 Wittesjö B, Eitrem R, Niklasson B, Vene S, Mangiafico J. Japanese encephalitis after a 10-day holiday in Bali. *Lancet* 1995; **345**: 856–57.
- 7 Buhl MR, Black FT, Andersen PL, Laursen A. Fatal Japanese encephalitis in a Danish tourist visiting Bali for 12 days. *Scand J Infect Dis* 1996; **28**: 189.
- 8 Kari K, Liu W, Gautama K, et al. A hospital-based surveillance for Japanese encephalitis in Bali, Indonesia. *BMC Med* 2006; **4**: 8.
- 9 Statistik Peternakan Dan Kesehatan Hewan. Livestock and animal health statistics. [http://ditjenpkh.pertanian.go.id/userfiles/File/Buku_Statistik_2017_\(ebook\).pdf?time=1505127443012](http://ditjenpkh.pertanian.go.id/userfiles/File/Buku_Statistik_2017_(ebook).pdf?time=1505127443012) (accessed April 5, 2018).
- 10 WHO. Newly accessible Japanese encephalitis vaccine will make saving children easier in developing countries. 2014. http://www.who.int/mediacentre/news/releases/2013/japanese_encephalitis_20131009/en (accessed Feb 26, 2018).

Alpha-chain disease: a lymphomagenesis model

Science is generally more interested in exploring the unknowns and mysteries of the present and future than in commemorating events of the

past. However, recalling certain works (ie, apparent breakthroughs in their given field at the time of publication) to measure their contributions and the progress made over the ensuing years, can be useful. In this case, alpha-chain disease is of paramount interest. Thanks to the exemplary collaboration between a clinician, Jean-Claude Rambaud, and a physician scientist in immunology, Maxime Seligmann, the discovery in 1968 of alpha-chain disease^{1,2} in a young Syrian woman with an abdominal lymphoma led to game-changing outcomes over the following 50 years, including a model of lymphomagenesis that is still in progress.

First, the discovery of alpha-chain disease made it possible to attribute to this disease most cases (up to 87%) of Mediterranean lymphoma—previously described in the Middle East in the early 1960s—and gave a specific and previously absent immunological marker to this type of lymphoma in low-income countries.³ Alpha-chain disease shows a marked epidemiology, primarily affecting individuals from developing countries including India and those in the Mediterranean, the Middle East, Africa, and South America, where low socioeconomic status, poor hygiene, malnutrition, enteric infections, and parasitoses are common. The prevalence of alpha-chain disease has recently decreased in parallel with improved socioeconomic conditions, particularly sanitation.

Second, the discovery of alpha-chain disease and its natural history shed light on an original model of lymphoma development potentially related to the intestinal microbiome. From an initial phase of plasmacytic proliferation, which appears benign from a morphological perspective and might fully regress with oral antibiotics alone, alpha-chain disease progresses to an overt malignant immunoblastic lymphoma derived from the initial plasma cell clone.³

Third, alpha-chain disease led to the concept of immunoproliferative

small intestinal disease, internationally recognised by WHO in 1976.⁴ Furthermore, alpha-chain disease, which affects the IgA secretory immune system, greatly contributed to the establishment in the early 1980s of the concept of infection-related mucosa-associated lymphoid tissue lymphomas, derived from B cells of the marginal zone.⁵ This discovery turned immunoproliferative small intestinal disease into a model of antigen-driven, preventable lymphoproliferation in humans, especially from low-income countries.⁵ Finally, alpha-chain disease and immunoproliferative small intestinal disease still constitutes an exciting model of the development of antigen-driven B-cell lymphoma and should be stimulating further molecular genetic analyses, especially of the intestinal microbiome.⁶

I declare no competing interests.

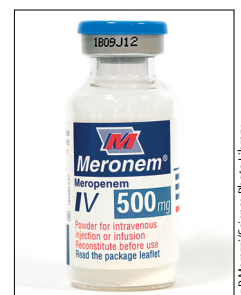
Claude Matuchansky
claude.matuchansky@wanadoo.fr

Faculty of Medicine, Paris-Diderot University, 75010 Paris, France

- 1 Rambaud JC, Bognel C, Prost A, et al. Clinico-pathological study of a patient with "Mediterranean" type of abdominal lymphoma and a new type of IgA abnormality ("alpha chain disease"). *Digestion* 1968; **1**: 321–36.
- 2 Seligmann M, Danon, F, Hurez D, Mihaesco E, Preud'Homme JL. Alpha-chain disease: a new immunoglobulin abnormality. *Science* 1968; **162**: 1396–97.
- 3 Salem PA, Estephan FF. Immunoproliferative small intestinal disease: current concepts. *Cancer J* 2005; **11**: 374–82.
- 4 Alpha-chain disease and related small-intestinal lymphoma: a memorandum. *Bull World Health Organ* 1976; **54**: 615–24.
- 5 Isaacson PG, Du MQ. MALT lymphoma: from morphology to molecules. *Nat Rev Cancer* 2004; **4**: 644–53.
- 6 Bianchi G, Sohani AR. Heavy chain disease of the small bowel. *Curr Gastroenterol Rep* 2018; **20**: 3.

Infected necrotising pancreatitis: antibiotic administration remains the first step

We appreciate the important work published by Sandra van Brunschot and colleagues in *The Lancet* (Jan 6, p 51)¹ comparing endoscopic



Dr P Manazil/Science Photo Library

with surgical step-up approaches for the management of infected necrotising pancreatitis. We are, however, concerned by the paucity of data provided regarding antibiotic management.

Antibiotics are considered to be the first step in the management of infected necrosis.^{2,3} The authors report that antibiotics were used in cases of suspected infected necrosis to postpone intervention, but at the time of randomisation, only 20% of the patients had received antibiotics. Details about the subsequent introduction of antibiotics, including microbiological data and details of drug choice, dosage, and duration, were not discussed. These data are particularly important in the context of a recent report by the same group that 5% of patients with infected necrosis could be successfully managed with supportive care and antibiotic therapy, without additional intervention.⁴ The authors report that two patients in this study were randomly assigned, but subsequently had spontaneous improvement. However, the criteria for spontaneous clinical improvement are not discussed. Does a subset of clinically stable and minimally symptomatic patients exist with walled-off pancreatic necrosis who would never require drainage?

We declare no competing interests.

*Nicolas Nessler, James T Ross, Yannick Mallédant
nicolas.nesseler@chu-rennes.fr

Intensive Care Unit, Anesthesia and Critical Care Department, Pontchaillou University Hospital, Rennes 35033, France (NN, YM); and Department of Surgery, University of California, San Francisco, CA, USA (JTR)

- 1 van Brunschot S, van Grinsven J, van Santvoort HC, et al. Endoscopic or surgical step-up approach for infected necrotising pancreatitis: a multicentre randomised trial. *Lancet* 2018; **391**: 51–58.
- 2 Lankisch PG, Apte M, Banks PA. Acute pancreatitis. *Lancet* 2015; **386**: 85–96.
- 3 Mallédant Y, Malbrain MLNG, Reuter DA. What's new in the management of severe acute pancreatitis? *Intensive Care Med* 2015; **41**: 1957–60.
- 4 van Santvoort HC, Bakker OJ, Bollen TL, et al. A conservative and minimally invasive approach to necrotizing pancreatitis improves outcome. *Gastroenterology* 2011; **141**: 1254–63.

Authors' reply

We agree with Nicolas Nessler and colleagues¹ that intravenous antibiotics should be the first step in the treatment of infected necrosis. Antibiotics can postpone intervention in patients with infected necrosis until it is walled off. In a small group of patients, antibiotics will be the only treatment required, obviating the need for invasive interventions.² We have previously shown that this subgroup consists of approximately 3% of patients with infected necrotising pancreatitis.³

In our trial (Jan 6, p 51),⁴ antibiotics were used to postpone intervention in patients with suspected infected necrosis. In each group, one patient did not receive an intervention because of rapid clinical improvement shortly after randomisation while being treated with antibiotics. Clinical improvement was comparable with the definition of clinical improvement in the post-intervention phase of the study. Besides the use of antibiotics, another possible explanation for this improvement could be spontaneous fistulation of the infected collection to the gastrointestinal tract. However, no endoscopy or imaging was done and, therefore, this remains hypothetical.

At the time of randomisation, only 20% of patients received antibiotic treatment according to our trial registry. Since a substantial number of patients were transferred to a participating tertiary centre just before randomisation, not all data on previous antibiotic use might have been registered. More patients might have received antibiotic treatment at some stage leading up to randomisation.

Generally, we agree with the statement that antibiotics can be useful to postpone interventions in infected necrotising pancreatitis and might prevent the need for an invasive intervention in a small subgroup of patients. Nevertheless, we feel that infected walled-off necrosis should primarily be treated with catheter drainage until we have solid clinical evidence of which

subgroup of patients' antibiotics are likely to be a definitive treatment. The Dutch Pancreatitis Study Group is currently running the POINTER trial (ISRCTN33682933) that compares the effect of immediate intervention (ie, catheter drainage within 24 h) versus the current approach of delaying intervention and first using antibiotics until the stage of walled-off necrosis. This trial might provide further insight into the additional value of antibiotics as the first step of the existing step-up approach.

PF reports grants from Boston Scientific and Ovesco, and personal fees from Olympus, Cook, Ethicon Endosurgery, Medtronic, and Fujifilm outside the submitted work. All other authors declare no competing interests.

*Sandra van Brunschot, Hjalmar van Santvoort, Marc Besselink, Paul Fockens
s.vanbrunschot@pancreatitis.nl

Department of Gastroenterology and Hepatology (SvB, PF), and Department of Surgery (MB), Academic Medical Center, University of Amsterdam, 1105 AZ Amsterdam, Netherlands; Department of Surgery, St Antonius Hospital, Nieuwegein, Netherlands (HvS); and Department of Surgery, University Medical Center Utrecht, Cancer Center, Utrecht, Netherlands (HvS)

- 1 Lankisch PG, Apte M, Banks PA. Acute pancreatitis. *Lancet* 2015; **386**: 85–96.
- 2 Malledant Y, Malbrain ML, Reuter DA. What's new in the management of severe acute pancreatitis? *Intensive Care Med* 2015; **41**: 1957–60.
- 3 van Santvoort HC, Bakker OJ, Bollen TL, et al. A conservative and minimally invasive approach to necrotizing pancreatitis improves outcome. *Gastroenterology* 2011; **141**: 1254–63.
- 4 van Brunschot S, van Grinsven J, van Santvoort HC, et al. Endoscopic or surgical step-up approach for infected necrotising pancreatitis: a multicentre randomised trial. *Lancet* 2018; **391**: 51–58.