

Surgical Management of Necrotizing Pancreatitis

Dane Thompson, Siavash Bolourani and Matthew Giangola

Abstract

Pancreatic necrosis is a highly morbid condition. It is most commonly associated with severe, acute pancreatitis, but can also be caused by trauma or chronic pancreatitis. Once diagnosed, management of pancreatic necrosis begins with supportive care, with an emphasis on early, and preferably, enteral nutrition. Intervention for necrosis, sterile or infected, is dictated by patient symptoms and response to conservative management. When possible, intervention should be delayed to allow the necrotic collection to form a capsule. First-line treatment for necrosis is with percutaneous drainage or endoscopic, transmural drainage. These strategies can be effective as monotherapy, but the need for repeated interventions, or for progression to more invasive interventions, is not uncommon. Necrosectomy may be performed using a previously established drainage tract, as in percutaneous endoscopic necrosectomy (PEN), video-assisted retroperitoneal debridement (VARD), and direct endoscopic necrosectomy (DEN). Although outcomes for these minimally-invasive techniques are better than for traditional necrosectomy, both laparoscopic and open techniques remain important for patients with extensive disease that cannot otherwise be adequately treated. This is especially true when pancreatic necrosis is complicated by disconnected pancreatic duct syndrome (DPDS), where necrosectomy remains standard of care.

Keywords: necrotizing pancreatitis, pancreatic necrosis, percutaneous, endoscopic, pancreatectomy, necrosectomy

1. Introduction

Pancreatic necrosis is the presence of nonviable pancreatic parenchyma or peripancreatic fat which may be localized or diffuse. It is classified radiologically according to the Atlanta Criteria as an acute necrotic collection (ANC), which is defined as a non-encapsulated area of necrosis, or as walled-off necrosis (WON), which is encapsulated [1]. Although pancreatic necrosis may result from trauma, malignancy, or chronic pancreatitis, the most common cause is acute pancreatitis; 20% of patients with acute pancreatitis develop necrosis. For patients who develop necrosis, the mortality rate is 15–30% [2]. Surgery has historically been the primary treatment for pancreatic necrosis. However, the superior outcomes associated with new, less invasive techniques have narrowed the scope for surgical intervention. Despite these shifts in practice, surgical care remains an important tool for the treatment of pancreatic necrosis.

2. Diagnosis and conservative management

Although the diagnosis of pancreatitis is generally clinical, the primary diagnostic tool for pancreatic necrosis is the computed tomography (CT) scan. With this modality, normal pancreatic parenchyma is low attenuation, 40–50 Hounsfield units (HU), but increases with contrast to 100–150 HU. In comparison, areas of necrosis remain hypoattenuating, <30 HU [3]. MRI and endoscopic ultrasound are also used, but CT scan is considered to be the gold standard for diagnosis and characterization [4].

Regardless of the presence of necrosis, fluid resuscitation, and early nutritional support are paramount to the treatment of patients with acute pancreatitis. For patients who are able to tolerate enteral nutrition, there is a significant reduction in the rates of infected pancreatic necrosis, multiorgan failure, surgical intervention, and mortality when compared to patients who are given total parenteral nutrition (TPN) [5, 6]. Thus, prior to initiation of TPN, patients should be evaluated for tolerance of oral, nasogastric, and nasojejunal feeding. Route notwithstanding, nutrition should be addressed in the first 24–48 hours of admission for acute pancreatitis [7].

Sterile pancreatic necrosis does not have a specific clinical presentation, but is more common in patients with symptoms lasting more than 48 hours and with concomitant organ failure [8]. The morbidity and mortality associated with pancreatic necrosis is exacerbated by development of infection, which may result of seeding associated with bacteremia, colonic bacterial translocation, or direct contamination from a procedure (e.g. endoscopic retrograde cholangiopancreatography (ERCP) or surgery) [9]. The risk of infection correlates with the degree of necrosis. If more than 30% of the pancreatic parenchyma is necrotic, there is a 22% risk of infection. If 30–50% is necrotic, the risk of infection is 37%. If necrosis exceeds 50%, the risk of infection is 46% [10]. The signs and symptoms of infected pancreatic necrosis are similar to those of other types of infection, including: fever, leukocytosis, and worsening condition with optimal supportive care. Once the necrosis becomes infected, the incidence of organ failure increases, along with the risk of mortality [11].

Differentiating sterile from infected necrosis based on clinical presentation can be difficult. Patients with sterile necrosis can proceed to organ failure in similar fashion to patients with infected necrosis. Infection can be detected non-invasively on CT scan by looking for the presence of gas locules within the area of necrosis, suggesting microbial gas production. However, these findings are not always seen on CT, and fine-needle aspiration (FNA) may be necessary for definitive diagnosis. Multiple FNA aspirates may be required due to the 10% false negative rate of this test [12].

However, proof of infection on radiology or by tissue culture is not necessary to initiate treatment. If infection is strongly suspected due to clinical course, antibiotics are indicated regardless of radiologic or tissue diagnosis. If no antibiotic sensitivities are available from culture results, broad-spectrum antibiotics should be started. Due to the ability to penetrate the necrotic tissue, carbapenems are considered first-line treatment [13]. Prophylactic use of antibiotics has not been shown to impact the rate of developing infected necrosis, systemic complications, mortality, or need for surgical intervention and is not recommended [14–16].

Prior to any invasive management, a patient should be treated with optimal supportive care. This includes fluid resuscitation, nutritional support, and antibiotics, if infection is suspected. The need for invasive management of sterile pancreatic necrosis is rare, especially in acute phase. However intervention may be necessary during the late phase for protracted abdominal pain, obstruction, or, less often, for

failure of clinical improvement. Infected necrosis requires invasive intervention more often, both in order to gain source control and in order to resolve other non-infectious symptoms [17].

3. Percutaneous and endoscopic interventions

Although percutaneous and endoscopic interventions have historically been considered temporizing measures, not definitive management, many patients with pancreatic necrosis are successfully treated with these techniques, without need for more invasive therapy. Percutaneous drainage can successfully treat acute necrotizing pancreatitis in more than 50% of patients without need for surgical necrosectomy. The success rate with endoscopic therapy can reach 80% when used in conjunction with DEN [18, 19]. Thus, development of less invasive methods for addressing pancreatic necrosis led to a decrease in the indications for surgical intervention. The choice of intervention, percutaneous or endoscopic, is dependent on the situation, timing, and accessibility of the area of necrosis (**Figure 1**).

Endoscopic management of pancreatic necrosis is performed transmurally, either across the duodenum, for pancreatic head necrosis, or the stomach, for neck or body necrosis. Although technically feasible earlier in the clinical course, endoscopic intervention should be delayed to 4 weeks after onset of symptoms in order for an appropriate capsule to form around the necrotic tissue [20]. In cases where intervention can be delayed until WON form, and the WON is accessible transmurally, this is considered first-line intervention [18].

With or without the aid of endoscopic ultrasound (EUS), a plastic or self-expanding metal stent (SEMS) is placed from the lumen of the duodenum or stomach into the area of WON. In addition to allowing the WON to drain into the

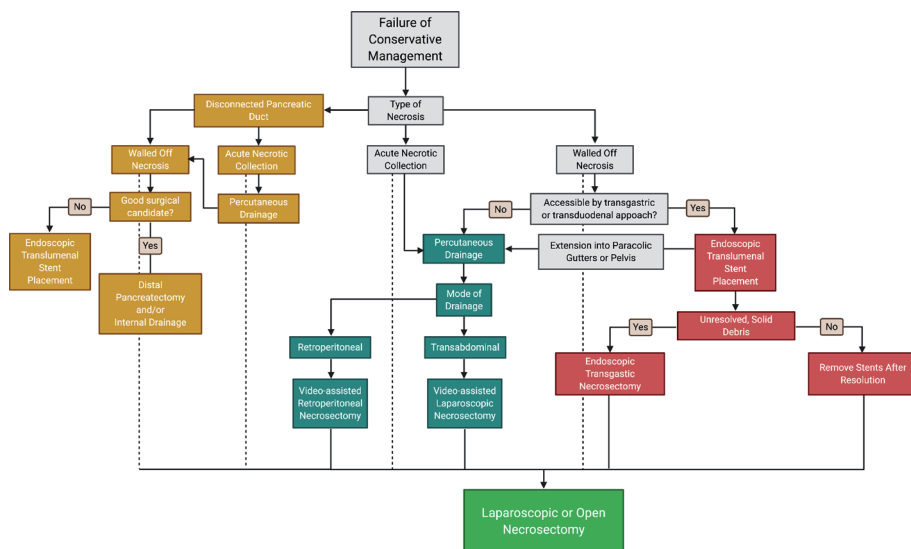


Figure 1. Flowchart for Management of Pancreatic Necrosis after Failure of conservative management. After failure of conservative management – Supportive care, antibiotics, and nutrition – The appropriate intervention depends on the nature of the necrosis. If it is associated with a disconnected duct, a separate pathway, which ends with distal pancreatectomy, internal drainage, or endoscopic transluminal stent placement, is indicated. If there is no disconnected duct, the correct pathway is dictated by the stage of necrosis, as a nonencapsulated acute necrotic collection or as walled off necrosis. Endoscopic and percutaneous strategies are preferred in each situation, and traditional, laparoscopic or open necrosectomy serves as the final option for patients that fail other management, or in hospitals without resources or staff to perform other procedures.

lumen, these stents also allow access to the area for debridement, via irrigation or DEN [21] (**Figure 2**). In DEN, an endoscope with one or two working ports is advanced through the previously placed, transluminal stent. Upon entering the WON, a number of tools, including forceps and snares are used to remove debris that would otherwise not be susceptible to removal with irrigation [21]. On average, 3–6 endoscopic interventions are necessary prior to resolution of necrosis [22].

DEN was first compared to surgical necrosectomy in the Pancreatitis, Endoscopic Transgastric vs. Primary Necrosectomy in Patients with Infected Necrosis (PENQUIN) Trial. In this trial, patients in the surgery group underwent a number of different operations, including 6 video-assisted retroperitoneal debridement (VARD) surgeries, 4 open necrosectomies, and 2 percutaneous drainage placements without need for more invasive therapy. The two patient who did not have a necrosectomy were excluded from final statistical analysis. All 10 patients in the endoscopic group had ultrasound guided stent placement, irrigation, and DEN. Following intervention, the rates of new-onset organ failure and pancreatic fistula were lower in the endoscopic group. The trial also compared the groups with regard to a composite clinical outcome, which included major post-operative complications and mortality, and found a lower rate in the endoscopic group [23, 24]. These findings were later replicated in the Minimally-invasive Surgery Versus Endoscopy Randomized (MISER) Trial. Additionally, MISER showed lower rates of pancreatic fistula formation and a higher quality of life at 3 months after surgery in the endoscopic group [25]. In the Transluminal Endoscopic Step-up Approach Versus Minimally-invasive Surgical Step-up Approach in Patients with Infected Necrotizing Pancreatitis (TENSION) Trial, a larger randomized trial, no difference in mortality was observed. However, the rates of pancreatic fistula and length of stay favored the endoscopic group [26].

Percutaneous drainage is preferable in patients that are deemed too unstable to tolerate endoscopic drainage or if the area of necrosis extends into a dependent

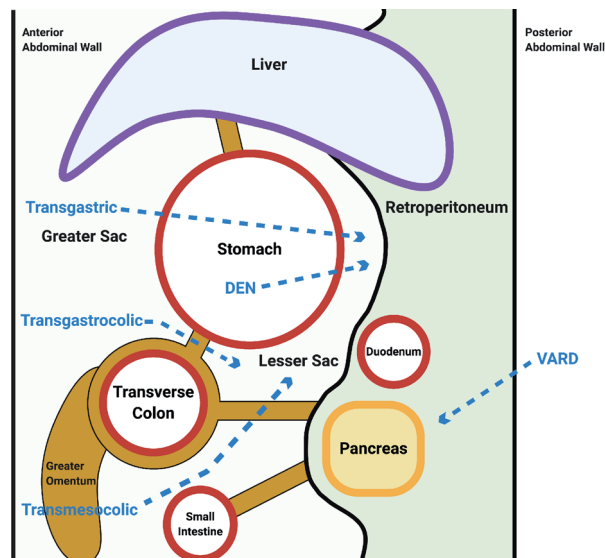


Figure 2. Surgical approaches to Necrosectomy. Access the lesser sac and retroperitoneum for the purposes of pancreatic necrosectomy can be achieved through a number of approaches. Direct endoscopic necrosectomy (DEN) is performed by accessing the stomach via the esophagus and then creating a posterior gastrotomy. The transgastric approach, performed laparoscopically or open, requires both an anterior and a posterior gastrotomy. The lesser sac can also be accessed by opening the gastrocolic ligament or transverse mesocolon, either by traversing a previously established, drainage tract or with a surgical approach.

space, such as the paracolic gutters or pelvis. It is also an acceptable alternative when endoscopic drainage is unavailable or not technically feasible, specifically in the setting of ANC, when there is no capsule that could support an endoscopic stent [27].

Percutaneous drainage is usually CT-guided, although ultrasound-guided drainage can also be performed. These drains may be transperitoneal, with the external portion of the drain fixed in the anterior abdominal wall. These drains may also be placed through the flank, directly into the retroperitoneum, without traversing the peritoneum. In addition to draining ANC and WON, percutaneous drains can also be used for irrigation [28].

Although percutaneous drainage is successful as monotherapy in some patients, patients with larger areas of necrosis, multifocal necrosis, incomplete liquefaction, and pre-procedural organ failure are less likely to be adequately treated. While some of these factors can be overcome with larger drainage catheters, for these reasons, percutaneous drainage remains a bridge to therapy, allowing patients to survive the acute period of disease, and undergo definitive management later, with improved outcomes [26, 29, 30].

4. General considerations for surgical management

Surgical management may be minimally-invasive or open, but has the same two primary goals: obtaining source control by removing as much necrotic tissue as possible and providing access for irrigation and drainage. As a general principle, minimally-invasive approaches are preferred to open necrosectomy as first-line treatment. The improved outcomes of minimally-invasive techniques lead to development of the “step-up” approach to management, which begins with percutaneous or endoscopic intervention, followed by a progression to surgical intervention as indicated by unresolved disease. However, the final treatment decision is dictated by the patient, surgeon, and available resources. A second principle is that surgical intervention should be delayed as long as possible in order to improve outcomes. Operating during the early, acute phase of pancreatitis, especially in the presence of ANC, rather than WON, is associated with higher morbidity and mortality regardless of surgical approach. A third principle is that long-term nutritional access, through a gastrostomy or gastrojejunostomy tube, should be obtained prior to concluding the procedure if no other method for enteral feeding has been established. Fourth, a cholecystectomy may also be performed if gallstones were implicated in the etiology of pancreatitis, provided the patient is adequately stable to undergo an additional procedure (**Figure 1**).

5. Minimally-invasive necrosectomy

VARD is a technique, used as the final phase of the step-up approach, where the retroperitoneum is accessed through a previously established, left flank, percutaneous drainage tract (**Figure 2**). The tract is then serially dilated, in order to accommodate progressively larger drainage catheters. At the time of surgery, in order to facilitate introduction of laparoscopic instruments, a small, 4–6 centimeter incision is made where the tract exits the skin. After confirming entry into the WON with a probe, tissue and fluid are removed with suction. The laparoscope is then inserted, with or without CO₂ insufflation, for continued debridement under direct visualization, using blunt laparoscopic forceps. Following debridement, again under direct visualization, large drainage catheters or chest tubes, 28-French or greater, are placed. After surgery, these catheters are used for repeated lavage as well as for drainage [31].

The superiority of VARD, and the step-up approach, compared to surgery for the treatment of necrotizing pancreatitis was first published in the Minimally-invasive Step-up Approach Versus Maximal Necrosectomy in Patients with Acute Necrotizing Pancreatitis (PANTER) Trial. In this study, 35% of the patients assigned to the step-up arm were successfully treated with percutaneous drainage alone. When comparing the step-up and surgical groups, the step-up group was less likely to have new-onset organ failure, less likely to develop an incisional hernia, and had an overall lower rate of endocrine insufficiency. However, the mortality rate was not significantly different, 19% in the step-up group versus 16% in surgery group [31].

A similar procedure, percutaneous endoscopic necrosectomy (PEN), can be performed utilizing a previously established percutaneous drainage tract. Unlike VARD, PEN utilizes a flexible endoscope, as compared to a rigid laparoscope. Because the endoscope has working ports, in addition to irrigation and suction, an additional incision around the tract is not needed. Also unlike VARD, PEN can be performed at bedside, with conscious sedation [32].

PEN was shown to be effective in a large, prospective study of 171 patients with infected pancreatic necrosis. The primary outcome investigated was control of sepsis and resolution of the infected collection. In this study, 18 of 26 (69%) patients with infected ANC and 23 of 27 (85%) with infected WON who underwent PEN were successfully treated, while the remainder required surgical necrosectomy. Predictors of failure included >50% parenchymal necrosis and early organ failure. ANC was not predictive. The overall mortality rate for this study was 38% [32, 33]. Although this technique has not been directly compared to surgery, VARD, or transmural endoscopy, this study demonstrated the safety and utility of PEN in patients with infected pancreatic necrosis.

Regardless of the type of minimally-invasive drainage, VARD or PEN, it has been shown that the “step-up approach,” beginning with drainage and progressing to debridement, is superior to upfront surgical approaches in terms of mortality, rates of pancreaticocutaneous fistula formation, and long-term morbidity [25, 30, 34].

6. Transgastric necrosectomy

In addition to utilizing a percutaneous drainage tract for necrosectomy, access can also be gained through the stomach. By entering the abdomen and opening the anterior wall of the stomach and then opening the posterior aspect of the stomach, access to the lesser sac and underlying pancreas is achieved (**Figure 2**). An aperture between the WON and posterior wall of the stomach is then created, either with sutures or by stapling, providing a definitive drainage tract. This tract is then used for necrosectomy following the same principles as DEN.

This approach is most well suited for WON limited to the lesser sac. When there is extensive necrosis extending to the retroperitoneum or paracolic gutters, VARD or traditional necrosectomy are more appropriate, due to the limited exposure with this method. These limitations are counterbalanced by the minimal amount of mobilization required to enter the lesser sac by the transgastric method [35].

When performed laparoscopically, five ports are typically placed; in addition to an umbilical port, two ports are placed in the right upper quadrant, one port is placed in the left upper quadrant, and one port in the epigastrium. After entering the abdomen and creating the anterior gastrotomy, an ultrasound is used to identify the necrosis and plan the locations of the posterior gastrotomy. Ultrasound is adjunctive to preoperative imaging, which is also essential to surgical planning.

Both anterior and posterior gastrotomies should be made after placement of stay sutures. Upon entering the lesser sac, necrosectomy should be performed with blunt instruments, such as a ring forceps, taking great care to remove only loose material and avoid avulsing adherent tissue or vessels that may be bridging the area of necrosis. Following necrosectomy, a cystogastrostomy is created with an endoscopic stapler, or suture. The anterior gastrotomy is then closed with sutures or with a stapler [36].

When performed open, an upper midline incision is made, and the procedure proceeds in the same fashion as in the laparoscopic procedure. One difference in the open procedure is that many surgeons elect to use digital dissection for the necrosectomy, as opposed to instruments [37].

Open and laparoscopic approaches to transgastric drainage have been shown to have similar outcomes. In a recent retrospective review of patients from three tertiary referral centers, rates of morbidity, including rates of reoperation and hemorrhage, and mortality were not significantly different. However, the patients who underwent laparoscopic drainage had a higher rate of readmission. It should be noted that the overall mortality in this study was 2% at an average follow-up of 21 months, significantly less than reported elsewhere in the literature. The overall morbidity rate of 38% is in alignment with commonly reported rates elsewhere in literature [38].

Although surgical transgastric necrosectomy is relatively well tolerated, outcomes favor endoscopic transgastric drainage. Meta-analysis comparing the two show lower rates of overall major complications, pancreatic fistula formation, post-procedural organ failure, and hernia with an endoscopic approach. However, the overall rate of clinical resolution, post-operative bleeding, endocrine dysfunction, exocrine insufficiency, and mortality were not significantly different [39]. Thus, surgical transgastric necrosectomy is a valid alternative to other approaches of necrosectomy in the absence of an experienced endoscopist or at a center without access to advanced endoscopic tools.

7. Laparoscopic and open necrosectomy

Although utilization of a drainage tract and the transgastric approach are important for management of pancreatic necrosis, traditional laparoscopic and open necrosectomy methods also continue to be utilized.

For laparoscopic necrosectomy, patients are typically placed in lithotomy position, with the operating surgeon standing between the legs. An umbilical port is placed first. Upon entering the abdomen, a diagnostic laparoscopy should be performed. Subsequently, two left lateral ports and an epigastric port are placed. In some cases, a hand-assist port is placed to augment dissection and removal of tissue. Following lysis of adhesions, a transgastrocolic, for pancreatic head or body necrosis, or transmesocolic, for pancreatic tail necrosis, approach to retrogastric necrosectomy can be taken (**Figure 2**). Upon entering the area of necrosis, blunt instruments are used to remove loose, necrotic tissue. This tissue is then placed into an endocatch bag for removal from the abdomen. Dissection is alternated with irrigation and suction to remove as much necrotic tissue as possible [40]. Once the necrosectomy is complete, large drainage catheters are placed in the cavity, which also allow for post-operative irrigation. At this time, consideration should also be given to cholecystectomy, if gallstones were implicated in the development of pancreatitis, and to nutritional access. Depending on the specific study, mortality for patients who require laparoscopic necrosectomy ranges from 10 to 18%. Rates of reoperation also vary widely, ranging from 11 to 38% [41, 42].

The most invasive procedure used for the treatment of pancreatic necrosis is the open debridement. This technique is reserved for patients that fail other less invasive techniques, or patients who require concurrent intervention for another intraabdominal process, such as bowel ischemia or abdominal compartment syndrome. Unless midline laparotomy is required for another indication, the abdomen can be opened with bilateral, subcostal incisions. The gastrocolic ligament is then opened, and the stomach is reflected superiorly, exposing the lesser sac (**Figure 2**). The transverse mesocolon is then opened, exposing the retroperitoneum. The hepatic and splenic flexures of the transverse colon are often taken down at this point. A Kocher maneuver may also be necessary if the area of necrosis involves the head of the pancreas. Once the pancreas is adequately exposed, blunt debridement can begin. This is usually accomplished with digital dissection or with lavage in order to minimize the risk of bleeding or bile duct injury. These risks must be balanced with adequate removal of loose, nonviable tissue. Wide drainage of the area with a sumping tube (i.e. Abramson drain) can facilitate continue lavage and debridement. The quality of the initial necrosectomy predicts the need for subsequent operations.

After necrosectomy, the abdomen may be kept open, with packing in place, to allow for repeated removal of necrotic tissue. Alternatively, the closed packing technique can also be used. This technique consists of filling the cavity created by the necrosectomy with gauze-filled Penrose drains. The drains are removed one at a time, until the cavity closes [43]. A third option is continuous irrigation, where large catheters are placed into the lesser sac under direct visualization. Additional drainage catheters are left in the peritoneal cavity. The abdomen is then closed and the large catheters are used for continuous installation of hypertonic fluid [44].

As in patients who undergo laparoscopic necrosectomy, the rates of morbidity and mortality following open necrosectomy are high. Rates of post-operative morbidity range from 34 to 95% and mortality ranges from 6 to 47%, depending on the pre-operative severity of illness. Rates of reoperation vary depending on the packing technique. When the abdomen is left open, reoperation is planned rather than required because of deterioration or other complications, such as hemorrhage. Depending on the study, when the abdomen is left open, patients may return to the operating room from 1 to 17 times. Comparatively, relaparotomy is required in 17% of patients treated with closed packing and 17–27% of patients treated with continuous irrigation. Rates of pancreatic fistula also differ depending on packing technique with a 25–46% rate in open abdomens, 53% rate in closed packing, and 13–19% rate with continuous irrigation [45].

The outcomes for both of these techniques are improved when intervention can be delayed at least 3 weeks. Delayed necrosectomy is associated with lower rates of exocrine and endocrine insufficiency, adverse post-operative events, including bleeding, and mortality [17, 46]. Early surgical intervention only provides a survival benefit in the case of decompression of abdominal compartment syndrome [47, 48].

When compared directly, in a retrospective case series, the rates of pancreatic fistula, post-operative pulmonary infections, and surgical site infections were all significantly lower with laparoscopic necrosectomy. Additionally, patients who underwent laparoscopic necrosectomy also had a shorter length of stay, but a longer initial operation. There was no difference in need for reoperation, overall morbidity, or mortality. It should be noted that mortality was very low compared to other literature in this study, 5.9% in the open group and 4% in the laparoscopic group [49].

8. Disconnected pancreatic duct syndrome

While parenchymal destruction in pancreatic necrosis confers significant morbidity and mortality, the seriousness of this condition can be further compounded by concurrent disruption of the pancreatic duct. Disconnected pancreatic duct syndrome (DPDS) occurs when the remnant of pancreas distal to the necrosis, and duct disruption, remains viable and continues to release digestive enzymes into the retroperitoneum. DPDS most commonly occurs in the setting of severe acute pancreatitis, and can be found in up to 46% of patients with pancreatic necrosis [50]. DPDS can also occur as the result of trauma and chronic pancreatitis. The clinical presentation of DPDS is heterogenous. Some patients are asymptomatic and the injury is incidentally diagnosed on radiology. While others may have early satiety due to the size of the resulting fluid collection or symptomatic ascites [51, 52].

DPDS is an often overlooked complication due to the low accuracy of imaging in differentiating between full-thickness pancreatic necrosis, affecting the pancreatic duct, and partial thickness or peripancreatic necrosis. Often multiple imaging modalities are required for accurate diagnosis, which in turn leads to delays in diagnosis, increased morbidity, and increased costs [53–55]. Diagnostic criteria for DPDS include: necrosis of ≥ 2 cm of pancreatic parenchyma, viable pancreatic tissue distal to the area of necrosis, and extravasation of contrast when injected into the main pancreatic duct during ERCP [56].

Once DPDS is diagnosed, choice of intervention is dependent on the patient's clinical condition and the phase of disease. As in pancreatic necrosis without DPDS, intervention during the acute phase, when inflammation is high, is not only challenging, but also hazardous. Although the historical standard of care for these patients was surgery, if a patient deteriorates during the acute phase, initial therapy should be percutaneous or endoscopic. Percutaneous drainage, although useful as a temporizing measure, especially in unstable patients, is unlikely to succeed as monotherapy [57, 58]. Although success rates are dependent on the extent of necrosis, transpapillary and transmural endoscopic interventions have better short-term outcomes, with up to an 87% success rate of fistula resolution [50, 59, 60]. However, in order for endoscopic treatment to be successful, multiple interventions are often required, including hybrid approaches with percutaneous drains. Further, long-term data regarding patency and migration of indwelling stents is not available [60, 61]. Thus, percutaneous and endoscopic treatments remain temporizing measures, rather than definitive treatment, for DPDS, except for in patients who are poor surgical candidates [62].

Once a patient reaches the late stage of disease, or if a patient deteriorates despite optimal percutaneous and endoscopic intervention during the acute phase, surgery becomes the primary treatment for DPDS. Because of the technical difficulty of operating in the retroperitoneum after tissue planes have been obscured by inflammation, and because of the frequency of splenic vein thrombosis, and resulting sinistral portal hypertension, this operation is usually performed with a midline laparotomy and not laparoscopically [63].

Surgery for DPDS consists of resection of the distal, disconnected pancreas, and creation of internal drainage tracts. These techniques may be used independently or in combination. When the entirety of the disconnected pancreas is resected, splenectomy is also performed in almost all cases. However, when a pancreatojejunostomy, pancreaticogastrostomy, or fistuloenterostomy is made with the viable distal pancreas, the spleen may be preserved, in addition to preserving the pancreatic remnant. In this way, internal drainage not only provide a conduit for pancreatic secretions, but also decreases the risk of exocrine pancreatic insufficiency and

diabetes. Importantly, patients who undergo internal drainage, compared to other surgical modalities, also have lower incidence of organ failure, development of pancreatic fistula, and need for long-term percutaneous drainage [50, 64].

9. Conclusions

Pancreatic necrosis is a significant and challenging disease process with mortality reaching beyond 30% in most studies. Intervention begins with supportive care and nutritional support. However, invasive therapy is often needed, especially when necrosis becomes infected.

First-line interventions for pancreatic necrosis may be percutaneous or transmural endoscopic drainage depending on if the necrosis is encapsulated, the accessibility of the necrosis, the patient's clinical condition, and the capabilities of the hospital. These minimally-invasive interventions are often successful as monotherapy, without the need for further intervention. They are also preferable to open or laparoscopic necrosectomy when performed as part of a step-up approach.

Despite all of the improvement in minimally-invasive management of pancreatic necrosis, some percentage of patients continue to require surgical intervention. Both laparoscopic and open approaches have been shown to be effective via transgastric, transgastrocolic, and transmesocolic routes.

When pancreatic necrosis is further complicated by a disconnected pancreatic duct, although minimally-invasive management has been described and shown to be effective, surgical management remains standard of care.

Despite the advances in care driven by clinical trials and new technology, management of pancreatic necrosis remains difficult. Further study is needed to reduce the morbidity and mortality of this devastating disease.

Acknowledgements

All authors contributed equally to the authorship of this chapter.

Conflict of interest

The authors declare no conflicts of interest.

Notes/thanks/other declarations

The authors would like to thank the leadership of the Department of Surgery at the Donald and Barbara School of Medicine at Hofstra/Northwell, including Drs. Vihās Patel and Gene Coppa, for sponsoring the writing of this chapter.

Appendices and nomenclature

ACN	acute necrotic collection
CT	computed tomography
DEN	direct endoscopic necrosectomy
DPDS	disconnected pancreatic duct syndrome
ERCP	endoscopic retrograde cholangiopancreatography

EUS	endoscopic ultrasound
FNA	fine needle aspiration
HU	Hounsfield units
PEN	percutaneous endoscopic necrosectomy
SEMS	self-expanding metal stent
TPN	total parenteral nutrition
WON	walled of necrosis
VARD	video-assisted retroperitoneal debridement

Author details

Dane Thompson^{1,2,3,4}, Siavash Bolourani^{1,2,3,4} and Matthew Giangola^{4*}

1 The Feinstein Institutes for Medical Research, Manhasset, New York, United States


2 Elmezzi Graduate School of Molecular Medicine, Manhasset, New York, United States

3 Donald and Barbara Zucker School of Medicine at Hofstra/Northwell, Manhasset, New York, United States

4 Department of Surgery, Donald and Barbara Zucker School of Medicine at Hofstra Northwell School of Medicine, Manhasset, New York, United States

*Address all correspondence to: mgiangola@northwell.edu

IntechOpen

© 2021 The Author(s). Licensee IntechOpen. This chapter is distributed under the terms of the Creative Commons Attribution License (<http://creativecommons.org/licenses/by/3.0>), which permits unrestricted use, distribution, and reproduction in any medium, provided the original work is properly cited. 

References

- [1] Banks PA, Bollen TL, Dervenis C, Gooszen HG, Johnson CD, Sarr MG, et al. Classification of acute pancreatitis—2012: revision of the Atlanta classification and definitions by international consensus. *Gut* 2013;62:102-111. <https://doi.org/10.1136/gutjnl-2012-302779>.
- [2] Kokosis G, Perez A, Pappas TN. Surgical management of necrotizing pancreatitis: an overview. *World J Gastroenterol* 2014;20:16106-12. <https://doi.org/10.3748/wjg.v20.i43.16106>.
- [3] Türkvatan A, Erden A, Türkoğlu MA, Seçil M, Yener Ö. Imaging of acute pancreatitis and its complications. Part 1: Acute pancreatitis. *Diagn Interv Imaging* 2015;96:151-60. <https://doi.org/10.1016/j.diii.2013.12.017>.
- [4] Koo BC, Chinogureyi A, Shaw AS. Imaging acute pancreatitis. *Br J Radiol* 2010;83:104-12. <https://doi.org/10.1259/bjr/13359269>.
- [5] Petrov MS, Kukosh MV, Emelyanov NV. A randomized controlled trial of enteral versus parenteral feeding in patients with predicted severe acute pancreatitis shows a significant reduction in mortality and in infected pancreatic complications with total enteral nutrition. *Dig Surg* 2006;23:336-44; discussion 344-345. <https://doi.org/10.1159/000097949>.
- [6] Wu X-M, Ji K-Q, Wang H-Y, Li G-F, Zang B, Chen W-M. Total enteral nutrition in prevention of pancreatic necrotic infection in severe acute pancreatitis. *Pancreas* 2010;39:248-51. <https://doi.org/10.1097/MPA.0b013e3181bd6370>.
- [7] Wu X-M, Liao Y-W, Wang H-Y, Ji K-Q, Li G-F, Zang B. When to initialize enteral nutrition in patients with severe acute pancreatitis? A retrospective review in a single institution experience (2003-2013). *Pancreas* 2015;44:507-11. <https://doi.org/10.1097/MPA.0000000000000293>.
- [8] Leppäniemi A, Tolonen M, Tarasconi A, Segovia-Lohse H, Gamberini E, Kirkpatrick AW, et al. 2019 WSES guidelines for the management of severe acute pancreatitis. *World J Emerg Surg* 2019;14:27. <https://doi.org/10.1186/s13017-019-0247-0>.
- [9] Jj H, N S, A S, As R, Ss I, Si G, et al. Outcomes of Infected versus Symptomatic Sterile Walled-Off Pancreatic Necrosis Treated with a Minimally Invasive Therapy. *Gut Liver* 2019;13. <https://doi.org/10.5009/gnl18234>.
- [10] Beger HG, Rau BM. Severe acute pancreatitis: Clinical course and management. *World J Gastroenterol WJG* 2007;13:5043. <https://doi.org/10.3748/wjg.v13.i38.5043>.
- [11] Schepers NJ, Bakker OJ, Besselink MG, Ali UA, Bollen TL, Gooszen HG, et al. Impact of characteristics of organ failure and infected necrosis on mortality in necrotising pancreatitis. *Gut* 2019;68:1044-51. <https://doi.org/10.1136/gutjnl-2017-314657>.
- [12] Choe KA. Imaging in pancreatic infection. *J Hepatobiliary Pancreat Surg* 2003;10:401-5. <https://doi.org/10.1007/s00534-002-0713-y>.
- [13] Baron TH, DiMaio CJ, Wang AY, Morgan KA. American Gastroenterological Association Clinical Practice Update: Management of Pancreatic Necrosis. *Gastroenterology* 2020;158:67-75.e1. <https://doi.org/10.1053/j.gastro.2019.07.064>.

- [14] Isenmann R, Rünzi M, Kron M, Kahl S, Kraus D, Jung N, et al. Prophylactic antibiotic treatment in patients with predicted severe acute pancreatitis: a placebo-controlled, double-blind trial. *Gastroenterology* 2004;126:997-1004. <https://doi.org/10.1053/j.gastro.2003.12.050>.
- [15] Dellinger EP, Tellado JM, Soto NE, Ashley SW, Barie PS, Dugernier T, et al. Early antibiotic treatment for severe acute necrotizing pancreatitis: a randomized, double-blind, placebo-controlled study. *Ann Surg* 2007;245:674-83. <https://doi.org/10.1097/01.sla.0000250414.09255.84>.
- [16] García-Barrasa A, Borobia FG, Pallares R, Jorba R, Poves I, Busquets J, et al. A double-blind, placebo-controlled trial of ciprofloxacin prophylaxis in patients with acute necrotizing pancreatitis. *J Gastrointest Surg Off J Soc Surg Aliment Tract* 2009;13:768-74. <https://doi.org/10.1007/s11605-008-0773-7>.
- [17] Bugiantella W, Rondelli F, Boni M, Stella P, Polistena A, Sanguinetti A, et al. Necrotizing pancreatitis: A review of the interventions. *Int J Surg* 2016;28:S163-71. <https://doi.org/10.1016/j.ijso.2015.12.038>.
- [18] van Brunschot S, Fockens P, Bakker OJ, Besselink MG, Voermans RP, Poley J-W, et al. Endoscopic transluminal necrosectomy in necrotising pancreatitis: a systematic review. *Surg Endosc* 2014;28:1425-38. <https://doi.org/10.1007/s00464-013-3382-9>.
- [19] van Baal MC, van Santvoort HC, Bollen TL, Bakker OJ, Besselink MG, Gooszen HG, et al. Systematic review of percutaneous catheter drainage as primary treatment for necrotizing pancreatitis. *Br J Surg* 2011;98:18-27. <https://doi.org/10.1002/bjs.7304>.
- [20] Patel R, Gardner TB. Early versus late necrotic pancreatic fluid collection drainage: Does timing make a difference? *Gastrointest Endosc* 2020;91:1310-1. <https://doi.org/10.1016/j.gie.2020.02.023>.
- [21] Kumar N, Conwell DL, Thompson CC. Direct Endoscopic Necrosectomy Versus Step-Up Approach for Walled-Off Pancreatic Necrosis: Comparison of Clinical Outcome and Health Care Utilization. *Pancreas* 2014;43:1334-1339. <https://doi.org/10.1097/MPA.0000000000000213>.
- [22] Jha AK, Goenka MK, Kumar R, Suchismita A. Endotherapy for pancreatic necrosis: An update. *JGH Open* 2019;3:80-8. <https://doi.org/10.1002/jgh3.12109>.
- [23] Bakker OJ, van Santvoort HC, van Brunschot S, Geskus RB, Besselink MG, Bollen TL, et al. Endoscopic Transgastric vs Surgical Necrosectomy for Infected Necrotizing Pancreatitis: A Randomized Trial. *JAMA* 2012;307:1053. <https://doi.org/10.1001/jama.2012.276>.
- [24] Hines OJ, Donald GW. Endoscopic Transgastric Necrosectomy for Infected Necrotizing Pancreatitis. *JAMA J Am Med Assoc* 2012;307:1084-5. <https://doi.org/10.1001/jama.2012.306>.
- [25] Bang JY, Arnoletti JP, Holt BA, Sutton B, Hasan MK, Navaneethan U, et al. An Endoscopic Transluminal Approach, Compared With Minimally Invasive Surgery, Reduces Complications and Costs for Patients With Necrotizing Pancreatitis. *Gastroenterology* 2019;156:1027-1040.e3. <https://doi.org/10.1053/j.gastro.2018.11.031>.
- [26] van Brunschot S, van Grinsven J, van Santvoort HC, Bakker OJ, Besselink MG, Boermeester MA, et al. Endoscopic or surgical step-up approach for infected necrotising pancreatitis: a multicentre

randomised trial. *The Lancet* 2018;391:51-8. [https://doi.org/10.1016/S0140-6736\(17\)32404-2](https://doi.org/10.1016/S0140-6736(17)32404-2).

[27] Sharma P. CT Guided Percutaneous Drainage in Necrotizing Pancreatitis – Highly Successful In Appropriately Selected Patients - Single Center Experience 2019:6.

[28] Tyberg A, Karia K, Gabr M, Desai A, Doshi R, Gaidhane M, et al. Management of pancreatic fluid collections: A comprehensive review of the literature. *World J Gastroenterol* 2016;22:2256-70. <https://doi.org/10.3748/wjg.v22.i7.2256>.

[29] Wroński M, Cebulski W, Karkocha D, Słodkowski M, Wysocki Ł, Jankowski M, et al. Ultrasound-guided percutaneous drainage of infected pancreatic necrosis. *Surg Endosc* 2013;27:2841-8. <https://doi.org/10.1007/s00464-013-2831-9>.

[30] van Santvoort HC, Besselink MG, Bakker OJ, Hofker HS, Boermeester MA, Dejong CH, et al. A Step-up Approach or Open Necrosectomy for Necrotizing Pancreatitis. *N Engl J Med* 2010;362:1491-502. <https://doi.org/10.1056/NEJMoa0908821>.

[31] van Santvoort HC, Besselink MGH, Horvath KD, Sinanan MN, Bollen TL, van Ramshorst B, et al. Videoscopic assisted retroperitoneal debridement in infected necrotizing pancreatitis. *HPB* 2007;9:156-9. <https://doi.org/10.1080/13651820701225688>.

[32] Jain S, Padhan R, Bopanna S, Jain SK, Dhingra R, Dash NR, et al. Percutaneous Endoscopic Step-Up Therapy Is an Effective Minimally Invasive Approach for Infected Necrotizing Pancreatitis. *Dig Dis Sci* 2020;65:615-22. <https://doi.org/10.1007/s10620-019-05696-2>.

[33] Trikudanathan G. Percutaneous Endoscopic Necrosectomy (PEN):

Is the PEN Mightier Than the VARD? *Dig Dis Sci* 2020;65:339-41. <https://doi.org/10.1007/s10620-019-05790-5>.

[34] Hollemans RA, Bakker OJ, Boermeester MA, Bollen TL, Bosscha K, Bruno MJ, et al. Superiority of Step-up Approach vs Open Necrosectomy in Long-term Follow-up of Patients With Necrotizing Pancreatitis. *Gastroenterology* 2019;156:1016-26. <https://doi.org/10.1053/j.gastro.2018.10.045>.

[35] Zyromski NJ, Nakeeb A, House MG, Jester AL. Transgastric Pancreatic Necrosectomy: How I Do It. *J Gastrointest Surg Off J Soc Surg Aliment Tract* 2016;20:445-9. <https://doi.org/10.1007/s11605-015-3058-y>.

[36] Kulkarni S, Bogart A, Buxbaum J, Matsuoka L, Selby R, Parekh D. Surgical transgastric debridement of walled off pancreatic necrosis: an option for patients with necrotizing pancreatitis. *Surg Endosc* 2015;29:575-82. <https://doi.org/10.1007/s00464-014-3700-x>.

[37] Sasnur P, Nidoni R, Baloorkar R, Sindgikar V, Shankar B. Extended Open Transgastric Necrosectomy (EOTN) as a Safer Procedure for Necrotizing Pancreatitis. *J Clin Diagn Res JCDR* 2014;8:NR01-02. <https://doi.org/10.7860/JCDR/2013/8196.4600>.

[38] Driedger M, Zyromski NJ, Visser BC, Jester A, Sutherland FR, Nakeeb A, et al. Surgical Transgastric Necrosectomy for Necrotizing Pancreatitis: A Single-stage Procedure for Walled-off Pancreatic Necrosis. *Ann Surg* 2020;271:163-8. <https://doi.org/10.1097/SLA.0000000000003048>.

[39] Luo D, Liu X, Du J, Liu J, Chen X, Zhou P, et al. Endoscopic Transgastric Versus Surgical Approach for Infected Necrotizing Pancreatitis: A Systematic Review and Meta-Analysis. *Surg Laparosc Endosc Percutan Tech*

2019;29:141-9. <https://doi.org/10.1097/SLE.0000000000000632>.

[40] Mathew MJ, Parmar AK, Sahu D, Reddy PK. Laparoscopic necrosectomy in acute necrotizing pancreatitis: Our experience. *J Minimal Access Surg* 2014;10:126-31. <https://doi.org/10.4103/0972-9941.134875>.

[41] Parekh D. Laparoscopic-assisted pancreatic necrosectomy: A new surgical option for treatment of severe necrotizing pancreatitis. *Arch Surg Chic Ill* 1960 2006;141:895-902; discussion 902-903. <https://doi.org/10.1001/archsurg.141.9.895>.

[42] Gagner null. Laparoscopic Treatment of Acute Necrotizing Pancreatitis. *Semin Laparosc Surg* 1996;3:21-8. <https://doi.org/10.1053/SLAS00300021>.

[43] Rodriguez JR, Razo AO, Targarona J, Thayer SP, Rattner DW, Warshaw AL, et al. Debridement and Closed Packing for Sterile or Infected Necrotizing Pancreatitis. *Ann Surg* 2008;247:294-9. <https://doi.org/10.1097/SLA.0b013e31815b6976>.

[44] Rau B, Bothe A, Beger HG. Surgical treatment of necrotizing pancreatitis by necrosectomy and closed lavage: changing patient characteristics and outcome in a 19-year, single-center series. *Surgery* 2005;138:28-39. <https://doi.org/10.1016/j.surg.2005.03.010>.

[45] Werner J, Feuerbach S, Uhl W, Büchler MW. Management of acute pancreatitis: from surgery to interventional intensive care. *Gut* 2005;54:426-36. <https://doi.org/10.1136/gut.2003.035907>.

[46] Mier J, León EL, Castillo A, Robledo F, Blanco R. Early versus late necrosectomy in severe necrotizing pancreatitis. *Am J Surg* 1997;173:71-5. [https://doi.org/10.1016/S0002-9610\(96\)00425-4](https://doi.org/10.1016/S0002-9610(96)00425-4).

[47] Freeman ML, Werner J, Santvoort HCV, Baron TH, Besselink MG, Windsor JA, et al. Interventions for necrotizing pancreatitis: Summary of a multidisciplinary consensus conference. *Pancreas* 2012;41:1176-94. <https://doi.org/10.1097/MPA.0b013e318269c660>.

[48] Mentula P, Hienonen P, Kemppainen E, Puolakkainen P, Leppäniemi A. Surgical Decompression for Abdominal Compartment Syndrome in Severe Acute Pancreatitis. *Arch Surg* 2010;145:764-9. <https://doi.org/10.1001/archsurg.2010.132>.

[49] Tan J, Tan H, Hu B, Ke C, Ding X, Chen F, et al. Short-Term Outcomes from a Multicenter Retrospective Study in China Comparing Laparoscopic and Open Surgery for the Treatment of Infected Pancreatic Necrosis. *J Laparoendosc Adv Surg Tech* 2012;22:27-33. <https://doi.org/10.1089/lap.2011.0248>.

[50] Maatman TK, Roch AM, Lewellen KA, Heimberger MA, Ceppa EP, House MG, et al. Disconnected Pancreatic Duct Syndrome: Spectrum of Operative Management. *J Surg Res* 2020;247:297-303. <https://doi.org/10.1016/j.jss.2019.09.068>.

[51] Fischer TD, Gutman DS, Hughes SJ, Trevino JG, Behrns KE. Disconnected pancreatic duct syndrome: disease classification and management strategies. *J Am Coll Surg* 2014;219:704-12. <https://doi.org/10.1016/j.jamcollsurg.2014.03.055>.

[52] Rana SS, Sharma RK, Gupta R. Endoscopic management of pancreatic ascites due to duct disruption following acute necrotizing pancreatitis. *JGH Open Access J Gastroenterol Hepatol* 2019;3:111-6. <https://doi.org/10.1002/jgh3.12113>.

[53] Timmerhuis HC, van Dijk SM, Verdonk RC, Bollen TL, Bruno MJ,

Fockens P, et al. Various Modalities Accurate in Diagnosing a Disrupted or Disconnected Pancreatic Duct in Acute Pancreatitis: A Systematic Review. *Dig Dis Sci* 2020. <https://doi.org/10.1007/s10620-020-06413-0>.

[54] Chen Y, Jiang Y, Qian W, Yu Q, Dong Y, Zhu H, et al. Endoscopic transpapillary drainage in disconnected pancreatic duct syndrome after acute pancreatitis and trauma: long-term outcomes in 31 patients. *BMC Gastroenterol* 2019;19:54. <https://doi.org/10.1186/s12876-019-0977-1>.

[55] Verma S, Rana SS. Disconnected pancreatic duct syndrome: Updated review on clinical implications and management. *Pancreatol Off J Int Assoc Pancreatol IAP AI* 2020;20:1035-44. <https://doi.org/10.1016/j.pan.2020.07.402>.

[56] Sandrasegaran K, Tann M, Jennings SG, Maglinte DD, Peter SD, Sherman S, et al. Disconnection of the pancreatic duct: an important but overlooked complication of severe acute pancreatitis. *Radiogr Rev Publ Radiol Soc N Am Inc* 2007;27:1389-400. <https://doi.org/10.1148/rg.275065163>.

[57] Nealon WH, Bhutani M, Riall TS, Raju G, Ozkan O, Neilan R. A unifying concept: pancreatic ductal anatomy both predicts and determines the major complications resulting from pancreatitis. *J Am Coll Surg* 2009;208:790-9; discussion 799-801. <https://doi.org/10.1016/j.jamcollsurg.2008.12.027>.

[58] Larsen M, Kozarek RA. Management of Disconnected Pancreatic Duct Syndrome. *Curr Treat Options Gastroenterol* 2016;14:348-59. <https://doi.org/10.1007/s11938-016-0098-7>.

[59] Irani S, Gluck M, Ross A, Gan SI, Crane R, Brandabur JJ, et al. Resolving

external pancreatic fistulas in patients with disconnected pancreatic duct syndrome: using rendezvous techniques to avoid surgery (with video). *Gastrointest Endosc* 2012;76:586-593.e1-3. <https://doi.org/10.1016/j.gie.2012.05.006>.

[60] Varadarajulu S, Noone TC, Tutuian R, Hawes RH, Cotton PB. Predictors of outcome in pancreatic duct disruption managed by endoscopic transpapillary stent placement. *Gastrointest Endosc* 2005;61:568-75. [https://doi.org/10.1016/s0016-5107\(04\)02832-9](https://doi.org/10.1016/s0016-5107(04)02832-9).

[61] Bang JY, Wilcox CM, Navaneethan U, Hasan MK, Peter S, Christein J, et al. Impact of Disconnected Pancreatic Duct Syndrome on the Endoscopic Management of Pancreatic Fluid Collections. *Ann Surg* 2018;267:561-8. <https://doi.org/10.1097/SLA.0000000000002082>.

[62] Nadkarni NA, Kotwal V, Sarr MG, Swaroop Vege S. Disconnected Pancreatic Duct Syndrome: Endoscopic Stent or Surgeon's Knife? *Pancreas* 2015;44:16-22. <https://doi.org/10.1097/MPA.0000000000000216>.

[63] Howard TJ, Moore SA, Saxena R, Matthews DE, Schmidt CM, Wiebke EA. Pancreatic duct strictures are a common cause of recurrent pancreatitis after successful management of pancreatic necrosis. *Surgery* 2004;136:909-16. <https://doi.org/10.1016/j.surg.2004.06.028>.

[64] van Dijk SM, Timmerhuis HC, Verdonk RC, Reijnders E, Bruno MJ, Fockens P, et al. Treatment of disrupted and disconnected pancreatic duct in necrotizing pancreatitis: A systematic review and meta-analysis. *Pancreatol Off J Int Assoc Pancreatol IAP AI* 2019;19:905-15. <https://doi.org/10.1016/j.pan.2019.08.006>.