

Research Article

Protective Effect of *Nigella Sativa* on Taurocholate Induced Pancreatitis in Rats

Mehmet Ali Kosekli^{1,*}, Ozlem Ozmen², Sima Sahinduran³, Mustafa Yilmaz⁴

¹Department of Gastroenterology, Faculty of Medicine, Abant Izzet Baysal University, Bolu, Turkey.

²Department of Pathology, Faculty of Veterinary Medicine, Mehmet Akif Ersoy University, Burdur, Turkey.

³Department of Internal Medicine, Faculty of Veterinary Medicine, Mehmet Akif Ersoy University, Burdur, Turkey.

⁴Department of Gastroenterology, Faculty of Medicine, Pamukkale University, Denizli, Turkey.

Abstract: Introduction: Acute necrotizing pancreatitis with a high mortality rate and the search for treatment continues. We investigated the protective effect of *Nigella Sativa* (NS), with antioxidant and anti-inflammatory effects, in experimental acute necrotizing pancreatitis.

Materials and Methods: Thirty six male Wistar albino rats (weights 180-220 g) were randomised into four groups. Group 1 (Control): Rats were given standard mouse chow. No pro-drug or pancreatic intervention was performed. Group 2 (NS): In addition to their standard diet, rats were given 0.1 ml/100gr of NS orally for 3 days prior to the experiment. Group 3: Necrotizing pancreatitis was induced by retrograde administration of 3% Na-Taurocholate through the distal common bile duct of the rats on on experiment day. Group 4 (NS+ANP): Necrotizing pancreatitis was also formed in rats receiving 0.1ml/100 mg of NS for 3 days. Rats were given high-dose anesthesia 8 hours after the onset of pancreatitis. Immunohistochemical (TNF- α , MDA, MPO, Caspase), histological pancreatitis scoring and biochemical (LDH, Lipase, amylase) analyzes were performed from the blood and pancreatic tissue samples obtained.

Results: There was no difference in histopathological, immunohistochemical and biochemical values between Group 1 and Group 2 ($p>0.05$). There were significant differences between Group 4 and Group 3 in terms of histopathological, immunohistochemical and biochemical parameters ($p<0.001$). The pancreatitis findings of the Group 4 were found to be significantly milder than Group 3, which did not receive NS.

Conclusion: NS pretreatment alleviates NaTaurocholate-induced experimental pancreatitis. NS firstly studied in experimental models of pancreatitis.

Keywords: Acute pancreatitis, *Nigella Sativa*, Inflammation, Antioxidant, Rat, Immunohistochemical malondialdehyde.

INTRODUCTION

Acute pancreatitis (AP) is defined as an inflammation of various degrees which developed suddenly in pancreas. Biliary causes are the most common causes of AP in clinical practice [1]. It is thought that pancreatic auto digestion is initiated with the activation of enzymes in acinar cells as a result of obstruction of the common biliary duct with bile sludge or stone [2]. Despite most of the AP cases are mild, acute necrotizing pancreatitis (ANP) remains as an important condition with a mortality rate around 15-20% [3,4]. Parallel to the increase in obesity and the incidence of gallstones, an increase in the incidence of the disease is observed, while the mortality rate does not decrease at the same rate [5].

Antagonizing the mediators, which pass through the bloodstream and responsible from the complications, could be a therapeutic option or ameliorating the complications of AP. *Nigella Sativa* oil (NS); is an herbal extract that has anti-oxidant, anti-inflammatory, and anti-TNF effects [6-10].

There is no data about NS's effects on ANP. Therefore, we aimed to study the effects of NS as a pretreatment agent in experimental ANP model.

MATERIALS AND METHODS

The study was performed in Experimental Animal Center of Pamukkale University after approval of the study protocol by local ethics committee. International regulations on animal experiments have been followed during the study experiments. Thirty-six male Wistar albino rats (Weights 180-220 g) were randomised into four groups. Rats have been kept on single cages, moist and temperature was automatically arranged, during study in day and night cycles of 12 hours. They have been starved for 12 hours on the experiment day.

Group 1: Control Group

Rats in the group were given standard rat chow. No pro-drug or pancreatic intervention was performed.

Group 2: *Nigella Sativa* (NS) Group

In addition to their standard diet, the rats in this group were

*Address correspondence to this author at the Department of Gastroenterology, Faculty of Medicine, Abant Izzet Baysal University Hospital, Bolu, Turkey. Email: kosekli@gmail.com

given 0.1 ml/100gr NS orally for 3 days prior the experiment.

Group 3: Pancreatitis Group

Necrotizing pancreatitis (ANP) was induced by retrograde administration of 3% Na-Taurocholate through the distal common bile duct of the rats on an experiment day.

Group 4: Treatment Group (NS+ANP)

After 3 days of 1ml/kg NS administration, necrotizing pancreatitis was induced same way. Laparotomy have been performed under 80 mg/kg ketamin (Ketalar®, Eczacıbaşı, İstanbul) and 10mg/kg xylazine (Rhompun®, Bayer, İstanbul) anesthesia in sterile conditions.

ACUTE NECROTIZING PANCREATITIS PROTOCOL

After the seromuscular layer was opened 2 to 3 mm away from the duodenum-ductus choledochus junction, common bile duct cannulation was provided by entering with a 27 gauge dental needle. The distal biliopancreatic duct and hilar common bile duct were clamped to prevent the escape of taurocholate into the duodenum and liver. Sterile 3% Na-Taurocholate was slowly infused (with 25 mm water pressure) at 0.1 ml per 100 g of body weight. The needle and clamps were removed after completion of the taurocholate infusion and the abdominal wall was closed in 2 layers [11,12]. Rats were sacrificed 8 hours after pancreatitis was induced.

Pancreatic tissue was isolated. Histopathological scoring and Immunohistochemical Malondialdehyde (MDA), Caspase, Myeloperoxidase (MPO), and Tumor necrosis Factor-alpha (TNF- α) staining were performed. Lactate dehydrogenase (LDH) lipase and Amylase were studied in serum obtained from intracardiac blood samples.

HISTOPATHOLOGIC EVALUATION

All rats were killed after blood samples were taken from the intracardiac route under anesthesia. Pancreatic tissue was separated and placed in formalin containers. Histopathological changes and pancreatic injury scoring were evaluated by a veterinary pathologist unaware of the experiment. Histopathological changes in pancreatic tissue were subdivided and standardized. The severity of pancreatitis was evaluated according to the scoring system modified in our previous study in the light of the literature. Leukocyte infiltration, edema, hemorrhage, parenchyma and adipose tissue necrosis in pancreatic tissue were graded. Each parameter was scored from 0 to 3 [13, 14].

IMMUNOHISTOCHEMICAL STAINING STUDIES

Isolated pancreatic tissue were immunostained with Caspase-3 antibody [Abcam, 1/100 subtilization] MPO

[Abcam, 1/100 subtilization], MDA [Abcam, 1/100 subtilization] and TNF- α [Abcam, 1/100 subtilization]. The streptavidin-biotin peroxidase technique was applied to evaluate the apoptotic activity of TNF- α , MPO, MDA, and cells. The Novostain Universal Detection Kit (ready to use) [Abbotec, San Diego, CA,] was used as the secondary antibody. Immunoreactivity was assessed by examining 10 randomly selected microscopic fields (X40) near the necrotic areas for each slide or the pancreatic duct for controls. The proportion of Positive cells was determined by counting 100 cells.

BIOCHEMICAL ANALYSIS

The serums of the blood were isolated by centrifugation at 25°C for 10 minutes at 300 rpm. Lipase, amylase and LDH levels were studied from samples stored at -20°C using the IDEXX (Westbrooke, Maine) VetTest commercial assay.

STATISTICAL EVALUATION

Statistical analysis was performed with the SPSS 21.0 program package (SPSS Inc, Chicago, Ill). Shapiro Wilk test used in normality analysis. One-way analysis of variance (ANOVA) was used for comparisons between groups. Duncan's test was performed for significance evaluation. Results were expressed as mean \pm SD. P<0.05 values were considered statistically significant.

RESULTS

There were no histopathological abnormalities in groups 1 and 2 (Fig. 1). All results of the groups are shown in Table 1. Necrotic pancreatitis findings consistent with were detected in the pancreatic tissues of the rats in Group 3 and Group 4. In the pancreatic tissue of the rats in Group 3 and Group 4, leukocyte infiltration, edema, bleeding, acinar and fat necrosis, which represent severe necrotic pancreatitis, were detected (Table 1, Fig. 2). Histopathological pancreatitis scores were found to be significantly lower in rats receiving NS pretreatment (Group 4) compared to rats receiving standard nutrition (Group 3) (Fig. 3).

TNF- α , MDA, Caspase-3, MPO, lipase, Amylase and LDH levels were similar among rats not having pancreatitis nutrished by NS or not (Groups 1 and 2) (Table 1), but they were significantly increased in experimental pancreatitis rats (Groups 3 and 4), (Fig. 4). However, these paramaters were significantly lower in rats with experimental pancreatitis pretreated with NS (Group 4) than rats with pancreatitis not ingesting NS (Group 3) (Table 1).

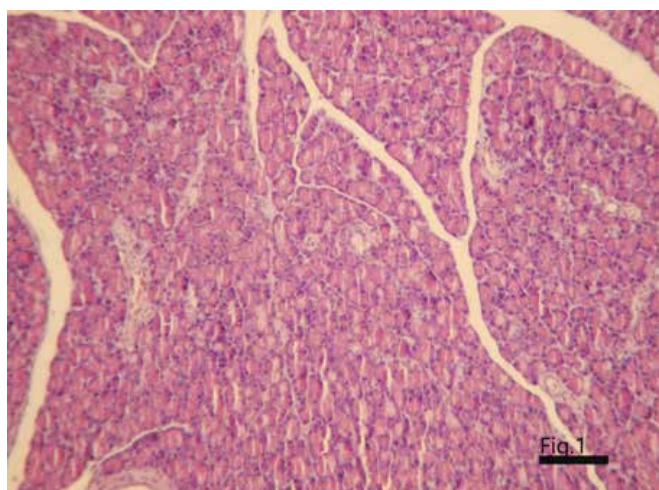


Fig. (1). Normal Histology of Pancreas from a Rat in Control Group, HE, X200.

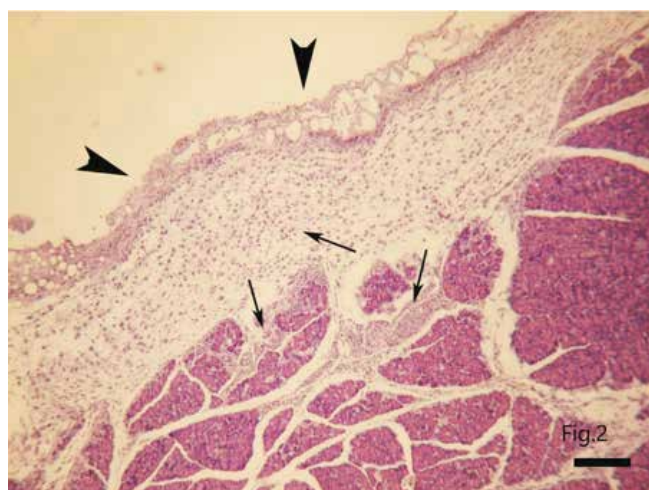


Fig. (2). Acute Necrotic Pancreatitis, Severe Necrosis (arrow heads) and Numerous Neutrophil Leukocytes (arrows) in the Pancreas in a Rat from SAP Group, HE, X400.

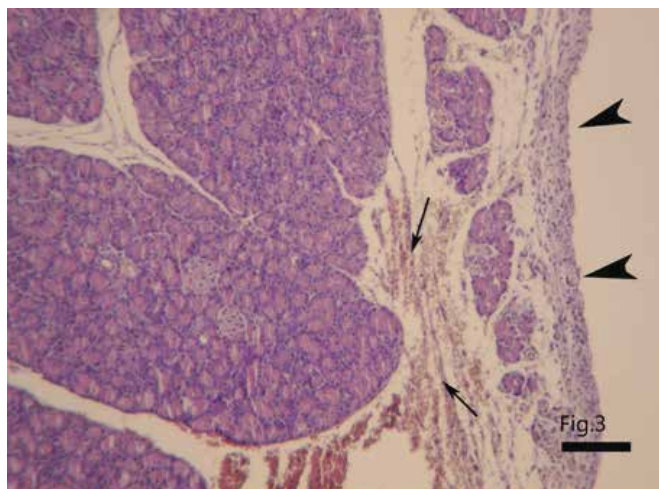


Fig. (3). Slight Necrosis (arrow heads) and Hemorrhage in a Rat from NS+ANP Group, Ameliorative Effect of NS can be seen, HE, X200.

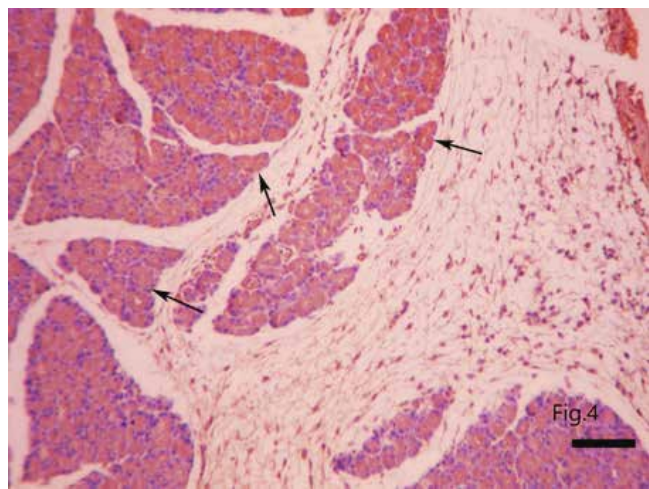


Fig. (4). Marked Caspase-3 Immunoreaction in Acinar Cells (arrows) of Pancreas in a Rat from ANP Group, Streptavidine-Biotin Peroxidase Technique with Hematoxylin Counterstain, X200.

Table 1. Biochemical, Immunohistochemical and Histopathologic results of the groups.

Groups	Group 1 Control (n=9)	Group 2 NS (n=9)	Group 3 ANP (n=9)	Group 4 NS+ANP (n=9)	P value
Amylase(U/L)	1044.75±52.45 ^a	1006.00±48.79 ^a	2807.28±147.17 ^b	1896.66±266.10 ^c	<0.001 ^{***}
Lipase(U/L)	41.00±8.05 ^a	41.77±7.77 ^a	342.42±47.69 ^b	277.55±74.40 ^b	<0.001 ^{***}
LDH(U/L)	746.33±38.27 ^a	776.33±68.11 ^a	3915.28±183.37 ^b	1863.33±174±71 ^c	<0.001 ^{***}
TNF-α	0.37±0.74 ^a	0.44±0.52 ^a	2.42±0.78 ^b	1.00±0.70 ^a	<0.05 [*]
MDA	0.37±0.26 ^a	0.11±0.11 ^a	2.00±0.30 ^b	1.22±0.32 ^c	<0.001 ^{***}
Caspase-3	0.62±0.32 ^a	0.55±0.29 ^a	2.00±0.30 ^b	1.11±0.26 ^a	<0.01 ^{**}
MPO	0.37±0.18 ^a	0.33±0.16 ^a	1.42±0.20 ^b	1.11±0.20 ^b	<0.001 ^{***}
Edema	0.00±0.00 ^a	0.00±0.00 ^a	1.85±0.40 ^b	1.00±0.23 ^c	<0.001 ^{***}
Hemorrhage	0.00±0.00 ^a	0.00±0.00 ^a	1.71±0.18 ^b	0.88±0.26 ^c	<0.001 ^{***}
Leukocyte Infiltration	0.00±0.00 ^a	0.00±0.00 ^a	1.57±0.36 ^b	0.77±0.22 ^c	<0.001 ^{***}
Fat Necrosis	0.00±0.00 ^a	0.00±0.00 ^a	1.28±0.42 ^b	0.88±0.26 ^b	<0.01 ^{**}
Paranchymal Necrosis	0.00±0.00 ^a	0.00±0.00 ^a	1.71±0.35 ^b	0.66±0.23 ^c	<0.001 ^{***}

NS: *Nigella Sativa* Oil, ANP: Acute Necrotizing Pancreatitis. ^{a,b,c}: Mean values marked with different superscripts in the same line are significantly different from each other (P<0.05, P<0.01 and P<0.001). *Moderate significant. **Significant. ***Highly significant.

DISCUSSION

The main finding of present study was pretreatment NS could ameliorate Acute Necrotizing Pancreatitis (ANP). This conclusion was confirmed by histopathological, immuno-histochemical and biochemical findings.

Obstruction of common duct by biliary stone or sludge which cause pancreatic stasis and biliary reflux to the pancreatic canal is the most popular theory in biliary pancreatitis [15]. The experimental AP in rats which induced by Na Taurocholate via choledoc retrograde way, is the most likely severe AP that seen in clinical practice [16]. Treatment of AP depends only fluid resuscitation and supportive care in daily practice. Therefore area of research about treatment of AP is still unsatisfactory.

Nigella Sativa is a plant extract whose antioxidant, anti-inflammatory and antimicrobial effects have been shown to have therapeutic properties in different diseases [17-19]. Neutrophil chemotaxis into pancreatic tissues is triggered by activation of the inflammatory cascade [20]. Neutrophil extracellular traps (NET) has been shown to have important role in tissue damage and trypsinogen activation [21,22]. Authors suggested that pancreatic damage could be ameliorated by reduction of the NET formation [23]. In present study, intensive neutrophil infiltration and increased MPO activity were noted in severe AP group. NS pretreatment yielded reduction in MPO activity and ameliorated tissue damage via neutrophil stabilization. Acinar destruction was prominent in SAP group in histopathological examination while the damage was limited in NS group.

Nigella Sativa has some effects on lymphocytes and the phagocytic activity of leukocytes [24,25]. A similar study showed regulatory effects of Slymarin pretreatment in AP by stabilization of the neutrophils [26]. Similarly, neutrophil recruitment was decreased and acinar cell damage was minimized with NS pretreatment in our study. Thus, it reduced the pancreatic destruction induced by taurocholate.

Nuclear Factor-Kappa Beta (NF- κ B) stimulation, triggered by the inflammatory cascade leads to an increase in TNF- α levels. This contributes to the development of local and systemic complications of pancreatic inflammation [27]. Neutrophils are activated, free oxygen radicals are released, and lipid peroxidation, cell edema and death occur with the effect of TNF alpha [28]. Therefore, it is not surprising that TNF- α blockade reduces inflammation and limits pancreatic damage. Many studies have shown that pancreatic damage is alleviated by TNF blockade [14, 29]. While TNF- α levels were significantly higher in the SAP group, pancreatic TNF levels were significantly decreased with NS pretreatment in present study. NS pretreatment limited the pancreatic inflam-

mation by decreasing the tissue TNF- α level.

Damage to the pancreatic parenchyma for various reasons, especially bile acid reflux, leads to acinar cell death via apoptosis or necrosis. Free oxygen radicals (ROS) and endoplasmic reticulum (ER) stress are responsible for acinar cell apoptosis. Factors that cause ER stress cause irreversible damage to acinar cells; It causes disruption of Ca⁺⁺ signaling, elevated ROS levels, and cytochrome c release, resulting in a local inflammatory response. However, lower levels of ROS prevent necrosis and reduce the severity of AP [30-32]. We showed that tissue oxidative stress decreased, MDA levels decreased and cell apoptosis was limited with a decrease in caspase 3 levels in the group that received NS pretreatment in present report.

It has been shown in other studies that NS reduces oxidative stress, has a scavenger effect against free oxygen radicals, and reduces lipid peroxidation [19,33]. In our study, it was shown that while oxidative stress and apoptosis indicators increased in the ANP group, MDA and Caspase levels decreased with NS pretreatment. A reduction was observed in amylase, lipase and LDH levels with the minimization of acinar cell damage.

Thimoquinone is held responsible for the basic biological activity of NS. However, Also, vitamins (1-4%), proteins (25%), carbohydrates (33%), alkaloids (0.01%), fixed oil (22-38%), minerals (3.7-7%), essential oil (0.40-1.5%), and saponins (0.013%) are included in its composition. Different components in its content are responsible for the different effects of NS [34]. It can be revealed which compound is for which target with further studies. In a study, it was reported that there was no efficacy difference between NS and NS Oil in terms of anti-inflammatory and antioxidant effects in the inflammation picture driven by LPS [35].

It is a limitation in our study that we did not show which component of the NS had protective effect of NS, and only TNF- α levels were studied, and the levels of other cytokines were not investigated. Nevertheless, it is the first study to investigate the effect of NS in the ANP model.

CONCLUSION

In conclusion, NS pretreatment ameliorated pancreatic tissue damage in taurocholate-induced AP in rats. This protective effect was demonstrated histologically, immunohistochemically, and biochemically. We can say that the protective effect of NS is exerted by inhibiting the TNF- α through neutrophils and by blocking the NF-KB pathway, and it has an antioxidant effect by reducing lipid peroxidation in the inflammatory process. More detailed experimental and clinical studies are required to understand how NS acts in acute pancreatitis.

AUTHORS' CONTRIBUTION

Mehmet Ali Kosekli, Ozlem Ozmen: Design, Conduct.
Mustafa Yilmaz, Sima Sahinduran, Mehmet Ali Kosekli: Data collection.
Mehmet Ali Kosekli: Experimental procedure.
Ozlem Ozmen, Sima Sahinduran: Statistical analysis.
Mehmet Ali Kosekli: Writing of first draft.
Mehmet Ali Kosekli, Ozlem Ozmen, Sima Sahinduran, Mustafa Yilmaz: Approval of the final version.

CONFLICT OF INTEREST

Declared none.

ACKNOWLEDGEMENTS

Declared none.

REFERENCES

- [1] Isogai M, Yamaguchi A, Hori A, Nakano S. Hepatic histopathological changes in biliary pancreatitis. *Am J Gastroenterol* 1995; 90 (3): 449-54.
- [2] Saluja A, Saluja M, Villa A, et al. Pancreatic duct obstruction in rabbits causes digestive zymogen and lysosomal enzyme colocalization. *J Clin Invest* 1989; 84 (4): 1260-6. DOI: 10.1172/JCI114293
- [3] van Santvoort HC, Bakker OJ, Bollen TL, et al. A conservative and minimally invasive approach to necrotizing pancreatitis improves outcome. *Gastroenterology* 2011; 141 (4): 1254-63. DOI: 10.1053/j.gastro.2011.06.073
- [4] Schepers NJ, Bakker OJ, Besselink MG, et al. Impact of characteristics of organ failure and infected necrosis on mortality in necrotizing pancreatitis. *Gut* 2019; 68 (6): 1044-51. DOI: 10.1136/gutjnl-2017-314657
- [5] Popovic JR, Hall MJ. 1999 National Hospital Discharge Survey: Annual summary with detailed diagnosis and procedure data. *Vital Health Stat* 13 2001; (151): i-v, 1-206. DOI: 10.1037/e309042005-001
- [6] Sharieatzadeh SM, MalkyRad A, Hovaida R, Rahzani K, AghaJohary M, Fazli D. The effect of *Nigella Sativa* on oxidative stress. *J Shahrekord Univ Med Sci* 2011; 12 (4): 21-6.
- [7] Burits M, Bucar F. Antioxidant activity of *Nigella Sativa* essential oil. *Phytotherapy Res* 2000; 14 (5): 323-8. DOI: 10.1002/1099-1573(200008)14:5<323::AID-PTR621>3.0.CO;2-Q
- [8] Houghton PJ, Zarka R, de las Heras B, Hoult J. Fixed oil of *Nigella Sativa* and derived thymoquinone inhibit eicosanoid generation in leukocytes and membrane lipid peroxidation. *Planta Medica* 1995; 61 (1): 33-6. DOI: 10.1055/s-2006-957994
- [9] Tekeoglu I, Dogan A, Demiralp L. RETRACTION: Effects of thymoquinone (volatile oil of black cumin) on rheumatoid arthritis in rat models. *Phytother Res* 2006; 20(10): 869-71. DOI: 10.1002/ptr.1964
- [10] Khader M, Bresgen N, Eckl P. *In vitro* toxicological properties of thymoquinone. *Food Chem Toxicol* 2009; 47 (1): 129-33. DOI: 10.1016/j.fct.2008.10.019
- [11] Schwarz M, Thomsen J, Meyer H, Büchler MW, Beger HG. Frequency and time course of pancreatic and extrapancreatic bacterial infection in experimental acute pancreatitis in rats. *Surgery* 2000; 127(4): 427-32 DOI: 10.1067/m-sy.2000.104116
- [12] Chan YC, Leung PS. Acute pancreatitis: Animal models and recent advances in basic research. *Pancreas* 2007; 34 (1): 1-14. DOI: 10.1097/01.mpa.0000246658.38375.04
- [13] Shields C, Winter D, Sookhai S, Ryan L, Kirwan W, Redmond H. Hypertonic saline attenuates end-organ damage in an experimental model of acute pancreatitis. *Br J Surg* 2000; 87 (10): 1336-40. DOI: 10.1046/j.1365-2168.2000.01626.x
- [14] Kosekli MA, Herek Ö, Ozmen Ö, Sahinduran S. Ameliorative effect of certolizumab on experimentally induced acute necrotic pancreatitis in rats. *Rev Assoc Med Brasil* 2019; 65 (2): 204-10. DOI: 10.1590/1806-9282.65.2.204
- [15] Dimagno EP, Shorter RG, Taylor WF, Go VLW. Relationships between pancreaticobiliary ductal anatomy and pancreatic ductal and parenchymal histology. *Cancer* 1982; 49 (2): 361-8. DOI:10.1002/1097-0142(19820115)49:2<361::AID-CN-CR2820490225>3.0.CO;2-O
- [16] Lerch MM, Saluja AK, Rünzi M, Dawra R, Saluja M, Steer ML. Pancreatic duct obstruction triggers acute necrotizing pancreatitis in the opossum. *Gastroenterology* 1993; 104 (3): 853-61. DOI: 10.1016/0016-5085(93)91022-A
- [17] Emeka LB, Emeka PM, Khan TM. Antimicrobial activity of *Nigella Sativa* L. seed oil against multi-drug resistant *Staphylococcus aureus* isolated from diabetic wounds. *Pakistan J Pharm Sci* 2015; 28 (6): 1985-90.
- [18] Chehl N, Chipitsyna G, Gong Q, Yeo CJ, Arafat HA. Anti-inflammatory effects of the *Nigella Sativa* seed extract, thymoquinone, in pancreatic cancer cells. *HPB* 2009; 11 (5): 373-81. DOI: 10.1111/j.1477-2574.2009.00059.x
- [19] Bordoni L, Fedeli D, Nasuti C, et al. Antioxidant and anti-inflammatory properties of *Nigella Sativa* oil in human pre-adipocytes. *Antioxidants* 2019; 8 (2): 51. DOI: 10.3390/antiox8020051
- [20] Vonlaufen A, Wilson JS, Apte MV. Molecular mechanisms of pancreatitis: Current opinion. *J Gastroenterol Hepatol* 2008; 23 (9): 1339-48. DOI: 10.1111/j.1440-1746.2008.05520.x
- [21] Merza M, Hartman H, Rahman M, et al. Neutrophil extracellular traps induce trypsin activation, inflammation, and tissue

- damage in mice with severe acute pancreatitis. *Gastroenterology* 2015; 149 (7): 1920-31. e1928. DOI: 10.1053/j.gastro.2015.08.026
- [22] Leppkes M, Maueröder C, Hirth S, *et al.* Externalized decondensed neutrophil chromatin occludes pancreatic ducts and drives pancreatitis. *Nat Commun* 2016; 7 (1): 1-13. DOI: 10.1038/ncomms10973
- [23] Madhi R, Rahman M, Taha D, Mörgelin* M, Thorlacius H. Targeting peptidylarginine deiminase reduces neutrophil extracellular trap formation and tissue injury in severe acute pancreatitis. *J Cell Physiol* 2019; 234 (7): 11850-1160. DOI: 10.1002/jcp.27874
- [24] Haq A, Abdullatif M, Lobo PI, Khabar KS, Sheth KV, Al-Se-dairy ST. *Nigella Sativa* : Effect on human lymphocytes and polymorphonuclear leukocyte phagocytic activity. *Immunopharmacology* 1995; 30 (2): 147-55. DOI: 10.1016/0162-3109(95)00016-M
- [25] Kacem R, Meraihi Z. Effects of essential oil extracted from *Nigella Sativa* (L.) seeds and its main components on human neutrophil elastase activity. *Yakugaku Zasshi* 2006; 126 (4): 301-5. DOI: 10.1248/yakushi.126.301
- [26] Abdulla A, Awla D, Thorlacius H, Regnér S. Role of neutrophils in the activation of trypsinogen in severe acute pancreatitis. *J Leukocyte Biol* 2011; 90 (5): 975-82. DOI: 10.1189/jlb.0411195
- [27] McKay C, Gallagher G, Brooks B, Imrie C, Baxter J. Increased monocyte cytokine production in association with systemic complications in acute pancreatitis. *J Br Surg* 1996; 83(7): 919-23. DOI: 10.1002/bjs.1800830712
- [28] Jakkampudi A, Jangala R, Reddy R, *et al.* Acinar injury and early cytokine response in human acute biliary pancreatitis. *Scientific Rep* 2017; 7(1): 1-13. DOI: 10.1038/s41598-017-15479-2
- [29] Yilmaz M, Topsakal S, Herek O, *et al.* Effects of etanercept on sodium taurocholate-induced acute pancreatitis in rats. *Transl Res* 2009; 154(5): 241-9. DOI: 10.1016/j.trsl.2009.07.009
- [30] Lugea A, Waldron RT, French SW, Pandol SJ. Drinking and driving pancreatitis: Links between endoplasmic reticulum stress and autophagy. *Autophagy* 2011; 7(7): 783-5. DOI: 10.4161/auto.7.7.15594
- [31] Barrera K, Stanek A, Okochi K, *et al.* Acinar cell injury induced by inadequate unfolded protein response in acute pancreatitis. *World J Gastrointestinal Pathophysiol* 2018; 9 (2): 37-46. DOI: 10.4291/wjgp.v9.i2.37
- [32] Armstrong JA, Cash NJ, Ouyang Y, *et al.* Oxidative stress alters mitochondrial bioenergetics and modifies pancreatic cell death independently of cyclophilin D, resulting in an apoptosis-to-necrosis shift. *J Biol Chem* 2018; 293 (21): 8032-47. DOI: 10.1074/jbc.RA118.003200
- [33] Pourgholamhossein F, Shariffar F, *et al.* Thymoquinone effectively alleviates lung fibrosis induced by paraquat herbicide through down-regulation of pro-fibrotic genes and inhibition of oxidative stress. *Environ Toxicol Pharmacol* 2016; 45: 340-5. DOI: 10.1016/j.etap.2016.06.019
- [34] Amin B, Hosseinzadeh H. Black cumin (*Nigella Sativa*) and its active constituent, thymoquinone: An overview on the analgesic and anti-inflammatory effects. *Planta Medica* 2016; 82 (1-2): 8-16. DOI: 10.1055/s-0035-1557838
- [35] Entok E, Ustuner MC, Ozbayer C, *et al.* Anti-inflammatar and anti-oxidative effects of *Nigella Sativa* L.: 18 FDG-PET imaging of inflammation. *Mol Biol Rep* 2014; 41 (5): 2827-34. DOI: 10.1007/s11033-014-3137-2