

Retrospective Cohort Study

Resection of pancreatic cystic neoplasms in recurrent acute pancreatitis prevents recurrent pancreatitis but does not identify more malignancies

Thiruvengadam Muniraj, Harry R Aslanian, Loren Laine, Priya A Jamidar, James F Farrell, Kisha A Mitchell, Ronald R Salem

ORCID number: Thiruvengadam Muniraj 0000-0002-4904-2645; Harry R Aslanian 0000-0000-0001-0001; Loren Laine 0000-0000-0002-0002; Priya A Jamidar 0000-0000-0003-0003; James F Farrell 0000-0003-0004-5693; Kisha A Mitchell 0000-0000-0006-0006; Ronald R Salem 0000-0000-0007-0007.

Author contributions: Muniraj T, Aslanian HR, Laine L and Salem RR performed the study design; Muniraj T, Aslanian HR, and Salem RR performed the data acquisition; Muniraj T performed the statistical analysis; Muniraj T, Aslanian HR, and Laine L drafting of the manuscript; all authors performed data interpretation, review of manuscript for important intellectual content, final approval of the manuscript, and access to the data and a role in writing the manuscript.

Institutional review board

statement: The study was reviewed and approved by the Yale University Institutional Review Board, USA, No. 2000029508.

Informed consent statement: The signed informed consent forms have been waived by the Yale

Thiruvengadam Muniraj, Harry R Aslanian, Loren Laine, Priya A Jamidar, James F Farrell, Section of Digestive Diseases, Department of Medicine, Yale University School of Medicine, New Haven, CT 06510, United States

Kisha A Mitchell, Department of Pathology, Yale University School of Medicine, New Haven, CT 06510, United States

Ronald R Salem, Department of Surgery, Yale University School of Medicine, New Haven, CT 06510, United States

Corresponding author: Thiruvengadam Muniraj, MD, Assistant Professor, Department of Digestive Diseases, Yale University School of Medicine, 15 York Street, New Haven, CT 06510, United States. thiruvengadam.muniraj@yale.edu

Abstract**BACKGROUND**

Recurrent acute pancreatitis (RAP) may be a presenting feature of and an indication for resection of pancreatic cysts, including intra-ductal papillary mucinous neoplasm (IPMN). Few data are available regarding the prevalence of malignancy and post-operative RAP in this population.

AIM

To study the role of resection to help prevent RAP and analyze if presentation as RAP would be a predictor for malignancy.

METHODS

This retrospective study assessed 172 patients who underwent surgical resection of pancreatic cystic neoplasms at a university hospital between 2002 and 2016. The prevalence of preoperative high-risk cyst features, and of neoplasia was compared between patients with and without RAP. To identify the cause of pancreatitis, all the patients had a detailed history of alcohol, smoking, medications obtained, and had cross-sectional imaging (contrast-enhanced computed tomography/magnetic resonance imaging) and endoscopic ultrasound to look for gallstone etiology and other structural causes for pancreatitis. The incidence of RAP post-resection was the primary outcome.

University Institutional Review Board.

Conflict-of-interest statement: They authors declare that they have no conflict of interest.

Data sharing statement: No additional data are available.

STROBE statement: The authors have read the STROBE Statement – checklist of items, and the manuscript was prepared and revised according to the STROBE Statement – checklist of items.

Open-Access: This article is an open-access article that was selected by an in-house editor and fully peer-reviewed by external reviewers. It is distributed in accordance with the Creative Commons Attribution NonCommercial (CC BY-NC 4.0) license, which permits others to distribute, remix, adapt, build upon this work non-commercially, and license their derivative works on different terms, provided the original work is properly cited and the use is non-commercial. See: <http://creativecommons.org/licenses/by-nc/4.0/>

Manuscript source: Invited manuscript

Specialty type: Gastroenterology and hepatology

Country/Territory of origin: United States

Peer-review report's scientific quality classification

Grade A (Excellent): 0
Grade B (Very good): B, B
Grade C (Good): C, C, C
Grade D (Fair): D
Grade E (Poor): 0

Received: December 21, 2020

Peer-review started: December 21, 2020

First decision: January 10, 2021

Revised: January 24, 2021

Accepted: March 22, 2021

Article in press: March 22, 2021

Published online: April 21, 2021

P-Reviewer: Faias S, Gupta V, Inchingolo R, Sato H

RESULTS

IPMN accounted for 101 cases (58.7%) {[branch duct (BD) 59 (34.3%), main duct (MD) 42] (24.4%)}. Twenty-nine (16.9%) presented with RAP (mean 2.2 episodes): 15 had BD-IPMN, 8 MD-IPMN, 5 mucinous cystic neoplasm and 1 serous cystic neoplasm. Malignancy was similar among those with *vs* without RAP for all patients [6/29 (20.7%) *vs* 24/143 (16.8%)] and IPMN patients [6/23 (26.1%) *vs* 23/78 (29.5%)], although tended to be higher with RAP in BD-IPMN, [5/15 (33.3%) *vs* 3/44 (6.8%), $P = 0.04$]. At mean follow-up of 7.2 years, 1 (3.4%) RAP patient had post-resection RAP. The mean episodes of acute pancreatitis before *vs* after surgery were 3.4 *vs* 0.02 ($P < 0.0001$).

CONCLUSION

Malignancy was not increased in patients with pancreatic cystic neoplasms who have RAP compared to those without RAP. In addition, specific cyst characteristics were not clearly associated with RAP. The incidence of RAP was markedly decreased in almost all patients following cyst resection.

Key Words: Pancreatic cyst; Pancreatic neoplasm; Pancreatitis; Malignancies

©The Author(s) 2021. Published by Baishideng Publishing Group Inc. All rights reserved.

Core Tip: Our findings from this original study support international consensus guidelines recommendations for surgical resection of pancreatic cystic neoplasms presenting with acute pancreatitis but more for the effective treatment of recurrent acute pancreatitis (RAP) rather than for the identification of malignancy. The objective of this research was to study the role of resection to help prevent RAP and analyze if presentation as RAP would be a predictor for malignancy.

Citation: Muniraj T, Aslanian HR, Laine L, Jamidar PA, Farrell JF, Mitchell KA, Salem RR. Resection of pancreatic cystic neoplasms in recurrent acute pancreatitis prevents recurrent pancreatitis but does not identify more malignancies. *World J Gastroenterol* 2021; 27(15): 1630-1642

URL: <https://www.wjgnet.com/1007-9327/full/v27/i15/1630.htm>

DOI: <https://dx.doi.org/10.3748/wjg.v27.i15.1630>

INTRODUCTION

Acute pancreatitis is among the most frequent gastrointestinal causes of hospital admission in the United States with nearly 280000 hospitalizations annually^[1]. While pancreatic cysts in the setting of pancreatitis are frequently assumed to be pseudocysts, neoplastic pancreatic cysts are recognized as a cause of acute pancreatitis. Intra-ductal papillary mucinous neoplasms (IPMN) are the most common cystic pancreatic neoplasms. They arise within the main pancreatic duct or side-branches and are characterized by production of thick mucinous fluid. Additional pancreas cystic neoplasms include mucinous cystic neoplasm and serous cystic neoplasm. Pancreatic cysts may cause acute pancreatitis by compression of the pancreatic duct or by obstruction of the pancreatic duct with mucus. The reported rate of acute pancreatitis among patients with IPMN varies between 7% and 67%^[2-5]. A careful clinical history could help to differentiate such neoplastic cysts from a mature, encapsulated fluid collection without necrosis (pseudocyst) or with necrosis (walled-off necrosis, WON) that may occur as a cystic lesion after 4 wk from the onset of acute pancreatitis^[6]. The presence of a pancreatic cyst in imaging at diagnosis of index pancreatitis is probably a neoplastic cyst, while the detection of a cyst in the follow-up of pancreatitis with a normal first imaging exam likely a post inflammatory pseudocyst or WON.

The diagnosis of acute pancreatitis is based on the presence of two of the following three features: (1) Abdominal pain consistent with acute pancreatitis (acute onset of a persistent, severe, epigastric pain often radiating to the back); (2) Serum lipase activity (or amylase activity) at least three times greater than the upper limit of normal; And (3) Characteristic findings of acute pancreatitis on contrast-enhanced computed

S-Editor: Fan JR**L-Editor:** A**P-Editor:** Ma YJ

tomography (CECT) or magnetic resonance imaging (MRI) or transabdominal ultrasonography^[6]. Recurrent acute pancreatitis (RAP), defined as two or more definite episodes of acute pancreatitis, occurs in approximately 17% to 29% of patients who present with a first episode of acute pancreatitis^[5,7-9]. Approximately 80% of RAP is related to alcohol and gallstones. Other etiologies include medications, pancreas divisum, sphincter of Oddi dysfunction, pancreatic cancer, hypertriglyceridemia, hypercalcemia, infections, and genetic predisposition^[10,11].

Few data are available regarding the prevalence of malignancy and on the course of RAP associated with pancreatic cystic neoplasms, such as IPMN, and the potential benefit of surgical resection in patients with acute pancreatitis due to pancreatic cysts. We, therefore, performed a retrospective study to assess the characteristics of patients with pancreatic cystic neoplasms who present with unexplained RAP and the effect of surgical resection on the natural history.

MATERIALS AND METHODS

We conducted a retrospective cohort study at the Yale-New Haven Hospital to identify patients who underwent surgical resection of pancreatic cystic neoplasms between January 1, 2002 and December 1, 2016. Those who had RAP, defined as 2 or more episodes of acute pancreatitis without an identifiable cause prior to resection^[12], and imaging [computed tomography, magnetic resonance imaging, and/or endoscopic ultrasound (EUS)] documenting the cyst pre-operatively were defined as the RAP cohort. To identify the cause of pancreatitis, all the patients had detailed history of alcohol, smoking, medications obtained and had cross-sectional imaging (CECT/MRI) and EUS to look for gallstone etiology and other structural causes for pancreatitis. The diagnosis was double-checked. Patients with resection who did not have prior RAP served as the control cohort. Patient follow-up extended until September 2018. The study was approved by the institutional review board at Yale University.

Preoperative classification was based on preoperative imaging and results of fine-needle aspiration, if performed. Cysts were classified as IPMNs and non-IPMNs. The IPMNs were sub-classified as main-duct (MD) and branch-duct (BD). Mixed-type IPMNs were included in the MD group. Preoperative diagnosis of IPMNs were based on clinical findings from the images obtained. Histopathology from post-surgical resection specimens was used as the gold standard to ascertain the final diagnosis. The pathological classification and pre-surgical classification were made on the basis of World Health Organization criteria and current literature^[13-16]. Performing metastatic urothelial cancer (MUC) staining or gene sequencing

Malignancy was defined as the presence of invasive carcinoma or high-grade dysplasia on final surgical pathology. Patients with no follow-up data post-operatively, known pseudocysts and predominantly solid pancreatic masses were excluded. Patient demographic, clinical, radiographic, and pathologic data were extracted from the medical record. In patients with multiple cysts, the features of the largest cyst or the cyst with the most concerning high-risk features (*e.g.*, mural nodules) were the characteristics recorded for the patient. Patient data post-resection were also extracted, with the primary goal of identifying episodes of acute pancreatitis. On surgically resected specimens, MUC staining, histologic examination and gene sequencing were used for pathologic subclassification^[17,18].

Statistical analysis

The primary analysis involved a comparison of the number of episodes of acute pancreatitis pre- and post-resection of pancreas cyst in patients who had RAP. We also compared baseline patient and cyst characteristics between patients with RAP and those without RAP. Comparisons between the RAP cohort and control (non-RAP) cohort and between the preoperative and post-operative time period were performed with the Mantel-Haenszel risk difference calculation for continuous variables and Mantel-Haenszel risk ratio for proportions. Statistical analysis was performed by using the statistical algorithms in Cochrane Review Manager Software 5.3.

RESULTS

A total of 172 patients with pancreatic cysts underwent surgery between 2002 and

2016. The indication for surgery was RAP along with cyst characteristics in 11 patients and among all other patients, the indication for surgery was based on the cyst morphology. IPMNs accounted for 101 (58.7%) of these 172 cases {BD-IPMN [59 (34.3%)] and MD-IPMN [42 (24.4%)]} (Table 1 and Figure 1). The next most common types of lesions were mucinous cystic neoplasms [32/172 (18.6%)] and serous cystic neoplasms [16/172 (9.3%)] (Table 1). Since preoperative diagnosis on cysts were made using radiologic findings, the final diagnosis might have varied based on surgical findings. Twenty-nine (16.9%) patients had RAP without other identifiable cause prior to resection, while the remaining 143 (83.1%) patients had no episodes of acute pancreatitis prior to resection. No patient had evidence of chronic pancreatitis. Among the 29 patients with RAP with cystic neoplasms, the surgical procedure performed was pancreaticoduodenectomy ($n = 18$) or distal pancreatectomy ($n = 11$) with surgical mortality 0%, morbidity 3/29 (10%) (one patient had mesenteric bleeding requiring immediate exploratory laparotomy, one had afferent limb syndrome 2 wk later required exploratory laparotomy for adhesion lysis, and other with a delayed abscess in left upper quadrant managed with external drainage).

Comparison of pre-resection and post-resection period in the RAP cohort

The mean number of pancreatitis episodes *per* patient prior to resection in the RAP cohort was 2.2 (range 2-32 episodes). The median elapsed time between the first episode of acupuncture (AP) and surgery was 17 mo (range 1.5 mo to 7 years). The mean follow-up after surgery was 7.2 years (range 1.9-13.8 years).

Only 1 (3%) of 29 RAP patients (with BD-IPMN) had acute pancreatitis documented post-resection. The mean number of recurrent episodes of acute pancreatitis *per* patient-year before *vs* after surgery was 3.40 *vs* 0.02 (absolute difference = 3.38, 95% CI 1.76 to 5.00; $P < 0.0001$). All the episodes were mild acute pancreatitis and none of the patients in this cohort had severe acute pancreatitis^[6]. A marked decrease was seen in all types of cysts (Table 2). The one patient with recurrent pancreatitis after resection had BD-IPMN; he had 8 episodes before resection and 32 after resection and progressed to chronic pancreatitis with ductal calcification at 6 years after resection. No patient without prior RAP developed acute pancreatitis after resection.

Comparison of RAP and control cohort

Selected characteristics of the RAP and control cohorts are shown in Table 3. Median age and proportion who were male were comparable. No clear differences were identified between the cohorts in characteristics of the cystic lesions, including in size, or proportion with malignancy except for location in the tail of pancreas where most cyst patients were without RAP. IPMNs tended to be more common among patients with RAP than in those without RAP (79.3% *vs* 54.5%; risk difference = 0.25; 95% CI: 0.08, 0.41, $P = 0.004$) with most of the difference seen in the BD-IPMN patients.

Table 4 shows the results for the RAP and control cohorts in all patients with IPMN. Patients with RAP were more likely to have intestinal and less likely to the gastric IPMN cysts (intestinal: 34.8% *vs* 12.8%; risk difference: 0.22 (95% CI: 0.01, 0.43); $P = 0.04$; gastric: 13% *vs* 53.9%; risk difference: -0.41 (95% CI: -0.58, -0.23); $P < 0.0001$). The pathological subtypes of 21.8% of RAP patients and 10.3% of non-RAP patients was unknown.

Table 5 is restricted to patients with BD-IPMN. Again, no clear differences were seen between cohorts in patient or cyst characteristics with the possible exception of a tendency to a higher prevalence of malignancy in the RAP group *vs* non-RAP group with BD-IPMNs {33.3% *vs* 6.8%, [risk difference = 0.27 (95% CI: 0.02, 0.52); $P = 0.04$] although the numbers in each cohort were small. A similar difference in pathological subtypes were noted. Patients with RAP were more likely to have BD-IPMN of an intestinal subtype and less likely to have a gastric subtype *vs* the control cohort [intestinal: 46.7% *vs* 9.1%; risk difference = 0.38 (95% CI: 0.11, 0.64); $P = 0.006$; gastric: 0% *vs* 68.2%; risk difference = -0.68 (95% CI: -0.84, -0.52); $P < 0.001$]. However, it should be noted that the pathological subtype of 26.7% of BD-IPMNs was not recorded. Based on the significant results from Univariate analysis, multivariable analysis logistic regression performed, however, the results did not vary in any significance (Tables 6-8).

DISCUSSION

Surgical resection has been recommended for patients with pancreatic cystic neoplasms who present with acute pancreatitis^[16], regardless of cyst type. Reasons for

Table 1 Types of pancreatic cysts

IPMN cysts (total)	101
BD-IPMN	59
MD-IPMN	42
Non-IPMN cysts (total)	71
Mucinous cystic neoplasm	32
Serous cystic neoplasm	16
Pancreatic neuroendocrine tumor	11
Solid pseudopapillary epithelial neoplasm	6
Squamoid	3
Benign	2
Cystic degeneration	1

IPMN: Intra-ductal papillary mucinous neoplasm; MD-IPMN: Main duct-IPMN; BD-IPMN: Branch duct-IPMN.

Table 2 Incidence of recurrent acute pancreatitis episodes in recurrent acute pancreatitis patients

	Episodes per patient-year (mean + SD)		Mean difference [95%CI]	P value
	Pre-resection	Post-resection		
All cysts (<i>n</i> = 29)	3.40 (4.46)	0.02 (0.08)	3.38 [1.76, 5.00]	< 0.0001
IPMN (<i>n</i> = 23)	2.32 (1.69)	0.03 (0.09)	2.29 [1.60, 2.98]	< 0.0001
BD-IPMN (<i>n</i> = 15)	2.06 (1.85)	0.04 (0.11)	2.02 [1.08, 2.96]	< 0.0001
MD-IPMN (<i>n</i> = 8)	2.81 (1.32)	0 (0) ¹	2.81 [1.83, 3.79]	< 0.0001
Non-IPMN (<i>n</i> = 6)	7.52 (8.53)	0 (0) ¹	7.52 [0.69, 14.35]	0.03

¹In order to calculate mean differences and risk ratios, a standard deviation of 0.0001 was substituted for zero. IPMN: Intra-ductal papillary mucinous neoplasm; MD-IPMN: Main duct-IPMN; BD-IPMN: Branch duct-IPMN; SD: Standard deviation; CI: Confidence interval.

resection include identification and removal of underlying malignancy, prevention of the development of malignancy, and prevention of additional attacks of pancreatitis^[16]. The characteristics of cystic neoplasms associated with acute pancreatitis and the impact of surgical resection on the prevention of malignancy and future episodes of RAP, however, have not been well defined. We found that cyst characteristics, such as location, size, the proportion with solid component, and prevalence of malignancy were not clearly different between patients with *vs* without RAP. IPMN was the most common cystic neoplasm among patients with a history of RAP undergoing surgical resection. Although a prior report found MD/combined type IPMN to be more frequently associated with RAP (%)^[3] and another study found no difference^[5], we found that among patients with IPMN, RAP was more often associated with BD-IPMN (65%) than MD-IPMN (35%). Our results are different from Jang *et al*^[3] where MD/combined IPMN resulting more RAP was thought to be due to mechanical obstruction of the main pancreatic duct by thick mucin, resulting in ductal hypertension, thereby premature activation and release of pancreatic enzymes^[3]. However, BD-IPMN leading to AP/RAP is assumed primarily due to the obstruction of the main pancreatic duct by the migration of mucin from the BD or may not be related to mucin but just to the viscosity of cyst fluid^[3]. Patients with RAP also were more likely to have intestinal histological subtype *vs* the control cohort, although histologic subtype was unknown in a third of patients.

Malignancy was present in approximately one-fifth of patients undergoing surgical resection of pancreatic cysts, with similar proportions in those with and without RAP. Malignancy tended to be more common in BD-IPMN patients with RAP (33.3% *vs* 6.8% without RAP), although given relatively small numbers and multiple comparisons, this finding must be viewed as hypothesis-generating. Prior studies vary

Table 3 Characteristics of all patients (n = 172)

	With RAP (n = 29) n (%)	Without RAP (n = 143) n (%)	Risk difference [95%CI]	P value
Median age	61 (IQR 18)	65 (IQR 15)	NA	0.65
Sex (M)	13 (44.8)	58 (40.6)	NA	0.67
Location of cyst				
Head	16 (55.2)	65 (45.5)	0.10 [-0.10, 0.30]	0.34
Neck	2 (6.9)	7 (4.9)	0.02 [-0.08, 0.12]	0.69
Body	8 (27.6)	32 (22.4)	0.05 [-0.12, 0.23]	0.56
Tail	3 (10.3)	37 (25.9)	-0.16 [-0.29, -0.02]	0.02
Diffuse	0 (0)	2 (1.4)	-0.01 [-0.06, 0.04]	0.59
Main pancreas duct > 10	4 (13.8)	10 (7.0)	0.07 [-0.06, 0.20]	0.31
Cyst size > 3	6 (20.7)	36 (25.2)	-0.04 [-0.21, 0.12]	0.59
Solid component	7 (24.1)	46 (32.2)	-0.08 [-0.25, 0.09]	0.36
Malignancy	6 (20.7)	24 (16.8)	0.04 [-0.12, 0.20]	0.63
Pathological subtype				
Intestinal	10 (34.5)	11 (7.7)	0.27 [0.09, 0.45]	0.003
Gastric	3 (10.3)	43 (30.1)	-0.20 [-0.33, -0.06]	0.004
Pancreatobiliary	7 (24.1)	15 (10.5)	0.14 [-0.03, 0.30]	0.10
Oncocytic	0 (0)	3 (2.1)	-0.02 [-0.07, 0.03]	0.43
Unknown	9 (31.0)	71 (49.7)	-0.19 [-0.37, 0.001]	0.05
Cyst type				
IPMN total	23 (79.3)	78 (54.5)	0.25 [0.08, 0.41]	0.004
BD-IPMN	15 (51.7)	44 (30.8)	0.21 [0.01, 0.41]	0.04
MD-IPMN	8 (27.6)	34 (23.8)	0.04 [-0.14, 0.22]	0.67
Non-IPMN	6 (20.7)	65 (45.5)	-0.25 [-0.42, -0.08]	0.004

RAP: Recurrent acute pancreatitis; IPMN: Intra-ductal papillary mucinous neoplasm; MD-IPMN: Main duct-IPMN; BD-IPMN: Branch duct-IPMN; IQR: Interquartile range; CI: Confidence interval.

in the reported association of malignancy within pancreatic cysts in patients presenting with acute pancreatitis^[19]. Some report no increased risk^[20-22]. However, a recent study identified IPMN presenting with acute pancreatitis to be associated with an increased risk of malignancy as compared to IPMN without pancreatitis on multivariable analysis^[23]. Morales-Oyarvide *et al*^[23] also identified a significant association of AP with IPMN of intestinal subtype (OR = 4.7, 2.5-8.8)^[23]. The intestinal phenotype of IPMN has a propensity for mucin hypersecretion, which may promote AP due to ductal obstruction^[24-27]. In addition, the intestinal phenotype has been associated with an increased risk of malignancy and with colloid carcinoma^[25].

Among the 15 BD-IPMN patients with RAP who had surgical resection in our study, pre-operatively only 1 (6.7%) demonstrated all 3 high-risk features for malignancy (dilated main pancreatic duct > 10 mm, size > 3 cm, solid component)^[28] and 3 (20%) had 2 high-risk features. One-third, however, had malignancy identified on surgical pathology. Based on the presence of high-risk stigmata/worrisome features alone, *per* international revised consensus guidelines of 2017^[16,29] or European guidelines^[30], resection would not have been indicated in 14 of the 15 BD-IPMN patients if they had not presented with acute pancreatitis. And based on American Gastroenterological Association guidelines, if these patients did not have RAP, only 3 of 15 would have had EUS based on the requirement for at least 2 high-risk features^[28]. American College of Gastroenterology guidelines recommends EUS or referral to a multidisciplinary team for pancreatic cystic lesions in the presence of pancreatitis regardless of high-risk

Table 4 Characteristics of patients with intra-ductal papillary mucinous neoplasm with and without recurrent acute pancreatitis

	With RAP (n = 23) n (%)	Without RAP (n = 78) n (%)	Risk difference [95%CI]	P value
Median age	64 (IQR 17)	67 (IQR 12)	NA	0.64
Sex (M)	13 (56.5)	38 (48.7)	NA	0.51
Location of cyst				
Head	16 (69.6)	46 (59)	0.11 [-0.11, 0.32]	0.34
Body/Tail	7 (30.4)	32 (41)	-0.11 [-0.32, 0.11]	0.34
Main pancreas duct > 10	4 (17.4)	10 (12.8)	0.05 [-0.13, 0.22]	0.60
Cyst size > 3 cm	6 (26)	36 (46.2)	-0.20 [-0.41, 0.01]	0.06
Solid component	5 (21.7)	20 (25.6)	-0.04 [-0.23, 0.16]	0.69
Malignancy	6 (26.1)	23 (29.5)	-0.03 [-0.24, 0.17]	0.75
Pathological subtype				
Intestinal	8 (34.8)	10 (12.8)	0.22 [0.01, 0.43]	0.04
Gastric	3 (13)	42 (53.9)	-0.41 [-0.58, -0.23]	< 0.0001
Pancreatobiliary	7 (30.4)	15 (19.2)	0.11 [-0.10, 0.32]	0.29
Oncocytic	0 (0%)	3 (3.8)	-0.04 [-0.11, 0.03]	0.30
Unknown	5 (21.8)	8 (10.3)	0.11 [-0.07, 0.30]	0.22

RAP: Recurrent acute pancreatitis; IQR: Interquartile range; CI: Confidence interval.

features^[31]. While observational studies have suggested an increased risk of pancreatic cancer in all patients presenting with acute pancreatitis^[19,32], further studies are needed to evaluate whether acute pancreatitis may be an independent predictor of malignancy within pancreatic cysts.

The primary goal of our study was to determine the post-resection course of patients with RAP associated with pancreatic cystic neoplasms. We found that episodes of RAP are rare following surgical resection of pancreatic cystic neoplasms, suggesting that the pancreatic cystic neoplasms were indeed the cause of RAP in almost all cases. Only 1 (3%) of 29 patients presenting with RAP had RAP after resection, and the rate of acute pancreatitis *per patient-year* decreased from 3.4 to 0.02 ($P < 0.0001$), with marked reductions in all types of pancreatic cystic lesions. It is also important to note that as the pancreatic exocrine function decreases after pancreas resection, the mere resection itself may reduce the frequency of RAP^[33]. Pancreatic surgery for an indication of RAP alone is a very invasive procedure and therefore, risk/benefits should be considered while making the decision. In such cases, since the pancreatic ductal occlusion at the site of the papilla has been postulated to be the main reason for RAP in IPMN, performing an endoscopic pancreatic sphincterotomy with or without stenting may be effective in preventing pancreatitis recurrence^[34].

We recognize several limitations to this study, including the retrospective review of data. In addition, this cohort is limited to patients who have undergone surgical resection of pancreas cystic neoplasms, which makes it a selected population not representative of the overall group of patients with pancreatic cystic neoplasms. For example, most patients with BD-IPMN or serous cystic neoplasms do not undergo resection. Patient cases were reviewed to exclude other identifiable causes of acute pancreatitis; however, given the study's retrospective nature, the evaluation was not standardized. All of the patients in our surgical cohort had RAP, with 2 or more episodes. This is reflective of clinical practice for BD-IPMN, as resection in the absence of multiple high-risk features is typically not pursued following a single episode of idiopathic pancreatitis. Although, this study clearly shows the risk reduction of RAP after the pancreatic resection, further investigation with large population prospective study is needed to prove causal relationship between the cause of RAP and pancreatic resection.

Table 5 Characteristics of patients with branch-duct intra-ductal papillary mucinous neoplasm with and without recurrent acute pancreatitis

	With RAP (<i>n</i> = 15) <i>n</i> (%)	Without RAP (<i>n</i> = 44) <i>n</i> (%)	Risk difference [95%CI]	<i>P</i> value
Median age	60 (IQR 23)	65 (IQR 12.5)	NA	0.50
Sex (M)	8 (53.3)	24 (54.6)	NA	0.94
Location of cyst				
Head	11 (73)	28 (64)	0.10 [-0.17, 0.36]	0.47
Body/Tail	4 (9.1)	16 (36)	-0.10 [-0.36, 0.17]	0.47
Main pancreas duct > 10	2 (13.3)	2 (4.6)	0.09 [-0.10, 0.27]	0.35
Cyst size > 3 cm	6 (40)	21 (47.7)	-0.08 [-0.37, 0.21]	0.60
Solid component	2 (13.3)	4 (9.1)	0.04 [-0.15, 0.23]	0.66
Malignancy	5 (33.3)	3 (6.8)	0.27 [0.02, 0.52]	0.04
Pathological subtype				
Intestinal	7 (46.7)	4 (9.1)	0.38 [0.11, 0.64]	0.006
Gastric	0	30 (68.2)	-0.68 [-0.84, -0.52]	< 0.001
Pancreatobiliary	4 (26.7)	7 (16)	0.11 [-0.14, 0.36]	0.4
Oncocytic	0	0	NA	NA
Unknown	4 (26.7)	3 (6.8)	0.20 [-0.04, 0.43]	0.10

RAP: Recurrent acute pancreatitis; IQR: Interquartile range; NA: Not available; CI: Confidence interval.

CONCLUSION

In conclusion, we found that malignancy is not increased in patients with pancreatic cystic neoplasms who have RAP compared to those without RAP. In addition, specific cyst characteristics were not clearly associated with RAP, although intestinal histological subtype appeared to be more common in patients with RAP. Most importantly, episodes of RAP were markedly reduced after cyst resection, with only one of 29 patients having recurrent episodes. Our findings support international consensus guidelines recommendations for surgical resection of pancreatic cystic neoplasms presenting with acute pancreatitis but more for the effective treatment of RAP rather than for the identification of malignancy^[16].

Table 6 Multivariable analysis of all patients (*n* = 172)

	With RAP (<i>n</i> = 29)	Without RAP (<i>n</i> = 143)	<i>P</i> value
	Odds ratio	95%CI	
Location of cyst			
Head	-		
Neck	1.240013	[0.19933, 7.713993]	0.818
Body	1.736854	[0.570778, 5.285173]	0.331
Tail	0.686678	[0.155679, 3.028833]	0.62
Diffuse	-		
Pathological subtype			
Intestinal			
Gastric	0.059886	[0.013402, 0.267608]	< 0.001
Pancreatobiliary	0.454606	[0.122387, 1.688636]	0.239
Oncocytic	-		
Unknown	0.355592	[0.088518, 1.428472]	0.145
Cyst type			
IPMN total	3.462462	[0.782586, 15.31927]	0.102
BD-IPMN	1.660612	[0.558816, 4.934779]	0.361
MD-IPMN	-		

RAP: Recurrent acute pancreatitis; IPMN: Intra-ductal papillary mucinous neoplasm; MD-IPMN: Main duct-IPMN; BD-IPMN: Branch duct-IPMN; CI: Confidence interval.

Table 7 Multivariable analysis of patients with intra-ductal papillary mucinous neoplasm with and without recurrent acute pancreatitis

	With RAP (n = 29)	Without RAP (n = 143)	P value
	Odds ratio	95%CI	
Location of cyst			
Head	-	-	
Neck	1.265446	[0.169046, 9.472912]	0.819
Body	0.506621	[0.111835, 2.295024]	0.378
Tail	0.572817	[0.090659, 3.619267]	0.554
Diffuse	-	-	
Pathological subtype			
Intestinal	-	-	
Gastric	0.096091	[0.020977, 0.440165]	0.003
Pancreatobiliary	0.773074	[0.199147, 3.001027]	0.71
Oncocytic	-	-	
Unknown	1.034683	[0.214488, 4.991279]	0.966
Cyst type			
IPMN total			
BD-IPMN	1.571892	[0.530571, 4.65695]	0.414
MD-IPMN	-	-	

RAP: Recurrent acute pancreatitis; IPMN: Intra-ductal papillary mucinous neoplasm; MD-IPMN: Main duct-IPMN; BD-IPMN: Branch duct-IPMN; CI: Confidence interval.

Table 8 Multivariable analysis patients with branch-duct intra-ductal papillary mucinous neoplasm with and without recurrent acute pancreatitis

	With RAP (n = 29)	Without RAP (n = 143)	P value
	Odds ratio	95%CI	
Location of cyst			
Head	-	-	
Neck	-	-	
Body	0.61173	[0.059835, 6.254136]	0.679
Tail	0.537057	[0.050552, 5.705601]	0.606
Diffuse	-	-	
Pathological subtype			
Intestinal	-	-	
Gastric	-	-	
Pancreatobiliary	0.461648	[0.063565, 3.352753]	0.445
Oncocytic	-	-	
Unknown	1.458186	[0.15039, 14.13861]	0.745

RAP: Recurrent acute pancreatitis; CI: Confidence interval.

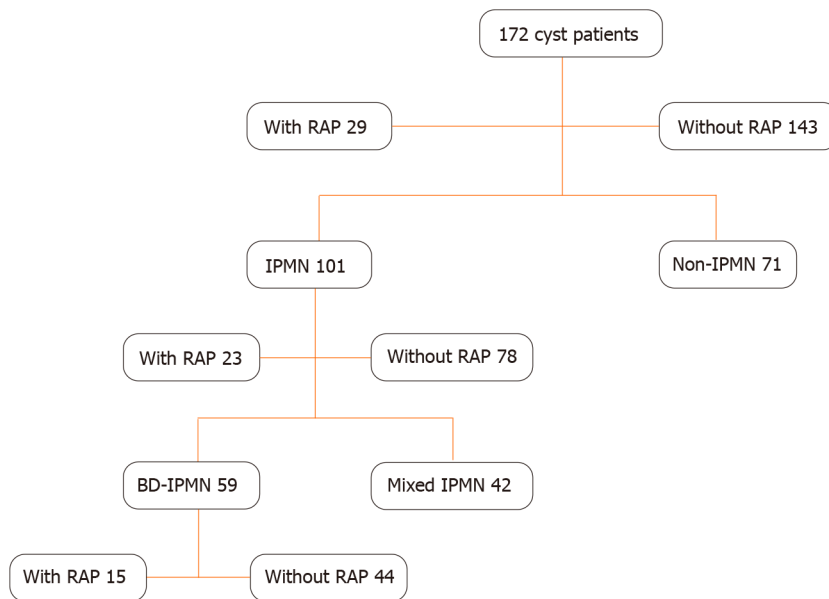


Figure 1 Flow chart of patient population with cyst resection. RAP: Recurrent acute pancreatitis; IPMN: Intra-ductal papillary mucinous neoplasm; BD-IPMN: Branch duct-IPMN.

ARTICLE HIGHLIGHTS

Research background

Pancreatic cystic neoplasms may present recurrent acute pancreatitis (RAP). Little is known on the role of resection for preventing RAP and if any correlation of higher prevalence of malignancy is seen among these patients.

Research motivation

Predicting malignancy among the pancreatic cystic neoplasms and management of RAP is challenging.

Research objectives

The objective of this research was to study the role of resection to help prevent RAP and analyze if presentation as RAP would be a predictor for malignancy.

Research methods

We adopted a retrospective cohort study model, enrolling all the patients with pancreatic cystic neoplasms who underwent surgical resection and compare between those who presented with RAP and without RAP. Incidence of RAP after resection and prevalence of malignancy among those who presented with RAP were the primary outcomes.

Research results

Malignancy was similar among those with *vs* without RAP for all patients 20.7% *vs* 16.8%. The mean episodes of acute pancreatitis before *vs* after surgery were 3.4 *vs* 0.02 ($P < 0.0001$). These findings clearly contribute much to this area of science. Although, this study clearly shows the risk reduction of RAP after the pancreatic resection, further investigation with large population prospective study is needed to prove a causal relationship between the cause of RAP and pancreatic resection.

Research conclusions

When patients with RAP are noted to have pancreatic cysts, it should be emphasized to differentiate if those cysts are the cause or the effect of RAP, *i.e.*, if cystic neoplasms are causing the RAP or if cysts are pseudocysts as a result of RAP. Larger data is needed to see if there exists a causal relationship. Similar to the presentation of jaundice as a predictor for malignancy among pancreas cystic neoplasms, RAP may have a role as a predictor of high-risk cysts.

Research perspectives

Future research to be focused on a larger prospective cohort to answer the above two questions.

REFERENCES

- 1 **Peery AF**, Crockett SD, Murphy CC, Lund JL, Dellon ES, Williams JL, Jensen ET, Shaheen NJ, Barritt AS, Lieber SR, Kochar B, Barnes EL, Fan YC, Pate V, Galanko J, Baron TH, Sandler RS. Burden and Cost of Gastrointestinal, Liver, and Pancreatic Diseases in the United States: Update 2018. *Gastroenterology* 2019; **156**: 254-272. e11 [PMID: [30315778](#) DOI: [10.1053/j.gastro.2018.08.063](#)]
- 2 **Venkatesh PG**, Navaneethan U, Vege SS. Intraductal papillary mucinous neoplasm and acute pancreatitis. *J Clin Gastroenterol* 2011; **45**: 755-758 [PMID: [21602701](#) DOI: [10.1097/MCG.0b013e31821b1081](#)]
- 3 **Jang JW**, Kim MH, Jeong SU, Kim J, Park DH, Lee SS, Seo DW, Lee SK, Kim JH. Clinical characteristics of intraductal papillary mucinous neoplasm manifesting as acute pancreatitis or acute recurrent pancreatitis. *J Gastroenterol Hepatol* 2013; **28**: 731-738 [PMID: [23301513](#) DOI: [10.1111/jgh.12121](#)]
- 4 **Tibayan F**, Vierra M, Mindelzun B, Tsang D, McClenathan J, Young H, Trueblood HW. Clinical presentation of mucin-secreting tumors of the pancreas. *Am J Surg* 2000; **179**: 349-351 [PMID: [10930477](#) DOI: [10.1016/s0002-9610\(00\)00376-7](#)]
- 5 **Crippa S**, Fernández-Del Castillo C, Salvia R, Finkelstein D, Bassi C, Dominguez I, Muzikansky A, Thayer SP, Falconi M, Mino-Kenudson M, Capelli P, Lauwers GY, Partelli S, Pederzoli P, Warshaw AL. Mucin-producing neoplasms of the pancreas: an analysis of distinguishing clinical and epidemiologic characteristics. *Clin Gastroenterol Hepatol* 2010; **8**: 213-219 [PMID: [19835989](#) DOI: [10.1016/j.cgh.2009.10.001](#)]
- 6 **Banks PA**, Bollen TL, Dervenis C, Gooszen HG, Johnson CD, Sarr MG, Tsiotos GG, Vege SS; Acute Pancreatitis Classification Working Group. Classification of acute pancreatitis--2012: revision of the Atlanta classification and definitions by international consensus. *Gut* 2013; **62**: 102-111 [PMID: [23100216](#) DOI: [10.1136/gutjnl-2012-302779](#)]
- 7 **Ahmed Ali U**, Issa Y, Hagens JC, Bakker OJ, van Goor H, Nieuwenhuijs VB, Bollen TL, van Ramshorst B, Witteman BJ, Brink MA, Schaapherder AF, Dejong CH, Spanier BW, Heisterkamp J, van der Harst E, van Eijck CH, Besselink MG, Gooszen HG, van Santvoort HC, Boermeester MA. Risk of Recurrent Pancreatitis and Progression to Chronic Pancreatitis After a First Episode of Acute Pancreatitis. *Clin Gastroenterol Hepatol* 2016; **14**: 738-746 [PMID: [26772149](#) DOI: [10.1016/j.cgh.2015.12.040](#)]
- 8 **Yadav D**, O'Connell M, Papachristou GI. Natural history following the first attack of acute pancreatitis. *Am J Gastroenterol* 2012; **107**: 1096-1103 [PMID: [22613906](#) DOI: [10.1038/ajg.2012.126](#)]
- 9 **Sankaran SJ**, Xiao AY, Wu LM, Windsor JA, Forsmark CE, Petrov MS. Frequency of progression from acute to chronic pancreatitis and risk factors: a meta-analysis. *Gastroenterology* 2015; **149**: 1490-1500. e1 [PMID: [26299411](#) DOI: [10.1053/j.gastro.2015.07.066](#)]
- 10 **Coyle WJ**, Pineau BC, Tarnasky PR, Knapple WL, Aabakken L, Hoffman BJ, Cunningham JT, Hawes RH, Cotton PB. Evaluation of unexplained acute and acute recurrent pancreatitis using endoscopic retrograde cholangiopancreatography, sphincter of Oddi manometry and endoscopic ultrasound. *Endoscopy* 2002; **34**: 617-623 [PMID: [12173081](#) DOI: [10.1055/s-2002-33245](#)]
- 11 **Sajith KG**, Chacko A, Dutta AK. Recurrent acute pancreatitis: clinical profile and an approach to diagnosis. *Dig Dis Sci* 2010; **55**: 3610-3616 [PMID: [20232145](#) DOI: [10.1007/s10620-010-1175-8](#)]
- 12 **Testoni PA**. Acute recurrent pancreatitis: Etiopathogenesis, diagnosis and treatment. *World J Gastroenterol* 2014; **20**: 16891-16901 [PMID: [25493002](#) DOI: [10.3748/wjg.v20.i45.16891](#)]
- 13 **Hruban RPM**, Klimstra DS. Tumors of the Pancreas. Washington, DC: American Registry of Pathology, 2007
- 14 **Adsay NV**, Fukushima N, Bosman FT, Carneiro F, Hruban RH, Theise ND. Intraductal neoplasms of the pancreas, WHO Classification of Tumors. 4th ed. Lyon, France: WHO Press, 2010
- 15 **Ma GK**, Goldberg DS, Thiruvengadam N, Chandrasekhara V, Kochman ML, Ginsberg GG, Vollmer CM, Ahmad NA. Comparing American Gastroenterological Association Pancreatic Cyst Management Guidelines with Fukuoka Consensus Guidelines as Predictors of Advanced Neoplasia in Patients with Suspected Pancreatic Cystic Neoplasms. *J Am Coll Surg* 2016; **223**: 729-737. e1 [PMID: [27497827](#) DOI: [10.1016/j.jamcollsurg.2016.07.011](#)]
- 16 **Tanaka M**, Fernández-del Castillo C, Adsay V, Chari S, Falconi M, Jang JY, Kimura W, Levy P, Pitman MB, Schmidt CM, Shimizu M, Wolfgang CL, Yamaguchi K, Yamao K; International Association of Pancreatology. International consensus guidelines 2012 for the management of IPMN and MCN of the pancreas. *Pancreatol* 2012; **12**: 183-197 [PMID: [22687371](#) DOI: [10.1016/j.pan.2012.04.004](#)]
- 17 **Patra KC**, Bardeesy N, Mizukami Y. Diversity of Precursor Lesions For Pancreatic Cancer: The Genetics and Biology of Intraductal Papillary Mucinous Neoplasm. *Clin Transl Gastroenterol* 2017; **8**: e86 [PMID: [28383565](#) DOI: [10.1038/ctg.2017.3](#)]

- 18 **Furukawa T**, Hatori T, Fujita I, Yamamoto M, Kobayashi M, Ohike N, Morohoshi T, Egawa S, Unno M, Takao S, Osako M, Yonezawa S, Mino-Kenudson M, Lauwers GY, Yamaguchi H, Ban S, Shimizu M. Prognostic relevance of morphological types of intraductal papillary mucinous neoplasms of the pancreas. *Gut* 2011; **60**: 509-516 [PMID: [21193453](#) DOI: [10.1136/gut.2010.210567](#)]
- 19 **Goh BK**, Tan YM, Cheow PC, Chung YF, Chow PK, Wong WK, Ooi LL. Cystic lesions of the pancreas: an appraisal of an aggressive resectional policy adopted at a single institution during 15 years. *Am J Surg* 2006; **192**: 148-154 [PMID: [16860621](#) DOI: [10.1016/j.amjsurg.2006.02.020](#)]
- 20 **Kitagawa Y**, Unger TA, Taylor S, Kozarek RA, Traverso LW. Mucus is a predictor of better prognosis and survival in patients with intraductal papillary mucinous tumor of the pancreas. *J Gastrointest Surg* 2003; **7**: 12-19 [PMID: [12559180](#) DOI: [10.1016/S1091-255X\(02\)00152-X](#)]
- 21 **Sugiyama M**, Izumisato Y, Abe N, Masaki T, Mori T, Atomi Y. Predictive factors for malignancy in intraductal papillary-mucinous tumours of the pancreas. *Br J Surg* 2003; **90**: 1244-1249 [PMID: [14515294](#) DOI: [10.1002/bjs.4265](#)]
- 22 **Pelletier AL**, Hammel P, Rebours V, Couvelard A, Vullierme MP, Maire F, Hentic O, Aubert A, Sauvanet A, Lévy P, Ruszniewski P. Acute pancreatitis in patients operated on for intraductal papillary mucinous neoplasms of the pancreas: frequency, severity, and clinicopathologic correlations. *Pancreas* 2010; **39**: 658-661 [PMID: [20173669](#) DOI: [10.1097/MPA.0b013e3181c81b74](#)]
- 23 **Morales-Oyarvide V**, Mino-Kenudson M, Ferrone CR, Gonzalez-Gonzalez LA, Warsaw AL, Lillemoie KD, Fernández-del Castillo C. Acute pancreatitis in intraductal papillary mucinous neoplasms: A common predictor of malignant intestinal subtype. *Surgery* 2015; **158**: 1219-1225 [PMID: [26077509](#) DOI: [10.1016/j.surg.2015.04.029](#)]
- 24 **Aso T**, Ohtsuka T, Ideno N, Kono H, Nagayoshi Y, Mori Y, Ohuchida K, Ueda J, Takahata S, Morimatsu K, Aishima S, Igarashi H, Ito T, Ishigami K, Mizumoto K, Tanaka M. Diagnostic significance of a dilated orifice of the duodenal papilla in intraductal papillary mucinous neoplasm of the pancreas. *Gastrointest Endosc* 2012; **76**: 313-320 [PMID: [22658387](#) DOI: [10.1016/j.gie.2012.03.682](#)]
- 25 **Adsay NV**, Merati K, Basturk O, Iacobuzio-Donahue C, Levi E, Cheng JD, Sarkar FH, Hruban RH, Klimstra DS. Pathologically and biologically distinct types of epithelium in intraductal papillary mucinous neoplasms: delineation of an "intestinal" pathway of carcinogenesis in the pancreas. *Am J Surg Pathol* 2004; **28**: 839-848 [PMID: [15223952](#) DOI: [10.1097/0000478-200407000-00001](#)]
- 26 **Adsay NV**, Merati K, Andea A, Sarkar F, Hruban RH, Wilentz RE, Goggins M, Iacobuzio-Donahue C, Longnecker DS, Klimstra DS. The dichotomy in the preinvasive neoplasia to invasive carcinoma sequence in the pancreas: differential expression of MUC1 and MUC2 supports the existence of two separate pathways of carcinogenesis. *Mod Pathol* 2002; **15**: 1087-1095 [PMID: [12379756](#) DOI: [10.1097/01.mp.0000028647.98725.8b](#)]
- 27 **Hata T**, Sakata N, Okada T, Aoki T, Motoi F, Katayose Y, Egawa S, Unno M. Dilated papilla with mucin extrusion is a potential predictor of acute pancreatitis associated with intraductal papillary mucinous neoplasms of pancreas. *Pancreatol* 2013; **13**: 615-620 [PMID: [24280579](#) DOI: [10.1016/j.pan.2013.09.003](#)]
- 28 **Vege SS**, Ziring B, Jain R, Moayyedi P; Clinical Guidelines Committee; American Gastroenterology Association. American gastroenterological association institute guideline on the diagnosis and management of asymptomatic neoplastic pancreatic cysts. *Gastroenterology* 2015; **148**: 819-22; quiz:12 [PMID: [25805375](#) DOI: [10.1053/j.gastro.2015.01.015](#)]
- 29 **Tanaka M**, Fernández-Del Castillo C, Kamisawa T, Jang JY, Levy P, Ohtsuka T, Salvia R, Shimizu Y, Tada M, Wolfgang CL. Revisions of international consensus Fukuoka guidelines for the management of IPMN of the pancreas. *Pancreatol* 2017; **17**: 738-753 [PMID: [28735806](#) DOI: [10.1016/j.pan.2017.07.007](#)]
- 30 **European Study Group on Cystic Tumours of the Pancreas**. European evidence-based guidelines on pancreatic cystic neoplasms. *Gut* 2018; **67**: 789-804 [PMID: [29574408](#) DOI: [10.1136/gutjnl-2018-316027](#)]
- 31 **Elta GH**, Enestvedt BK, Sauer BG, Lennon AM. ACG Clinical Guideline: Diagnosis and Management of Pancreatic Cysts. *Am J Gastroenterol* 2018; **113**: 464-479 [PMID: [29485131](#) DOI: [10.1038/ajg.2018.14](#)]
- 32 **Kirkegård J**, Cronin-Fenton D, Heide-Jørgensen U, Mortensen FV. Acute Pancreatitis and Pancreatic Cancer Risk: A Nationwide Matched-Cohort Study in Denmark. *Gastroenterology* 2018; **154**: 1729-1736 [PMID: [29432727](#) DOI: [10.1053/j.gastro.2018.02.011](#)]
- 33 **Moore JV**, Tom S, Scoggins CR, Philips P, Egger ME, Martin RCG 2nd. Exocrine Pancreatic Insufficiency After Pancreatectomy for Malignancy: Systematic Review and Optimal Management Recommendations. *J Gastrointest Surg* 2021 [PMID: [33483914](#) DOI: [10.1007/s11605-020-04883-1](#)]
- 34 **Bernardoni L**, Crinò SF, De Conti G, Conti Bellocchi MC, De Pretis N, Amodio A, Frulloni L, Gabbriellini A. Preliminary experience with pancreatic sphincterotomy as treatment for intraductal papillary mucinous neoplasm-associated recurrent pancreatitis. *Endosc Int Open* 2017; **5**: E1144-E1150 [PMID: [29124124](#) DOI: [10.1055/s-0043-119753](#)]



Published by **Baishideng Publishing Group Inc**
7041 Koll Center Parkway, Suite 160, Pleasanton, CA 94566, USA
Telephone: +1-925-3991568
E-mail: bpgoffice@wjgnet.com
Help Desk: <https://www.f6publishing.com/helpdesk>
<https://www.wjgnet.com>

