

Endoscopic Management of Pain due to Chronic Pancreatitis



Arjun Kundra, MD^a, Daniel S. Strand, MD^b,
Vanessa M. Shami, MD^{c,*}

KEYWORDS

- Chronic pancreatitis • Pancreatic duct stones • Pancreatic duct obstruction
- Extracorporeal shockwave lithotripsy • ESWL • Celiac plexus block • Pain

KEY POINTS

- Pain secondary to chronic pancreatitis is a poorly understood and complex phenomenon.
- Treatments such as pancreatic duct decompression secondary to strictures, stones, or inflammatory and neoplastic processes are the mainstay of endoscopic therapy.
- For continued pain despite endoscopic treatment, endoscopic ultrasound -guided celiac block may be entertained; however, data are not robust on its effectiveness.

THE CLINICAL PROBLEM OF PAIN IN CHRONIC PANCREATITIS

Abdominal pain secondary to chronic pancreatitis (CP) is a vexing problem that results in a significant decrease in quality of life (QOL)¹ for patients and high costs to health care systems.² Classically, pain of pancreatic origin is described as episodic and localized to the mid-epigastrium with radiation to the back. While this description of pain is highly consistent in patients with acute pancreatitis, it does not conform particularly well to the variable presentations of pain in patients with CP.^{3,4}

Historically, pain in CP was siloed into 2 discrete patterns (Type A and Type B) based upon the natural history observed in the cohort study by *Ammann and colleagues*.⁵ Type A pain was described as *episodic* in nature, typically less than 2 weeks in duration, with symptom-free intervals between each episode. Type B pain, on the other hand, was defined by *persistent and daily pain*, which could also be accompanied by exacerbation(s). The North American Pancreatitis II (NAPS2) study group later demonstrated that those individuals with *persistent pain (Type B)* were also more likely

^a Department of Gastroenterology and Hepatology, University of Virginia, Charlottesville, VA, USA; ^b Department of Gastroenterology, University of Virginia, Charlottesville, VA, USA;

^c Department of Medicine, University of Virginia, Charlottesville, VA, USA

* Corresponding author. Digestive Health Center, University of Virginia Health, Box 800701, Charlottesville, VA 22908.

E-mail address: vms4e@uvahealth.org

to experience adverse health outcomes such as reduced QOL, disability, repetitive hospital admissions, and/or long-term opioid-use.⁶ Complicating matters, pain is not ubiquitous in CP, as previously believed. Some patients, for reasons that are not entirely transparent, have absolutely no symptoms despite a radiographic diagnosis of CP.⁷ This broad variability in clinical presentation underscores the complex milieu of pain in CP.²

Current expert consensus regarding pain in CP holds that it is extremely unreliable to objectively assess by the degree of end-organ pathology alone.^{2,8} Pain is fundamentally a complex experience, characterized by sensory input subject to interpretation through myriad individualized factors.^{2,6,9} Indeed, the subset of patients who experience severe pain due to altered nociception in CP may be uniquely susceptible in ways that were unappreciated in the past.⁹ For example, a recent observational study suggests that patients with persistent pain from CP have a distinctly different profile of circulating chemokines and cytokines than those who do not.¹⁰ Additionally, testing of patients from the NAPS2 cohort demonstrates a clear association of genetic loci for major depression in the fraction of patients who experience constant-severe pain from CP.^{9,11} Novel differences such as these serve to underscore the complex interplay of central nervous system pathways, genetic predisposition, and biochemical and psychological cofactors that contribute to pain in patients with CP. None of these are intuitively accessible to the practicing endoscopist as a target for pancreatic endotherapy. This understanding is the basis for the growing notion that reflexive endoscopy for pain in CP is no longer broadly recommended but should be considered thoughtfully in the context of each patient with CP.¹²

Local mechanisms can also influence the development of pain in CP, and these factors are often felt to be more amenable to direct intervention.¹³ Examples of these may include the development of local inflammation due to a discernible duct injury (ie, a duct leak), pancreatic ductal hypertension due to stricture and/or calculus, or the development of obstruction due to an inflammatory mass (eg, groove or para duodenal pancreatitis). Prior articles have addressed, in detail, the evidence regarding managing many of these specific structural complications of pancreatitis. Pain, which is refractory to conservative measures, is the most common reason why patients with CP are hospitalized, or are referred for surgery or endoscopic intervention.²

Endoscopic therapy for CP has mainly focused on decompression of pancreatic duct (PD) obstruction and splanchnic neural blockade targeting ganglia that innervate abdominal organs such as the pancreas. This section focuses on endoscopic pain management in patients with CP.

PANCREATIC DUCT OBSTRUCTION

Of the reasons for intervention typically cited by the endoscopist, pain due to pancreatic ductal hypertension is by far the most common.¹⁴ Pancreatic duct obstruction can occur due to the progressive formation of calculi, often in the setting of fibroinflammatory strictures within the outflow tract of pancreatic secretion. Pain in this setting has been frequently attributed to increased pancreatic duct and parenchymal pressure or, possibly, local oxidative stress and ischemia. Pain due to PD obstruction is frequently characterized as *colicky* in nature and often *post-prandial*.^{2,11} Despite the PD hypertension hypothesis, the results of studies designed to assess the correlation between PD pressure and symptoms have been mixed. Not all patients with elevated pancreatic duct pressures experience pain, and objectively measurable reductions in duct pressures do not reliably improve symptoms.^{15,16}

Despite the lack of support for the “pressure” etiopathology, there is evidence from the NAPS2 cohort (and elsewhere) that patients with abdominal pain do benefit from endoscopic intervention in CP.¹⁷ Response rates to pancreatic intervention, typically endoscopic placement of a pancreatic stent in retrospective cohorts are highly variable and depend considerably upon context and design. Results range from no statistical benefit to significant relief of pain in 85% of included patients.^{17–19} Nearly all of the existing data are derived from observational, retrospective, and heterogeneous studies. As such, our understanding of the expected results of pancreatic endotherapy is subject to considerable bias and thus should be interpreted cautiously. Controlled, randomized data are rare, and where studies do exist, they are far from definitive.²⁰

Patient selection is also essential when offering endoscopic therapy to those with CP, and the presence of complicating variables (such as ongoing alcohol and cigarette use) makes any accurate prediction of benefit extremely challenging.¹³ Perhaps in recognition of the overall lack of high-quality data in this milieu, general guidance regarding the role of endoscopic intervention in CP is available from multiple societies.^{12–14} Specific intervention(s) performed by gastrointestinal endoscopists may include endoscopic retrograde pancreatography (ERCP)-directed relief of obstruction, remodeling of PD stricture(s), and elimination of stones. Endoscopic ultrasound (EUS) is typically employed to deliver splanchnic nociceptive blockade via the celiac plexus or ganglion.^{12,14}

Preprocedural Planning

Before undertaking any endoscopic therapy, cross-sectional imaging is paramount to determine ductal diameter, level of obstruction, presence, size, and number of calculi and concomitant strictures, presence of parenchymal atrophy or extensive parenchymal calcifications, and findings suggestive of an underlying malignancy. Computed tomography (CT) and MRI are complementary. MRI with secretin stimulation provides the best assessment of the PD and is preferable in the setting of a disconnected main PD.

PANCREATIC SPHINCTEROTOMY

PD orifice sphincterotomy is a commonly performed endoscopic intervention. It is typically done with the intent to relieve papillary sphincter stenosis or allow for improved duct access for endoscopic instruments. PD sphincterotomy can also facilitate passage of pancreatoscopes (10Fr caliber) and luminal delivery of main duct calculi (before or after fragmentation) (**Fig. 1**). Typically, PD sphincterotomy is an adjunct maneuver, though this can be a primary therapy when sphincter sclerosis is felt to be the driver of patient symptoms in the absence of upstream ductal obstruction in the setting of chronic pancreatitis.¹⁴ In patients with pancreas divisum, minor papilla sphincterotomy may be considered to reduce episodic attacks of acute pancreatitis or to provide pain relief.¹² It should be noted that patients who develop pancreatitis in the setting of divisum rarely do so in isolation. Nearly half of such patients will have an identifiable secondary cause, such as a cystic fibrosis transmembrane conductance regulator mutation, which can make it challenging to determine if endoscopic therapy will be beneficial.²¹

PANCREATIC DUCT STENTING

Main pancreatic duct (MPD) stent placement is one of the most performed endoscopic procedures to affect pancreatic duct decompression (**Fig. 2**). Some endoscopists place a main pancreatic stent across any obstruction to assess pain relief before

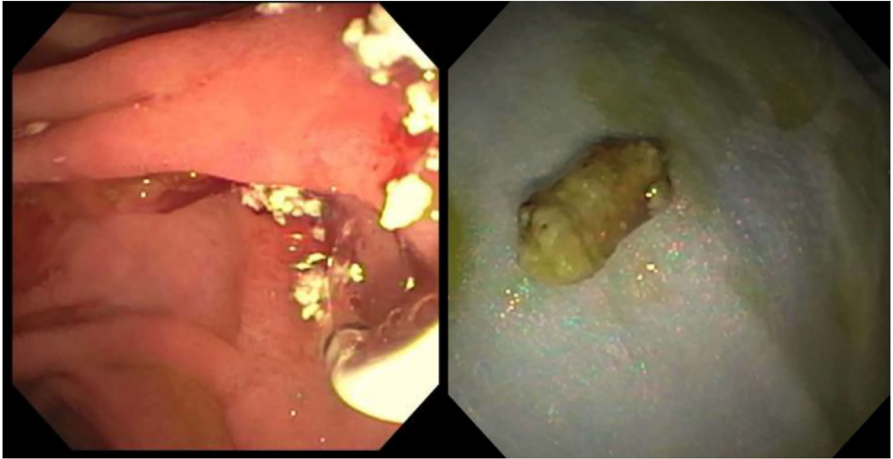


Fig. 1. Pancreatic duct (PD) calculi. The white appearance is due to calcification, which is common with PDstones.

embarking on attempts to definitively resolve ductal pathology, which often requires multiple, sometimes labor-intensive (eg, Pancreatoscopy with intraductal lithotripsy) endoscopic procedures.

While there is little doubt that endoscopic ductal therapy with balloon dilation and placement of 1 or more stents can mitigate the radiographic appearance of a

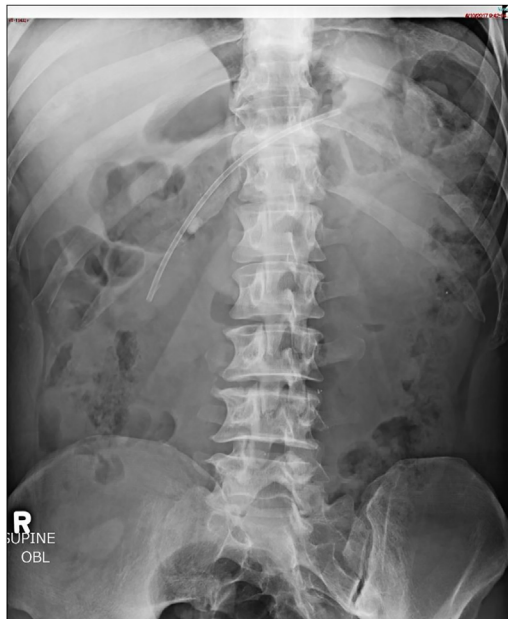

Fig. 2. Long plastic PD stent placed into the tail of the pancreas, with large, calcific pancreatic duct stone visible at the level of the pancreatic neck.

pancreatic duct stricture, the efficacy of this intervention for pain remains subject to considerable debate.¹² As stated previously, the causal relationship between pancreatic ductal hypertension and pain is unclear,¹⁵ as is the fundamental expectation that relief of pressure will ameliorate pain.¹⁶

The largest retrospective, multicenter cohort study included over 1000 patients with CP who underwent MPD stent placement for a dominant main pancreatic duct stricture. Of these, 57% of the patients demonstrated significant pain relief at long-term follow-up (mean of 4.9 years). An additional 19% of those included had significant symptom improvement but also required ongoing endoscopic intervention.²² Modern cohort studies, which provide the same level of evidence for pain relief, typically demonstrate similar findings. One such experience, by *Tringali and colleagues*, reported durable pain relief in 75% of the treated patients following stent removal for up to approximately 180 months after stricture remediation.²³

Current multi-society (International Association of Pancreatology [IAP]/American Pancreatic Association [APA]/Japan Pancreas Society [JPS]/European Pancreas Club [EPC]) guidance argues that up to 60% of appropriate patients who are selected for MPD stent placement can expect to experience both short-term (<2 years) and long-term (>5 years) symptom relief.²⁴ These authors acknowledge that the data upon which this recommendation is based are heterogeneous, low quality (by GRADE methodology), and prototypically observational.

Despite these limitations, it was recommended by Drewes and colleagues to target patients early in their disease course and to consider prioritizing patients with a single dominant stricture or stone in the pancreatic head. Data from NAPS2 also support this recommendation, as patients with a shorter disease duration appear more likely to respond to endoscopic therapy (4 vs 40 months; $P = .017$).¹⁷ Despite observational data, durable relief of symptoms remains a significant problem,²⁰ particularly because the natural history of pain in chronic pancreatitis appears independent of disease duration³ for reasons discussed in the preamble. While endoscopic decompression is unquestionably useful, in the authors' estimation, the perfect positioning of ERCP-directed stent placement in patients with CP is not well defined. The decision to proceed with ERCP, especially when the endpoint is pain relief, should be thoughtfully considered and transparently discussed with prospective patients.

When endoscopic intervention is selected, plastic PD stents are typically placed to bridge a stricture in the MPD. This can be done as singular therapy or following endoscopic balloon dilation to a diameter appropriate for the caliber of the upstream pancreatic duct. These plastic stents are typically exchanged at 3-month intervals but may be left for a longer duration if larger (ie, 10 French) in caliber.¹⁴ Overall treatment duration typically exceeds 12 months, as shorter treatment periods are associated with inferior outcomes.^{14,19} The preferred strategy is to place and, on exchanges, either upsize or add multiple plastic stents in parallel to allow for improved caliber of the strictured ductal segment during remodeling.¹²

To reduce the number of ERCP procedures required to achieve durable stricture resolution, fully covered self-expanding metal stents (fcSEMS) have been used for this indication. Several individual studies²⁵ and a recent systemic review and meta-analysis²⁶ have examined this practice. Both plastic stents and FcSEMS are generally observed to resolve MPD strictures in most patients (approximately 90%) and are associated with similar rates of pain relief (88% vs 89%).²⁶ Importantly, however, significantly more AEs were observed in patients who underwent treatment with fcSEMS compared to plastic stents (39% vs 14%).²⁶ Due to the preferable safety profile, this expert group of authors favors upsizing or placing coaxial parallel plastic stents to treat MPD strictures. This practice is in keeping with recommendations

proffered in the American Gastroenterology Association Clinical Practice Update by *Strand and colleagues*.¹²

It should also be noted that MPD stent placement is not an entirely benign affair, and AEs have been reported in up to 10% to 20% of patients. Most commonly, this is due to stent migration or the development of a stricture at the proximal (upstream) end of an indwelling stent.¹⁷ Given these observations, the authors' typical practice favors the placement of longer MPD stents that terminate in the tail of the pancreas. This decision is largely agnostic of the location of the stricture to be treated (head or body), but rather to avoid AEs, as the authors' anecdotal experience suggests that stents that terminate at the site of directional transition (ie, the genu) within the PD are the most problematic.

PANCREATIC DUCT STONE MANAGEMENT

Pancreatic duct calculi can be a significant challenge to manage, as they are a different composition than biliary stones. Specifically, PD stones are often composed of a small inner nidus of sulfur and chlorine with successive outer shell layers of calcium carbonate.²⁷ This chemical composition results in a high-density, rigid stone that can prove refractory to standard ERCP maneuvers. Additionally, they typically form *in situ* and may result in cast-like duct obstruction that can impede the progress of (or break) endoscopic instruments such as dilation and extraction balloons.²⁸ Obstructing stones that are small (<4-5 mm) and located within the head and neck of the PD are the most amenable to endoscopic therapy.¹² Larger stones (>5 mm) may require lithotripsy, which can be performed via ERCP-directed techniques or extracorporeal shock wave lithotripsy (ESWL).²⁹ It should also be noted that the presence of a stone is not a *sine qua non* for intervention. Many patients possess *extensive* calcific chronic pancreatitis in the absence of clinical symptoms, including pain.⁷ In this setting, preventing future complications (such as the development of diabetes) is often cited as the rationale for treating asymptomatic stones, though data supporting such practice remain limited.³⁰ Once the decision is made to pursue intervention for a PD stone, management is often predicated on the location and size of the target.

Management of small stones (<4 mm) can usually be accomplished by conventional ERCP techniques. In most cases, fluoroscopically directed extraction using a standard retrieval balloon or basket after endoscopic pancreatic sphincterotomy will suffice. Sometimes, balloon dilation of the papillary orifice or a focal stricture downstream to the stone may be necessary as an adjunct maneuver.³¹ If a stone cannot be removed in a single session, endoscopic stent across the obstruction is typically performed.³²

Larger (> 5 mm) or impacted stones often require ESWL (**Figs. 3–5**). ESWL is the oldest and perhaps most widely studied intervention for refractory PD calculi. Although the availability of ESWL in the United States is limited, it remains a highly effective intervention for fragmentation of PD stones.^{14,29} This can be performed alone or in combination with subsequent ERCs to retrieve fragments. A randomized controlled trial of 55 patients by *Dumonceau and colleagues* suggested that ESWL alone may be comparable to a combination of ESWL and ERCP to relieve pancreatitis-related pain.²⁹ Additional observational studies³³ also favor ESWL as an effective sole intervention for pain. Accordingly, multiple guidelines include ESWL as an important modality in the schema for PD stone management.^{14,24} Relying entirely on ESWL, however, can be problematic. A Japanese study by *Tadenuma and colleagues* observed that in patients who have incomplete stone removal at the time of

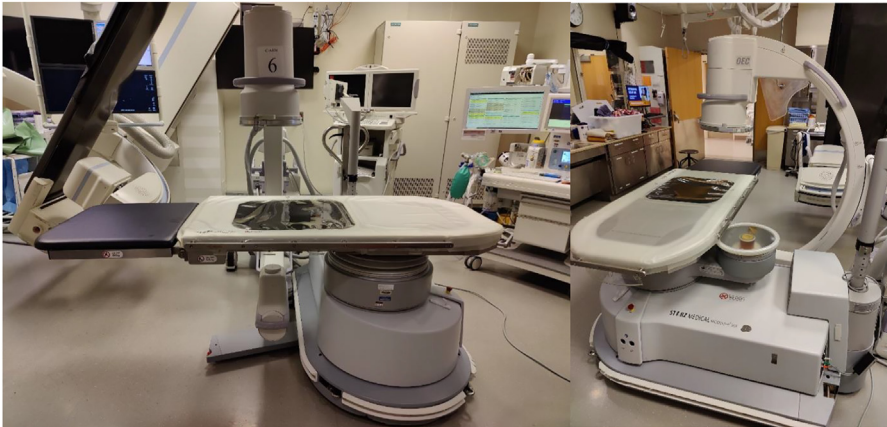

Fig. 3. ESWL setup, showing C-arm for targeting and delivering shocks, to be targeted within the field of the waterbed section.

initial therapy, symptoms of abdominal pain following ESWL relapse much more commonly.³⁴ Thus, complete clearance of stones from the pancreatic duct by ERCP should be considered in patients who have residual stones following ESWL.¹⁴ The ideal method and timeline to ensure spontaneous passage of pancreatic duct residua prior to embarking on a subsequent ERCP is not well established.³⁴

ERCP with single-operator pancreatoscopy-directed lithotripsy is an alternative to ESWL. Specific treatment modalities delivered by this method include electrohydraulic lithotripsy (EHL) and laser lithotripsy (LL). Intraductal therapy is subject to significant endoscopist enthusiasm, given the limited availability of ESWL in the United States and the prospect of PD clearance in a “single session.” Retrospective data on these techniques, typically performed at expert tertiary care centers reveal a high degree of technical success comparable to ESWL.^{28,33,35–37} These data further support the notion that pancreatoscopy-directed lithotripsy is safe and likely effective, though it is often technically challenging, and thus, generalizability beyond expert centers may be limited. It should also be noted that some retrospective studies of intraductal therapy combine patients treated with EHL and LL into a single cohort

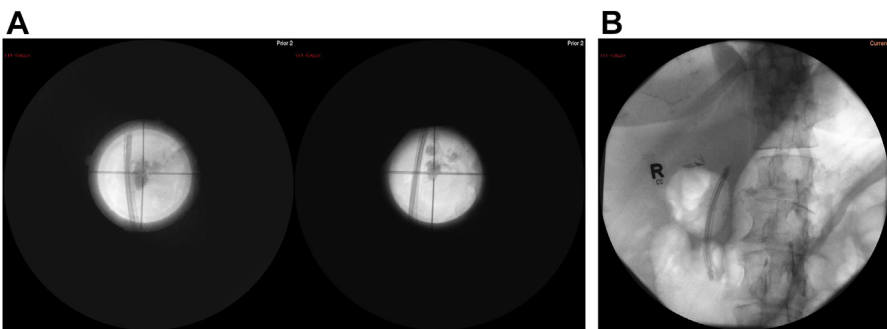


Fig. 4. (A) Stone targeting and progression of PD stone fracturing with extracorporeal shock wave lithotripsy shock deliverance in a patient. (B) Complete clearance of obstructing PD stone in the same patient.

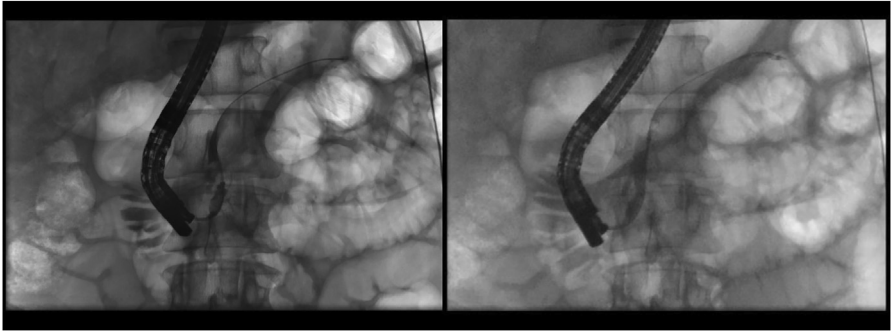


Fig. 5. Resolution of pancreatic duct patency with clearance of large pancreatic duct stone at the level of the neck of the pancreas.

despite these treatments having different operating variables.³⁸ Additionally, the cost burden of intraductal treatment compared to ESWL is not well established, though it may favor the former. At present, there are no high-quality, randomized data that provide the means to make a definitive choice between these 2 modalities for PD stone destruction—though this may be forthcoming.³⁹

CELIAC PLEXUS BLOCK

The celiac plexus is a network of 1 to 5 ganglia that relays preganglionic sympathetic and parasympathetic efferent fibers and visceral sensory afferent fibers to the upper abdominal viscera, including the pancreas. It is in the vicinity of the celiac artery at its takeoff from the aorta. The celiac plexus can be identified by endoscopic ultrasound. First, the aorta is identified in the thorax and followed distally to its first major branch below the diaphragm, the celiac artery. The ganglia surround the celiac artery take-off and can often be individually visualized (**Fig. 6**).

CELIAC PLEXUS BLOCK/TECHNIQUE

In patients with CP, celiac plexus block (CPB) has been utilized to decrease pain with hopes of improving QOL and reducing narcotic use. The typical technique involves

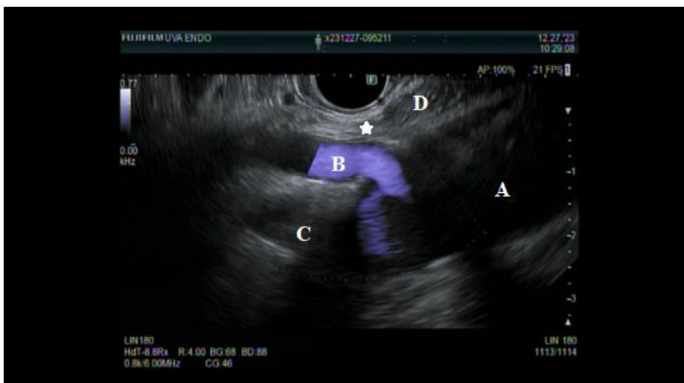


Fig. 6. Endosonographic image taken with a linear echoendoscope demonstrating the aorta (A), celiac artery takeoff, (B), superior mesenteric artery takeoff (C), diaphragm (D) and expected location for the celiac ganglion to target for injection (*star*), highlighted with eFlow.

injecting bupivacaine and triamcinolone into the celiac axis.¹³ Contraindications include patients with esophageal strictures, altered anatomy precluding access to the proximal stomach, coagulopathy, or thrombocytopenia (platelet count <50,000/mm³).

Patients are given intravenous volume expansion (Lactated Ringer's or normal saline) before and during the procedure to minimize hypotension due to dilation of the splanchnic vasculature as a result of the block. Once the patient is sedated, the celiac axis is identified. The needle is inserted into the region of the celiac axis; aspiration is performed for several seconds to ensure that it is not in a vascular structure. A combination of 20 mL of 0.25% bupivacaine and 80 mg triamcinolone is injected into the plexus adjacent to the celiac artery takeoff. After completion of the procedure, patients are observed for hypotension for at least 1 hour.

Unilateral Versus Bilateral Injection

Since the plexus surrounds the celiac artery, instead of injecting the bupivacaine and triamcinolone on 1 side of the takeoff, known as the unilateral approach, some advocate for injection of half of the injectant on both sides of the celiac artery (bilateral approach). No robust data favor either the unilateral or bilateral approach. When reviewing the sparse data for CPB, in a prospective trial of 160 patients, bilateral CPB was found to be more effective.⁴⁰ Pain relief was 70.4% on day 7 in bilateral versus 45.9% in unilateral arm. However, another prospective randomized trial showed no difference in duration or time to onset of pain relief.⁴¹

Indirect Versus Direct Injection

Direct targeting of the ganglia has also been reported. However, the data are sparse. In a study, celiac plexus block (CPB) and celiac plexus neurolysis (CPN) were performed for CP and pancreatic cancer. For CP, four-fifth (80%) who received alcohol injection reported pain relief versus five-thirteenth (38%) receiving corticosteroid injection.⁴² In a recent prospective study of patients with unresectable pancreatic cancer, those who underwent celiac ganglion neurolysis (CGN) had reduced survival time without improving pain, QOL, or AEs versus CPN. The patients who experienced increased post-procedural pain appeared to have improved results.⁴³ Whether these results are generalizable to patients with CP undergoing CPB is unclear.

CELIAC PLEXUS BLOCK/DATA

Several retrospective and prospective studies have demonstrated the technical success of EUS-CPB is as high as 95%.^{40,41,44-48} However, its efficacy in pain relief is suboptimal, and 2 meta-analyses demonstrate disappointing response rates.^{44,48} The first study, authored by *Kaufman and colleagues*.⁴⁴, included 6 trials with 221 patients who underwent EUS-CPB for CP. Pain relief was only reported in 51.46% of the patients included. The second meta-analysis, by *Puli and colleagues*.⁴⁸, included 9 studies with 376 patients. The response rate was higher, with 59% reporting symptom improvement; however, the degree of reported pain relief was modest, and most patients included in the analysis continued to require analgesic medications. Such meta-analyses are subject to considerable methodologic limitations, and these 2 examples notably included abstract-level data and no higher quality randomized trials.

CPB is even more disappointing when stringent criteria to define pain relief are applied. In a study by *Stevens and colleagues*, 40 patients with abdominal pain secondary to CP were randomized to receive CPB with either triamcinolone and bupivacaine or bupivacaine alone (control group).⁴⁹ Following CPB, the patients were

assessed at 30 days with a primary endpoint defined as a decrease in the pain disability index of 10 or more. Although there was no difference between groups, the results of CPB were uniformly dismal: Only 14.3% of patients who received triamcinolone met the primary endpoint for pain relief versus 15.8% for controls.⁴⁹

Conversely, a randomized trial by *Gress and colleagues*⁴⁷ compared EUS to CT-guided CPB for pain in patients with CP. In this study, approximately (5/10) 50% of the patients in the EUS group experienced significant short-term pain reduction. Continued benefit was noted in approximately 40% of the responders at 8 weeks and 30% at 24 weeks. The EUS-directed approach was superior to CT-CPB, where only one-fourth (25%) experienced a significant reduction in abdominal pain.⁴⁷ The same authors later published a prospective, single-center experience of EUS-CPB on 90 patients with CP.⁴⁷ In this series, 55% (50/90) of the patients reported significant short-term improvement in objective pain scores. This benefit appeared transient, however, as only 26% of the responders had a persistent benefit by 12 weeks, and 10% at 24 weeks.⁴⁷

While data on the efficacy of EUS-CPB on pain relief in patients with CP are generally underwhelming, there are data to support the role of serial CPB in patients who demonstrate prior benefit.^{13,45} Enthusiasm for this approach should be tempered, however, as the duration of response remains limited (approximately 10 weeks), and there is no apparent benefit associated with repeated injections for those who do not respond initially.

Current expert and societal recommendations regarding the utility of CPB in CP are variable and sometimes appear conflicting.^{12,13} The observed discrepancy is principally due to differences in the interpretation of existing low-quality evidence filtered through the perceived risk of CPB against alternative treatments. The American College of gastroenterology (ACG) recommends “considering” celiac plexus block for CP-related pain,¹³ whereas the recent AGA Clinical Practice Update counsels that “CPB should not be routinely performed” for this indication.¹² While seemingly at odds, when read closely, these recommendations are, in fact, very similar. The decision to proceed with CPB in selected patients with debilitating pain in whom other therapeutic measures have failed can be considered on a case-by-case basis, but only after discussion of the uncertain benefit of this intervention and its procedural risks.¹²

CELIAC PLEXUS BLOCK/ADVERSE EVENTS

AEs are observed in up to 40% of patients, including diarrhea and hypotension, which are the most common.^{42,46,47,50} Diarrhea is related to the blockade of sympathetic innervation to the abdominal viscera and results from unopposed parasympathetic stimulation. Hypotension occurs due to the dilation of the splanchnic vasculature and can be treated with intravenous volume expansion.

Fortunately, significant AE from CPB are rare and occur in <1% of patients. Reported AEs include abscess formation, bleeding, and intravascular injection. Reports of paralysis, which are extremely rare, have been limited to alcohol-based celiac neurolysis.^{45,51–55}

LIMITATIONS OF ENDOSCOPIC THERAPY AND THE CASE FOR SURGERY

Newer guidelines published in 2021 on the management of CP also suggest that long-term repeated endoscopic treatment beyond 2 to 3 years should not be used to treat pain in patients with chronic pancreatitis. However, the strength of this recommendation was weak.⁵⁶ This is likely due to the nature of the pain becoming more neuropathic

as the course of the disease progresses. In cases where pain is exceptionally challenging to manage, surgery can be considered. Although the superiority of surgery in managing CP pain has been demonstrated in the Early Surgery versus optimal Current step-up practice for chronic Pancreatitis (ESCAPE) randomized controlled trial,²⁰ endoscopic therapies are still considered first-line as they are less invasive and have low AE rates. Surgical treatment options include distal pancreatectomy, Whipple's operation to achieve partial resection, and Puestow procedure for improved drainage. Additionally, there are combined procedures such as Frey's, Berne, and Beger operations for resection and improved drainage.⁵⁷

CLINICAL CARE POINTS

- Identifying the characteristics of pancreatic pain, and structural causes such as stones or strictures is instrumental in deciding whether endoscopic therapy is indicated and which type of therapy would likely be most effective.
- Main pancreatic duct stent placement for management of pancreatic duct strictures in carefully selected patients can provide both short and long term pain relief in >50% of patients. Success is more likely if patients are targeted early in their disease course.
- Fully covered self-expanding metal stents carry a higher adverse event rate for main pancreatic duct strictures, and as such coaxial parallel plastic stents is favored.
- Extracorporeal shock wave lithotripsy (ESWL) is useful in management of larger pancreatic stones and additional ERCP for stone clearance after ESWL can be considered in patients who have residual stones following ERCP.
- Intraductal therapy for pancreatic duct stones with electrohydraulic lithotripsy is a reasonable alternative to ESWL Pitfalls:.
- Offering endoscopic therapy for duct decompression without clear evidence of obstruction may result in unnecessary procedures and possible complications.
- The ideal method and timeline to ensure spontaneous passage of pancreatic duct residua after ESWL, prior to embarking on a subsequent ERCP is not well established.

SUMMARY

Pain from CP is multifactorial and not fully understood. Treatments such as pancreatic duct decompression secondary to strictures, stones, or inflammatory and neoplastic processes are the mainstay of endoscopic therapy. For continued pain despite endoscopic treatment, EUS-guided celiac block may be entertained; however, data are not robust on its effectiveness.

DISCLOSURE

A. Kundra and D.S. Strand has nothing to disclose. V.M. Shami: Consultant for Cook Medical, Olympus America, and Boston Scientific.

REFERENCES

1. Machicado JD, Amann ST, Anderson MA, et al. Quality of Life in Chronic Pancreatitis is Determined by Constant Pain, Disability/Unemployment, Current Smoking, and Associated Co-Morbidities. *Am J Gastroenterol* 2017;112:633–42. Available at: <https://pubmed.ncbi.nlm.nih.gov/28244497/>. [Accessed 27 December 2023].

2. Anderson MA, Akshintala V, Albers KM, et al. Mechanism, Assessment and Management of Pain in Chronic Pancreatitis: Recommendations of a Multidisciplinary Study Group. *Pancreatology* 2016;16:83. Available at: <http://pmc/articles/PMC4761301/>. [Accessed 27 December 2023].
3. Vipperla K, Kanakis A, Slivka A, et al. Natural course of pain in chronic pancreatitis is independent of disease duration. *Pancreatology* 2021;21:649–57. Available at: <https://pubmed.ncbi.nlm.nih.gov/33674197/>. [Accessed 27 December 2023].
4. Wilcox CM, Yadav D, Ye T, et al. Chronic pancreatitis pain pattern and severity are independent of abdominal imaging findings. *Clin Gastroenterol Hepatol* 2015;13: 552–60. Available at: <https://pubmed.ncbi.nlm.nih.gov/25424572/>. [Accessed 27 December 2023].
5. Ammann RW, Muellhaupt B, Akovbiantz A, et al. The natural history of pain in alcoholic chronic pancreatitis. *Gastroenterology* 1999;116:1132–40. Available at: <https://pubmed.ncbi.nlm.nih.gov/10220505/>. [Accessed 27 December 2023].
6. Mullady DK, Yadav D, Amann ST, et al. Type of pain, pain-associated complications, quality of life, disability and resource utilisation in chronic pancreatitis: a prospective cohort study. *Gut* 2011;60:77–84. Available at: <https://pubmed.ncbi.nlm.nih.gov/21148579/>. [Accessed 27 December 2023].
7. Ahmed A, Shah I, Bocchino R, et al. Natural history, clinical characteristics, outcomes, and long-term follow-up of pain-free chronic pancreatitis. *Gastroenterol Rep (Oxf)* 2023;11. Available at: <https://pubmed.ncbi.nlm.nih.gov/37153703/>. [Accessed 27 December 2023].
8. Pain HM. Pain terms: a list with definitions and notes on usage. Recommended by the IASP Subcommittee on Taxonomy. *cir.nii.ac.jp*. 1979 undefined. Available at: <https://cir.nii.ac.jp/crid/1572543024166034688>. [Accessed 27 December 2023].
9. Dunbar E, Greer PJ, Melhem N, et al. Constant-severe pain in chronic pancreatitis is associated with genetic loci for major depression in the NAPS2 cohort. *J Gastroenterol* 2020;55:1000–9. Available at: <https://pubmed.ncbi.nlm.nih.gov/32681239/>. [Accessed 27 December 2023].
10. Saloman JL, Tang G, Stello KM, et al. Serum biomarkers for chronic pancreatitis pain patterns. *Pancreatology* 2021;21:1411–8. Available at: <https://pubmed.ncbi.nlm.nih.gov/34602367/>. [Accessed 27 December 2023].
11. Dunbar EK, Saloman JL, Phillips AE, et al. Severe Pain in Chronic Pancreatitis Patients: Considering Mental Health and Associated Genetic Factors. *J Pain Res* 2021;14:773–84. Available at: <https://pubmed.ncbi.nlm.nih.gov/33762844/>. [Accessed 27 December 2023].
12. Strand DS, Law RJ, Yang D, et al. AGA clinical practice update on the endoscopic approach to recurrent acute and chronic pancreatitis: expert review. *Gastroenterology*; 2022. p. 163. Available at: <https://pubmed.ncbi.nlm.nih.gov/36008176/>. [Accessed 27 December 2023].
13. Gardner TB, Adler DG, Forsmark CE, et al. ACG clinical guideline: chronic pancreatitis. *Am J Gastroenterol* 2020;115:322–39. Available at: <https://pubmed.ncbi.nlm.nih.gov/32022720/>. [Accessed 27 December 2023].
14. Dumonceau JM, Delhaye M, Tringali A, et al. Endoscopic treatment of chronic pancreatitis: European Society of Gastrointestinal Endoscopy (ESGE) Guideline - Updated August 2018. *Endoscopy* 2019;51:179–93. Available at: <https://pubmed.ncbi.nlm.nih.gov/30654394/>. [Accessed 27 December 2023].
15. Novis BH, Bornman PC, Girdwood AW, et al. Endoscopic manometry of the pancreatic duct and sphincter zone in patients with chronic pancreatitis. *Dig*

- Dis Sci 1985;30:225–8. Available at: <https://pubmed.ncbi.nlm.nih.gov/3971834/>. [Accessed 27 December 2023].
16. Renou C, Grandval P, Ville E, et al. Endoscopic treatment of the main pancreatic duct: correlations among morphology, manometry, and clinical follow-up. *Int J Pancreatol* 2000;27:143–9. Available at: <https://pubmed.ncbi.nlm.nih.gov/10862513/>. [Accessed 27 December 2023].
 17. Clarke B, Slivka A, Tomizawa Y, et al. Endoscopic therapy is effective for patients with chronic pancreatitis. *Clin Gastroenterol Hepatol* 2012;10:795–802. Available at: <https://pubmed.ncbi.nlm.nih.gov/22245964/>. [Accessed 27 December 2023].
 18. Seza K, Yamaguchi T, Ishihara T, et al. A long-term controlled trial of endoscopic pancreatic stenting for treatment of main pancreatic duct stricture in chronic pancreatitis. *Hepato-Gastroenterology* 2011;58:2128–31. Available at: <https://pubmed.ncbi.nlm.nih.gov/22234084/>. [Accessed 27 December 2023].
 19. Eleftheriadis N, Dinu F, Delhaye M, et al. Long-term outcome after pancreatic stenting in severe chronic pancreatitis. *Endoscopy* 2005;37:223–30. Available at: <https://pubmed.ncbi.nlm.nih.gov/18556820/>. [Accessed 27 December 2023].
 20. Issa Y, Kempeneers MA, Bruno MJ, et al. Effect of Early Surgery vs Endoscopy-First Approach on Pain in Patients With Chronic Pancreatitis: The ESCAPE Randomized Clinical Trial. *JAMA* 2020;323:237–47. Available at: <https://pubmed.ncbi.nlm.nih.gov/31961419/>. [Accessed 27 December 2023].
 21. Bertin C, Pelletier AL, Vullierme MP, et al. Pancreas divisum is not a cause of pancreatitis by itself but acts as a partner of genetic mutations. *Am J Gastroenterol* 2012;107:311–7. Available at: <https://pubmed.ncbi.nlm.nih.gov/22158025/>. [Accessed 27 December 2023].
 22. Rösch T, Daniel S, Scholz M, et al. Endoscopic treatment of chronic pancreatitis: a multicenter study of 1000 patients with long-term follow-up. *Endoscopy* 2002; 34:765–71. Available at: <https://pubmed.ncbi.nlm.nih.gov/12244496/>. [Accessed 27 December 2023].
 23. Tringali A, Bove V, Vadalà Di Prampero SF, et al. Long-term follow-up after multiple plastic stenting for refractory pancreatic duct strictures in chronic pancreatitis. *Endoscopy* 2019;51:930–5.
 24. Drewes AM, Bouwense SAW, Campbell CM, et al. Guidelines for the understanding and management of pain in chronic pancreatitis. *Pancreatology* 2017;17: 720–31. Available at: <https://pubmed.ncbi.nlm.nih.gov/28734722/>. [Accessed 27 December 2023].
 25. Oh D, Lee JH, Song TJ, et al. Long-term outcomes of 6-mm diameter fully covered self-expandable metal stents in benign refractory pancreatic ductal stricture. *Dig Endosc* 2018;30:508–15. Available at: <https://pubmed.ncbi.nlm.nih.gov/29453786/>. [Accessed 27 December 2023].
 26. Sofi AA, Khan MA, Ahmad S, et al. Comparison of clinical outcomes of multiple plastic stents and covered metal stent in refractory pancreatic ductal strictures in chronic pancreatitis- a systematic review and meta-analysis. *Pancreatology* 2021;21:854–61. Available at: <https://pubmed.ncbi.nlm.nih.gov/33941467/>. [Accessed 27 December 2023].
 27. Jing ZP. Ultrastructure and elemental composition of pancreatic stones. *Zhonghua Wai Ke Za Zhi* 1990;28:421–3. Available at: <https://europepmc.org/article/MED/2269050>. [Accessed 27 December 2023].
 28. Han S, Shah RJ, Brauer BC, et al. A Comparison of Endoscopic Retrograde Pancreatography With or Without Pancreatostomy for Removal of Pancreatic Duct Stones. *Pancreas* 2019;48:690–7. Available at: <https://pubmed.ncbi.nlm.nih.gov/31091217/>. [Accessed 27 December 2023].

29. Dumonceau JM, Costamagna G, Tringali A, et al. Treatment for painful calcified chronic pancreatitis: extracorporeal shock wave lithotripsy versus endoscopic treatment: a randomised controlled trial. *Gut* 2007;56:545–52. Available at: <https://pubmed.ncbi.nlm.nih.gov/17047101/>. [Accessed 27 December 2023].
30. Talukdar R, Reddy DN, Tandan M, et al. Impact of ductal interventions on diabetes in patients with chronic pancreatitis. *J Gastroenterol Hepatol* 2021;36:1226–34. Available at: <https://pubmed.ncbi.nlm.nih.gov/33000865/>. [Accessed 27 December 2023].
31. Bansal R, Patil G, Puri R, et al. Endoscopic pancreatic balloon sphincteroplasty for difficult to treat pancreatic stones and strictures: experience in 80 patients. *Endosc Int Open* 2017;5:E1229–34. Available at: <https://pubmed.ncbi.nlm.nih.gov/29218314/>. [Accessed 27 December 2023].
32. Choi EK, McHenry L, Watkins JL, et al. Use of intravenous secretin during extracorporeal shock wave lithotripsy to facilitate endoscopic clearance of pancreatic duct stones. *Pancreatology* 2012;12:272–5. Available at: <https://pubmed.ncbi.nlm.nih.gov/22687384/>. [Accessed 27 December 2023].
33. Vaysse T, Boytchev I, Antoni G, et al. Efficacy and safety of extracorporeal shock wave lithotripsy for chronic pancreatitis. *Scand J Gastroenterol* 2016;51:1380–5. Available at: <https://pubmed.ncbi.nlm.nih.gov/27595309/>. [Accessed 27 December 2023].
34. Tadenuma H, Ishihara T, Yamaguchi T, et al. Long-term results of extracorporeal shockwave lithotripsy and endoscopic therapy for pancreatic stones. *Clin Gastroenterol Hepatol* 2005;3:1128–35. Available at: <https://pubmed.ncbi.nlm.nih.gov/16271345/>. [Accessed 27 December 2023].
35. McCarty TR, Sobani Z, Rustagi T. Per-oral pancreatoscopy with intraductal lithotripsy for difficult pancreatic duct stones: a systematic review and meta-analysis. *Endosc Int Open* 2020;8:E1460–70. Available at: <https://pubmed.ncbi.nlm.nih.gov/33043115/>. [Accessed 27 December 2023].
36. Wiel SE, Stassen PMC, Poley JW, et al. Pancreatoscopy-guided electrohydraulic lithotripsy for the treatment of obstructive pancreatic duct stones: a prospective consecutive case series. *Gastrointest Endosc* 2022;95:905–14.e2. Available at: <https://pubmed.ncbi.nlm.nih.gov/34906545/>. [Accessed 27 December 2023].
37. Bekkali NLH, Murray S, Johnson GJ, et al. Pancreatoscopy-Directed Electrohydraulic Lithotripsy for Pancreatic Ductal Stones in Painful Chronic Pancreatitis Using SpyGlass. *Pancreas* 2017;46:528–30. Available at: <https://pubmed.ncbi.nlm.nih.gov/28196019/>. [Accessed 27 December 2023].
38. Brewer Gutierrez OI, Rajjman I, Shah RJ, et al. Safety and efficacy of digital single-operator pancreatoscopy for obstructing pancreatic ductal stones. *Endosc Int Open* 2019;7:E896–903. Available at: <https://pubmed.ncbi.nlm.nih.gov/31281875/>. [Accessed 27 December 2023].
39. Olesen SS, Drewes AM, Gaud R, et al. Combined extracorporeal shock wave lithotripsy and endoscopic treatment for pain in chronic pancreatitis (SCHOKE trial): study protocol for a randomized, sham-controlled trial. *Trials* 2020;21. Available at: <https://pubmed.ncbi.nlm.nih.gov/32299454/>. [Accessed 27 December 2023].
40. Sahai AV, Lemelin V, Lam E, et al. Central vs. bilateral endoscopic ultrasound-guided celiac plexus block or neurolysis: a comparative study of short-term effectiveness. *Am J Gastroenterol* 2009;104:326–9. Available at: <https://pubmed.ncbi.nlm.nih.gov/19174816/>. [Accessed 27 December 2023].
41. LeBlanc JK, DeWitt J, Johnson C, et al. A prospective randomized trial of 1 versus 2 injections during EUS-guided celiac plexus block for chronic

- pancreatitis pain. *Gastrointest Endosc* 2009;69:835–42. Available at: <https://pubmed.ncbi.nlm.nih.gov/19136101/>. [Accessed 27 December 2023].
42. Levy MJ, Topazian MD, Wiersema MJ, et al. Initial evaluation of the efficacy and safety of endoscopic ultrasound-guided direct Ganglia neurolysis and block. *Am J Gastroenterol* 2008;103:98–103. Available at: <https://pubmed.ncbi.nlm.nih.gov/17970834/>. [Accessed 27 December 2023].
 43. Levy MJ, Gleeson FC, Topazian MD, et al. Combined Celiac Ganglia and Plexus Neurolysis Shortens Survival, Without Benefit, vs Plexus Neurolysis Alone. *Clin Gastroenterol Hepatol* 2019;17:728–38.e9. Available at: <https://pubmed.ncbi.nlm.nih.gov/30217513/>. [Accessed 27 December 2023].
 44. Kaufman M, Singh G, Das S, et al. Efficacy of endoscopic ultrasound-guided celiac plexus block and celiac plexus neurolysis for managing abdominal pain associated with chronic pancreatitis and pancreatic cancer. *J Clin Gastroenterol* 2010;44:127–34. Available at: <https://pubmed.ncbi.nlm.nih.gov/19826273/>. [Accessed 27 December 2023].
 45. Sey M, Schmaltz L, Al-Haddad M, et al. Effectiveness and safety of serial endoscopic ultrasound-guided celiac plexus block for chronic pancreatitis. *Endosc Int Open* 2015;3:E56–9. Available at: <https://pubmed.ncbi.nlm.nih.gov/26134773/>. [Accessed 27 December 2023].
 46. Gress F, Schmitt C, Sherman S, et al. Endoscopic ultrasound-guided celiac plexus block for managing abdominal pain associated with chronic pancreatitis: a prospective single center experience. *Am J Gastroenterol* 2001;96:409–16. Available at: <https://pubmed.ncbi.nlm.nih.gov/11232683/>. [Accessed 27 December 2023].
 47. Gress F, Schmitt C, Sherman S, et al. A Prospective Randomized Comparison of Endoscopic Ultrasound- and Computed Tomography-Guided Celiac Plexus Block for Managing Chronic Pancreatitis Pain. *Am J Gastroenterol* 1999;94:900–5.
 48. Puli SR, Reddy JBK, Bechtold ML, et al. EUS-guided celiac plexus neurolysis for pain due to chronic pancreatitis or pancreatic cancer pain: a meta-analysis and systematic review. *Dig Dis Sci* 2009;54:2330–7. Available at: <https://pubmed.ncbi.nlm.nih.gov/19137428/>. [Accessed 27 December 2023].
 49. Stevens T, Costanzo A, Lopez R, et al. Adding tramcinolone to endoscopic ultrasound-guided celiac plexus blockade does not reduce pain in patients with chronic pancreatitis. *Clin Gastroenterol Hepatol* 2012;10. Available at: <https://pubmed.ncbi.nlm.nih.gov/21946121/>. [Accessed 27 December 2023].
 50. Michaels AJ, Draganov PV. Endoscopic ultrasonography guided celiac plexus neurolysis and celiac plexus block in the management of pain due to pancreatic cancer and chronic pancreatitis. *World J Gastroenterol* 2007;13:3575–80. Available at: <https://pubmed.ncbi.nlm.nih.gov/17659707/>. [Accessed 27 December 2023].
 51. Lillemoe KD, Cameron JL, Kaufman HS, et al. Chemical splanchnicectomy in patients with unresectable pancreatic cancer. A prospective randomized trial. *Ann Surg* 1993;217:447–57. Available at: <https://pubmed.ncbi.nlm.nih.gov/7683868/>. [Accessed 27 December 2023].
 52. Muscatiello N, Panella C, Pietrini L, et al. Complication of endoscopic ultrasound-guided celiac plexus neurolysis. *Endoscopy* 2006;38:858. Available at: <https://pubmed.ncbi.nlm.nih.gov/17001583/>. [Accessed 27 December 2023].
 53. HM A, SE F, HF H, et al. End-organ ischemia as an unforeseen complication of endoscopic-ultrasound-guided celiac plexus neurolysis. *Endoscopy* 2009;

- 41(Suppl 2):E218–9. Available at: <https://pubmed.ncbi.nlm.nih.gov/19757362/>. [Accessed 27 December 2023].
54. Jang HY, Cha SW, Lee BH, et al. Hepatic and splenic infarction and bowel ischemia following endoscopic ultrasound-guided celiac plexus neurolysis. *Clin Endosc* 2013;46:306–9. Available at: <https://pubmed.ncbi.nlm.nih.gov/23767046/>. [Accessed 27 December 2023].
55. Petersen EW, Pohler KR, Burnett CJ, et al. Pulmonary embolism: a rare complication of neurolytic alcohol celiac plexus block. *Pain Physician* 2017;20:E751–3. Available at: <https://europepmc.org/article/MED/28727720>. [Accessed 27 December 2023].
56. Shimizu K, Ito T, Irisawa A, et al. Evidence-based clinical practice guidelines for chronic pancreatitis 2021. *J Gastroenterol* 2022;57:709–24. Available at: <https://pubmed.ncbi.nlm.nih.gov/35994093/>. [Accessed 27 December 2023].
57. Singh VK, Yadav D, Garg PK. Diagnosis and Management of Chronic Pancreatitis: A Review. *JAMA* 2019;322:2422–34. Available at: <https://pubmed.ncbi.nlm.nih.gov/31860051/>. [Accessed 27 December 2023].