Puebla ''Dr. Eduardo Vázquez Navarro'', Antiguo Camino a Guadalupe Hidalgo 11350, Agua Santa, Puebla 72490, Mexico.
E-mail address: rubenpevelez@hotmail.com
(R. Peña-Vélez).

2255-534X/ © 2022 Asociación Mexicana de Gastroenterología. Published by Masson Doyma México S.A. This is an open access article under the CC BY-NC-ND license (http://creativecommons.org/licenses/by-nc-nd/4.0/).

Laparoendoscopic modified Puestow procedure. A report on two cases☆

Procedimiento de Puestow modificado laparoendoscópico. Reporte de dos casos

Chronic pancreatitis (CP) is characterized by chronic inflammation, fibrosis, and irreversible scarring that results in the loss of both exocrine (acinar) and endocrine (islet cells) pancreatic tissue[1].

Etiology can be toxic-metabolic (alcohol, tobacco, medications, etc.), idiopathic, genetic, autoimmune, obstructive, or due to episodes of recurrent acute pancreatitis[2].

CP causes healthy parenchyma to be substituted with fibrous connective tissue, resulting in increased density, atrophy, calcification, pseudocysts, and irregularities in the main pancreatic duct (MPD) and its branches. Complications of CP are stricture of the MPD and/or bile ducts, pseudocysts, pancreatolithiasis, duodenal stricture, malnutrition, vascular complications, and recurrent pain[3].

Stones in the MPD cause an increase in the pressure of the parenchyma, as well as ischemia and chronic abdominal pain[4].

Endoscopic management focuses on resolving MPD obstruction through dilation or stent placement, in the case of MPD stricture, or through the removal of stones[5].

Surgical options include drainage, resection, resection with extended drainage, pancreatic denervation alone, or islet autotransplantation. The choice of the procedure depends on the morphologic changes of the pancreas (dilation of the MPD, stricture, lithiasis)[6].

Studies conclude that surgical treatment is more efficacious and longer lasting than endoscopic treatment[7–9]. At present, the ideal time for surgical intervention is not known. Nealon et al. suggest that early surgical decompression of the MPD delays the progressive destruction of the pancreas[8].

The modified Puestow procedure consists of a side-to-side longitudinal pancreaticojejunostomy of at least 10 cm, with no resection of the pancreatic tail or the pancreas. It is indicated in patients with MPD dilation > 7 mm, a ''chain of lakes'', and no inflammatory mass in the pancreatic head. Pain relief resulting from that surgery has been shown to be around 60–70%[10].

☆ Please cite this article as: Brito-Carmona RD, Cuendis-Velázquez A, Carrión-Astudillo CM, Bozada-Gutiérrez KE, García-Manzano RA. Procedimiento de Puestow modificado laparoendoscópico. Reporte de dos casos. Rev Gastroenterol Méx. 2022;87:501–503.

Case 1

A 47-year-old man had a past medical history of chronic alcoholism and type 2 diabetes mellitus, both of 10-year progression. He presented with a high risk for choledocholithiasis. Endoscopic retrograde cholangiopancreatography (ERCP) was performed, revealing common bile duct stricture, and an endostent was placed. Later, the patient presented with pain, and an endoscopic ultrasound (EUS) study was carried out that identified a dilated MPD (10 mm), with multiple intraductal stones, calcifications in the pancreatic parenchyma, atrophy of the pancreatic head and tail, and dilation of the intrahepatic and extrahepatic bile ducts. Laparoendoscopic modified Puestow procedure plus cholecystectomy was performed. Oral diet was started the same day and the patient was released from the hospital 48 h after the procedure, with no complications.

Case 2

A 22-year-old man had a past medical history of numerous hospital admissions due to severe acute pancreatitis of biliary origin, from 2017 to the present date (eight hospital admissions). EUS identified signs of CP, MPD dilation, and intraparenchymal calcifications in the head, body, and tail of the pancreas and inside the MPD (Fig. 1A1–A3). Contrast-enhanced abdominal computed tomography scan revealed CP with multiple calcifications (Fig. 1B1–B2). The laparoendoscopic modified Puestow procedure with pancreatic biopsy was performed on September 2, 2021, confirming CP, with extensive fibrosis, associated with chronic inflammation (Fig. 1C). Oral diet was started the same day, in the afternoon, and the patient was released from the hospital 48 h after the procedure, with no complications.

For the approach, a 12 mm supraumbilical camera port was placed; two 12 mm trocars were placed in the left and right midline of the clavicle; and two 5 mm trocars were placed in the anterior axillary line of both flanks (Fig. 2A). The gastrocolic ligament was cut with a Harmonic Ace® scalpel (Ethicon Endo-Surgery Inc.) (Fig. 2B), the omentum was accessed by cutting the short vessels, and the posterior gastric surface was fixed to the parietal peritoneum with a polypropylene GEA extracorporeal knot, to enable exposure (Fig. 2C). The atrophic and hardened pancreas was observed (Fig. 2D) and the main pancreatic duct was punctured, releasing pancreatic fluid (Fig. 2E). A 7 cm long pancreatotomy was made from the neck to the tail and the pancreatic duct was deroofed with a monopolar hook (Fig. 2F). Pancreatoscopy (Fig. 2G) revealed intraductal stones (Fig. 2H) that were then removed. Irrigation with physiologic solution was carried out through a 5 Fr catheter (Fig. 2I). Repeat pancreatoscopy corroborated the absence

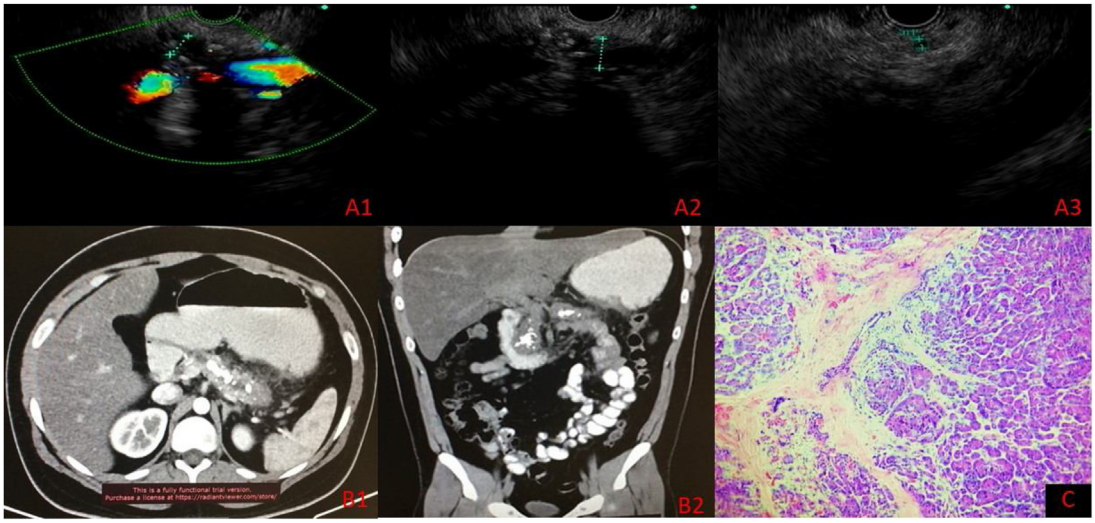

Figure 1 A) Endoscopic ultrasound with main pancreatic duct measurement. A1) Neck 7 mm. A2) Body 10 mm. A3) Tail 3 mm (intraductal calcifications in body and tail). B1-B2) Contrast-enhanced abdominal computed tomography scan. C) Histopathology: chronic pancreatitis with extensive fibrosis associated with chronic inflammation.

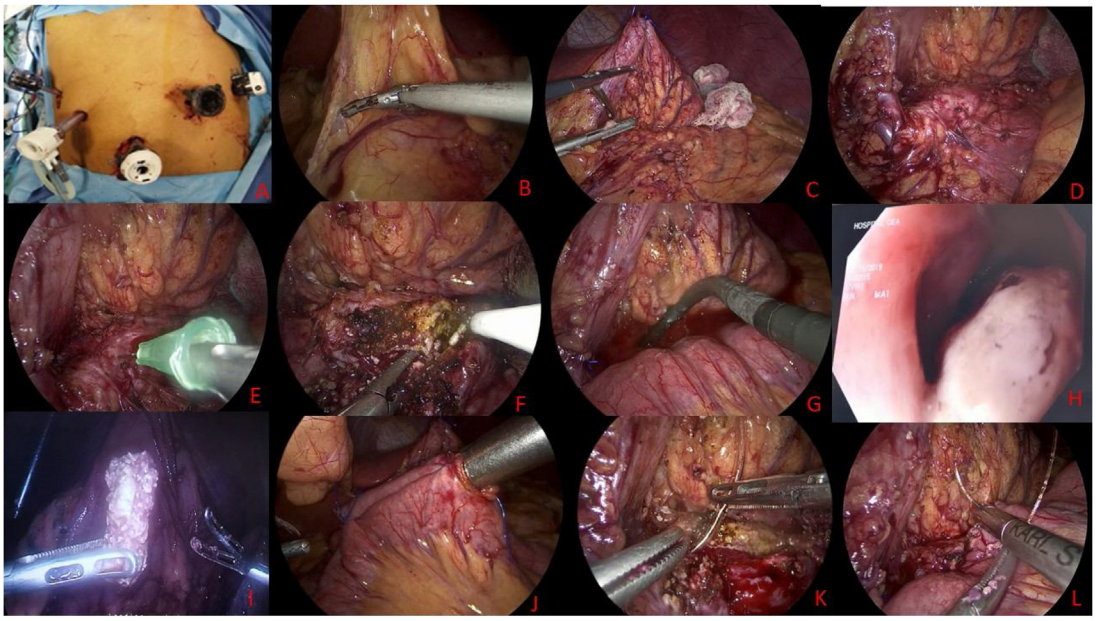

Figure 2 A) Trocar placement. B) Opening of the gastrocolic ligament. C) Stomach fixed to the perineum to expose the pancreas. D) Atrophic pancreas. E) Main pancreatic duct puncture. F) Opening of the main pancreatic duct. G) Pancreatoscopy. H) Stones in the main pancreatic duct. I) Stone after its extraction. J) Roux-en-Y formation. K) Posterior wall pancreatojejunoanastomosis. L) Anterior wall pancreatojejunoanastomosis.

of ductal stones. A Roux-en-Y 60 cm biliary loop and 50 cm feeding loop were made utilizing an Endo-GIA™ stapler (Covidien, Minnesota, USA) (60 mm staples) (Fig. 2J). The jejunal isoperistaltic loop was lifted in front of the colon (antecolic) and a manual side-to-side pancreaticojejunostomy was performed. Continuous two-layer suturing was carried out with 2-0 polypropylene and reinforced with 2-0 barbed suture at the posterior surface (Fig. 2K) and with continuous 2-0 barbed suture at the anterior surface (Fig. 2L). Jackson Pratt drains were then placed at the posterior and anterior surfaces of the stomach.

Ethical considerations

A written statement of informed consent was obtained from the patients and responsible relatives, with two witnesses, before the surgical procedure was performed. Given that the present article is a case report and not a research study, authorization from the ethics committee of the *Hospital General Dr. Manuel Gea González* was not requested. The authors declare that this article contains no personal information of any type that could identify the patients.

References

1. Levy P, Domínguez-Muñoz E, Imrie C, et al. Epidemiology of chronic pancreatitis: burden of the disease and consequences. United European Gastroenterol J. 2014;2:345–54, http://dx.doi.org/10.1177/2050640614548208.
2. Whitcomb DC. Pancreatitis: TIGAR-O Version 2 risk/etiology checklist with topic reviews, updates, and use primers. Clin Transl Gastroenterol. 2019;10:e00027, http://dx.doi.org/10.14309/ctg.0000000000000027.
3. Hoffmeister A, Mayerle J, Beglinger C, et al. English language version of the S3-consensus guidelines on chronic pancreatitis: Definition, aetiology, diagnostic examinations, medical, endoscopic and surgical management of chronic pancreatitis. Z Gastroenterol. 2015;53:1447–95, http://dx.doi.org/10.1055/s-0041-107379.
4. Bhasin DK, Rana SS, Sidhu RS, et al. Clinical presentation and outcome of endoscopic therapy in patients with symptomatic chronic pancreatitis associated with pancreas divisum. JOP. 2013;14:50–6, http://dx.doi.org/10.6092/1590-8577/1218.
5. Dumonceau J-M, Delhaye M, Tringali A, et al. Endoscopic treatment of chronic pancreatitis: European Society of Gastrointestinal Endoscopy (ESGE) guideline - updated august 2018. Endoscopy. 2019;51:179–93, http://dx.doi.org/10.1055/a-0822-0832.
6. Beger HG, Büchler M. Duodenum-preserving resection of the head of the pancreas in chronic pancreatitis with inflammatory mass in the head. World J Surg. 1990;14:83–7, http://dx.doi.org/10.1007/BF01670550.
7. Issa Y, Kempeneers MA, Bruno MJ, et al. Effect of early surgery vs endoscopy-first approach on pain in patients with chronic pancreatitis: The ESCAPE randomized clinical trial. JAMA. 2020;323:237–47, http://dx.doi.org/10.1001/jama.2019.20967.
8. Nealon WH, Thompson JC. Progressive loss of pancreatic function in chronic pancreatitis is delayed by main pancreatic duct decompression. A longitudinal prospective analysis of the modified puestow procedure. Ann Surg. 1993;217:458–66, http://dx.doi.org/10.1097/00000658-199305010-00005.
9. Cahen DL, Gouma DJ, Nio Y, et al. Endoscopic versus surgical drainage of the pancreatic duct in chronic pancreatitis. N Engl J Med. 2007;356:676–84, http://dx.doi.org/10.1056/NEJMoa060610.
10. D'Haese JG, Cahen DL, Werner J. Current Surgical Treatment Options in Chronic Pancreatitis. In: Pancreapedia: Exocrine Pancreas Knowledge Base; 2016, http://dx.doi.org/10.3998/panc.2016.26.

R.D. Brito-Carmona*, A. Cuendis-Velázquez, C.M. Carrión-Astudillo, K.E. Bozada-Gutiérrez, R.A. García-Manzano

Departamento de Cirugía General y endoscópica, Hospital General ''Dr. Manuel Gea González'', SSA, Mexico City, Mexico

*Corresponding author at: Calz. de Tlalpan 4800, Belisario Domínguez Secc 16, Tlalpan, 14080, Mexico City, Mexico. Tel.: 5543152027.
E-mail address: ronniedamian@hotmail.com (R.D. Brito-Carmona).

2255-534X/ © 2022 Asociación Mexicana de Gastroenterología. Published by Masson Doyma México S.A. This is an open access article under the CC BY-NC-ND license (http://creativecommons.org/licenses/by-nc-nd/4.0/).

Gastrointestinal bleeding as the first manifestation of gastric amyloidoma: A case report☆

Sangrado gastrointestinal como primera manifestación de amiloidoma gástrico: reporte de caso

The word amyloidosis refers to a pathologic finding that encompasses a heterogeneous spectrum of etiologies and clinical presentations. The main characteristic of amyloidosis is the deposition of insoluble extracellular protein fragments in various organs, abnormally folded in such a way that they are resistant to digestion[1]. Those deposits affect both the structure and function of the compromised organs.

In the gastrointestinal tract, amyloid deposition is produced in the *muscularis mucosae*, very close to the vasculature, nerves, and nerve plexuses[2]. Said deposition increases blood vessel fragility, hinders intrinsic peristalsis, and reduces intestinal wall distensibility[3]. Those events explain the symptoms of gastrointestinal amyloidosis of weight loss, diarrhea, abdominal pain, malabsorption, esophageal reflux, and different grades of upper and lower gastrointestinal bleeding[4,5], with severe bleeding being a rare manifestation[5]. We report herein the case of a patient with signs of gastric amyloidosis who presented with gastrointestinal bleeding.

A 59-year-old man, with an unremarkable past medical history, came to the emergency department on two occasions due to epigastric pain, melena, diaphoresis, and dyspnea, of seven-day progression. The initial evaluation showed anemia (hemoglobin: 9.7 g/dl) and hemodynamic stability, for which he received outpatient management with oral omeprazole. He sought medical attention 48 h later because of hematochezia. Upper gastrointestinal endoscopy identified a 10 × 10 mm lesion with a neoplastic aspect in the gastric body, toward the greater curvature, with surrounding infiltrate-like mucosa (Fig. 1). Numerous biopsy samples were taken that contained deposits of pale pink interstitial and extracellular material with a thick and cracked hyaline appearance. Congo Red staining produced a salmon-pink color that, under polarized light, showed apple-green birefringence (Fig. 2).

In conjunction with the hematology service, the possibility of secondary amyloidosis was evaluated, with no signs of a monoclonal peak. Strikingly, there was a slight increase in the Kappa light chains, with respect to the Lambda chains, in values not consistent with immunoglobulin amyloid light chain (AL) amyloidosis, and so the conclusion was a single

☆ Please cite this article as: Hani AC, Tobón A, Vargas MJ, Muñoz OM. Sangrado gastrointestinal como primera manifestación de amiloidoma gástrico: reporte de caso. Rev Gastroenterol Méx. 2022;87:503–505.