

---

# **Role of Surgery in the Treatment of Pancreatitis and Its Complications**

---

Vincenzo Neri

Additional information is available at the end of the chapter

<http://dx.doi.org/10.5772/58932>

---

## **1. Introduction**

The nosography of pancreatitis has been modified because the established distinction between acute and chronic pancreatitis is under critical revision. In this argument there is a reduced availability or absence of histological data connected to a clinical picture; on the other hand the various classifications are based exclusively on clinical or laboratory data or on imaging exams [1]. Moreover, the extremely diversified territorial distribution of the various forms of pancreatitis generates uncertainties: this often provides different experiences to different observers. The rigorous distinction between acute and chronic pancreatitis has represented the basis of classifications in which there have been two distinct diseases. More recently, more comprehensive, prolonged and detailed clinical observations have enabled a more thorough knowledge of pancreatitis. These observations show that acute and chronic pancreatitis overlap [1]. According to these new perspectives, two clinical pictures should be reviewed and reconsidered: the onset and/or the acute manifestations of chronic pancreatitis due to severe tissue inflammation more evident than main/branch duct dilation; and acute pancreatitis that evolves anatomico-clinically towards chronic forms, because of the recurrence of acute episodes with evolution of inflammation in fibrosis, sclerosis and calcifications. The aim of the chapter is to evaluate surgical procedures with a minimally invasive approach as the preferred choice, demonstrating separately the diagnostic and therapeutic pathways for acute and chronic pancreatitis.

## **2. Acute pancreatitis**

Acute pancreatitis is one of the most common gastrointestinal diseases. An increase in the annual incidence for acute pancreatitis has been reported in many countries. In the United

---

States, pancreatitis is among the most common gastrointestinal diseases requiring acute hospitalization [2,3]. The incidence of acute pancreatitis varies between 4.8 to 24.2 cases per population of 100,000 following data from England, Denmark and theUS, but has been also associated with an incidence of 40-50 cases per 100,000 habitants a year [4]. While part of this increase is certainly due to better clinical and diagnostic knowledge of these diseases, the possibility of a real increase cannot be ruled out [5]. Acute pancreatitis is a complex gastrointestinal disease with various aetiologies, most frequent biliary and alcoholic. Clinical presentation shows different degrees of severity with biphasic evolution. Acute pancreatitis is an inflammatory disease that can occur in an oedematous reversible form, most frequently, or in a necrotic one that is less frequent. Inflammatory diseases of the pancreas are characterized by autodigestion processes of the gland carried out by enzymes that have been inappropriately activated in the gland. Activation of trypsinogen into trypsin within the acinar cells is the starting event. The activation of other pancreatic proenzymes follows (proelastase, chymotrypsinogen, etc.). This autoactivation process of trypsin leads to pancreatic acinar cell damage with spillage of activated enzymes into the pancreatic and peripancreatic tissue [6-8].

### 2.1. Aetiological and nosographic assessment as a guide for surgery in therapeutic programmes

Many factors play an aetiological role in acute pancreatitis. In most countries biliary lithiasis and excessive alcohol consumption are the most frequent causes reaching a total incidence of 80%. Moreover, numerous other causes of pancreatitis are recognized that represent 20% of the total [9]. This remaining 20% constitutes a rather various group of causes of pancreatitis: hypercalcaemia, hypertriglyceridaemia, hereditary causes, sphincter of Oddi dysfunction, pancreas divisum, pancreatic neoplasms, medications, infections and parasitic agents, endoscopic retrograde cholangiopancreatography (ERCP) trauma (table. 1).

Common causes	Uncommon causes	Rare causes
Gallstones	Autoimmunity	Pancreas divisum
Alcoholism	Genetics	Annular pancreas
Hypertriglyceridaemia	Abdominal trauma	Scorpion venom
Post-endoscopic retrograde cholangiopancreatography	Postoperative causes	Posterior penetrating ulcer
Drug use	Sphincter of Oddi dysfunction	
	Ischaemia	
	Infections	
	Hypercalcaemiaand	
	hyperparathyroidism	

**Table 1.** Aetiology of acute pancreatitis

Therefore pancreatitis can be considered diseases with different aetiological incidences in different countries based on environmental features and lifestyle.

In the current clinical appearance of acute pancreatitis the majority of patients (70-80%) present with a mild-moderate disease; however, approximately 20-30% run a severe course and require appropriate management in an intensive care unit. In the severe forms, in approximately 20% of cases, development of persistent organ failure and/or of infected pancreatic complications necessitates the definition of the most severe forms, identified as critical, early severe acute pancreatitis [10,11]. Critical forms are characterized by a short course, progressive multiple organ dysfunction, early hypoxaemia, high computed tomography severity index (CTSI), and increased incidences of necrosis, infection and abdominal compartment syndrome (ACS). Early severe acute pancreatitis mortality rate can be very high: 40% according to the literature. [12-16]

Severe acute pancreatitis can be seen as a biphasic disease, with the first two weeks phase characterized by early toxic-enzymatic injury (systemic inflammation response syndrome (SIRS)) and a late phase—in the third and fourth week—characterized by septic complications (infection of necrotic tissue and of peripancreatic fluid collection). Pancreatitis can present different severities in the first (toxic) phase: it can be self-limiting or quickly responsive to intensive care (especially rehydration), or it can quickly evolve into SIRS and multi-organ failure (MOF). The acute pancreatitis may progress and worsen from local disease to general involvement. The key of this evolution is the tissue response of the pancreas to acinous cell necrosis. Local actions of phlogosis lead to the activation of local macrophages and attraction of activated polymorphonuclear cells. General diffusion of phlogosis (SIRS) can develop from the passage of inflammatory mediators (pro-anti inflammatory mediators released from the splanchnic area) to systemic compartments by the lymphatic system, portal veins, and general circulation. Vascular alterations cause gut barrier failure with translocation by bacteria and endotoxin diffusion. The final results are distant organfailure (MOF) and generally later infection of fluid-necrotic pancreatic-peripancreatic gatherings [17-25].

The examination and evaluation of homogeneous clinical cases allows us to clarify the surgical options in the overall treatment programme. In our institution between 1998 to 2013 we observed and treated 304 pancreatitis cases, 294 acute biliary pancreatitis cases, and ten chronic alcoholic pancreatitis cases. The mean age was 49 years (range 30-86 years). Male:female ratio was 1:1.33 (table 2).

304 pancreatitis-mean age 49 yrs. (range 30-86 yrs.)- M:F ratio 1:1.33	
Acute pancreatitis	Chronic pancreatitis
294	10

**Table 2.** Demographic data, 304 pancreatitis.

An acute episode of pancreatitis was defined, at first assessment, on the basis of the clinical appearance of nausea, vomiting and abdominal pain in mesogastrium radiating through the back with abdominal wall tenderness (superficial/depth) and muscular rigidity of varying degrees, and laboratory data with almost twice the normal increase of the serum lipase and

pancreatic amylase. This initial diagnostic phase was completed by evaluation of the involvement of general conditions and of the degree of pancreatic impairment by abdominal US.

Biliary aetiology was confirmed in 294 patients. This group included 93 patients with previous repeated episodes (31.63%). Among the 93 recurrent pancreatitis cases were also 20 patients, recently observed, with recurrent unexplained pancreatitis at first aetiological evaluation [26]. The biliary aetiology of pancreatitis has been established in a large majority of patients at initial etiological assessment by the research on abdominal US, gallbladder lithiasis, and/or gallstones, sludge, microlithiasis, etc. in the common bile duct (CBD), or also a dilation of the CBD (>8mm) with the addition of liver function tests, fasting serum calcium, and lipid profile (Tab 3). In 20% of these patients alcohol consumption slightly over the average has also been noted. Twenty patients (6.8%) have been diagnosed with recurrent unexplained forms at first-level aetiological assessment. The following diagnostic study, MRCP and/or endoscopic US, confirmed the biliary origin of pancreatitis in the majority of cases (14 patients). Only in six cases did the aetiology of pancreatitis remain unexplained. Following empirical criteria, four cholecystectomies and two ERCP/ES procedures were carried out in these six patients whose aetiology remained undefined and who had already undergone cholecystectomy.

Dir Bil (0.02-0.30 mg/dL) <2 mg/dl	Dir Bil (0.02-0.30 mg/dL) 2-5 mg/dl	AST/ALT X3	g-GT (7-38 u/L) >200 u/L	
61.2%	38.8%	29.4%	63.4%	
Serum calcium (8.4-10.5 mg/dL) >10.5 mg/dL	Triglyceridaemia (40-170 mg/dL) >170 mg/dL	Cholelithiasis/ sludge	CBD size (US) (8mm)	Undefined aetiology
16%	43%	84%	41.3%	6.8%

**Table 3.** 294 acute biliary pancreatitis: percentage incidence of biliary lithiasis and cholestasis indexes at first level aetiological assessment

Acute pancreatitis shows a wide range of disease, ranging from a mild form to a severe or early severe, rapidly progressive illness. The most common cause of acute pancreatitis is biliary lithiasis—almost the total number of cases in our experience. The majority of our patients had a mild-moderate disease. Mild acute pancreatitis takes a self-limiting form characterized by pancreatic or peripancreatic oedema and normal enhancement of pancreatic parenchyma on contrast-enhanced CT. Moderate pancreatitis develops early acute fluid collections located in or near the pancreas without a wall of fibrous tissue, almost always with spontaneous regression. These forms are not accompanied by impairment of the patient’s general condition. In summary, regarding a first-line therapeutic approach, mild-moderate acute pancreatitis requires only supportive therapy and generally evolves towards a spontaneous recovery. Among 294 acute biliary pancreatitis cases we have observed and treated 167 (56.80%) mild-moderate forms, 61 (20.74%) moderate severe forms, 51 (17.34%) severe acute pancreatitis cases, and 15 (5.10%) early severe acute pancreatitis cases. Moderate-severe acute pancreatitis

is characterized by large, broad peripancreatic and pancreatic involvement with fluid/necrotic collections but without impairment of general clinical conditions. Organ failure is transient or absent. Severe forms have diffuse or local areas of non-viable pancreatic parenchyma, peripancreatic fat necrosis, non-enhanced pancreatic parenchyma on contrast CT, and/or fluid-necrotic peripancreatic collections with persistent or transient organ failure [27-28]. Within the severe forms there are also critical or early severe forms with persistent or transient organ failure and infected pancreatic and peripancreatic collections. In our patients (294) we have applied CTSI with Balthazar scoring for the grading of acute pancreatitis and points for necrosis [29-31]. This classification is based on morphological and functional features: local or diffuse enlargement of the pancreas, pancreatic gland abnormalities, peripancreatic inflammation with pancreatic and peripancreatic fluid collections, and areas of non-enhanced parenchyma. In this morphologic assessment moderate (167), moderate-severe (61), severe (51) and early severe acute pancreatitis (15) cases have been included (table 4).

Grade B1		160 (54.42%)
Grade C2		68 (23.12%)
Grade D3		51 (17.34%)
Grade E4		15 (5.10%)
Pancreatic necrosis		
0	None	228
2	Less than/equal to 30%	49
4	>30-50%	17
6	>50%	-

**Table 4.** 294 acute biliary pancreatitis. CT severity index: CT grade point+point for necrosis (Balthazar)

The therapeutic approach of acute biliary pancreatitis usually develops in two phases following the evolution of the disease. The first phase in mild-moderate forms consists of simple fluid rehydration and control of abdominal pain. In severe acute pancreatitis the first phase is conventionally referred to the first two weeks from onset, and the initial approach is based on intensive care, initial aggressive fluid resuscitation, low dose steroids, anticoagulatory agents for anti-inflammatory properties, correction of hypoxaemia, enteral nutrition to preserve the intestinal wall integrity and antibiotic prophylaxis [32]. In this phase the most important purpose is to control and treat—by intensive care support—the impairment of the general conditions and single or multiple organ failure that can occur. Besides, the central key in the global therapeutic programme for acute biliary pancreatitis is the control and treatment of papillary patency. ERCP and endoscopic sphincterotomy (ES) can assure papillary flow and CBD cleaning if lithiasis obstacle, sludge, and microlithiasis are present. We scheduled ERCP/ES for within three to four days from onset in 217 patients (73.8%); three patients needed to be excluded because the procedure was not feasible. This therapeutic programme was performed in the following cases: 64 patients with severe and early severe acute pancreatitis, 60 with

moderate-severe disease and 73 with recurrent pancreatitis, and finally in 17 with moderate pancreatitis. In these patients we achieved laboratoristic or US or MRCP confirmation of a papillary or CBD lithiasic obstacle. In seven patients with severe acute and moderate-severe pancreatitis ERCP/ES was delayed for ten days. Among 214 patients who underwent ERCP/ES, CBD cleaning was confirmed in 163 (76.16%). The therapeutic programme of acute biliary pancreatitis ends with videolaparocholecystectomy (VLC). The timing of the VLC is connected with the evolution of acute pancreatitis, waiting for the stabilization of the local phlogistic process, and of the general condition. In any case, in our opinion, the cholecystectomy should be performed in the same hospital stay [33,34]. The severe and early severe forms of acute biliary pancreatitis were evident for local and/or systemic complications. The degree of pancreas impairment with Balthazar score was five in severe acute pancreatitis (SAP), and eight in early severe acute pancreatitis (ESAP). Abdominal compartment syndrome (ACS) was demonstrated in only one patient with ESAP (1/15–6.6%), multiple organ dysfunction syndrome (MODS) in six patients with ESAP (6/15–40.46%), simple organ dysfunction in 26 patients with SAP (26/51–50.98%) versus eight patients with ESAP (8/15–53.33%), pancreatic sepsis in four patients with SAP (4/51–7.84%) versus three patients with ESAP (3/15–20%), hypoxaemia in 34 patients with SAP (34/51–66.66%) versus 11 patients with ESAP (11/15–73.33%). Mortality rate was 3.92% (2/51) (late) in SAP versus 13.33% in ESAP (2/15) (early). Mortality occurred early in patients with ACS (fifth postoperative day) and in patients with multiple organ dysfunction syndrome (first week from onset), and later in two patients who had not undergone surgical treatment, for prolonged organ dysfunction (third and fourth week) (table5).

	SAP	ESAP
Impairment degree of pancreas (Balthazar CT score)	5	8
Abdominal compartment syndrome (ACS) (%)	-	6.6% (1/15)
Multiple organ dysfunction syndrome	-	40.46% (6/15)
Simple organ dysfunction	50.98% (26/51)	53.33% (8/15)
Pancreatic sepsis	7.84% (4/51)	20% (3/15)
Hypoxaemia	66.66% (34/51)	73.33% (11/15)
Mortality	3.92% (2/51) late	13.33% (2/15) early

**Table 5.** Comparison of the clinical appearance of early severe acute pancreatitis (ESAP) and severe acute pancreatitis (SAP)

These forms required appropriate management in intensive care. In early severe forms there was a great compromise of general conditions by early toxic-enzymatic injury and high rate of early mortality (13.33%). The later phase of the disease (third and fourth week) was characterized by septic complications of pancreatic or peripancreatic fluid-necrotic collections.

The preferred approach to fluid and necrotic collections was US/CT guided percutaneous drainage. In our experience, considering 66 patients (51 SAP and 15 ESAP), we intervened only in eight patients: three US/CT guided percutaneous drainages of peripancreatic septic gatherings, two US/CT guided percutaneous drainages of fluid intrahepatic gatherings, and two US/CT guided percutaneous drainages of necrotic gatherings. These minimally invasive approaches were followed by clinical improvement without further intervention. We performed an open approach for decompression with midline laparotomy and immediate skin coverage in one patient with ACS. In the case of late evolution of acute pancreatitis we performed two pseudocyst-jejunostomies by an open procedure for acute postnecrotic pseudocysts.

Complications of ERCP/ES, including post-procedural pancreatitis, perforations, bleeding and infections are not unusual. The incidence of overall complications is evaluated to be about 10%, with a major morbidity of 1.5% and mortality less than 0.5% [35,36]. Recent data from the literature have shown an overall complication rate that is never negligible, but the majority of events are of mild-to-moderate severity [37]. In our experience, we registered two duodenal perforations (2/214-0.93%). One patient was treated with conservative therapy, and the other case was submitted to surgical intervention by cholecystectomy, duodenostomy and gastro-jejunal anastomosis. Severe post-procedural pancreatitis occurred in three patients (3/214-1.40%) and was treated with medical therapy followed by resolution with a prolonged hospital stay (ten days). We also observed two post-ERCP bleeding cases (2/214-0.93%) treated with an endoscopic approach (adrenalin infiltration). Minor complications such as mild pancreatitis with hyperamylasaemia alone and rapid self-limiting evolution were observed in 18 patients (18/214-8.41%). In this endoscopic procedure it is important to identify the risk factors in order to lower complication rates: physiopathological conditions such as Oddi sphincter dysfunction and biliary duct dilation, technical difficulties of the manoeuvres performed such as the use of a guide-wires, necessity to perform a pre-cut, and finally elderly high-risk patients.

A clinical and instrumental follow-up programme, three and six months after discharge, based on clinical control, laboratory tests and abdominal US has been planned for 294 patients with acute biliary pancreatitis. The follow-up programme has divided the patients of ERCP/ES (214/217 scheduled) from the patients not submitted to this therapeutic procedure (80), with mild-moderate forms of pancreatitis. Delayed control was carried out for 124 patients (124/214-57.94%) of the first group (submitted to ERCP/ES); 90 patients could not be reached. The results of the follow-up, at three and six months, showed the absence of critical episodes, and stable normalization of laboratory and instrumental cholestasis tests (table 6)

Four patients (4/124-3.22%) had a recurrence of a mild-moderate pancreatitis before the first control. The persistence of the papillary obstacle for incomplete sphincterotomyl was assessed: the new sphincterotomy and medical therapy for resolution was performed. The same check was performed in 38 patients with mild-moderate pancreatitis not submitted to ERCP/ES (38/80-47.50%); 42 patients could not be reached. This control at three and six months from the

Direct bilirubin (range 0,1-0,3 mg/dL)	0.17 mg/dL
Gamma-GT (range 31-64 iU/L)	52 iU/L
AST (range 22-57 iU/L)	25 iU/L
ALT (range 25-64 iU/L)	31 iU/L
Lipasaemia (range 120-221 iU/L)	165 iU/L
Pancreatic amylasaemia (range 34-72 iU/L)	47 iU/L
Alkaline phosphatase (range 67-220 iU/L)	115 iU/L
CBD size (range 5-8 mm, Abdominal US)	7 mm
Detection of CBD stones (Abdominal US)	-

**Table 6.** 124 patients with acute biliary pancreatitis submitted to ERCP/ES. Follow-up at three to six months (mean of two controls)

discharge was normal. No patient had a relapse of the acute attack and the haematochemical values of cholestasis indexes and pancreatic enzymes were normal (table 7)

Direct bilirubin (range 0,1-0,3 mg/dL)	0.21 mg/dL
Gamma-GT (range 31-64 iU/L)	48 iU/L
AST (range 22-57 iU/L)	24 iU/L
ALT (range 25-64 iU/L)	29 iU/L
Lipasaemia (range 120-221 iU/L)	171 iU/L
Pancreatic amylasaemia (range 34-72 iU/L)	42 iU/L
Alkaline phosphatase (range 67-220 iU/L)	105 iU/L
CBD size (range 5-8 mm, Abdominal US)	5 mm
Detection of CBD stones (Abdominal US)	-

**Table 7.** 38 patients with acute biliary pancreatitis not submitted to ERCP/ES. Follow-up at three to six months (mean of two controls)

## 2.2. Role of surgery in the treatment of acute pancreatitis

General guidelines for surgical treatment can be found for acute pancreatitis, mainly with biliary pathogenesis, which are clearly geared towards less aggression and minimally invasive approaches.

In mild-moderate acute biliary pancreatitis the minimally invasive therapeutic approach is the rule. The management programme includes the first-line diagnostic evaluation with the control of cholestasis laboratory tests and of CBD imaging (size, lithiasis, microlithiasis, sludge) by non-invasive instrumental exams (US). Usually the mild-moderate form undergoes a favourable self-limiting evolution; in fact, it needs only supportive therapy. In

some patients the onset of moderate pancreatitis can be more aggressive but not with heavy impairment of general conditions. In these cases it is useful to direct intensive care with rehydration, control of abdominal pain, antibiotic prophylaxis, and enteral nutrition [38,39]. In patients with cholestasis index increases and/or dilation of the CBD, the MRCP should be mandatory. In patients with mild-moderate forms, without an increase of cholestasis indexes, and in the absence of a dilation of the intra- and extrahepatic biliary ducts, it is all the same useful to know if obstacles not clinically manifest are present in the CBD, and these patients should be submitted to an MRCP before cholecystectomy. In all these cases the extensive use of MRCP can be useful for a significant reduction in the number of non-therapeutic ERCP/ES incidences [40,41].

Therefore if a papillary or CBD lithiasic obstacle is demonstrated, the therapeutic programme includes assuring papillary patency and common bile duct cleaning with ERCP/ES [42-52]. In all patients with pancreatitis with biliary pathogenesis, submitted to ERCP/ES or not, it is necessary to perform laparoscopic cholecystectomy in the same hospital stay to complete the gallstone treatment. The timing of laparoscopic cholecystectomy is connected with acute pancreatitis evolution because it is preferable to wait for the stabilization and improvement of the general condition and of the phlogistic impairment of pancreatic and peripancreatic tissue.

In severe and early severe acute biliary pancreatitis the therapeutic minimally invasive approach is generally the procedure of choice. Severe and early severe acute pancreatitis can develop through an altered balance between the proinflammatory reaction to pancreatic necrosis in the peritoneal compartment (positive effect) and systemic circulation and diffusion of the high level of anti-inflammatory mediators (negative effect). This balance alteration can cause SIRS and MODS. The minimally invasive therapeutic programme of severe and early severe pancreatitis follows the biphasic development of the disease. The minimal invasiveness is necessary in the first phase because it promotes the control of the impairment of general conditions by means of systemic intensive therapies that encompass initial aggressive fluid resuscitation and support of vasopression (dopamine, vasopressin, etc.) [53]. In biliary severe acute pancreatitis, the papillary obstacle (lithiasis, microlithiasis, oddities) and choledocholithiasis can have a minimally invasive endolaparoscopic approach by ERCP/ES. In the later evolution (second phase), local complications, if not solved spontaneously, allow an efficacious minimally invasive approach to be preferred in patients in unstable conditions. Control and treatment of pancreatic peripancreatic gatherings (necrotic, fluid, infected) and control and treatment of belated acute postnecrotic pseudocysts should be planned.

In the very wide perspective of the role of the surgery in the treatment of acute pancreatitis, there are some points of discussion about the surgical therapeutic approach in various clinical appearances, difference for timing of presentation (early-late), and degree of severity.

The indications of emergency surgical procedures for severe and early severe acute pancreatitis are evident. This initial clinical event is placed at the onset of acute pancreatitis definitely comes outside of septic complications, which are on the contrary characteristics of the next evolution of the disease. In the first phase of severe acute pancreatitis the clinical scenario is dominated by the impairment of general conditions (toxic phase), emergency surgery has restricted indications such as ACS, and there exists cases of uncertainty of diagnosis that may persist

even after imaging exams (US and/or CT). Aggressive fluid therapy is the rational treatment in the early phase of severe acute pancreatitis. This treatment allows the correction of hypovolaemia by third space fluid loss and a reduction of the high haematocrit that can serve as a marker of haemoconcentration, which is present in up to 60% of patients who develop organ failure. Aggressive fluid resuscitation with associated leaking capillaries can increase tissue oedema with consequent intra-abdominal hypertension (IAH) and ACS [54,55]. Therefore, severe pancreatitis fluid resuscitation and capillary leakage can lead to intra-abdominal hypertension. For this reason monitoring of intra-abdominal pressure (IAP) is necessary for patients at risk of developing ACS. If IAP reaches 12 mmHg conservative methods such as appropriate restriction of intravenous fluids, gastrointestinal decompression by nasogastric tube, and drainage of ascites fluid should be applied to prevent the development of ACS. This conservative management can be successful. If ACS develops in spite of these procedures, surgical emergency decompression should be performed. The surgical procedures used in the treatment of ACS are very complex; they can be grouped under the definition of surgical decompression. The most commonly employed surgical procedure is the midline laparotomy. All the layers of the abdominal wall are divided by a xiphopubic vertical incision and complete exposition of the abdominal cavity. A similar result can be achieved with a transverse bilaterally extended incision few centimetres below the costal margins [56-57]. A reduction of IAP can be achieved with both techniques. The clinical scenarios of the management of the open abdomen are very difficult. The various methods to cover the abdominal viscera for the necessary time until ACS improvement—generally some days—include a plastic silo (Bogotá bag), vacuum-assisted wound closure, or a vacuum pack or self-made negative pressure dressing. Finally vacuum-assisted wound closure combined with a mesh-mediated fascial traction [58] has been proposed. After surgical decompression and ACS has been treated, the following step is the abdominal wall closure. The available techniques encompass the primary fascial closure or planned hernia with skin coverage and subsequent delayed abdominal wall reconstruction.

In our experience, urgent surgical decompression with midline laparotomy and immediate skin coverage has been useful in patients who have developed ACS. The uncertainty of the diagnosis in SAP is rather unusual because of the diagnostic efficiency of laboratory and instrumental exams. Furthermore in doubt of the acute abdomen the emergency laparotomy is mandatory. Outside of these aforementioned clinical situations, surgical procedures should be avoided in patients with severe pancreatitis due to the high death rate when performed within the first few days of onset.

Patient choice and the timing of ERCP/ES are a much-debated issue in the therapy of acute biliary pancreatitis. Papillary obstruction is widely recognized as the pathogenic factor of acute biliary pancreatitis. The role of papillary obstruction by stones, sludge, and microlithiasis migration to the CBD from the gallbladder with bile reflux into pancreatic ducts, was described by Opie in 1901 [59]. It must also be remembered that the obstacle can be transitory, with the spontaneous migration of the stones in the duodenum; in addition the transit of the stones may be followed by inflammation and papillary sclerosis. The diagnostic confirmation of acute biliary pancreatitis is almost always possible on the basis of clinical, laboratory and instru-

mental data. The severity of the disease can also be established by multifactorial scores (Ranson [60], Glasgow [61], Apache II [62]) at the point of admission and in the first 24-48 hours, by unifactorial markers (PCR, TAP [63], Procalcitonin [64], Hct), and subsequently by means of imaging (Balthazar score and CTSI). In severe or early severe acute pancreatitis the initial therapeutic approach, as mentioned, is based on aggressive fluid resuscitation, invasive hemodynamic monitoring, intensive care, correction of hypoxaemia, and enteral nutrition [65]. Next, the cornerstone of the therapeutic programme required, in the opinion of many authors [38-48], an urgent ERCP with endoscopic sphincterotomy. This is also in the absence of cholangitis and sometimes without the verification of cholestasis, because the papillary obstacle is the cause of pancreatitis. Recent evidences suggest that can useful to modify this therapeutic choice; ERCP/ES should be performed based on clinical-laboratory evidence of cholestasis and/or cholangitis or on demonstration of biliary or papillary obstacle by MRCP [38,49,66,67]. Furthermore, in the course of mild-moderate acute biliary pancreatitis the ERCP/ES is reserved for cases with a documented papillary obstacle based on the increase of cholestasis indexes and/or of CBD size, or with obstacle presence (stones, odditis, etc.) in the CBD demonstrated by US/MRCP. On the other hand, only the therapeutic role of ERCP/ES has been established, while the diagnostic role for detection of CBD/papillary obstacles is played by MRCP.

There is a difficult decision to be made about the indication of ERCP/ES in a patient with acute pancreatitis with deterioration of general condition. Emergency ERCP in a patient submitted to intensive care, with the requirement of assisted ventilation, is a procedure with risk. In this clinical situation the therapeutic choice is not unanimously defined. In practice urgent ERCP/ES (within three to four days from the onset) should be performed in severe and early severe acute pancreatitis with cholangitis, or cholestasis or jaundice with evidence of SIRS. In conclusion, there is no clear-cut answer to the question as to whether or not early ERCP/ES in cases of acute biliary pancreatitis (within 24-72 hours from onset) reduces the risk of progression of acute pancreatitis to severe disease (organ failure and/or necrosis). [38]

It is, however, determined in severe and early severe cases without evidence of cholestasis, in recurrent acute pancreatitis, in moderate-severe pancreatitis and in patients with mild-moderate forms, to be appropriate and useful to confirm papillary or CBD lithiasis obstacle by laboratory, US or MRCP before therapeutic ERCP/ES. In patients with mild-moderate pancreatitis without instrumental, clinical-laboratory demonstration of papillary-CBD obstruction, the ES is not indicated. This therapeutic choice is based on the consideration that in mild-moderate forms the papillary obstacle (without cholestasis) may be transient and the treatment is not required [49,51].

A flow-chart of ERCP/ES employment in acute biliary pancreatitis is shown in figure 1.

The management of acute severe necrotizing pancreatitis has been much modified over time. The prevalence of acute necrotizing pancreatitis is 15-20% and its pathological basis is the hypoperfusion of the parenchyma on a contrast-enhanced CT (Balthazar score) [31]. The necrotic process involves the pancreatic gland and the peripancreatic tissues with very variable extension. The extensive interstitial oedema is associated with pancreatic and peripancreatic necrosis in a short period of 48-72 hours after the onset of acute attack. These inflammatory,

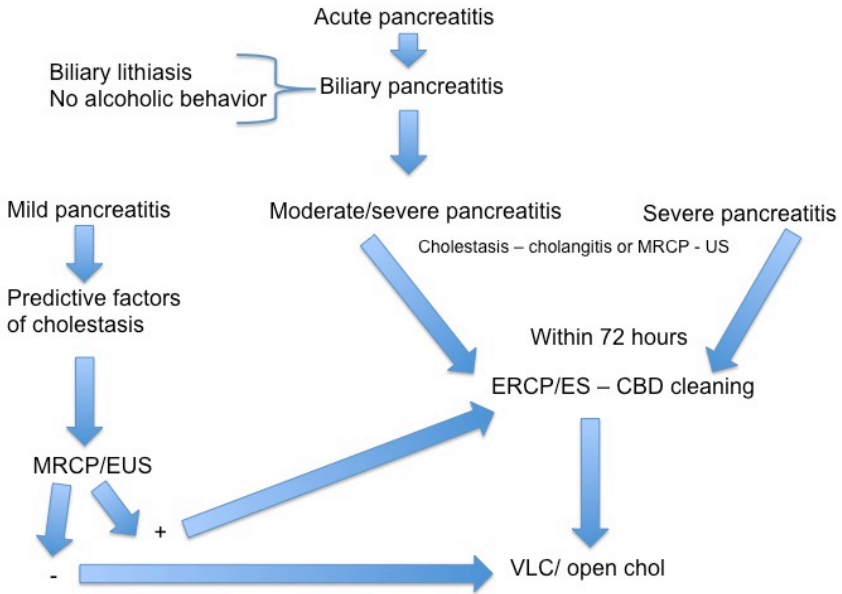


Figure 1. Flow-chart: ERCP/ES in acute biliary pancreatitis

necrotic tissues subsequently cause acute fluid collections with an amount of devitalized tissue. The further evolution of these fluid gatherings is characterized by demarcation between viable and necrotic tissue, and the limit is set with a wall of granulation tissue. The management of these pancreatic peripancreatic fluid-necrotic collections and their complications is the longest and most debated therapeutic problem.

Particularly in question are some specific surgical decisions: how long the control and observation of uncomplicated fluid-necrotic gatherings may be prolonged; which clinical, laboratory and instrumental data we must follow to differentiate between infected and sterile pancreatic necrosis; whether the intervention may be delayed for a few (four to eight) weeks in some patients with infected necrosis when the gathering has become walled off; and finally the choice of the best surgical approach for the treatment of fluid-necrotic complicated collections.

In severe acute pancreatitis (necrotizing) we can distinguish between two phases in the evolution of the disease, as is already reported; however, these two distinct phases can also be considered in relation to the surgical procedures. There is an early toxic phase (one to two weeks from the onset), characterized by the severe involvement of general conditions and the start of the dreaded SIRS: in this phase the main purpose is minimizing the mortality from MODS, and all surgical procedures should be avoided. The late phase (from the third week)

is characterized by the fluid-necrotic collections with or without septic complications, such as infected pancreatic necrosis.

Uncomplicated fluid necrotic gatherings may be submitted to conservative procedures that can be extended for four to eight weeks, when persisting peripancreatic fluid collections are referred to as acute postnecrotic pseudocysts. If these gatherings in this phase are not symptomatic, surgical manoeuvres and percutaneous drainages should be avoided. Placement of a drain into a sterile necrotic collection can result in secondary infection, and prolonged drainage may increase the risk further [68,69]. Most patients with sterile necrosis show results with conservative non-surgical management. It is debatable as to which patients the surgical procedure to treat sterile pancreatic necrosis can be useful for. In the data from the literature there is no complete solution, but there is a suggestion that, in selected cases with persistent organ failure and severe impairment of general conditions despite intensive care unit therapy, surgery may be useful in sterile necrosis [70-72]. In our experience we have undergone US/CT guided percutaneous drainage in two patients with symptomatic fluid intrahepatic gatherings.

After diagnosis of pancreatic necrotic collections the next step is the differentiation between sterile and infected necrosis. This diagnostic data may be essential for the therapeutic choice. The exam of choice is the fine-needle aspiration for bacteriology (FNAB), which can usually be guided by CT and/or US. The suspicion of infection may be based on the demonstration by CECT of gas bubbles into the gatherings. Moreover, this should be performed in patients with evident pancreatic peripancreatic necrotic gatherings and clinical signs of sepsis. This diagnostic procedure is accurate and safe with a very low incidence of complications such as bleeding. If the clinical, laboratory, and instrumental data do not raise suspicion of sepsis in necrotic collections, the FNAB should not be performed, owing to a potential risk of secondary infection [73-76]. Surgical intervention is required in patients with fluid-necrotic septic collection, also because the septic condition worsens the impairment of general condition and organ failure. On the other hand, not all patients with infected necrosis but without compromise of general conditions and/or organ dysfunction will require urgent intervention [77,78]. This therapeutic choice is based on the purpose to delay the surgical procedure for some weeks when the collection has become walled off [79].

### **2.3. Choice of surgical approach for gatherings**

All therapeutic choices in acute pancreatitis should be connected with the evolution of the disease, which may be very complex. Organ failure (MODS) in the first phase of the disease is usually not related to infection but to SIRS. However, septic complications of disorganized necrotizing tissue can also occur in this phase, with further worsening of disease evolution [80]. The latter phase of the disease is characterized by a counteractive anti-inflammatory response syndrome (CARS). In this phase there is the risk of infected necrosis and organ failure related to infections. Gooszen et al. [81] report three scenarios in the late evolution of severe acute pancreatitis. First is improvement with intensive care after early onset organ failure, but this is followed by deterioration in the third or fourth week, often due to infection of necrosis. Another scenario is clinical impairment without distinct early organ failure, most likely to be caused by infected necrosis in the third or fourth week. In both cases further interventional

procedures should be indicated. Finally, stable early onset organ failure without improvement is also indicated in the second to third week; in this case the verification of collection infection (FNAB, gas bubbles on CECT) can be useful for the programming of surgical intervention.

Sterile pancreatic peripancreatic fluid-necrotic collections require observation and conservative treatment. This choice is based on the physiopathological evolution of necrotizing pancreatitis. The principal characteristic that should be considered is the time of evolution of necrotizing pancreatic gatherings: this period is usually very long, from 24-36 hours up to 12 weeks. This evolution goes through three phases until the resolution or constitution of acute postnecrotic pseudocysts if the collection remains sterile [82]. In the first phase is true pancreatic necrosis with minimal separation of devitalized tissues, with a high solid/liquid ratio. Then comes the transitional pancreatic necrosis, also called the intermediate lesion. Infection can arise in every occurrence of this phase. The following phase is organized pancreatic necrosis with good separation of devitalized tissue within a fluid gathering, with development of a fibrous-granular wall. This last phase can be defined as a walled-off pancreatic necrosis. The acute postnecrotic pseudocyst is the final evolution characterized by the complete separation of the tissues, with a liquid content and fibrous wall. Therefore, in most cases the sterile asymptomatic pancreatic peripancreatic fluid-necrotic gatherings do not need treatment, instead requiring only clinical-instrumental observation by US-CT every 4 to 6 weeks, because the resolution can occur in 8 to 12 weeks in mean. There also exists in the literature extreme data up to 280 days [83] or one year [84]. In the phase of walled-off pancreatic necrosis, infected pancreatic peripancreatic necrotic fluid collections diagnosed by FNAB or gas bubbles on CECT, or suspected infection but with the impairment of general condition, has traditionally been considered an accepted indication for intervention. Based on the evolution of pancreatic peripancreatic necrosis the importance of choice on the timing of intervention is evident. From the data of the literature the almost unanimous conclusion is that the best choice is to delay intervention until the fluid-necrotic collections are encapsulated, and thus called walled-off necrosis. This process is usually completed in 4 to 6 weeks. If, during this evolution process of pancreatic peripancreatic necrosis, the deterioration of general conditions occurs, the administration of broad-spectrum antibiotics can prevent infections and it allows to delay of the surgical procedure. Surgery in the first two weeks from the onset—frequently necrosectomy for infected collections—has a mortality rate of 75% with a gradual decrease to 5% if performed later than four weeks from the onset. Compromise of general condition and multiple organ dysfunction causes a worsening of results [69,85-87]. In spite of the benefit of the postponing intervention, it is not always possible to delay surgery if the general condition of patient deteriorates, because infected collections can worsen organ failure in the first week of pancreatitis [88]. In summary, the better results in the surgical treatment of fluid-necrotic pancreatic gatherings are clearly connected to a suitable time interval—between the onset of symptoms and intervention—for encapsulation of collection and the recovery of general condition of the patient.

The surgical procedure employed in the treatment of pancreatic peripancreatic necrotic gatherings in the last decade showed a progressive evolution to minimally invasive procedures. Nevertheless, in this setting there are no unanimously standardized and accepted

surgical procedures, and so overall there are no clearly defined indications for various surgical procedures. Until a short time ago, an open approach for infected necrotic collection (so called open necrosectomy) was the standard, first choice, surgical procedure. In this open procedure, the laparotomy is followed by complete debridement and necrosectomy and placement of a retroperitoneal lavage system and drains in the lesser sac. The mortality rate of this procedure, reported by Rau, is 25% [89]. Other open procedures are proposed but not commonly adopted, and have uncertain result, such as closed packing with referred mortality 11% [90], and the open abdomen strategy with planned relaparotomies, which has a very high mortality rate (70%) [81]. These results should be considered in a very severe disease scenario.

Recently necrosectomy by a minimally invasive procedure, such as percutaneous minimally invasive retroperitoneal necrosectomy, has been proposed [91]. Moreover the video-assisted retroperitoneal debridement (VARD) [92,93], by the minimally invasive surgical approach, aims to remove only some pieces of less adherent necrosis rather than all parts of the necrosis. In this way we can reduce the risk of bleeding, and the remnant necrotic tissue can be resorbed. This percutaneous procedure can be repeated, and drainage into cavity planned. Further minimally invasive procedures for the treatment of infected pancreatic necrotic collection include:

- Necrosectomy with minimally invasive step-up approach.
- Endoscopic transluminal necrosectomy (ETN).
- Percutaneous drainage.

The step-up approach has been proposed and compared with open necrosectomy in a Dutch multicentre randomised study on acute necrotizing pancreatitis [94]. The comparison showed minor complications with a step-up approach. This procedure consists of percutaneous or transgastric drainage, and then drain-guided necrosectomy if necessary. This procedure, which has been performed in some patients (35%), has achieved stable results only once.

In ETN the endoscopic access is usually transgastric. The procedure has a very low invasivity but there is the need for repeated procedures to remove the necrotic collection [95].

#### **2.4. The global evaluation of this minimally invasive procedure is in progress.**

Finally we have to consider the simple, basic percutaneous drainage of septic necrotic gatherings. The drainage is not necrosectomy but from the perspective of a minimally invasive approach, with a real possibility that the necrotic tissue can be resorbed, the percutaneous catheter drainage can be considered the first therapeutic approach in the case of (suspected or documented) infected necrotic pancreatic gatherings. Percutaneous drainage has been largely employed, but there is no complete therapeutic evaluation of this method. Recently many results of systematic reviews have become available [87]: the technical success rate was 99%, and the number of patients with necrotizing pancreatitis treated with percutaneous drainage alone was high (22-55%). In summary, we can accept that after the first step (percutaneous drainage) of a therapeutic programme for septic necrotic gatherings, if the drainage of the collection is incomplete, it should be necessary to perform a complete necrosectomy. Finally

we can conclude that it is not clear what the best procedure is for the treatment of septic necrotic pancreatic collections. Open necrosectomy remains the last option after the failure of less invasive procedures. A flow-chart of the management of pancreatic peripancreatic gatherings is shown in figure 2.

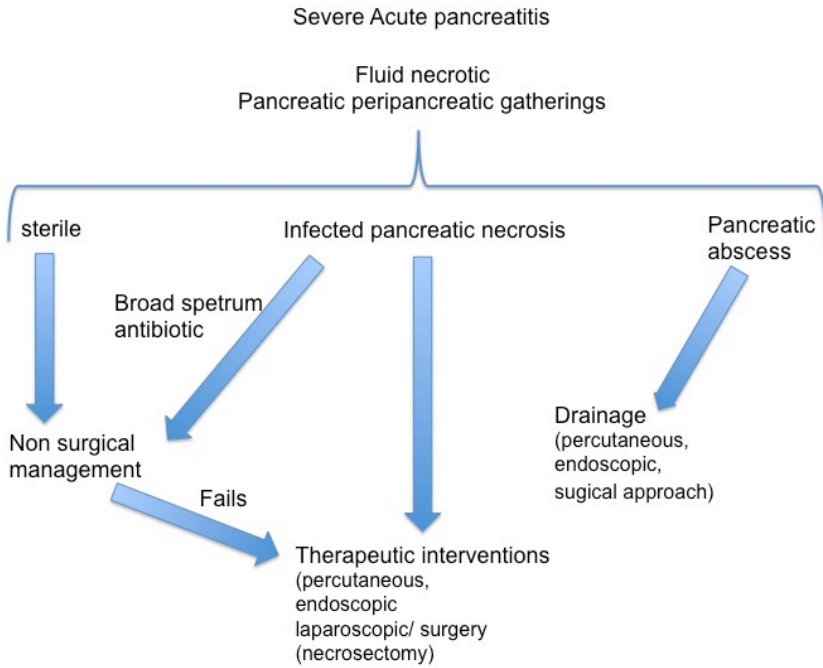


Figure 2. Flow-chart: management of pancreatic-peripancreatic gatherings

Acute postnecrotic pseudocysts are the final evolution of necrotizing pancreatic gatherings, characterized by complete separation of the tissues, with liquid content and a fibrous wall. The incidence of acute pseudocysts is low, at 5-16% [82]. The evolution of a lesion with a fibrous wall can be complete in many weeks (12-16 weeks). Small cysts (<5-6 cm) can be observed for many months without clinical appearance. In some cases there is some spontaneous improvement until the resolution of the pseudocysts [96]. Treatment is required for a pseudocyst larger than 6-7 cm, or one that is symptomatic or persistent over many months. There are various surgical procedures for the treatment of pseudocysts. The pathological characteristic of acute pseudocysts is the connection with pancreatic ducts. In fact simple percutaneous US/CT guided drainage can be often followed by persistent leakage from the drain; other complications of this procedure include infections and the repeated changes required of the drain [97]. Based on the communication of the pseudocysts with pancreatic ducts, all surgical procedures should involve a cystodigestive prolonged connection (anastomosis, fistulas) for the steady drainage of pancreatic secretions. During its development, the pseudocysts establish a

connection with adjacent intestinal organs to which the cyst is adherent: usually the stomach, small intestine, and duodenum. From this perspective there are various possible procedures. Drainage of the pseudocyst by endoscopic techniques has been proposed [98,99]: this is performed by creating a small opening between the cyst and stomach. The disadvantage of this technique is incomplete drainage with recurrence of pseudocysts and infection because the communication can be small and in site not decline. The surgical procedures use the adjacent intestinal organ (stomach, duodenum, small intestine) involved in each case for anastomosis with the cyst: cystogastrostomy, cystojejunostomy, cystoduodenostomy [96].

For cysts located in the body or tail of pancreas the cystojejunostomy or cystogastrostomy is performed depending the development of the cyst above or under the mesocolon. For pseudocysts developed in the head, cystoduodenostomy is usually performed. The same surgical procedures can be performed with a laparoscopic approach with the advantage of the minimal invasiveness.

### 3. Chronic pancreatitis

Chronic pancreatitis is a continuing, progressive inflammatory process of the pancreas, characterized by irreversible changes in the morphology of the gland. The gradual fibrosis of the parenchyma causes the loss of exocrine and endocrine functions. The incidence of chronic pancreatitis ranges from 1.6 to 23 cases per 100,000 population per year worldwide [100, 101]. The incidence and prevalence of chronic pancreatitis is low, and more than 50% are alcohol related. The incidence of the disease appeared to be increasing in past decades [102]. Whereas in acute pancreatitis tissue alteration may be reversible in the oedematous form, chronic pancreatitis is characterized by irreversible tissue changes and exocrine dysfunction. Chronic pancreatitis lies on a protracted inflammation of the pancreas characterized by the permanent alteration of the basic anatomical structure accompanied by functional deficits, even if the cause is eliminated. The cause of chronic disease is stable tissue inflammation by various causes. Therefore, there are multiple hypotheses as to the pathophysiology of chronic pancreatitis: necrosis-fibrosis, toxic-metabolic causes, plug and stone formation, duct obstruction, or sentinel acute pancreatitis event (SAPE) [100]. The pathological features are pancreatic parenchymal fibrosis, duct dilation, and pancreatic stones. Chronic abdominal pain characterizes the clinical appearance of the disease. Acute and chronic diseases are connected based on pathological features: both are characterized by a phlogistic process with autodigestive and/or ordinary varieties, interchangeable with each other but with different development processes [103,104]. Inflammatory processes of pancreatitis are generally characterized by autodigestion, but less frequently ordinary, uncharacteristic interstitial pancreatic phlogosis (as reaction to general disease) without signs of autodigestion can be observed. Both varieties of phlogosis can have an acute or chronic course. The ordinary variety of pancreatitis can transgress to an autodigestive or a chronic progressive variety at any time [105].

### 3.1. Aetiological and nosographic assessment as a guide for surgery in the therapeutic programmes

Chronic pancreatitis, in most cases caused by excessive alcohol consumption, is due to tissue injury by persistent inflammation based on toxic-metabolic hypothesis [106]. The pathologic features are destruction of pancreatic parenchyma, substitution with large fibrosis, and infiltration of inflammatory cells in various degrees [107].

Generally the effect of alcohol is amplified by a high fat diet and smoking [108]. Smoking can be an independent risk factor for the development and progression of chronic pancreatitis. Smoking can have adverse effects on the secretion of pancreatic bicarbonate and water and causes pancreatic calcifications through oxidative stress. Other less common causes of chronic pancreatitis include autoimmune-immunologic causes in autoimmune diseases such as primary autoimmune pancreatitis or associated with Crohn's disease; genetic/hereditary pancreatitis with autosomal dominant or recessive mutations in the cationic trypsinogen gene (PRSSI-SPINK1); severe hypercalcaemia with protein plug obstructive hypothesis; obstructive chronic pancreatitis (pancreatic adenocarcinoma, neuroendocrine tumours, intrapapillary mucinous tumours, annular pancreas, pancreas divisum, etc.); nutritional factor deficiencies; and idiopathic causes (table 8).

Common causes	Less common causes
Alcohol	Severe hypercalcaemia
Tobacco smoking	Autoimmune
	Genetic
	Duct obstruction
	Hyperlipidaemia
	Idiopathic

**Table 8.** Aetiology of chronic pancreatitis

Recurrent episodes of heavy abdominal pain with back bilateral diffusion, but without compromise of general condition, and a history of abnormal alcohol consumption for many years, characterized the clinical appearance of ten patients with chronic pancreatitis. Our patients were subdivided into stage A and B of Amman's classification [109]: six patients in Stage A, initial, characterized by recurrent acute attacks, with mild impairment of pancreatic function; and four patients in Stage B, later, with increasing abdominal pain and more frequent acute attacks, with some complications such as chronic pseudocysts and main pancreatic duct dilation, and impaired pancreatic function. In end-stage disease (none of our patients were in this stage) there are decreases in acute attacks and abdominal pain intensity, and marked impairment of pancreatic function. The diagnosis of chronic pancreatitis is simple in the later stages, but difficult in the initial stages. Laboratory and instrumental (EUS, CT) examinations have confirmed the diagnosis following a EUS-based criterion. The new Rosemont classification [110] of chronic pancreatitis identifies major criteria such as main pancreatic duct calculi and lobularity with honeycombing and hyperechoic foci with shadowing. Minor criteria were

cysts, dilated ducts >3.5 mm, irregular pancreatic duct contour, dilated side branches >1 mm, hyperechoic duct wall, and non-shadowing hyperechoic foci.

In our experience the diagnosis was based on imaging exams with confirmation of the main pancreatic duct and branch ducts being irregularly dilated or having stenosis and calcifications in some ducts. The common pancreatic function tests (focal elastase, fasting blood glucose/oral glucose tolerance tests) do not detect mild or moderate exocrine pancreatic insufficiency. Therefore these tests are subsidiary in the current clinical evaluation of chronic pancreatitis. In chronic pancreatitis the indication of the surgical approach comes after a long clinical evolution of the disease with a well-established diagnosis. In our experience chronic pancreatitis has been treated through an operative therapeutic approach in four patients: direct ductal-enteric drainage (Puestow procedure) in two patients; longitudinal pancreaticojejunostomy combined with a local pancreatic head resection (Frey procedure) in one patient; and pancreatoduodenectomy (Whipple procedure) in one patient. The remaining six patients have undergone conservative treatment that involves control and management of steatorrhea, malnutrition and pain.

### **3.2. Role of surgery in the treatment of chronic pancreatitis**

The pathological patterns of chronic pancreatitis are focused on inflammation and fibrosis of pancreatic parenchyma, stricture, and obstruction of the main and accessory ducts and intraductal calcification [111,112]. The particular histopathological characteristics are areas of acute inflammation and foci of pancreatic cell necrosis. The pain is connected with the foci of parenchymal inflammation and ductal hypertension. Also, the inflammatory damage of the sensory nerves of the pancreas can play a role in the development of the symptoms in chronic pancreatitis [113]. The first question concerns the indications for surgery in chronic pancreatitis: the principal symptom of chronic pancreatitis is abdominal pain. The most severe intractable pain is the cornerstone of surgical indication. The surgical treatment of chronic pancreatitis should be based on the clinical and pathological scenario: two types of surgical procedures are proposable. Decompression procedures with the aim of improving or eliminating ductal hypertension by intestinal anastomotic drainage can be performed. Resectional procedures aim to eliminate areas of chronic inflammation that are especially present in the head of the pancreas. There are also denervation procedures involving neurolysis of the celiac trunk and ganglia; the data from the literature report variable results [114]. The decompression procedure can involve the endoscopic treatment [115]. In the course of chronic pancreatitis, evident ductal dilation can develop as a late complication. The incidence of these chronic pseudocysts is high: 20-40% [85]. The endoscopic procedure aims to perform cystogastrostomy or duodenocystostomy following the development and anatomical connection between the pseudocyst and intestinal organ (stomach or duodenum) [116]. The morbidity of this procedure ranges from 3-11% with no mortality. The endoscopic approach can allow the treatment of the chronic pseudocyst by drainage through the duodenal papilla and ductal system. The procedure develops with selective endoscopic pancreatic sphincterotomy retrograde pancreatography and the positioning of the transpapillary endoprosthesis as drainage. The morbidity ranges from 2-7% with no mortality [116]. If intraductal stones are present, this approach can

allow transluminal stone removal and/or lithotripsy, followed by prolonged pancreatic duct stenting [115-117]. Unfortunately the endoscopic approaches are not always feasible because the anatomic difficulties such as location of the cysts, papillary patency, etc. The surgical management of pancreatic duct stones and stenosis has shown better results than endoscopic treatment [118,119]. The Puestow procedure [120] and its modification of Partington and Rochelle [121] are the standard surgical drainage methods in chronic pancreatitis with dilated ducts. In the original presentation there is the resection of the tail of pancreas, longitudinal incision of the main dilated duct along the body of the pancreas, and invaginating anastomosis with a Roux-en-Y loop of jejunum. The following modification is the elimination of the resection of the pancreatic tail. The immediate results of the procedure show very low mortality (less than 1%) and morbidity (less than 10%) [122]. Pain is relieved in 85-90% of patients; recurrent pain is observed in 30% [123-125].

In some patients with a dilated pancreatic duct, a fibrotic, inflammatory mass may be present in the head of the pancreas. In these patients, surgical approaches that couple drainage and resective procedures can be indicated. These interventions can be defined as 'hybrid' [125] and show numerous variants. In duodenum-preserving pancreatic head resection (DPPHR) proposed by Beger [126], the neck of the pancreas is divided, most of the head is resected sparing the CBD and duodenum, and the procedure is completed by side-to-side pancreato-jejuno-stomy (Roux-en-Y). Berne modification of DPPHR consists of excavation of the head of the pancreas, without division of the pancreatic neck, completed by pancreato-jejuno-stomy (Roux-en-Y) [127]. Frey described the local resection of the head of the pancreas and longitudinal pancreato-jejuno-stomy (LR-LPJ) [128]. Subsequently local resection of the pancreatic head with longitudinal pancreato-jejuno-stomy (Roux-en-Y) by Frey Hamburg modification [129], with the inclusion of the excavation of the central portion of uncinata process, in continuity with the V-shaped excavation of the body along the main pancreatic duct, has been proposed. All these hybrid surgical procedures give results that overlap, with a very low mortality (less than 1%) and a rate of morbidity from 20-30% [125]. Pain relief occurs in 80-85% of patients, also in late control [130].

The resective procedures had a general indication for the prevalence of the chronic phlogistic process in the pancreas parenchyma with lesser duct dilations. Pancreatoduodenectomy, generally called the Whipple procedure, is effective in managing pain in 70-90% of patients. The mortality is less than 5% but the morbidity can reach 40% [131]. Similar results are obtained with pylorus-preserving pancreatoduodenectomy (PPPD). The major problem of these surgical resective procedures is the pancreatic anastomotic leak that can occur with a variable incidence range from 10-30% or more. Although the pancreatic parenchyma in chronic disease generally has a hard consistency, the size of the main duct in the gland with diffuse sclerosis can be very small, at around 2-3 mm, and consequently difficult for anastomosis. Other resectional procedures are also proposed. Distal pancreatectomy, for example, has been proposed for the patients in whom the fibrotic process of the pancreas is located in the body and tail. These procedures have had medium results, resulting in pain relief in 60% of patients [132]. Almost total distal pancreatectomy and total pancreatectomy achieve good relief of abdominal pain but the metabolic consequences are an adverse result [133]. Pancreatectomy

with islet auto-transplantation has been proposed [134] with interesting results but its use is limited by diffusion. A flow-chart of therapeutic management in chronic pancreatitis is shown in figure 3.

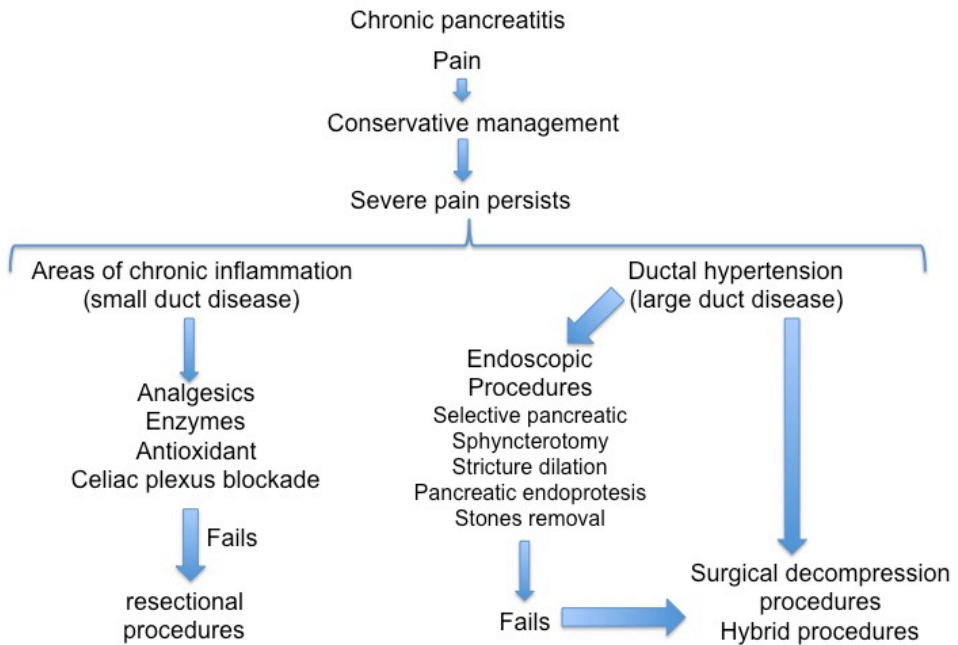


Figure 3. Flow-chart: management of chronic pancreatitis

#### 4. Conclusions

The management of severe acute pancreatitis requires a radical revision. The role of the surgery should be limited to percutaneous drainage of septic-necrotic collections, a procedure that in most cases could reduce the need for surgical intervention. If major surgical interventions are required, these should be as conservative as possible, and minimally invasive approaches are preferred [135].

In summary, chronic pancreatitis with duct obstruction, stones and protein plugs, chronic pseudocysts and abdominal pain exacerbation may be treated with drainage operations. Major resection procedures have infrequent indications based on prevalent phlogistic involvement of pancreatic parenchyma, non-dilated pancreatic ducts, and enlarged pancreatic head.

In conclusion, based on pathological and clinical observations, we can believe that the surgical interventions that couple the drainage of the distal pancreas and resection of the core of the head are procedures with acceptable results in the treatment of chronic pancreatitis.

## Author details

Vincenzo Neri\*

Address all correspondence to: vincenzo.neri@unifg.it

General Surgery-Dept. of Medical and Surgical Sciences-University of Foggia, Italy

## References

- [1] Bassi C, Butturini G. Definition and classification of pancreatitis. In: Blumgart LH et al. (eds). *Surgery of the liver, biliary tract and pancreas*. Saunders Elsevier Philadelphia; 2007:1. p. 685-699.
- [2] Fagenholz PJ, Fernandez del Castillo C, Harris NS et al. Direct medical costs of acute pancreatitis hospitalizations in the United States. *Pancreas* 2007 (4): 302-307.
- [3] Shaheen NJ, Hansen RA, Morgan DR et al. The burden of gastrointestinal and liver diseases. *Am J Gastroenterol* 2006; 101(9): 2128-2138.
- [4] Go VLW, Everhart JE. Pancreatitis in Everhart JE, ed. *Digestive disease in United States: epidemiology and impact*. Washington DC: US Department of Health and Human Services, Public Health Service, National Institutes of Health, National Institute of Diabetes and Digestive and Kidney Diseases; 1994 p. 693. NIH publ. no 94 1447.
- [5] Gullo L, Migliori M, Olah A et al. Acute pancreatitis in five European countries: aetiology and mortality. *Pancreas* 2002; 24:223-227.
- [6] Banks PA, Conwell DL, Toskes PP. The management of acute and chronic pancreatitis. *Gastroenterol Hepatol* 2010; 6:1-16.
- [7] Al Mofleh IA. Severe acute pancreatitis: pathogenetic aspects and prognostic factors. *World J Gastroenterol* 2008; 14(5): 675-84.
- [8] Wang GJ, Gao CF, Wei D et al. Acute pancreatitis: aetiology and common pathogenesis. *World J Gastroenterol* 2009. 15, 1427-1430.
- [9] Lankisch PG, Brener N, Burns A et al. Natural history of acute pancreatitis: a long-term population-based study. *Am J Gastroenterol* 2009; 104:2797-2805.

- [10] Yadav D, O'Connell M, Papachristou GJ. Natural history following the first attack of acute pancreatitis. *Am J Gastroenterol* 2012; 107:1096-1103.
- [11] Banks PA, Bollen TL, Dervenis C, Gooszen HG et al. Classification of acute pancreatitis-2012: revision of the Atlanta classification and definitions by international consensus. *Gut* 2013; 62 (1):102-111.
- [12] Bassi C, Falconi M, Butturini G et al. Early complications of severe acute pancreatitis. In Holzheimer RG, Mannick JA (eds). *Surgical treatment: evidence-based and problem-oriented*. Munich Zuckschwerdt 2001. <http://www.ncbi.nlm.nih.gov/books/NBK6978>.
- [13] Petrov MS, Windsor JA. Classification of the severity of acute pancreatitis: how many categories make sense? *Am J Gastroenterol* 2010;105:75-76.
- [14] Di Fabio F, Abu Hilal M, Johnson CD. Acute pancreatitis: mild, severe or potentially fatal. *Pancreatology* 2011;11:373-375.
- [15] Dellinger EP, Forsmark CE, Lamer P et al. Determinant-based classification of acute pancreatitis severity. An international multidisciplinary consultation. *Ann Surg* 2012;256:875-880.
- [16] Sarr MG. 2012 revision of the Atlanta classification of acute pancreatitis. *Polskie Archiwum Medycyny Wewnętrznej* 2013;123 (3): 118-123.
- [17] Dugernier TL, Laterre PF, Wittebole X et al. Compartmentalization of the inflammatory response during acute pancreatitis: correlation with local and systemic complications. *Am J Respir Crit Care Med* 2003; 168:148-157.
- [18] Mayer J, Rau B, Gansauge F et al. Inflammatory mediators in human acute pancreatitis: clinical and pathophysiological implications. *Gut* 2000; 47:546-552.
- [19] Makhija R, Kingsnorth AN. Cytokine storm in acute pancreatitis. *J Hepatobiliary Pancreat Surg* 2002; 9:401-410.
- [20] Lipsett PA. Serum cytokines, proteins, and receptors in acute pancreatitis: mediators, markers, or more of the same? *Crit Care Med* 2001; 29:1642-1644.
- [21] Pezzilli R, Maldini K, Morselli-Labate AM et al. Early activation of peripheral lymphocytes in human acute pancreatitis. *J Clin Gastroenterol* 2003; 36: 360-363.
- [22] Poch B, Gansauge F, Rau B et al. The role of polymorphonuclear leukocytes and oxygen-derived free radicals in experimental acute pancreatitis: mediators of local destruction and activators of inflammation. *FEBS Letters* 1999; 461: 268-272.
- [23] Sakai Y, Masamune A, Satoh A et al. Macrophage migration inhibitory factor is a critical mediator of severe acute pancreatitis. *Gastroenterology* 2003; 124:725-736.
- [24] Guzman EA, Rudnicki M. Intricacies of host response in acute pancreatitis. *J Am Coll Surg* 2006; 202:509-519.

- [25] Deitch EA, Xu DZ, Qi L, et al. Bacterial translocation from the gut impairs systemic immunity. *Surgery* 1991; 109: 269-276.
- [26] Neri V, Lapolla F, Di Lascia A et al. Defining a therapeutic program for recurrent acute pancreatitis patients with unknown etiology. *Clinical Med Insights: Gastroenterology* 2014; 7: 1-7.
- [27] Heider TR, Brown AB, Grimm IS et al. Endoscopic sphincterotomy permits internal laparoscopic cholecystectomy in patients with moderately severe gallstone pancreatitis. *J Gastro Surg* 2006; 10: 1-5.
- [28] Nealon WH, Bawdamiak J, Walser EM. Appropriate timing of cholecystectomy in patients who present with moderate to severe gallstone pancreatitis associated acute pancreatitis with peripancreatic fluid collections. *Ann Surg* 2004; 239: 741-751.
- [29] Balthazar EJ, Robinson DL, Megibow AJ et al. Acute pancreatitis: value of CT in establishing prognosis. *Radiology* 1990; 174: 331-336.
- [30] Balthazar EJ, Freeny PC, Vansonnenberg E. Imaging and intervention in acute pancreatitis. *Radiology* 1994; 193 (2): 297-306.
- [31] Balthazar EJ. Acute pancreatitis: assessment of severity with clinical and CT evaluation. *Radiology* 2002; 223: 603-613.
- [32] Beger HG, Rau BM. Severe acute pancreatitis: clinical course and management. *World J Gastroenterol* 2007; 13 (38): 5043-5051.
- [33] Van Baal MC, Besselink MG, Bakker OJ et al. Timing of cholecystectomy after mild biliary pancreatitis. A systematic review. *Ann Surg* 2012; 255: 860-866.
- [34] Neri V. Mild biliary pancreatitis: interval (delayed) cholecystectomy is associated with readmission for recurrent biliary events. *Evid Based Med* 2013; 18:e11-doi: 10.1136/eb-2012-100847.
- [35] Freeman ML. Adverse outcomes of endoscopic retrograde cholangiopancreatography. *Rev Gastroenterol Disord* 2002; 2: 147-168.
- [36] Davis WZ, Cotton PB, Arias R et al. ERCP and sphincterotomy in the context of laparoscopic cholecystectomy: academic and community practice patterns and results. *Am J Gastroenterol* 1997; 92(4): 597-601.
- [37] Andriulli A, Loperfido S, Napolitano G et al. Incidence rates of post-ERCP complications: a systematic survey of prospective studies. *Am J Gastroenterol* 2007; 102 (8): 1781-1788.
- [38] Tenner S, Bailie J, Dewitt J et al. American College of Gastroenterology guidelines: management of acute pancreatitis. *Am J Gastroenterol* Jul. 30 2013; 1-16 doi: 10.1038/ajg2013.218.

- [39] Haydock MD, Mittal A, Van den Heever M et al. National survey of fluid therapy in acute pancreatitis. Current practice lacks a sound evidence base. *World J Surg* Oct 2013; vol./is.37/10(2428-35),0364-2313.
- [40] Neri V, Fersini A, Ambrosi A. et al. Mild-moderate acute biliary pancreatitis: role of magnetic resonance cholangiopancreatography in preparation of cholecystectomy. *Pancreas* 2009; 38(6): 717.
- [41] Neri V, Fersini A, Ambrosi A et al. Diagnostic evaluation prior to cholecystectomy in mild-moderate acute biliary pancreatitis. *Ann It Chir* 2009; 80: 363-367.
- [42] Fan ST, Lai EC, Mok FP et al. Early treatment of acute biliary pancreatitis by endoscopic papillotomy. *N Engl J Med* 1993; 328(4): 228-32.
- [43] Folsch UR, Nitsche R, Ludtke R et al. Early ERCP and papillotomy compared with conservative treatment of acute biliary pancreatitis. The German Study Group on Acute Biliary Pancreatitis. *N Engl J Med* 1997; 336(4):237-242.
- [44] Neoptolemos JP, Carr-Locke DL, London NJ et al. Controlled trial of urgent endoscopic retrograde cholangiopancreatography and endoscopic sphincterotomy versus conservative treatment of acute pancreatitis due to gallstones. *Lancet* 1988; 2(8618): 979-983.
- [45] Kroh M, Chand B. Choledocholithiasis, endoscopic retrograde cholangiopancreatography, and laparoscopic common bile duct exploration. *Surg Clin North Am* 2008; 88(5):1019-1031.
- [46] Petrov MS. Early use of ERCP in acute biliary pancreatitis without jaundice: an unjaundiced view. *JOP* 2009; 10(1):1-7.
- [47] Kopetanos DJ. ERCP in acute biliary pancreatitis. *World J Gastrointest Endosc* 2010; 2(1):25-28.
- [48] Vitale GC, Davis BR, Zavaleta C et al. Endoscopic retrograde cholangiopancreatography and histopathology correlation for chronic pancreatitis. *Am Surg* 2009; 75(8): 649-653.
- [49] Petrov MS, van Santvoort HC, Besselink MG et al. Early endoscopic retrograde cholangiopancreatography versus conservative management in acute biliary pancreatitis without cholangitis: a meta-analysis of randomized trials. *Ann Surg* 2008; 247(2): 250-257.
- [50] Moretti A, Papi C, Aratari A et al. Is early endoscopic retrograde cholangiopancreatography useful in the management of acute biliary pancreatitis? A meta-analysis of randomized controlled trials. *Dig Liver Dis* 2008; 40(5):379-385.
- [51] Acosta JM, Katkhouda N, Debian KA et al. Early ductal decompression versus conservative management for gallstones pancreatitis with ampullary obstruction: a prospective randomized clinical trial. *Ann Surg* 2006; 243(1): 33-40.

- [52] van Santvoort HC, Besselink MG, de Vries AC et al. Early endoscopic retrograde cholangiopancreatography in predicted severe acute biliary pancreatitis: a prospective multicenter study. *Ann Surg* 2009; 250(1):68-75.
- [53] Gardner TB, Vege SS, Pearson RK et al. Fluid resuscitation in acute pancreatitis. *Clin. Gastroenterol. Hepatol.* 2008; 6:1070-1076.
- [54] Leppaniemi A. Surgical management of abdominal compartment syndrome; indications and techniques. *Scandinavian journal of trauma, resuscitation and emergency medicine* 2009;17:17-21.
- [55] Mentula P, Leppaniemi A. Timely interventions in severe acute pancreatitis are crucial for survival. *World Journal of Emergency Surgery* 2014; 9:15-24.
- [56] De Waele JJ, Hoste EA, Malbrain ML. Decompressive laparotomy for abdominal compartment syndrome. A critical analysis. *Crit. Care* 2006; 10:R51.
- [57] Leppaniemi A, Mentula P, Hienonen P et al. Transverse laparostomy is feasible and effective in the treatment of abdominal compartment syndrome in severe acute pancreatitis. *World J Emerg Surg* 2008; 3:6.
- [58] Petersson U, Acosta S, Bjorck M. Vacuum assisted wound closure and mesh-mediated fascial traction. A novel technique for late closure of the open abdomen. *World J Surg* 2007;31:2133-2137.
- [59] Opie EL. The aetiology of acute hemorrhagic pancreatitis. *Bull Johns Hopkins Hosp* 1901; 12; 182-188.
- [60] Ranson JH, Pasternack BS. Statistical methods for quantifying the severity of clinical acute pancreatitis. *J Surg Res* 1977; 22:79-91.
- [61] Blamey SL, Imrie CW, O'Neill J et al. Prognostic factors in acute pancreatitis. *GUT* 1984;25:1340-1346.
- [62] Knans WA, Draper EA, Wagner DP et al. APACHE II: a severity of disease classification system. *Crit Care Med* 1985;13:818-829.
- [63] Neoptolemos JP, Kempainen EA, Mayer JM et al. Early prediction of severity in acute pancreatitis by urinary trypsinogen activation peptide: a multicenter study. *Lancet* 2000; 355: 1955-1960.
- [64] Viedma JA, Perez-Mateo M, Agullo J et al. Inflammatory response in the early prediction of severity in human acute pancreatitis. *Gut* 1994; 35: 822-827.
- [65] De Madeira E, Soler Sola G, Sancez-Paya J et al. Influence of fluid therapy on the prognosis of acute pancreatitis: a prospective cohort study. *Am J Gastroenterol* 2011; 106:1843-1850.

- [66] Van Santvoort HC, Besselink MG, De Vries AC et al. Early endoscopic retrograde cholangiopancreatography in predicted severe acute biliary pancreatitis: a prospective multicenter study. *Ann Surg* 2009; 250:68-75.
- [67] Howard TJ. Acute and chronic pancreatitis in Gastrointestinal tract and abdomen ACS Surgery: principles and practice 2013; 11/13. Decker Intellectual Properties doi 10.2310/7800.1151.
- [68] Walser EM, Nealon WH, Marrognin S et al. Sterile fluid collections in acute pancreatitis: catheter drainage versus simple aspiration. *Cardiovasc Intervent Radiol* 2006; 29(1): 102-107.
- [69] Zerem E, Imamovic G, Omerovic S et al. Randomized controlled trial on sterile fluid collections management in acute pancreatitis: should they be removed? *Surg Endosc* 2009; 23(12): 2770-2777.
- [70] Karimgani J, Porter KA, Langevin RE, Banks PA. Prognostic factors in sterile pancreatic necrosis. *Gastroenterology* 1992;103:1636-1640.
- [71] Beger HG, Buchler M, Bittner R et al. Necrosectomy and postoperative local lavage in necrotizing pancreatitis. *Br J Surg* 1988; 75: 207-212.
- [72] Tsiotos GG, Luque Le, Sorcide JA et al. Management of necrotizing pancreatitis by repeated operative necrosectomy using a zipper technique. *Am J Surg* 1998; 175: 91-98.
- [73] Rau B, Pralle Y, Mayer JM et al. Role of ultrasonography guided fine-needle aspiration cytology in the diagnosis of infected pancreatic necrosis. *Br J Surg* 1998;85:179-184.
- [74] Gerzof SG, Banks PA, Robbins AH et al. Early diagnosis of pancreatic infection by computed tomography-guided aspiration. *Gastroenterology* 1987; 93:1315-1320.
- [75] Banks PA, Gerzof SG, Langevin RE et al. CT-guided aspiration of suspected pancreatic infection: bacteriology and clinical outcome. *Int J pancreatol* 1995;18:265-270.
- [76] Hiatt JR, Fink AS, King W et al. Percutaneous aspiration of peripancreatic fluid collections: a safe method to detect infection. *Surgery* 1987; 101: 523-530.
- [77] Buter A, Imrie CW, Carter CR et al. Dynamic nature of early organ dysfunction determines outcome in acute pancreatitis. *Br J Surg* 2002; 89:298-302.
- [78] McKay CJ, Imrie CW. The continuing challenge of early mortality in acute pancreatitis. *Br J Surg* 2004; 91:1243-1244.
- [79] Carter CR, McKay CJ. Management in necrotizing pancreatitis. In:KJ Bland et al. (eds). *Surgery of the pancreas and spleen* Springer Verlag London Limited; 2001. p 3-15.

- [80] Petrov MS, Shanbhag S, Chakreborty M et al. Organ failure and infection of pancreatic necrosis as determinants of mortality in patients with acute pancreatitis. *Gastroenterology* 2010; 139:813-820
- [81] Gooszen HG, Besselink MG, van Santvoort HC et al. Surgical treatment of acute pancreatitis. *Langerbecks Arch Surg* 2013; 398:799-806.
- [82] Carter CR. Percutaneous management of necrotizing pancreatitis. *HPB* 2007; 9(3): 235-239.
- [83] Dulcenserie R, Yzet T, Ducroix JP. Prophylactic antibiotics in treatment of severe acute alcoholic pancreatitis. *Pancreas* 1996;13:198-201.
- [84] Maringhini A, Uomo G, Patti R et al. Pseudocysts in acute nonalcoholic pancreatitis: incidence and natural history. *Dig Dis Sci* 1999; 44(8):1669-1673.
- [85] Mier J, Luque-de Leon E, Castillo A et al. Early versus late necrosectomy in severe pancreatitis. *Am J Surg* 1997; 173 (2): 71-75.
- [86] Besselink MG, van Santvoort HC, Bakker OJ et al. Draining sterile fluid collections in acute pancreatitis? *Primum non nocere. Surg Endosc* 2010;25(1):331-332.
- [87] Van Baal Mc, van Santvoort HC, Bollen TL et al. Systematic review of percutaneous catheter drainage as primary treatment for necrotizing pancreatitis. *Brit J Surg* 2011; 98(1): 18-27.
- [88] Besselink MG, van Santvoort HC, Boermeester MA et al. Timing and impact of infections in acute pancreatitis. *Br J Surg* 2009;96 (3):267-273.
- [89] Rau B, Bothe A, Beger HG. Surgical treatment of necrotizing pancreatitis by necrosectomy and closed lavage: changing patient characteristics and outcome in a 19-year, single center series. *Surgery* 2005; 138 (1):28-39.
- [90] Rodriguez JR, Razo AO, Targarona J et al. Debridement and closed packing for sterile or infected necrotizing pancreatitis: insights into indications and outcomes in 167 patients. *Ann Surg* 2008; 247(2): 294-299.
- [91] Raraty MG, Halloran CM, Dodd S et al. Minimal access retroperitoneal pancreatic necrosectomy: improvement in morbidity and mortality with a less invasive approach. *Ann Surg* 2010; 251(5): 787-793.
- [92] Horvath K, Freeny P, Escallon J et al. Safety and efficacy of video-assisted retroperitoneal debridement for infected pancreatic collections: a multicenter, prospective, single-arm phase 2 study. *Arch Surg* 2010; 145(9): 817-825.
- [93] van Santvoort HC, Besselink MG, Horvath KD et al. Videoscopic assisted retroperitoneal debridement in infected necrotizing pancreatitis. *HPB* 2007; 9(2): 156-159.
- [94] van Santvoort HC, Besselink MG, Bakker OJ et al. A step-up approach or open necrosectomy for necrotizing pancreatitis. *N Engl J Med* 2010; 362 (16): 1491-1502.

- [95] Bakker OJ, van Santvoort HC, van Brunshot S et al. Endoscopic transgastric vs surgical necrosectomy for infected necrotizing pancreatitis: a randomized trial. *JAMA* 2012; 307 (10): 1053-1061.
- [96] Werner J, Warshaw A. Cystic disease of the pancreas pseudocysts, postinflammatory cystic fluid collections and other non-neoplastic cysts. In: Trede M, Carter D (eds) *Surgery of the pancreas*. 2<sup>nd</sup> Ed. Churchill Livingstone New York ; 1997. p. 405-415.
- [97] Nealon W, Walser E. Main pancreatic duct anatomy can direct choice of modality for treating pancreatic pseudocysts. *Ann Surg* 2002; 235:751-758.
- [98] Ferrucci J, Muller P: Interventional approach to pancreatic fluid collections. *Radiol Clin North Ann* 2003; 41:1217-1226.
- [99] Naoum E, Zavos A, Goudis K et al. Pancreatic pseudocysts: 10 years of experience. *J Hepatobil Pancreat Surg* 2003; 10: 373-376.
- [100] Whitcomb DC. Hereditary pancreatitis: a model for understanding the genetic basis of acute and chronic pancreatitis. *Pancreatology* 2001; 1:565-570.
- [101] Schneider A, Whitcomb DC. Hereditary pancreatitis: a model for inflammatory diseases of the pancreas. *Best Pract Res Clin Gastroenterol* 2002; 16 (3) : 347-363.
- [102] Yadav D, Timmons L, Benson JT et al. Incidence, prevalence and survival of chronic pancreatitis: a population based study. *Am J Gastroenterol* 2011; 106 (12): 2209.
- [103] Bassi C, Butturini G. Definition and classification of pancreatitis. In: Blumgart LH et al. (eds). *Surgery of the Liver, biliary tract and pancreas*. Saunders Elsevier Philadelphia; 2007:1. p. 685-699.
- [104] Noigaard C, Becker U, Matzen P et al. Progression from acute to chronic pancreatitis: prognostic factors, mortality and natural course. *Pancreas* 2011; 40: 1195-1200.
- [105] Remmele W. Exokrines Pankreas. In: W Remmele (Hrsg). *Pathologie Springer Verlag Berlin*; 1997. p. 335-390.
- [106] Ammann RW. The natural history of alcoholic chronic pancreatitis. *Intern Med* 2001; 40: 368-375.
- [107] Witt H, Apte MV, Keim V et al. Chronic pancreatitis: challenges and advances in pathogenesis, genetics, diagnosis and therapy. *Gastroenterology* 2007; 132:1557-1573.
- [108] Yadav D, Whitcomb DC. The role of alcohol and smoking in pancreatitis. *Nat Rev Gastroenterol Hepatol* 2010; 7(3):131-145).
- [109] Amman RW. A clinically based classification system for alcoholic chronic pancreatitis: summary of an international workshop on chronic pancreatitis. *Pancreas* 1997; 14: 215-221.

- [110] Catalano MF, Sahai A, Levy M et al. EUS-based criteria for the diagnosis of chronic pancreatitis: the Rosemont classification. *Gastrointestinal endoscopy* 2009; 69 (7): 1251-1261.
- [111] Fisher WE, Andersen DK, Bell RH Jr. The Pancreas. In: Brunicaudi FC, Andersen Dk, Billian TR et al.(eds) *Schwartz's Principles of Surgery* 8<sup>th</sup> Ed. McGraw-Hill New York; NY 2005. p.1221-1296.
- [112] Proca DM, Ellison EC, Hibbert D et al. Major pancreatic resections for chronic pancreatitis. *Arch Pathol Lab Med* 2001; 125: 1051-1054.
- [113] Bockman DE, Buchler M. Pain mechanisms. In: Beger HG, Warshaw AL, Buchler MW (eds). *The Pancreas*. Blackwell-Science London; 1998. p.698.
- [114] Gress F, Schmitt C, Scherman S et al. A prospective randomized comparison of endoscopic ultrasound and computed tomography guided celiac plexus block for managing chronic pancreatitis pain. *Am J Gastroenterol* 1999; 94:900-905.
- [115] Eleftheriadis N, Dinu F, Delhay M. Long-term outcome after pancreatic stenting in severe chronic pancreatitis. *Endoscopy* 2005; 37:223-230.
- [116] Binmoeller KF, Sochendra N. Endoscopic ultrasonography in the diagnosis and treatment of pancreatic pseudocysts. *Gastrointest Endosc Clin N Am* 1995; 5: 805-816.
- [117] Vitale GC, Cothron K, Vitale EA et al. Role of pancreatic duct stenting in the treatment of chronic pancreatitis. *Surg Endosc* 2004; 18: 1431-1434.
- [118] Dite P, Ruzicka M, Zboril V et al. A prospective, randomized trial comparing endoscopic and surgical therapy of chronic pancreatitis. *Endoscopy* 2003; 35: 553-558.
- [119] Cahen DL, Gouma Dj, Nio Y et al. Endoscopic versus surgical drainage of the pancreatic duct in chronic pancreatitis. *N Engl J Med* 2007;356: 676-684.
- [120] Puestow CB, Gillesby WJ. Retrograde surgical drainage of pancreas for chronic relapsing pancreatitis. *AMA Arch Surg* 1958; 76:898-907.
- [121] Partington PF, Rochelle RE. Modified Puestow procedure for retrograde drainage of the pancreas duct. *Ann Surg* 1960; 152:1037-1043.
- [122] Izbiki JR et al. Surgical treatment of chronic pancreatitis and quality of life after operation. *Surg Clin North Am* 1999, 79:913-944.
- [123] Brandley EC III. Long term results of pancreatojejunostomy in patients with chronic pancreatitis. *Am J Surg* 1987; 153:207-213.
- [124] Mannel A, Adson MA, Mc Ierath DC et al. Surgical management of chronic pancreatitis: long-term results in 141 patients. *Br J Surg* 1988; 75:467-472.
- [125] Andersen DK, Frey CF. The evolution of the surgical treatment of chronic pancreatitis. *Ann Surg* 2010; 251:18-32.

- [126] Beger HG, Schlosser W, Friess HM et al. Duodenum preserving head resection in chronic pancreatitis changes the natural course of the disease: a single center 26 year experience. *Ann Surg* 1999; 230:512-519.
- [127] Gloor B, Friess H, Uhl W et al. A modified technique of the Beger and Frey procedure in patients with chronic pancreatitis. *Dig Surg* 2001; 18:21-25.
- [128] Frey CF, Smith GJ. Description and rationale of a new operation for chronic pancreatitis. *Pancreas* 1997; 2:701-707.
- [129] Izbiki JR, Bloechle C, Broering DC et al. Longitudinal V-shaped excision of the ventral pancreas for small duct disease in severe chronic pancreatitis: prospective evaluation of a new surgical procedure. *Ann Surg* 1998; 227:213-219
- [130] Strate T, Taherpour Z, Bloechle C et al. Long-term follow up of a randomized trial comparing the Beger and Frey procedures for patients suffering from chronic pancreatitis. *Ann Surg* 2005;241:591-598.
- [131] Russell RC, Theis BA. Pancreatoduodenectomy in the treatment of chronic pancreatitis. *World J Surg* 2003; 27:1203-1210.
- [132] Brancatisano RP, Williamson RL. Distal pancreatectomy with or without splenectomy. In: Beger HG, Warshaw AL, Buchler MN (eds) *The Pancreas*. Blackwell-Science London; 1998. p. 854.
- [133] Andersen DK. Mechanisms and emerging treatments of the metabolic complications of chronic pancreatitis. *Pancreas* 2007; 35:1-15.
- [134] Najarian JS, Sutherland DE, Baumgartner D et al. Total or near total pancreatectomy and islet autotransplantation for the treatment of chronic pancreatitis. *Am Surg* 1980; 192:526-542
- [135] Dutch Pancreatitis Study Group, van Santvoort HC, Bakker OJ et al. A conservative and minimally invasive approach to necrotizing pancreatitis improves outcome. *Gastroenterology* 2011; 141 (4): 1254-1263.

