

Department of General Thoracic and Esophageal Surgery,
Heart and Lung Center
Helsinki University Hospital, Helsinki, Finland

And

Department of Gastrointestinal Surgery,
Abdominal Center
Helsinki University Hospital, Helsinki, Finland

Doctoral Program in Clinical Research
University of Helsinki
Helsinki, Finland

Esophageal Adenocarcinoma: Pathogenesis, Prevention, and Prognosis

Tuuli Kauttu

ACADEMIC DISSERTATION

To be presented, with the permission of the Faculty of Medicine of the University of Helsinki, for public examination in lecture room 2, Biomedicum, on 9th June 2017, at 12 noon.

Helsinki 2017

Supervised by: Professor h.c. Jarmo A. Salo, MD, PhD
University of Helsinki

Professor Pauli Puolakkainen, MD, PhD
University of Helsinki

Reviewed by: Docent Juha Saarnio, MD, PhD
University of Oulu

Docent Paulina Salminen, MD, PhD
University of Turku

Opponent: Professor Paul Schneider
University of Köln, Germany

ISBN 978-951-51-3201-7 (paperback)

ISBN 978-951-51-3202-4 (PDF)

Unigrafia

Helsinki 2017

Table of contents

List of original publications	7
Abbreviations	8
Abstract	10
1 Introduction	12
2 Review of the literature	14
2.1 Functional anatomy and histology of the lower esophagus and gastric cardia	14
2.2 Gastroesophageal reflux disease (GERD)	15
2.2.1 The pathophysiology of GERD	15
2.2.2 Epidemiology of GERD	15
2.2.3 GERD symptoms	16
2.2.4 Endoscopic classification and severity of GERD	16
2.2.5 Other diagnostic methods	16
2.3 Barrett's esophagus (BE)	17
2.3.1 BE definition	17
2.3.2 BE epidemiology	18
2.3.3 The origin of BE	19
2.4 Risk factors for GERD, BE, and esophageal adenocarcinoma (EAC)	19
2.5 Endoscopic surveillance of BE	21
2.6 Barrett's dysplasia	21
2.7 Risk for progression of BE and associated dysplasia	22
2.8 Treatment of Barrett's dysplasia	22
2.9 Esophageal adenocarcinoma	23
2.9.1 Diagnosis of EAC	23
2.9.2 EAC incidence	23

2.9.3 Treatment of EAC	23
2.9.4 Lymph node retrieval and chemoradiotherapy	24
2.9.5 Complications of surgery	24
2.9.6 Survival of EAC	25
2.10 Adenocarcinoma of the gastroesophageal junction	25
2.11 Treatment of GERD	26
2.11.1 Lifestyle changes	26
2.11.2 Medical treatment	27
2.11.3 Surgical treatment	27
2.11.3.1 Indications	27
2.11.3.2 Antireflux surgery techniques	27
2.11.3.3 Results	29
2.11.4 Effect of GERD treatment on EAC development	30
2.11.4.1 Antireflux medication	30
2.11.4.2 Antireflux surgery	30
2.12 Endoscopic treatment of BE with or without dysplasia	31
2.12.1 Endoscopic resection	31
2.12.2 Ablation	32
2.12.2.1 Efficacy of ablation	33
2.12.2.2 EAC risk after ablation	34
2.12.2.3 Intestinal metaplasia buried under squamous epithelium	34
2.13 Molecular biology of GERD, BE, and EAC	35
2.13.1 Biomarkers	35
2.13.2 Caudal-related homeobox gene 2 (Cdx2)	36
2.13.3 Inflammation and oxidative stress	37
2.13.4 ADAMs	38

2.13.5 c-MYC and CIP2A	39
3 Aims of the study	40
4 Patients, materials, and methods	41
4.1 Patients and materials	41
4.2 Methods	42
4.2.1 Acquisition of clinical data	42
4.2.2 Acquisition of tissue samples	43
4.2.3 Histologic analysis	43
4.2.4 Oxidative stress analysis	43
4.2.5 mRNA quantification	43
4.2.6 Protein quantification	44
4.2.7 Statistical analysis	45
5 Results	46
5.1 ADAM expression profile in GERD and in EAC	46
5.1.1 ADAM expression in cell lines	46
5.1.2 ADAM expression in human samples	47
5.2 CIP2A and c-MYC expression in EAC	49
5.3 Long-term effects of laser ablation for BE	51
5.4 EAC after antireflux surgery	53
6 Discussion	56
6.1 ADAMs in GERD and EAC	56
6.2 CIP2A in EAC	58
6.3 Surgical treatment of GERD in preventing EAC – why does it fail?	59
6.4 Endoscopic eradication of BE	61
7 Summary	64
8 Conclusions	65

Acknowledgements	66
References	69
Original publications	90

List of original publications

Reprinted with the rightsholders' permission, and referred to in the text by their Roman numerals.

- I Kauttu T, Mustonen H, Vainionpää S, Krogerus L, Ilonen I, Räsänen J, Salo J, Puolakkainen P. Disintegrin and metalloproteinases (ADAMs) expression in gastroesophageal reflux disease and in esophageal adenocarcinoma. *Clin Transl Oncol.* 19:58-66, 2017.
- II Rantanen T, Kauttu T, Åkerla J, Honkanen T, Krogerus L, Salo J, Paavonen T, Oksala N. CIP2A expression and prognostic role in patients with esophageal adenocarcinoma. *Med Oncol.* 30:684, 2013.
- III Kauttu T, Räsänen J, Krogerus L, Sihvo E, Puolakkainen P, Salo JA. Long-term results of ablation with antireflux surgery for Barrett's esophagus: a clinical and molecular biologic study. *Surg Endosc.* 26:1892-7, 2012.
- IV Kauttu T, Rantanen T, Sihvo E, Räsänen J, Puolakkainen P, Salo JA. Esophageal adenocarcinoma arising after antireflux surgery: a population-based analysis. *Eur J Cardiothorac Surg.* 40:1450-4, 2011.

Abbreviations

AC	adenocarcinoma
ADAM	a disintegrin and metalloproteinase
AKT	protein kinase B
AR	antireflux surgery
BE	Barrett's esophagus
Cdx2	caudal-related homeobox gene 2
CIP2A	cancerous inhibitor of protein phosphatase 2A
EAC	esophageal adenocarcinoma
EMR	endoscopic mucosal resection
ER	endoscopic resection
ERD	erosive reflux disease
ESD	endoscopic submucosal dissection
GAPDH	glyceraldehyde-3-phosphate dehydrogenase
GEJ	gastroesophageal junction
GERD	gastroesophageal reflux disease
GSH	glutathione
HGD	high-grade dysplasia
H2RA	histamine2-receptor antagonist
IHC	immunohistochemistry
IM	intestinal metaplasia
IMC	intramucosal carcinoma
LES	lower esophageal sphincter
LGD	low-grade dysplasia
MIE	minimally invasive esophagectomy
MP	myeloperoxidase
mRNA	messenger ribonucleic acid
Nd-YAG laser	neodymium:yttrium-aluminum-garnet laser
NERD	non-erosive reflux disease
NF- κ B	nuclear factor- κ B
NSAID	non-steroidal anti-inflammatory drug
OR	odds ratio
PDT	photodynamic therapy
PPI	proton pump inhibitor
PP2A	protein phosphatase 2A
QOL	quality of life
RFA	radiofrequency ablation
RNS	reactive nitrogen species
ROS	reactive oxygen species
RT-PCR	reverse transcription polymerase chain reaction
SCJ	squamo-columnar junction
SEM	standard error of mean
SIR	standardized incidence ratio

SOD	superoxidedismutase
TLESR	transient lower esophageal sphincter relaxation
TMA	tissue microarray
8-OHdG	8-hydroxydeoxyguanosine

Abstract

Background: Esophageal adenocarcinoma (EAC) is a deadly cancer with an increasing incidence in Western countries during recent decades. Risk factors for EAC include obesity, smoking, increasing age, male gender, gastroesophageal reflux disease (GERD), and its possible sequel, Barrett's esophagus (BE). Medical or surgical treatment of GERD has not proven protective against EAC. The eradication of BE, combined with reflux suppression, is also unable to provide adequate EAC prevention. No long-term results are available regarding the effects of the most common BE ablation method, radiofrequency ablation (RFA). The origin of BE is still disputed, and despite active research, the molecular pathogenesis of EAC remains unknown. Consequently, no clinically validated marker molecules exist.

Aims: This study was undertaken 1) to explore the expression of molecules (a disintegrin and metalloproteinases, ADAMs) important for cellular signaling, carcinogenesis, and inflammation, in GERD and in EAC, 2) to investigate the role of the oncogene CIP2A and the associated oncogene c-MYC in EAC and EAC prognosis, 3) to evaluate the long-term effects of BE ablation on prevention of carcinogenesis at both the clinical and the molecular level, and 4) to assess both the possible reasons for EAC development after antireflux surgery and the incidence of EAC after antireflux surgery at population level in Finland.

Patients and methods: The possible importance of ADAM molecules for EAC was investigated by determining the expression of ADAMs 9, 10, 12, 17, and 19 in esophageal cell lines (mRNA and protein levels) and in patient samples at the different stages of GERD from esophagitis to EAC compared to samples from normal controls. Molecular characteristics of EAC were further investigated in terms of expression of the oncogene CIP2A, together with the interrelated c-MYC in EAC patients from two Finnish university hospital districts in 1990–2007. Their expression was measured by immunohistochemistry in tissue microarray blocks, and correlated with clinicopathologic characteristics and prognostic factors. The long-term follow-up of the neosquamous esophageal mucosa and the patients' clinical status was defined in 18 patients after Nd-YAG-laser ablation of BE and antireflux surgery during 1992-2005. Prevalence of residual BE was determined, as were the properties of the neosquamous epithelium in terms of its oxidative stress, intestinal differentiation, and potential for malignancy (p53 expression). EAC occurring despite prior antireflux surgery was investigated by identifying all the patients diagnosed with EAC and with a previous history of antireflux surgery in Finland during 1980-2006 (the Finnish Cancer Registry, the National Institute for Health and Welfare, Statistics Finland). All of these patient records were evaluated for identifying factors possibly associated with the occurrence of EAC after antireflux surgery. The standardized incidence ratio of EAC after antireflux surgery was calculated in the Finnish Cancer Registry.

Results: In EAC cell lines, both ADAM9 mRNA and protein expression was increased. In human samples, ADAM9 expression was increased in EAC, and at mRNA level, also in BE and BE with dysplasia. All stages from GERD to EAC exhibited changes in ADAM expression. The oncogenes CIP2A and c-MYC showed frequent expression in EAC (moderate or strong positivity for CIP2A in 78% and for c-MYC in 94%), but neither CIP2A nor c-MYC expression was associated with survival.

At the mean follow-up of eight years after BE ablation with combined antireflux surgery, of the 18 patients, macroscopic BE was detectable in 6 (33%) and intestinal metaplasia at histology in 8 (44%). The 8-hydroxydeoxyguanosine (8-OHdG) and superoxidedismutase (SOD) levels were elevated in the neosquamous epithelium as compared to controls' levels. Myeloperoxidase (MP) activity and glutathione (GSH) levels were normal. No abnormal caudal-related homeobox gene 2 (Cdx2)- or p53 expression was detectable in the neosquamous mucosa. Of the 1035 EAC patients diagnosed in Finland during 1980-2006, previous antireflux surgery had been performed for 53 (5.1%). In these patients, BE (45%), endoscopic esophagitis (77%), and hiatal hernia (75%) were frequent findings prior to antireflux surgery. Postoperatively, an additional 34% of the patients were found to have BE, leading to a histologically confirmed BE diagnosis in 79%. Patients with an intact fundoplication developed EAC earlier (mean 6.4 years) than those with a functionally failed fundoplication (mean 11.2 years). The standardized incidence ratio (SIR) for EAC after antireflux surgery was 9.21.

Conclusions: ADAM9 showed the most consistent increase in EAC and in BE. No clear progressive increase in a single ADAM was observable during the progressive stages from GERD to EAC. ADAMs may participate in the interplay of the signaling networks, also in stages before EAC. Their effects, especially those of ADAM9, could be further characterized in functional assays. Neither the oncogene CIP2A nor c-MYC predicted survival of EAC.

After BE ablation and antireflux surgery, the recurrence of intestinal metaplasia was common, and oxidative signaling was not fully normalized in the long term. The neosquamous mucosa did not exhibit markers of intestinalization or malignancy. Nationwide, EAC incidence after antireflux surgery remained higher than in the general population. EAC often developed late, more than 5 years after antireflux surgery. Antireflux surgery does not protect from EAC at population level.

1 Introduction

Esophageal adenocarcinoma is one of the two dominant cancer types in the esophagus. Esophageal cancer, the sixth most common cancer as a cause of cancer-related death worldwide [1], is often diagnosed late, with either regional (in 30%) or distant metastases (in 40%) already present at diagnosis [2]. Therefore, fewer than 60% of the patients are suitable for surgery with curative intention. EAC was once thought to arise from the stomach via overgrowth into the esophagus, or from esophageal submucous glands, or from ectopic gastric mucosa [3], with only the latter two representing primary esophageal adenocarcinomas. The findings of esophageal adenocarcinomas, lined by and separated distally from the stomach by columnar esophagus [4], strengthened the idea of primary esophageal adenocarcinomas. Norman Barrett, among others, found in the 1950s that this columnar lining of the esophagus was histologically different from gastric mucosa [5, 6]. The nature of this “Barrett’s esophagus” as an acquired condition or a malformation (a vestige of the embryonal endoderm lining the esophagus) was early debated [7].

Predisposing factors for esophageal adenocarcinoma include obesity, increasing age, smoking, male gender, and GERD [8]. GERD causes inflammation of the esophageal mucosa (esophagitis), which may turn into columnar intestinal metaplasia (Barrett’s esophagus), and later into dysplasia (dysplastic Barrett’s esophagus) and finally into EAC. However, only a minority of patients progress from one stage to another [9]. Moreover, EAC is often found in those without a diagnosis of GERD or BE [10]. It is thus probably the combination of risk factors that leads to EAC development. This combination may be assessed both to predict the risk for progression and to plan individualized follow-up and treatment.

GERD is a common complaint presenting with a wide continuum of disease severity and variable phenotypes, occurring in 9% to 28% of the population in North America and Europe, and in 3% to 33% in Asia [11]. Occasional GERD symptoms are experienced by many without GERD. In contrast, a significant proportion of those who are asymptomatic present with endoscopic signs of GERD [12]. GERD may be perceived as a pathologic continuum of a physiologic disturbance. BE prevalence is 1.6% at population level and 6% to 14% in those with GERD [2, 11, 13]. Current diagnostic methods, or the panel of clinical risk factors, are insufficient in predicting the progression to both EAC and Barrett’s dysplasia. Surveillance of Barrett’s esophagus has only recently shown a survival benefit [14, 15]. Such surveillance, with appropriate treatment of progression, may be cost-effective with a surveillance interval of 5 years in long-segment BE [16].

To enhance the efficacy of surveillance and treatment, molecular markers to aid in tailoring these are essential. To date, no single molecular pathway leading to EAC has been found and validated, and clinically useful markers are lacking [17, 18]. A distegrin and metalloproteinases, ADAMs, make up a protein subfamily that can activate many molecules essential for carcinogenesis and inflammation [19, 20]. Their increased expression occurs in many cancers, such as in gastric cancer [20, 21]. Their expression, at mRNA level, has also been increased in esophageal adenocarcinoma [22]. Importantly, their expression in the stages of GERD preceding EAC, and at protein level, has been unknown.

One of the few molecules emerging as a promising clinical marker for BE progression is p53 [23]. C-MYC, another oncogene with a possible role as a biomarker [18], interacts directly with an oncogene CIP2A (cancerous inhibitor of protein phosphatase 2A) involved in the phosphorylation cascades important in cellular signaling [24]. Overexpression of CIP2A occurs in many cancers, including gastric cancer and esophageal squamous cell carcinoma [25-27]. CIP2A expression has also been associated with the prognosis of many carcinomas, and with p53 expression [25, 28]. As yet, no studies appear to exist concerning the expression of CIP2A in EAC.

Attempts have been made to eliminate the cancer risk of BE by destroying the metaplastic mucosa, together with effectively treating GERD [29]. However, BE tends to return in about 12% to 16% of patients in 2 to 3 years after eradication [30, 31]. EAC may also appear after the treatment [30, 32], the reasons for which remain unknown. Ineffective acid suppression, genetic predisposition, and other risk factors unmodified by the treatment are likely to play a role, as well as the possible columnar mucosa hidden under the neosquamous epithelium. Given the small cancer risk in nondysplastic BE, the ablation of BE is currently reserved for patients with dysplasia or intramucosal cancer, with endoscopic resection techniques used first to remove the neoplastic lesions [2, 10].

GERD can be treated, with symptoms relieved and possible esophagitis healed, quite effectively by either medical acid suppression or by surgically enhancing the antireflux mechanism of the gastroesophageal junction (GEJ) [11, 33]. Conflicting results exist for PPIs in treatment of GERD, regarding risk for EAC, as studied in BE patients [34, 35]. For antireflux surgery, small earlier studies preliminarily suggested that antireflux surgery might be beneficial in EAC prevention in BE patients [36, 37], yet larger studies show that EAC risk after antireflux surgery remains elevated, a risk no different from that of nonoperative treatment [38-40]. Many reasons exist for the failure of GERD treatment to prevent EAC. GERD alone seems insufficient to cause EAC, and its treatment does not remove the effects of other important risk factors. Other proposed reasons include the already initiated, irreversible neoplastic transformation, and incomplete reflux prevention due to issues such as inadequate medication use or failure of antireflux surgery. The absence of GERD symptoms in many patients with ongoing harmful reflux is likely to play a role at the population level, as well. EAC risk from BE is in fact smaller than previously thought (about 0.1% to 0.3% annually) [10], demanding large-scale studies to find any possible effect, and demanding that the other risk factors for BE progression should be taken into account.

EAC nowadays still has a poor prognosis, especially due to the delayed diagnosis in the majority of cases, presenting too late for radical cure. Thus, possible means for its prevention are essential. The elucidation and understanding of molecular pathways leading to EAC could aid both in its prevention and treatment. The present means for EAC risk reduction are weight control, cessation of smoking, cure of GERD by life-style factors, proton-pump inhibitors, or surgery, and BE surveillance or endoscopic therapy. In this study, we assessed the expression of ADAM molecules in GERD and EAC, and the expression of CIP2A and c-MYC in EAC and their effect on survival. We also studied the possibility of preventing EAC by BE ablation or by antireflux surgery.

2 Review of the literature

2.1 Functional anatomy and histology of the lower esophagus and gastric cardia

During embryogenesis, the esophagus is first lined by columnar epithelium (the endoderm), which is replaced by squamous epithelium, starting from the mid-esophagus [41]. The adult esophagus contains submucosal glands, concentrated in both the upper and the lower esophagus, that secrete substances such as bicarbonate. The epithelium of their ducts transforms from cuboidal to squamous cells near the esophageal lumen [42]. Landmarks defining the gastroesophageal junction (GEJ) are the squamocolumnar junction, the proximal end of the gastric folds, and the distal end of the palisade vessels. Normally, these three are situated in approximately the same place [43]. Palisade vessels are the longitudinally arranged capillaries situated mainly in the lamina propria, at the most distal 2 to 3 cm of the esophagus. Inflammation may obscure their visualization [43, 44]. Endoscopically, the GEJ is usually defined as the beginning of the gastric folds because it is the most reliable landmark.

The mechanism inhibiting the reflux of stomach contents back into the esophagus is multifactorial, and is in GERD often impaired. Gastroesophageal reflux to a certain degree is a physiologic phenomenon occurring especially postprandially. The distal sphincter mechanism is formed by a 2- to 4-cm long thickened circular muscle layer (lower esophageal sphincter, LES), the phrenoesophageal ligaments, crural diaphragm, the angle of His, sling fibers of the proximal stomach (cardia), and the intra-abdominal location of GEJ [43, 45, 46]. LES is tonically contracted at rest [43, 47]. When LES relaxes, the longitudinal esophageal muscle contracts, and the gastric cardia rises upwards [48]. The phrenoesophageal ligaments are fascial elastic structures that insert circumferentially into the distal esophagus, close to the squamo-columnar junction (SCJ), from the diaphragmatic hiatus. They bring the GEJ back into place after it has risen during LES relaxation, for instance, in swallowing [43]. The right crus of the diaphragm is also important in assisting LES in that it contracts during LES relaxation and at times of increased intra-abdominal pressure [43, 48]. The sling fibers of the cardia also participate in the sphincter mechanism [45].

The location and definition of the gastric cardia have been debated, and also its nature as a congenital anatomic entity or an acquired metaplastic lesion. It lies directly distal to the gastroesophageal junction, and its glands secrete mucus, but do not contain parietal or chief cells (characteristic of the gastric oxyntic mucosa) and consequently do not secrete acid or pepsinogen [49]. Studies in children, fetuses, and embryos show evidence of the gastric cardia as a congenital structure already developing during pregnancy, with a length of 0.3 to 4.0 mm [50-52]. Cardiac epithelium has appeared in the GEJ in 67% of those older than 15 years undergoing upper gastrointestinal endoscopy [53]. The histological definition of GEJ has been proposed to be the proximal limit of the gastric oxyntic mucosa [54].

2.2 Gastroesophageal reflux disease (GERD)

2.2.1 The pathophysiology of GERD

The principal reflux mechanism in patients with normal GEJ anatomy – who also tend to have a milder form of GERD - is transient relaxations of the LES (TLESR) [43]. TLESRs occur independent of swallowing due to the distension of the stomach, especially the fundus, and they are normal during digestion and belching [43]. In GERD, reflux-associated, but not the total number of TLESRs, are increased [48]. Other mechanisms producing pathologic reflux include decreased LES pressure, anatomic disruption of the GEJ, impaired esophageal clearance due to weak or absent esophageal peristalsis [43, 48], and possibly delayed gastric emptying [55]. The angle of His, or the esophago-gastric insertion angle, is more obtuse in GERD patients than in control subjects [45]. Moreover, in GERD, the post-prandial acidic environment in the GEJ, the acid pocket or intra-sphincteric reflux, extends more proximally [48]. The level of gastric acid secretion is not elevated in GERD, nor does it relate to the severity of esophagitis [56].

Anatomic disruption of the GEJ may lead to a hiatal hernia, which predisposes to GERD through the altered GEJ physiology, including loss of its intra-abdominal location, loss of crural contraction, and loss of the normal angle of His. Hiatal hernias also impair esophageal acid clearance [43]. Of the four types of hiatal hernias, type I hiatal hernia is a sliding hiatal hernia accounting for 85% to 95% of all cases [57]. Hiatal widening (looseness of the right crus) and laxity of the phrenoesophageal ligaments allow the herniation of the GEJ and the proximal part of the stomach into the thoracic cavity [43]. The GEJ normally moves within 2 cm up- and downwards during swallowing, so a sliding hernia can be diagnosed when the movement is > 2 cm. [43]. Types II to IV (5-15%) are paraesophageal hernias. In type II, the gastric fundus herniates through the hiatus; type III has both a sliding hernia and a paraesophageal gastric fundic component; and in type IV, other abdominal organs herniate into the thoracic cavity [43, 57].

2.2.2 Epidemiology of GERD

The Montreal classification defines GERD as a disease in which the refluxed gastric contents cause troublesome symptoms or complications [58]. Many people experience occasional GERD symptoms without actually having the disease, while a significant number of patients with GERD are asymptomatic. The prevalence of GERD, defined as at least weekly heartburn or regurgitation, or both, ranges from 2.5% to 33.1% depending on geographic area, with a prevalence of 8.8% to 25.9% in Europe, and with even higher numbers in North America [11]. The incidence of GERD has been rising in western countries since 1995 [11], along with GERD-associated mortality [59]. GERD incidence in the UK and USA is approximately 5.0 per 1000 person-years [11]. Its incidence in children has also been increasing, for example in the USA by 30% to 50% during 2000-2005 [60].

2.2.3 GERD symptoms

The main GERD symptoms are heartburn and regurgitation. GERD may, however, present also with chest pain, dysphagia, or extraesophageal symptoms such as cough, laryngitis, asthma, and dental erosion [58] as well as hoarseness, throat-clearing, and wheezing [61]. Questionnaires can serve for GERD evaluation [62]; these include health-related quality-of-life questionnaires. Approximately 40% of patients with GERD symptoms have endoscopic esophagitis [63]. In contrast, of the patients with erosive esophagitis in Asia, 43% to 59% have been found to be asymptomatic [12, 64]. The severity of GERD symptoms, although correlating in part with endoscopic findings, does not predict the degree of esophagitis or esophageal metaplasia [58].

2.2.4 Endoscopic classification and severity of GERD

GERD is classified into erosive reflux disease (ERD) with visible endoscopic changes versus non-erosive reflux disease (NERD) without endoscopic changes. Symptom-correlation with acid reflux distinguishes NERD from functional heartburn [65, 66]. Endoscopic findings in ERD are most often classified according to the Los Angeles grading system, in which esophagitis is graded both by length and extension of the mucosal breaks over the mucosal folds [67]. In grade A, the distinct mucosal breaks are ≤ 5 mm; in grade B, they are > 5 mm; in grade C, the mucosal breaks are continuous and involve $< 75\%$ of the esophageal circumference; in grade D, the continuous mucosal breaks involve more than 75% of the circumference [67]. Barrett's esophagus (BE) and esophageal strictures are considered complications of ERD [58]. The significance of esophagitis detected only histologically, microscopic esophagitis, is unknown. It has, however, recently been detected only in patients with GERD and not in those with functional heartburn [68].

Several studies have demonstrated that increasing acid reflux is associated with more severe GERD, increasing from NERD to progressive stages of ERD. Lower LES pressure, ineffective esophageal motility, and a higher prevalence of a hiatal hernia also all increase with more severe GERD [69-71]. Bile reflux also increases in ERD and in BE [63]. Patients with ERD have shown male predominance (58% vs. 40%), higher BMI, a tendency to be older, and a more frequent occurrence of a hiatal hernia than did those with NERD, whereas no difference appeared in symptom duration [72]. A hiatal hernia is frequently found in patients with reflux esophagitis (50-94%), and in patients with BE (72-96%) when compared to 13% to 59% in normal controls [43].

2.2.5 Other diagnostic methods

In addition to symptom assessment and upper gastrointestinal endoscopy with biopsies, other diagnostic tools for GERD are pH-monitoring, manometry, and impedance testing. In 24-h pH-monitoring, esophageal acid exposure is measured with an electrode that

records acid reflux. The electrode is inserted transnasally to 5 cm above the LES and connected to an external recorder. There is also a wireless pH-probe option [62]. The number and duration of the reflux events are documented, with reflux during upright and supine positions distinguished. A pH < 4 is considered the threshold discriminating between physiological and pathological gastro-esophageal reflux episodes. Most often, the total percentage of time that pH is < 4 is reported, with normal values being ≤ 4 to 5.5% [73]. Symptoms occur during only 10% to 20% of all acid reflux events [73].

Manometry assesses esophageal motility, peristalsis, contractions, and LES pressure. In GERD evaluation, it may serve to exclude other conditions, and to aid in classifying the motility and pressure abnormalities of GERD, such as TLESRs and the LES pressure [62, 74]. A more precise application, high-resolution manometry, is better at characterizing TLESRs [74].

Impedance testing measures the electric resistance between electrodes positioned along the length of the esophagus on a catheter. It can detect and discriminate gas reflux from liquid reflux. The multiple-electrode system allows determination of the extent of reflux in the esophagus. Combined with pH-monitoring, the relationship of reflux of differing acidity can be measured and correlated with symptoms. With impedance testing, pH-monitoring, and manometry in combination, the sensitivity and specificity for GERD diagnosis are both over 90% [75].

2.3 Barrett's esophagus (BE)

2.3.1 BE definition

Barrett's esophagus (BE) is a condition in which metaplastic columnar (intestinal) mucosa has replaced part of the squamous mucosa of the distal esophagus (Figure 1). It is defined as an endoscopically visible esophageal columnar mucosa confirmed histologically [10], and frequently, with the evidence of intestinal-type goblet cells as evidence of intestinal metaplasia. In the UK and Asia, however, intestinal metaplasia is not required for the diagnosis of BE [13]. Other types of columnar epithelium that may occur in the metaplastic distal esophagus are of the gastric fundic and cardiac types [76]. The association between EAC and BE has been based on evidence of intestinal metaplasia (IM) [13, 77]. IM may also be patchy, requiring extensive sampling, and may thus be underdiagnosed [77]. However, also the cardiac type epithelium seems to carry a risk for EAC, although the magnitude of this risk is unknown, and controversy exists [76, 77]. The presence of cardiac epithelium is associated with features of GERD [53], and cardiac IM may be a condition preceding BE [78]. Multilayered epithelium at the gastroesophageal junction poses features of both columnar and squamous epithelia, but is of unknown significance [41].

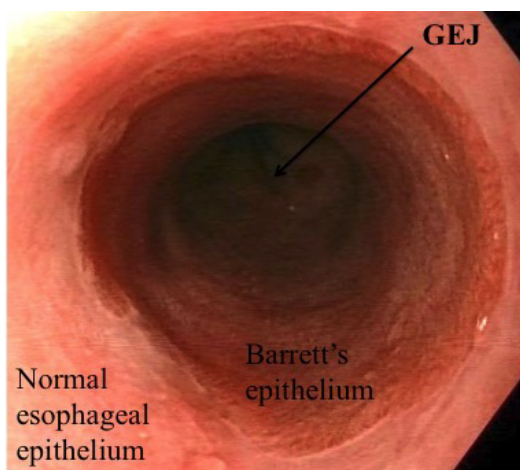


Figure 1 Endoscopic image of Barrett's esophagus. GEJ = gastroesophageal junction (Photograph by Henna Söderström)

The Prague criteria are the most-used criteria for endoscopic definition of BE extent. According to these criteria, BE length is defined as the circumferential extension (C, in centimeters) and the maximal (M, in centimeters) extent of the metaplasia proximal to the GEJ [79]. BE can also be classified by its length (Table 1).

Table 1 Classification of BE according to length. GEJ = gastroesophageal junction

Type of Barrett's esophagus	Length above the GEJ
long-segment	≥ 3 cm
short-segment	≥ 1 cm, < 3 cm
ultra-short-segment	< 1 cm

2.3.2 BE epidemiology

At population level in Sweden, BE has been found in 1.6% of adults [80]. In the same study, columnar-lined esophagus occurred in 8.3% [80]. In patients with symptomatic GERD, BE has been diagnosed in 14.1% and columnar-lined esophagus in 23.3% [13]. Other studies have reported BE in 6% to 12% of patients with longstanding GERD symptoms [2].

2.3.3 The origin of BE

BE is nowadays considered an acquired rather than a congenital condition. Causes and mechanisms leading to the replacement of normal esophageal squamous epithelium with columnar, mucus-secreting epithelium need clarification. Possible mechanisms include either mature esophageal squamous cells or immature progenitor cells turning into columnar cells, or stem cells from the bone marrow, gastric cardia, or gastroesophageal junction giving rise to the metaplastic epithelium [10]. The possible presence of multipotent stem cells' changing their commitment could explain the different types of columnar esophageal epithelia in GERD. The location of these possible stem cells inside or outside the mucosa (such as in submucosal gland ducts) remains unknown [41]. Recently, however, BE stem cells capable of long-term self-renewal have been grown from BE biopsies. These stem cells differed from cells grown from the squamous esophagus, or from the stomach [81].

2.4 Risk factors for GERD, BE, and esophageal adenocarcinoma (EAC)

GERD, BE, and EAC share similar risk factors. Importantly, GERD predisposes to BE and EAC. Symptomatic GERD is a risk factor for BE [82], and young age at the onset of GERD symptoms elevates BE risk [83]. Bile reflux is increased in BE [70, 84], and bile acids induce BE in rats [85]. For EAC, at least weakly symptoms of heartburn and/or regurgitation confer a 4.8- to 7.7-fold risk, a risk dependent both on duration and frequency of symptoms [86, 87]. Individuals suffering from at least weekly symptoms for at least 20 years had a 9.3-fold risk (odds ratio, OR) for EAC in a meta-analysis of case-control studies, whereas those with severe symptoms (a score based on the symptom type and frequency) for at least 20 years had a 44-fold risk for EAC in a case-control study [86, 87]. Nocturnal symptoms were associated with an over 10-fold risk for EAC [87]. Reflux symptoms are similarly associated with EAC in both BE patients and those without diagnosed BE [87]. Of patients undergoing esophagectomy for EAC, 22% had a history of reflux in one population-based study [88], whereas 64% reported a history of GERD symptoms in a single-center study [89].

BE is a risk factor for EAC. The reported proportion of EAC patients with a previous diagnosis of BE varies, ranging from 1.3% to 7.2% in population-based studies [14, 88] to about 5% to 34% in patients undergoing surgical resection for EAC [89, 90]. EAC risk increases with increasing length of BE [91]. A previous diagnosis of BE seems to be associated with lower tumor stage, milder histology, and enhanced survival [14]. During EAC diagnosis, BE may have disappeared due to overgrowth. In a study with an IM prevalence of 45% in junctional or cardiac, and 87% in distal esophageal tumors, IM was present in all tumors with diameter < 1 cm, and in all intramucosal tumors; IM prevalence decreased with increasing disease stage. [92].

Increasing age and male gender are risk factors for both BE and EAC [1, 10]. Obesity is a risk factor for GERD and subsequent metaplasia, dysplasia, and neoplasia

[10, 62]. Abdominal obesity in particular predisposes to erosive esophagitis, BE, and EAC [93]. EAC risk increases with rising body-mass index (BMI) [94]. The risk may be conferred by abdominal obesity, because it remains a risk factor when controlling for BMI and not vice versa [93, 95], and even in normal-weight individuals [96]. The increased risk may be due to increased reflux because of the increased intragastric pressure impairing GEJ function, or independently of GERD due to visceral fat-secreting pro-inflammatory cytokines [97]. Increased leptin levels and insulin resistance are associated with increased EAC risk in BE patients [98]. The risk of abdominal and general obesity for BE and EAC, respectively, seems independent of GERD [93, 94]. Importantly, obesity and GERD seem to cause increased EAC risk additively [94]. Smoking confers about a 2-fold risk for EAC, with the magnitude of risk depending on both dose and duration of smoking [99, 100]. Smoking is also a risk factor for GERD and BE [10, 62]. Alcohol may be a risk factor for BE in men and in Asians [101]. It is not a risk factor for EAC, however, although alcohol predisposes to the other important esophageal cancer type, squamous cell carcinoma [2].

There are genetic susceptibility loci of mutated genes for BE and EAC [102], hinting at a genetic predisposition. Genetic risk factors may interact with environmental factors such as GERD and smoking in contributing to EAC [103]. Familial clustering occurs in about 7% of BE and EAC cases, with EAC occurring at a younger age than usually [104]. The suggested inheritance type is autosomal dominant, but environmental factors may also play a role [105]. Race affects EAC risk: EAC incidence is low in Blacks and high in Hispanics, as compared to Caucasians [106], in whom BE is the most prevalent [107].

An inverse relationship exists between *Helicobacter pylori* (*H. pylori*) infection and risk for both EAC and BE. The possible protective role of this infection may be due to decreased gastric acidity [108]. In rats, esophageal *H. pylori* colonization elevated the severity of esophagitis and induced markers of BE and proliferation, however [109]. In addition, low vegetable- and fruit intake seems to be a risk factor for EAC [110], whereas high fiber intake reduces risk for EAC and BE. The risk-lowering effect of a high-fiber diet may be due to anti-proliferative and anti-inflammatory agents that this kind of diet contains [111]. LES-pressure-lowering medication seems to be a risk factor for EAC, probably by causing increased reflux [112]. These kinds of drugs, ones such as nitrates and anticholinergics, are also risk factors for GERD [62]. Non-steroidal anti-inflammatory drugs (NSAIDs) and statins are associated with reduced EAC risk [113-115]. Statins also reduce risk for BE [116]. Whether the mechanism of NSAIDs in preventing EAC is their anti-inflammatory properties is unclear. The effect of statins might be explained by their anti-proliferative action [114].

A possible role for female hormones explains in part the age- and gender associations of EAC. EAC incidence has been measured as 7.7-fold higher in men than in women [117]; also in BE patients, EAC incidence is higher in men [118]. The male-to-female incidence ratio is highest at ages 50 to 54 [117] or 50 to 59 [106], and in each study, declines after that. Hormone replacement therapy and oral contraceptives seem to reduce EAC risk [119]. At cell-line level, estrogen and selective estrogen receptor modulators have been shown to reduce growth in both EAC and BE cell lines, and in EAC cell lines they stimulate apoptosis [120].

2.5 Endoscopic surveillance of BE

Current guidelines suggest endoscopic surveillance for nondysplastic BE at intervals of 3 to 5 years [10]. The cost-benefits of endoscopic surveillance have, however, been questioned because of the rarity of EAC's being detected in surveillance (0.63% annually) and the low mortality (0.3% annually) in a meta-analysis [121]. By surveillance, cancers may be detected at an earlier stage and thus have a better prognosis [122], yet surveillance has also failed to show any impact on EAC mortality [123]. Recently, patients with a prior BE diagnosis have shown enhanced survival, and tumors have been of earlier stage and of lower histological grade with enhanced operative resectability [14]. A large prospective cohort study showed excellent results for BE (≥ 2 cm) surveillance; EAC was diagnosed at an earlier stage and with a survival not significantly differing from that of BE patients without cancer development (although the 5-year survival-rates were 74% vs. 94%, respectively), and similar to survival of stage 0- to 1 tumors detected in the general population [15]. Thus, although the cancer risk in BE is lower than previously estimated, surveillance may lead to survival advantage. Recent analysis suggests a less frequent surveillance protocol to be cost-effective: a surveillance interval of 5 years for long-segment BE without dysplasia and 3 years for long-segment BE with low-grade dysplasia [16]. However, the European Society of Gastrointestinal Endoscopy recommends a surveillance interval of 5 years for short-segment BE and of 3 years for long-segment BE (up to 10 cm, otherwise referral to a specialized center) [124]. To enhance the efficacy of surveillance, the protocols could be tailored also taking into account other associated risk factors, like obesity, smoking, and age.

2.6 Barrett's dysplasia

The neoplastic transformation of Barrett's metaplasia into EAC occurs through dysplastic changes. According to the Vienna classification, non-invasive intra-epithelial neoplasia comprises low-grade dysplasia (LGD), high-grade dysplasia (HGD), carcinoma in situ, and suspicion of invasive carcinoma. A lesion is classified as indefinite for dysplasia if its true nature is undetermined. The distinction between low-grade and high-grade dysplasia should correspond to risk for invasion [125]. This dysplasia grading applies well to Barrett's dysplasia, with the aid of p53 expression in the prediction of progression [126]. Histologically, LGD presents with nuclear polarity and mild changes in the appearance of the nuclei and potential glandular crowding. In HGD, the mucosal surface and glands are distorted, glandular crowding is present, the lamina propria is sparse, and the nuclei display many pathologic changes such as hyperchromasia, enlargement, and pleomorphism [127]. Dysplasia can also be morphologically characterized into adenomatous and foveolar types, and a combination of these, with a potential importance for carcinogenesis [128]. The detection and classification of dysplasia is complicated, as dysplastic spots may be patchy and invisible. The histologic characterization with varying depths of tissue biopsies is subjective, with distinct inter-observer variance. Inflammation and regeneration produce changes that can be hard to distinguish from dysplasia, and that

may hamper its grading. The diagnosis of dysplasia needs confirmation by an expert pathologist. Healing of esophagitis by medical treatment may help in distinguishing regenerative atypia from true dysplastic lesions [129]. Indeed, the incidence of regression from LGD to non-dysplastic BE has been 57% annually [16]. For increased accuracy of dysplasia classification and detection in BE surveillance, the metaplastic epithelium should be biopsied at 2-cm intervals from four sides of the esophageal lumen. If dysplasia has been previously detected, the biopsies should be taken at 1-cm intervals [129].

2.7 Risk for progression of BE and associated dysplasia

In patients with BE, EAC risk has, according to recent studies, been much lower than earlier suggested [118, 130]. The EAC incidence in BE is 0.29% to 0.43% annually, and when excluding cancers diagnosed less than one year after the initial BE diagnosis, EAC incidence in BE is 0.12% to 0.18% annually [118, 130-134]. According to one meta-analysis, short-segment BE also carries an annual 0.19% EAC risk [134]. Recently, annual cancer transition rates for differing lengths of BE were estimated to be 0.22% for long-segment BE, 0.03% for short-segment BE, and 0.01% for ultra-short-segment BE [91]. The incidence of LGD has been 3.6% to 5.7% annually, but the true transition rate was estimated at 2.3% annually [16, 133]. The incidence of HGD in BE has been 0.48% annually [133].

BE with LGD carries a 0.54% annual risk for EAC according to a meta-analysis, with the risk ranging from 0.02% to 11.4% across studies [135]. The incidence of either HGD or EAC in LGD was 1.73% annually (range 0.04%-26.7%) [135]. A recent prospective cohort study found the incidence of HGD or intramucosal EAC in LGD to be 13.1% annually, but the true annual transition rate was estimated to be lower, at 4.3% [16]. In BE with HGD, the annual EAC incidence in another meta-analysis was 5.6% [136]. In patients with HGD in pre-treatment biopsies, EAC confined to the mucosa or submucosa occurred in 52% of the endoscopic resection specimens. Most of the upgraded cases presented with a visible lesion at endoscopy [137]. In patients undergoing esophagectomy with a preoperative HGD diagnosis, the rate of upgraded cases has been lower, with EAC detectable in 17.6% [138].

2.8 Treatment of Barrett's dysplasia

All visible lesions in BE, irrespective of dysplasia grade, should always be removed by endoscopic resection [124] prior to possible ablation. If LGD is detected in random samples, and the diagnosis is confirmed, acid suppression treatment by proton pump inhibitors (PPIs) to heal esophagitis is recommended before follow-up endoscopy at 6 months [124, 129]. According to the guidelines of the European Society of Gastrointestinal Endoscopy, if the diagnosis remains LGD after the PPI therapy, the patient should receive endoscopic ablation. If LGD has disappeared, surveillance

endoscopies should be performed first at 12-month intervals. For HGD without visible pathology, endoscopic ablation is necessary [124].

2.9 Esophageal adenocarcinoma

2.9.1 Diagnosis of EAC

The most common symptom of esophageal cancer is dysphagia. Other symptoms include weight loss, fatigue, and anemia [8]. Diagnosis is made by upper gastrointestinal endoscopy and histology. Esophageal carcinoma is classified into five main stages according to the TNM classification [139]. Computed tomography, ¹⁸F-fluorodeoxyglucose positron-emission tomography (FDG-PET), endoscopic ultrasonography, and bronchoscopy (mid-thoracic tumors) are means for determining disease stage [1].

Esophageal cancer is classified according to its location: cancer in the cervical esophageal (C15.0), intrathoracic esophageal (C15.3, upper-; C15.4, mid-; and C15.5, lower thoracic portions), or esophagogastric-junction cancer (C16.0) [139]. EAC is most often situated in the distal esophagus.

2.9.2 EAC incidence

In Western countries, the incidence of EAC has been rising and even exceeding that of the worldwide-predominant squamous cell carcinoma in areas such as the USA, the UK, and Finland [1]. The rate of increase has, however, fallen in recent years [140, 141]. Contradictory results exist as to the similarity of the increasing rates in men and women. The mean increase in EAC incidence from 1975 to 2009 was almost the same for both sexes, 6.1% per year for men and 5.9% per year for women in the USA (average annual percentage change), with another study reporting annual positive percentage change higher for men, however [117, 141]. A shift has occurred in the stage distribution of EAC, with the proportion of local disease slightly increased and that of distant disease slightly decreased [142].

2.9.3 Treatment of EAC

Treatment methods for esophageal cancer, depending on disease stage, include endoscopic mucosal resections (with ablation of the BE), esophagectomy with or without neoadjuvant treatment, and chemoradiotherapy, as well as palliative procedures (such as stents, gastrostomy, jejunostomy). Endoscopic resection is commonly accepted for cancerous growth confined to the epithelial cells (carcinoma in situ), and for intramucosal T1-tumors

(T1a) [2]. However, the risk for lymph node spread (N1) in intramucosal T1-tumors has been 7% [143]. T1b tumors that extend into the submucosa may have lymph node metastasis in up to 20% of cases [2]. Tumors with superficial submucosal invasion (T1b sm1) may be treated with esophagectomy or endoscopic resection in selected cases. Endoscopic treatment may be appropriate for patients at an increased risk for operative complications, especially for well-differentiated tumors without lymphovascular invasion. Endoscopic ultrasonography may aid in evaluating the lymph node status in these T1b tumors. For tumors with deeper submucosal invasion (T1b sm2-3), esophagectomy should be performed, and endoscopic treatment remains a palliative option for patients unfit for surgery [129].

Esophagectomy is the treatment of choice for locally advanced EAC. It may be performed either via an open approach or mini-invasively by thoracoscopy and laparoscopy. There are several options for open esophagectomy: the Ivor-Lewis procedure with thoracic and abdominal incisions, transhiatal esophagectomy with abdominal and neck incisions, and a combination of neck, thoracic, and abdominal incisions [8]. The removed portion of the esophagus is replaced most often by tubularized stomach pulled into the chest. A segment of colon or jejunum may also be used. For tumors with distant metastasis, palliative procedures are used, and chemoradiation or chemotherapy. Immunologic agents are also under assessment [1].

2.9.4 Lymph node retrieval and chemoradiotherapy

The number of lymph nodes removed in surgery is important for the cure and prognosis of the disease and also for evaluation of adjuvant treatment. Controversy exists about the need for two-field lymphadenectomy comprising nodes in the abdomen and chest or three-field lymphadenectomy including also lymph nodes in the neck. In Western countries, two-field lymphadenectomy is common. Three-field lymphadenectomy may result in an increased number of complications without a survival advantage [1]. Both an increased and decreased number of retrieved lymph nodes have been reported in minimally invasive esophagectomy (MIE) as compared to open surgery [144, 145]. The indications, optimal timing, and the method (chemotherapy with or without radiotherapy) of adjuvant therapy for EAC are not yet clear. Neoadjuvant treatment is used for $\geq T3$ or $\geq N1$ disease [146]. In clinically staged T2 tumors, about half the patients have lymph node metastasis, suggesting the benefit of neoadjuvant treatment [147].

2.9.5 Complications of surgery

The 30-day morbidity rate of surgery is as high as 50% to 60% in locally advanced disease, and the 30-day mortality rate is 2% to 4% [144, 145]. Complications include pneumonia, empyema, cardiac complications, anastomotic leak, conduit necrosis, and vocal cord palsy [144].

Minimally invasive esophagectomy has been comparable to open esophagectomy in terms of mortality, but the hospital stay after MIE is shorter [144, 145]. After MIE, complication rates and 5-year-survival rates are similar with open esophagectomy [144].

2.9.6 Survival of EAC

Esophageal cancer spreads early, due to both the lack of visceral peritoneum (serosa) in the esophagus and extensive lymphatic drainage to both thoracic and abdominal nodes originating in both the esophageal mucosa and the muscularis layers [146]. In addition, EAC also spreads hematogenously. At diagnosis, 30% of the tumors already display regional metastasis, and 40% display distant metastasis [2].

The 5-year survival rate of esophageal carcinoma is only 15% to 25% [1], with a slightly higher survival rate for EAC than for squamous cell carcinoma [2]. Survival has improved over recent decades especially in those patients treated with surgical resection [142]. Survival depends on disease stage at diagnosis [1]. In superficial EAC (pT1N0-1, M0), the 5-year survival is 67%, and in locally advanced EAC (stage IIb-IIIc), 41% after minimally invasive esophagectomy and 56% after open esophagectomy [144, 148]. Locally advanced EAC, resected surgically after neoadjuvant treatment with a complete pathologic response (ypT0N0M0R0), leads to a 5-year survival of 55%, with the disease-specific survival rate being 68% [149]. In distant (stage IV) esophageal carcinoma, the 5-year survival is 6% [150].

Incidence-based mortality from EAC seems to be rising less steeply than is EAC incidence. In the 21st century, incidence-based mortality in local EAC may even have been slightly declining, while in regional EAC it seems to have nearly stabilized, but in distant disease it has kept rising [141].

2.10 Adenocarcinoma of the gastroesophageal junction

The definition of the origin of cancers located near the GE junction is difficult due to tumor overgrowth and the histologic similarity of these adenocarcinomas. They may arise from three different sources (from the mucosa of the esophagus, from the gastric cardia, or from the stomach below). In addition, the lack of consensus regarding the gastric cardia adds variability to the definition of these cancers. Adenocarcinoma around the gastroesophageal junction has been classified morphologically by Siewert into tumors originating in the distal esophagus, true cardia carcinomas, and tumors originating in the proximal stomach [151]. The present classification [152] is in Table 2.

Table 2 Classification of adenocarcinoma of the gastroesophageal junction (GEJ)

Type	Epicenter in relation to GEJ	Invasion to GEJ
I	1-5 cm above	yes / no
II	1 cm above to 2 cm below	yes
III	2-5 cm below	yes

Histologically, IM is a common finding also in tumors with their epicenter at or below the esophagogastric junction, although less common than in distal esophageal tumors (45% vs. 87%) [92]. The risk factors for gastroesophageal junction adenocarcinomas are much like those of EAC: smoking, GERD, obesity, and nutritional factors. *Helicobacter pylori* infection and the use of nonsteroidal anti-inflammatory drugs (NSAIDs) are associated with a reduced risk for this cancer. Except for smoking, the association of the risk factors is weaker than for EAC [153]. GERD entails a smaller risk for gastroesophageal junction adenocarcinomas than for EAC [40, 87, 154]. At least weekly symptoms of heartburn or regurgitation confer a 2.0- to 2.3-fold risk for junctional adenocarcinomas; the frequency and duration of symptoms show a much weaker association with GEJ cancer risk than with EAC [86, 87]. The incidence of adenocarcinomas of the GEJ increased until the beginning of the 1990s, but stabilized after that in the USA, unlike the incidence of EAC [153].

2.11 Treatment of GERD

The aim of GERD treatment is to relieve symptoms and heal esophagitis. The presence of a sliding hiatal hernia does not change the treatment protocol, because its treatment is also based on symptoms of GERD or complications such as ulcerations [43].

2.11.1 Lifestyle changes

The basis of conservative treatment is lifestyle changes to relieve symptoms, although their efficacy has not been well documented [11]. These include avoiding symptom-provoking food, slow eating to avoid concomitant air ingestion, eating at least two hours before going to bed, and sleeping with the upper body slightly raised to avoid supine reflux, and also weight reduction. Avoiding the risk factors of GERD, such as smoking and LES-relaxing medication, is also recommended.

2.11.2 Medical treatment

The most common and primary treatment method for GERD is medical treatment. For mild or post-prandial symptoms, the choice may be antacids or alginate. Antacids are drugs that neutralize acid, and alginate is a water-binding colloid that forms a viscous gel in the stomach [11]. When more efficient treatment is required, gastric acid secretion can be reduced by proton pump inhibitors (PPIs) or histamine₂-receptor antagonists (H₂RAs). PPIs reduce esophageal acidity more effectively than do H₂RAs [155], and are superior to H₂RAs in healing esophagitis, due to their longer effect on pH rise [73]. PPIs may also lead to the regression of BE length and area [155]. Their long-term use has suggested side-effects, such as predisposition for osteoporotic fractures and fundic gastric polyps [156].

Other drugs that may be useful in GERD are prokinetics such as metoclopramide, and drugs that relieve esophageal hypersensitivity such as tricyclic antidepressants or selective serotonin reuptake inhibitors [11].

2.11.3 Surgical treatment

2.11.3.1 Indications

Antireflux surgery is indicated for patients who continue to suffer severe reflux symptoms despite maximal medical treatment. GERD must be documented objectively by methods such as upper gastrointestinal endoscopy, pH-monitoring, or esophageal manometry [157]. Preoperative symptomatic response to PPI therapy may aid in evaluation of the probable surgical outcome. Patients with a good response to PPI therapy have better symptomatic relief after antireflux surgery than do non-responders [158].

2.11.3.2 Antireflux surgery techniques

The aim of antireflux surgery is to repair the anatomic and physiologic disturbances of the GEJ that cause GERD. This includes creation of a valve that compresses the esophagogastric junction area, leading to an increase in LES pressure, as well as in esophageal peristaltic amplitude and frequency [159, 160], and leading to re-establishment of the angle of His. An essential part of antireflux surgery is hiatal hernia repair and closure of a possible hiatal defect [161]. Fundoplication (Figure 2) is the gold standard of antireflux surgery and has been shown to reduce the rate of TLESRs, their association with reflux, and the distensibility of the GEJ, even > 5 years postoperatively, when compared to the situation in GERD patients without surgery [162].

In fundoplication, the fundus of the stomach is wrapped around the lower portion of the esophagus and sutured to construct a 360° plication around the GEJ area and the esophagus (a total wrap), or is sutured into the esophagus and surrounding structures (a partial wrap of 90-270°). The 360° total Nissen fundoplication, or its modified version

[163], is the most common antireflux procedure. A partial wrap may be constructed either anterior to (as in Thal, Dor, and Belsey Mark IV funduplications) or posterior to (as in Toupet fundoplication) the esophagus [157, 161]. The superiority of a total or partial wrap, in terms of reflux control and adverse effects (dysphagia, gas-bloat syndrome), is still debatable. Meta-analyses have shown that laparoscopic partial fundoplication results in less postoperative dysphagia and gas-related symptoms than does the laparoscopic Nissen fundoplication, whereas reflux control seems essentially equal – with the exception of a finding of reduced heartburn after the Nissen operation in one meta-analysis [164-166].

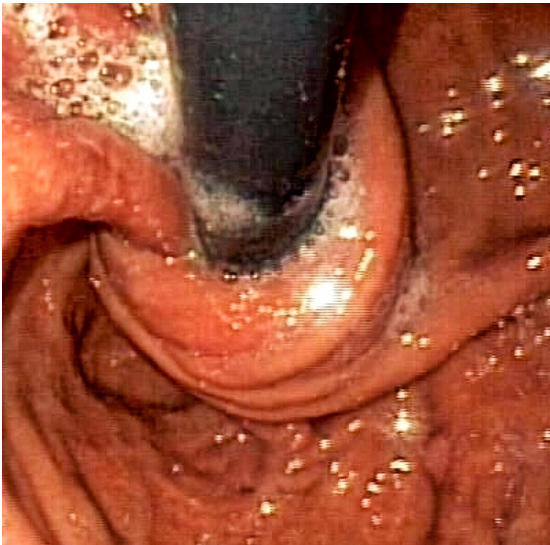


Figure 2 *Endoscopic image of an intact fundoplication wrap. (Photograph by Markku Luostarinen)*

Apart from fundoplication, partial gastrectomy with vagotomy and Roux-en-Y reconstruction is a method for reducing both acidic stomach secretion and bile reflux. Together with an antireflux procedure (fundoplication or Hill's gastropexy), it may lead to the regression of BE to the cardiac mucosa [167, 168]. Gastric bypass with a Roux-en-Y reconstruction in the obese may also result in BE regression [168]. These procedures (Roux-en-Y reconstruction combined with either fundoplication or Hill's gastropexy, antrectomy, and vagotomy, or with resectional gastric bypass) also show effective reflux control [167, 168]. New experimental techniques have also been introduced as alternatives to fundoplication in the treatment of GERD. A magnetic band placed around the GEJ (the LINX prosthesis) has initially shown promising results [169]. There also are endoscopic procedures aiming at plicating the stomach, with promising results in terms of diminished PPI use for the transoral EsophyX device at the 2-year follow-up [170]. Other techniques, such as laparoscopically implanted electrodes to stimulate LES, have also shown initially

promising results in subjective outcome as well as in pH-monitoring [171]. No studies cover the long-term durability and effectiveness of these new techniques.

2.11.3.3 Results

Antireflux surgery offers good relief of reflux symptoms in the majority of patients (77-92%) [33, 172]. Most patients are content with the results of surgery, more often after laparoscopic (92%) than after open surgery (76%) [172]. Antireflux surgery can also effectively heal esophagitis [33] and may lead to complete regression of BE and to the regression of LGD to IM [173]. In one meta-analysis, fundoplication appeared to result in better control of the reflux symptoms and in better patient-perceived GERD-related quality of life (QOL) than did antireflux medication, although many patients still used medication after surgery [174]. Although symptoms and medication use after antireflux surgery are important for the aspects of QOL and cost effectiveness, pathologic postoperative esophageal acid exposure is detectable in only a minority of patients with symptoms or ongoing medication [175, 176]. The postoperative use of PPIs varies greatly (15-80%) [177] and increases during the years after surgery, from 2.2% at one year to 46.5% at the 15-year follow-up [172, 178]. Postoperative PPI use often occurs without endoscopically or pH-monitoring-proven findings of reflux [172, 175].

Preoperative endoscopic findings of GERD, including BE and ERD vs. NERD, do not affect the symptomatic outcome of antireflux surgery [70]. In terms of extraesophageal symptoms, most studies report a positive response in over 50%, and up to 100%, of patients. Of patients with laryngeal symptoms, 65-94% benefit from fundoplication [179]. In a study of patients undergoing fundoplication after PPI treatment, fundoplication reduced both the esophageal and extraesophageal symptoms more effectively than did PPI [61]. Fundoplication may be more effective than medical treatment also in the healing of esophagitis [180].

Operative complications of fundoplication include esophageal or gastric injury, pneumothorax, splenic or liver injuries, and postoperative ileus [157]. Postoperative symptoms related to fundoplication include dysphagia, inability to belch or to vomit, and increased flatulence. Dysphagia and increased flatulence are more common complaints after fundoplication than occur on PPI therapy [61]. The long-term durability of surgery is not always good. Partial or total plication disruptions have been detectable in 11.1% of patients and hiatal hernias in 30.6% at the 15-year follow-up after laparoscopic Nissen fundoplication, with significantly higher plication disruption rates after open Nissen fundoplication than after laparoscopic fundoplication [172]. Reoperation after laparoscopic antireflux surgery has been necessary in 9.6% over a mean follow-up of 7.6 years [181].

2.11.4 Effect of GERD treatment on EAC development

The role of GERD as a risk factor for EAC suggests that eliminating this risk factor would also diminish EAC incidence. To date, no convincing evidence supports this hypothesis.

2.11.4.1 Antireflux medication

In addition to acid suppression, PPIs may have additional features such as anti-oxidant and immunomodulatory capabilities, and inhibitory effects on the adhesion of malignant cells [156]. Cancer-promoting effects of PPIs, resulting from the rise in serum gastrin levels and the ability of deconjugated bile salts to cause esophageal damage in a less acidic environment, have also been proposed [182]. Further, despite symptom relief, pathologic acid reflux is common during PPI therapy [183, 184]. Moreover, during PPI therapy, a common problem is non-compliance, manifested as irregular medication usage. No conclusive evidence shows PPIs as reducing risk for EAC in patients with BE. A meta-analysis of observational studies did show a 71% reduction in EAC/HGD risk in BE patients with PPI usage, and a pronounced effect with prolonged use. Use of HR2As, as analyzed by two of the studies, showed no protective effect [35]. A nationwide, registry-based study with almost 10 000 patients and a median follow-up of 10 years showed no protective effect of PPIs in BE patients; instead, it showed the highest EAC risk in the long-term, highly adherent users [34]. To add controversy, a recent large retrospective study of BE patients observed a protective effect of GERD treatment (mainly PPIs) on the progression to LGD, HGD, or EAC. [185] The severity of GERD symptoms, especially in patients using PPI, has been inversely correlated with the risk of patients presenting with either BE or EAC, although symptom severity correlated with the presence of esophagitis [186]. Interestingly, preoperative PPI usage may indicate a survival advantage in surgically treated EAC [89].

2.11.4.2 Antireflux surgery

Antireflux surgery may offer more complete reflux inhibition than does medical treatment, because surgery mechanically also prevents duodenogastroesophageal reflux (bile reflux). Despite this theoretical advantage, antireflux surgery has not been superior to non-surgical treatment of GERD in the prevention of EAC [38-40], and neither does EAC risk decrease after antireflux surgery [40, 154].

In BE patients, antireflux surgery was more efficient than medical treatment in inducing the regression of BE or dysplasia in one systematic review [187]. A study published after that review suggests a benefit in terms of IM reversal in short-segment BE for antireflux surgery over medical therapy, whereas neither therapy modality affects long-segment BE [188]. The systematic review also found a lower incidence of EAC in surgically than in medically treated patients, although in controlled studies this risk was

not statistically significant [187]. A previous meta-analysis found no significant difference in EAC incidence between the two treatment methods [189].

The main factor proposed to contribute to the development of EAC after antireflux surgery is persistent postoperative reflux due to failed antireflux surgery. The prevalence of abnormal postoperative acid reflux has ranged from 15% to 41% [173, 190]. At a median follow-up of 8.9 years after antireflux surgery in BE patients, progression to HGD or EAC was more frequent in patients with a disrupted fundoplication (27%)—one diagnosed at endoscopy—than in those with an intact fundoplication (3%). The progression rate from BE to HGD or EAC was 2.6% per patient year in those with a disrupted fundoplication compared to 0.36% in those with an intact plication [191]. Another study showed no differences in the clinical, endoscopic, pH-monitoring, or manometric findings, or in bilirubin monitoring (by Bilitec™ monitor) between BE patients with dysplastic progression and those without progression but requiring treatment for recurrent symptoms [192]. In one study with a small number of patients, the use of antireflux medication—interpreted as a sign of persistent reflux—was associated with EAC after antireflux surgery [193]. A nested, population-based case-control study has also suggested that patients who develop EAC after antireflux surgery exhibit reflux symptoms requiring treatment more often than those who do not. BMI, smoking, or type of fundoplication did not affect EAC risk [194].

2.12 Endoscopic treatment of BE with or without dysplasia

2.12.1 Endoscopic resection

Endoscopic resection (ER) serves to remove dysplastic lesions in BE and intramucosal EAC (Figure 3 a, b). Endoscopic resections consist of endoscopic mucosal resection (EMR) and endoscopic submucosal dissection (ESD). Removal of visible lesions is important, since pretreatment biopsies predict final histology at an accuracy of only 61% [137].

Several techniques for EMR include single-band EMR, multiband mucosectomy and cap-assisted EMR. The esophageal mucosa is lifted with suction and resected by cauterization. Some techniques require a prior submucosal injection of liquid. In ESD, the tissue piece is resected by a special electrocauterized knife to enable an en-bloc resection after submucosal liquid injection [195].

The complications of endoscopic resection techniques include bleeding, perforation, and strictures. Some studies report higher perforation and stricture formation rates for ESD than for EMR [195]. Currently, ESD is reserved for larger lesions, multifocal dysplasia or neoplasia, poorly lifting lesions, and lesions at higher risk for submucosal infiltration [195, 196]. The complication rate of endoscopic resection is lower than that of surgery [195]. High rates of remission (> 80-90%) have been reported, but recurrence has also been at 6% to 30% [195, 197].

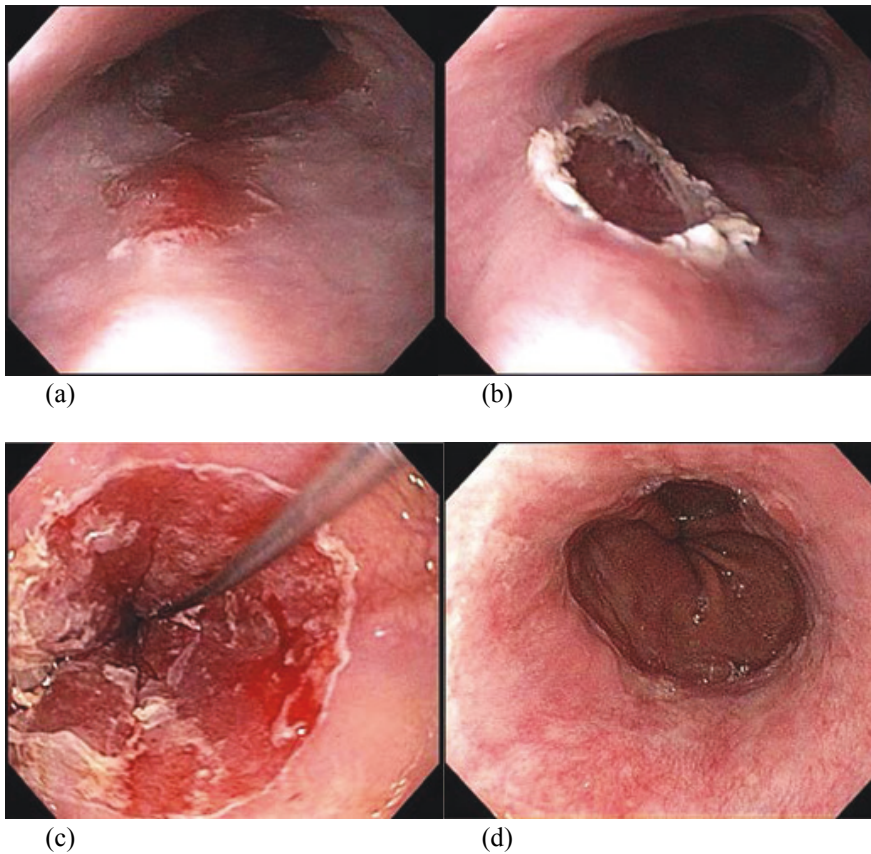


Figure 3 *An intramucosal EAC in BE (a) has been resected endoscopically (b). BE has been treated with RFA (c). Post-treatment, neosquamous esophageal mucosa (d). Reproduced and modified with permission from Massachusetts Medical Society, from Rustgi AK, El-Serag HB. Esophageal carcinoma. N Engl J Med. 371: 2499-2509, 2014.*

2.12.2 Ablation

Endoscopic ablation techniques comprise thermal ablation techniques including radiofrequency ablation (RFA) (Figure 3 c) and argon plasma coagulation, and cryotherapy and photodynamic therapy (PDT) [197], with RFA the most common method. Due to the low cancer risk in BE, the fairly common BE recurrence after ablation, and the costs and side-effects of ablation, this method is currently reserved for dysplastic BE. In one cost-effectiveness analysis, RFA seemed cost-effective for LGD, but not for non-dysplastic BE [198]. The complications of RFA include strictures (5%), pain (3%), bleeding (1%), and perforation [199].

Ablation aims to replace BE with neosquamous epithelium (Figure 3 d). This neosquamous epithelium is like the normal esophageal squamous epithelium, with regenerative changes evident especially shortly after ablation [200]. After successful RFA for neoplastic BE, the expression of Ki-67 (a proliferation marker) and p53 were normalized, and chromosomal abnormalities were undetectable in the neosquamous mucosa [201]. The neosquamous mucosa also contains mostly wild-type p16 and p53 genes, in contrast to adjacent BE [202]. The residual BE, however, shows persistent changes, such as increased Ki-67 expression and increased COX-2 and p53 expression [203, 204]. The origin of cells giving rise to the neosquamous epithelium—a reverse event in the development of BE—is unclear [200].

Effective reflux control, either medical or surgical, should be combined with endoscopic treatment of BE to lower the risk for recurrence. Recurrent intestinal metaplasia or dysplasia is most commonly found near the gastroesophageal junction and is macroscopically invisible in 40% [30]. Invisible IM at the new SCJ has been detected in 24% of patients during follow-up, most often without confirmation in the next endoscopies, however [31]. Risk for EAC persists even after successful ablation. EAC may arise from either residual or recurrent intestinal metaplasia, or from buried subquamous glandular tissue. Recurrent dysplasia or EAC can often be treated endoscopically [31, 205, 206], yet a significant number of EACs also progress to invasive disease that may be locally advanced or metastatic [207].

2.12.2.1 Efficacy of ablation

Studies exploring the efficacy of ablation methods are heterogenic in their patient material (variable proportions of patients with BE, dysplasia, and neoplasia), and the methods used (ablation methods, proportions of patients with ER). Moreover, determination of stage (HGD, intramucosal carcinoma = IMC, EAC) varies, and endpoints differ. Most studies since 2007 deal with the currently preferred RFA method [208], which has proven superior to a sham procedure or surveillance in preventing disease progression in dysplastic BE [32, 209].

In patients with BE, with or without dysplasia or neoplasia, initial eradication of intestinal metaplasia has been successful in 77% to 87%. Eradication of dysplasia or neoplasia of variable degrees has been successful in 86% to 92% of patients after RFA and possible associated EMR for focal lesions [31, 199, 209]. The results of RFA with or without EMR have improved over time, with an increasing rate of associated EMR procedures performed on focal lesions [207]. Long BE and long duration of dysplasia predispose to incomplete response (residual metaplasia or dysplasia) after four to five RFA treatments [197].

Most studies on BE ablation (with or without EMR) have reported follow-up of only 2 to 3 years. Recurrence rates have been 8% to 11% for recurrent IM and 4% to 5% for a neoplastic recurrence, but with recurrence rates sometimes as high as 33% by 2 years [30, 31, 205]. The longest follow-up available today after RFA with a prior endoscopic resection in 72% for BE with high-grade intraepithelial neoplasia or early-stage cancer, or

both, showed excellent results at the 5-year surveillance, with 90% in remission for both IM and neoplasia [210]. In contrast, a study with ablation or endoscopic resection (in a total of 81%), or both, for HGD and IMC patients found that at the 5-year follow-up, only 20% were in remission for both IM and dysplasia or neoplasia [206].

2.12.2.2 EAC risk after ablation

The rate of progression to EAC after RFA has been 0.78% annually, with mostly lower progression rates for BE, LGD, and HGD than reported for patients without ablation [211]. In other studies, the rate of patients progressing to EAC after ablation (varying histologic grades, with or without EMR) at the 1- to 1.5-year follow-up has been 0.7% to 3.6% [199, 207, 209]. However, a significant proportion (6.7%) have progressed to invasive EAC later (at a median 2.6 years) [207]. The significance of entry histology at ablation for the eradication results has been uncertain. Some studies have found that pretreatment histology may impact on both the efficacy of achieving complete eradication of BE with or without associated dysplasia or neoplasia and on the durability of the eradication, with worse results at more advanced stages [199, 212]. Other studies have not confirmed this significance for effect of pretreatment histology [205, 206, 213]. In a recent multicenter study, higher pathologic grade of BE and the longer length of BE, in addition to subsquamous pathology, predicted EAC development [211]. Annual EAC incidence after ablation was 3.0% in HGD, 0.43% in LGD, 0.15% in long-segment BE, and 0% in short-segment BE in that study of 4 698 patients. Higher entry pathology predicted mortality, and also that of EAC, which was 0.07 % annually. In the same study, of the post-ablation EAC cases, 46% were invasive, and 54% were intra-mucosal at detection, and intestinal metaplasia had been successfully eradicated earlier in only 15% and 27% of these patients [211].

Another study showed that in patients with HGD or IMC, the recurrence rate for dysplasia or neoplasia did not differ between those who achieved complete eradication of IM and those who did not [206]. Possible explanations for these differing results are varying treatment protocols in terms of technique, follow-up, and histopathologic examination, and the relatively small number of patients in each category. Frequent endoscopic surveillance, starting with 3- to 6-month intervals depending on pretreatment histology, and subsequently annually, is recommended after IM eradication [129].

2.12.2.3 Intestinal metaplasia buried under squamous epithelium

Intestinal metaplasia persisting underneath the neosquamous epithelium is a potential source for malignant development. This buried subsquamous IM occurs in BE also without ablation [209]. Buried BE is similar to non-buried BE, with a surface connection observed in 68% [200]. The frequency of post-ablation buried IM or dysplasia varies across studies and depends on treatment method. Sufficiently deep biopsies are needed to detect it. In one systematic review, buried subsquamous metaplasia was detectable in 0%

to 28% of patients before ablation, in 0.9% after RFA, and in 14.2% after PDT, and this buried metaplasia often occurred at the border of squamous and columnar epithelium [214]. In one sham-controlled trial, the prevalence of subsquamous intestinal metaplasia was lower after RFA (5% at 1 year) than before RFA (25%) in patients with dysplastic BE [209]. In recent studies, buried glands have been detectable in 0.02% to 0.08% of all the biopsies after RFA with or without endoscopic resection [31, 210].

EAC and HGD arising in the subsquamous buried glands after ablation have been detected [205, 214, 215], but the rate of progression of subsquamous IM has been unknown [10]. In a recent study, subsquamous BE (with or without dysplasia or neoplasia) before ablation predicted development of EAC, which developed at a rate of 5.0% annually. Subsquamous BE appeared in 3% of patients before IM was eradicated: 69% of the cases nondysplastic, and 5% representing EAC, and in only 0.8% after successful ablation and with no EAC detectable at that point [211]. In patients with mostly neoplastic BE, subsquamous IM has appeared in EMR resection samples of 98% patients, with 60% of the samples exhibiting a neoplastic subsquamous component [216]. After ablation with RFA or PDT for HGD or IMC, subsquamous HGD or neoplasia occurred in 2%, although benign subsquamous glands occurred only rarely [217]. One speculation is that decreased acid exposure to the cells hidden underneath the squamous epithelium may protect them. On the other hand, blockage of the glandular secretion might induce malignant development [200]. Buried BE has lower proliferation (Ki-67 expression) than does the adjacent BE [218], and after PDT, shows lower proliferation (Ki-67) than before treatment, and a normal DNA-content profile [203].

2.13 Molecular biology of GERD, BE, and EAC

2.13.1 Biomarkers

Various molecules that participate in carcinogenetic pathways have shown alterations during the development of EAC without any determining mechanism yet discovered. The goal in characterizing molecular expression is to gain means for prevention, treatment, and prognosis, and especially to find molecules to guide treatment of the various stages of GERD or EAC. These biomarkers are classified as 1) diagnostic of a condition (BE / EAC), 2) as indicating progression (of BE to malignancy), 3) as predictive of a response to therapy, and 4) as prognostic markers [18, 219]. Various molecules and genetic abnormalities appear in each category, but no single biomarker or a panel of them has yet proven useful for clinical decision-making. Based on the current marker panels, the nature of BE as being molecularly similar to GERD or EAC, or as a stage with distinctly individual molecular expression is controversial. The various alterations may occur at genetic level, in epigenetic regulation, or in expression of mRNA or of mature proteins. Potential serum biomarkers have also been evaluated, among them, antibodies to p53 [17].

Genome-wide association studies have found several loci associated with both BE and EAC [102, 220, 221]. DNA-content abnormalities at specific loci (including those of p53 [222]) and more generally (aneuploidy, tetraploidy) both predict EAC, with an enhanced effect for a combination of markers [113]. At epigenetic level, a genome-wide methylation analysis found the methylation patterns between the normal esophagus and BE or EAC to differ, while the distinction between BE and EAC was less clear [223]. Several microRNAs also show changes in BE and EAC, and have been identified as potential biomarkers. They seem not, however, to aid in distinguishing HDG or EAC from BE [224]. Clonal diversity – mostly genetic - predicts the progression of BE to EAC [225, 226], with the main determinant being diversity rather than any specific alteration [225].

Mature proteins with potential biomarker value include cell-cycle predictors (cyclin D1 both in the progression to EAC and in the prognosis of EAC), proliferation markers (Ki-67 in prognosis of EAC), tumor suppressors (p53), caudal homeobox transcription factor-2 (Cdx2) for BE, receptor tyrosine kinases, mucins, and stem cell markers [17, 219]. Aberrant p53 expression elevates the risk for progression of BE to EAC, with a higher risk from loss than from gain of its expression, and may be an even stronger predictor of progression than is low-grade dysplasia [23]. Mutated p53 also has a negative impact on prognosis in curatively resected Barrett's adenocarcinoma [227]. Additionally, p53 has been suggested as a marker for the prediction of response to chemotherapy [18, 219]. One gene expression analysis found differing sets of genes to be expressed in the normal esophagus, in BE, and in EAC, with EAC showing downregulation of many genes associated with epidermal differentiation [228]. In contrast, another gene expression study found a significant similarity between BE and EAC when compared to normal esophagus [229].

2.13.2 Caudal-related homeobox gene 2 (Cdx2)

Embryologic signaling pathways are implicated in the pathogenesis of BE [230-232]. Cdx2 is a transcription factor expressed during intestinal development in mice and a contributor to intestinal differentiation [233, 234].

Cdx2 expression has been increased by bile acids in esophageal adenocarcinoma and squamous cell lines [232], an effect enhanced by acidification in the Barrett's adenocarcinoma cell line (OE-33) [235]. In esophageal squamous cells, acid and bile salts lead to increased Cdx2 expression in cell lines from patients with BE but not in those without BE [236]. In one transgenic mouse model, Cdx2 expression in the squamous epithelium led to a transitional cell type between squamous and BE cells, with a weakened epithelial barrier [237]. Cdx2 mRNA may be found in esophageal squamous mucosa, mostly in BE patients [238, 239]. Cdx2 protein is expressed in 100% of BE samples, and only partly expressed (30%) in non-intestinalized esophageal columnar epithelium [240]. Cdx2 mRNA- and protein expression is elevated in BE and Barrett's adenocarcinoma relative to that in squamous epithelium. The Cdx2 protein expression is nuclear [241].

2.13.3 Inflammation and oxidative stress

Inflammation is implicated in the development of many cancers. Inflammatory pathways are part of the signaling networks of the tumor microenvironment [242], even in cancers not causally related to an inflammatory condition [243]. In fact, Hanahan and Weinberg have classified tumor-promoting inflammation as a factor enabling the acquisition of the hallmarks of cancers, along with genome instability and mutation [244]. The inflammation may derive from an existing inflammatory condition or from genetic events occurring in the neoplastic process [243]. In GERD, gastric and bile acids cause mucosal damage and inflammation, which may lead to the production of reactive oxygen species (ROS) and reactive nitrogen species (RNS), both of which cause DNA damage and genetic or epigenetic changes that in turn may lead to the activation of the intrinsic inflammatory pathway [245]. The relative contribution of extrinsic or intrinsic inflammation in the development of EAC is unclear. Two important cancer-promoting inflammatory pathways: the nuclear factor- κ B (NF- κ B) pathway and the interleukin 6 / signal transducer and activator of transcription 3 pathway, each seem to play a role in Barrett's carcinogenesis [245].

Inflammation activates the immune system, which also plays a role in tumor suppression. The ability of a tumor to avoid destruction by the immune system may in fact be an additional hallmark of cancer [244]. The immune responses—the type of cytokines, and the type of T-cells in the squamous epithelium—between reflux esophagitis and BE differ [246, 247]. In reflux esophagitis, esophageal mucosa expresses proinflammatory and T helper-1 type cytokines, whereas in BE it expresses T helper-2 type cytokines [246]. The tumor microenvironment of EAC may be dominated by immunosuppressive molecules [248].

Oxidative stress, ROS and RNS, also may contribute to the acquisition of all the capabilities essential for tumor development reported by Hanahan and Weinberg: self-sufficiency in growth signals, insensitivity to anti-growth signals, limitless replicative potential, avoidance of apoptosis, sustained angiogenesis, tissue invasion, and metastatic potential [249, 250]. Markers of oxidative stress studied in GERD, BE, and EAC include 8-hydroxydeoxyguanosine (8-OhdG), a marker of oxidative DNA damage; DNA-adducts; myeloperoxidase (MP), a peroxidase enzyme produced by inflammatory cells; superoxide dismutase (SOD) that turns the superoxide radical into oxygen and hydrogen peroxide; and glutathione (GSH), a redox buffer balancing the actions of ROS. Oxidative stress has been increased in BE and in associated dysplasia or neoplasia, appearing as increased 8-OhdG and MP levels and as increased DNA-adducts [251-254]. Most often, no progressive trend in oxidative stress has been found in the metaplasia–dysplasia–EAC sequence [251, 252, 255], although some results suggest otherwise [253]. Findings concerning antioxidant GSH content and SOD activity are conflicting. GSH content has been diminished in all stages of GERD to EAC, but in esophagitis, increased levels have also occurred [252, 254, 256]. Whereas the expression of SOD in GERD seems increased, its activity has been reduced, unchanged, or increased in esophagitis and BE, and increased in dysplastic BE [252, 254-256]. After antireflux surgery, both the oxidative

stress and antioxidant capacity in the esophageal mucosa have decreased (the levels of MP and GSH decreased), but not normalized, even 4 years postoperatively [257].

2.13.4 ADAMs

A disintegrin and metalloproteinases, ADAMs, are molecules belonging to the metzincin superfamily of proteases that participate in many signaling activities [20]. In addition to the metalloproteinase domain responsible for their proteolytic activity, ADAMs possess various domains that extend their capabilities, entailing a disintegrin domain with a possibility to interact with integrins, a cystein-rich domain for cellular adhesion, an EGF-like domain, a transmembrane domain, a cytoplasmic tail (containing regulatory phosphorylation and SRC 3 homology domain-binding domains), and a prodomain the removal of which activates the metalloproteinase domain [258].

ADAMs are able to cleave many signaling molecules involved in cancer, including tumor necrosis factor alpha and transforming growth factor beta, as well as cellular adhesion molecules (E-cadherin, CD44) [20, 259, 260], all of which have been implicated in EAC, or in the malignant progression of BE [261-263]. Studied in cell lines, ADAM9 expression has been promoted by oxidative stress, which may also contribute to the invasive potential of neoplastic cells [264, 265]. ADAM-integrin interaction may play a role in this cellular invasion [265]. Increased expression of ADAMs has emerged in many human cancers at mRNA- or protein level [20], including many adenocarcinomas, like gastric or breast cancer [21, 266, 267]. ADAM-protein expression in cancer has been localized in the cytoplasm and the cell surface [21, 266]. In EAC, many ADAMs have shown increased expression at mRNA level, with no information on this at protein level or in GERD or BE, however. The mRNA levels of ADAMs 9, 10, 12, 17, and 19 were approximately 1.6- to 3.8-fold increased in cancer compared to adjacent normal tissue, with the highest increase for ADAM12 [22]. ADAMs 12 and 19 have been increasingly hypermethylated both in BE and in EAC [223], suggesting their suppressed expression. Expression of ADAMs has been associated with prognosis in many cancers. In gastric cancer, ADAM10 expression is associated with more advanced disease, and with poorer survival in stages I to III [268]. High ADAM9 expression is associated with shorter survival in curatively resected stage I non-small cell lung cancer [269]. Similarly, high ADAM17 expression is associated with shorter survival in breast cancer [270]. Observations of the role of ADAM expression in cancer have led to investigations of the usefulness of anti-ADAM medication [46]. One inhibitor of ADAM17 has been shown to reduce proliferation in breast cancer cell lines and to sensitize them to chemotherapeutic agents [271].

Many of the molecules shed by ADAMs participate also in inflammatory processes [19]. In *Helicobacter pylori*-infected gastric mucosa and in gastric cancer, expression of ADAM 10 and 17 mRNA has been increased [267]. In epithelial-mesenchymal transition, a key process in the ability of a tumor to invade, an important event is the loss of E-cadherin. Patients with NERD or ERD have increased junctional permeability along with

cleavage of E-cadherin in their distal esophagus, and ADAM10 seems to play a role in in that cleavage [272].

2.13.5 c-MYC and CIP2A

c-MYC is an oncogenic transcription factor that can either induce or repress gene expression, with any changes resulting from its overexpression depending on cell type [273]. c-MYC participates in cellular processes such as apoptosis, differentiation, and proliferation. It is increased in many cancers such as gastric cancer and colonic adenocarcinoma [273]. It is also overexpressed in 73% to 90% of EAC cases, and in 37% to 50% of BE cases [274, 275]. Its expression rises in a linear fashion from controls to BE, BE with dysplasia, and EAC [274]. In BE, c-MYC is expressed in the nucleus, but with BE progression cytoplasmic staining increases. Due to its expression's being already frequent in BE, one suggestion is that in BE progression, other dysregulations—such as mutated p53—act synergistically. Bile acids, in an acidic environment, induce c-MYC expression in vitro [275]; also in vitro, c-MYC has induced the development of ROS [276].

Closely linked to c-MYC, the cancerous inhibitor of protein phosphatase 2A, CIP2A, is an oncogene increased in many human cancers [25]. As its name implies, it inhibits the tumor-suppressor protein phosphatase 2A (PP2A). PP2A regulates transcription factors such as p53 and c-MYC, and inhibition of its function in dephosphorylating c-MYC is one factor required for malignant cellular transformation. CIP2A inhibits PP2A by interacting directly with c-MYC and thereby protecting it from degradation [24]. c-MYC and CIP2A promote each other's expression in a positive feedback loop [277]. CIP2A promotes cellular growth and transformation, and promotes tumor growth (in mice) [24], and also acts independently of PPA2 in processes such as mitosis and cell-cycle progression. Its depletion leads to impairment in mitosis and delay in cell division [278].

CIP2A expression is increased in various cancers, including gastric, colorectal, and esophageal squamous cell carcinoma [24, 26-28]. CIP2A positivity has appeared in 90% of gastric cancer and of esophageal squamous cell carcinoma cases, whereas in normal tissues, it has appeared in 27% of gastric mucosa and 20% of esophageal mucosa [26, 27]. Increased CIP2A protein expression is mainly cytoplasmic in gastric and in colon cancer [26, 28]. In cancer cell lines, CIP2A depletion leads to impaired growth and clone formation, and to cellular senescence [26, 27]. In gastric cancer (with tumors ≤ 5 cm), CIP2A expression has been associated with reduced survival [277]. In other cancers as well, such as liver, colon, and pancreatic cancer, CIP2A plays a role as a prognostic factor [25]. CIP2A expression may also predict response to various antitumor agents. Targeting CIP2A instead of MYC in cancer treatment might be beneficial, since MYC function is essential for normal cells, but that of CIP2A does not seem to be [24, 25]. The overexpression of CIP2A is associated with both the expression of nuclear c-MYC and with p53 in colorectal cancer [28]. In breast cancer, CIP2A mRNA expression is associated with p53 mutation [279].

3 Aims of the study

1. A distegrin and metalloproteinases, ADAMs, are implicated in both inflammatory processes and cancer. They have been preliminarily found to be overexpressed in EAC. We aimed to define their expression in the development of EAC through the esophagitis–metaplasia–dysplasia–EAC sequence.
2. CIP2A is an oncogene overexpressed in many cancers. Its expression has often had a prognostic impact. We aimed to investigate its expression in EAC, together with the interacting oncogene c-MYC, and also the possible influence of both on EAC prognosis.
3. The effectiveness of BE ablation and the properties of the neosquamous mucosa have been unknown at long-term follow-up. We aimed to assess the long-term effects of laser ablation of BE, combined with antireflux surgery, on the recurrence of BE, on oxidative stress, and on the malignant potential of the neosquamous mucosa.
4. The incidence of EAC after antireflux surgery at population level has been unknown, and we aimed to define this incidence at a 20-year interval in Finland. The factors causing EAC to occur after antireflux surgery are disputable, so we explored factors that might predispose to EAC after antireflux surgery, such as anatomic and functional failure of antireflux surgery.

4 Patients, materials, and methods

4.1 Patients and materials

Study I

Esophageal biopsies were collected from patients presenting for a diagnostic or therapeutic upper gastrointestinal endoscopy or esophageal surgery in Helsinki University Hospital during 2007 - 2010. Samples were collected at the different stages of GERD: esophagitis (mild in 11, severe in 5), BE (20 patients), BE with low-grade dysplasia (5) and with high-grade dysplasia (7), and EAC (20). Patients with normal histological esophageal mucosa (26) served as controls. Of the EAC cases, 7 (35%) were Siewert I tumors, and 13 (65%) were Siewert II, and 5 (25%) patients had received neoadjuvant treatment. Differentiation of EAC cases was quite uniformly distributed between good (30%), moderate (35%), and poor (35%). Preliminary analysis of the expression of a disintegrin and metalloproteinases (ADAMs) was conducted with cell lines of a Barrett's adenocarcinoma (OE33) and of an adenocarcinoma of the gastroesophageal junction (OE19). We used the cell line Het-1A (from normal esophageal tissue, and transfected with a Simian Virus 40 large T antigen) as a control cell line.

Study II

This study included EAC patients from Tampere University Hospital in 1990-2007 and those surgically treated for EAC at Helsinki University Hospital during the same years, and with available tissue material, totaling 127. Of these patients, 72 (57%) had undergone surgical treatment for their cancers. 97.6% had cancer in either the distal esophagus or in the esophagogastric junction. Samples also included numbered 5 from the squamous tissue near the tumor, and 33 from BE from the cancer patients.

Study III

Patients comprised those 18 treated with neodymium-yttrium-aluminum-garnet (Nd-YAG) laser ablation of Barrett's esophagus and antireflux surgery for GERD at Helsinki University Central Hospital during 1992-2005 and available for follow-up by upper gastrointestinal endoscopy. One additional patient diagnosed with gastric cardia adenocarcinoma (distal from fundoplication) 4.3 years after ablation had been excluded. Sixteen patients had undergone a complete fundoplication (three laparoscopic, one combination of laparoscopy and minilaparotomy), one had open partial posterior fundoplication, and one underwent partial gastrectomy with Roux-en-Y reconstruction with vagotomy and fundophrenicopexy. Esophageal pH-monitoring was normal in all the 17 patients who underwent it. The average BE length before ablation was 3.6 cm (range 0.5–6 cm). Controls for the oxidative stress analysis were patients without GERD

symptoms or esophageal pathology at endoscopy (numbering 14 or 9 depending on the substance measured).

Study IV

The Finnish Cancer Registry provided information on all the 1035 patients with a diagnosis of esophageal adenocarcinoma during 1980-2006 in Finland. From the National Institute for Health and Welfare (THL), records covered the 19 542 patients who underwent antireflux surgery during 1987-2006 (registry data available since 1987). Patient records of all EAC patients allowed identification of all those with a previous antireflux surgery. Their patient records were ordered from the hospitals that had provided the information for the Cancer Registry, and death certificates of those with insufficient information came from Statistics Finland. Final analysis was conducted on 53 EAC patients with prior antireflux surgery. Analysis of the standardized incidence ratio of EAC after antireflux surgery involved the antireflux surgery patients of 1987-2006 and an age-, sex- and calendar-period-matched Finnish population.

4.2 Methods

4.2.1 Acquisition of clinical data

In Study I, basic data were collected on the patient characteristics and tumor location as well as on neoadjuvant treatment.

In Study II, data were collected on the type and location of the tumor, the treatment and the disease state of the patients.

For Study III, the macroscopic state of the esophageal mucosa and the state of the fundoplication were assessed during an upper gastrointestinal endoscopy. Data on the antireflux surgery and laser treatment came from patient records.

In Study IV, records were thoroughly surveyed of all patients with a previous antireflux surgery. Data were collected on the patients' history of GERD (such as BE, hiatal hernia, esophagitis) before and after antireflux surgery, on smoking or alcohol use, medications affecting GERD, type and time of antireflux surgery and the outcome of antireflux surgery in follow-up, and the diagnosis of EAC.

4.2.2 Acquisition of tissue samples

In Study I, tissue samples were taken from approximately 2 and 15 cm above the gastroesophageal junction. For mRNA analysis, the samples were placed in RNAlater (Qiagen, Hilden, Germany) and for protein analysis, were either fast-frozen or placed directly into formalin.

In Study II, tissue samples were formaldehyde-fixed, paraffin-embedded samples collected earlier for diagnostic and therapeutic purposes.

For Study III, biopsy samples were drawn during esophago-gastroscopy from the squamous epithelium of the esophagus at 1, 3, and 15 cm above the squamocolumnar junction. For the control group, samples were drawn at 5 cm and at 20 cm (for 8-OHdG) above that junction. Samples were either fast-frozen (for the oxidative stress analysis) or placed in formalin (for immunohistochemistry).

4.2.3 Histologic analysis

In Studies I to III an experienced pathologist analyzed the histology.

4.2.4 Oxidative stress analysis

Analysis of 8-OHdG, SOD, GSH, and MP levels took place at the MCA Research Laboratory Ltd. in Turku, Finland. The techniques have been described previously: 8-OHdG was measured by high-performance liquid chromatography with an electrochemical detector (and a ultra violet-detector for deoxyguanosine) [251]; SOD activity was measured by the method of Laihia and colleagues [280]; GSH content was measured by Saville's method [281]; MP activity was measured with Suzuki's modified method [282]. Concentrations are expressed as the ratio of 8-OHdG per 10^5 dG (8-OHdG), units/mg protein (SOD, MP), and nmol/mg protein (GSH).

4.2.5 mRNA quantification

In Study I, mRNA was isolated with the RNeasy Mini Kit (Qiagen, Germantown, MD, USA) for cell lines, and with the RNeasy Fibrous Tissue Mini Kit (Qiagen) for tissue samples that were first homogenized. Reverse transcription was performed with the High Capacity cDNA Archive Kit (Applied Biosystems, Foster City, CA, USA) and reverse transcription-PCR (RT-PCR) was then performed and cDNA measured with ABI Prism 7000 Sequence Detection Software with Taqman technology. Primers (ADAM9: Hs00177638_m1, ADAM10: Hs00153853_m1, ADAM12: Hs01106104_m1, ADAM17: Hs00234224_m1, and ADAM19: Hs00224960_m1) were from Applied Biosystems. The

results were standardized with a dilution batch of the cell line NCI-N87 run in every plate, and in cell lines with glyceraldehyde-3-phosphate dehydrogenase (GAPDH) expression and in tissue samples also with beta-actin expression.

4.2.6 Protein quantification

In Study I, after extraction of the proteins from the cell lines, the Quant-it kit (Invitrogen, Eugene, OR, USA) and a fluorescence plate reader (Wallac 1420, Perkin-Elmer, Turku, Finland) served for protein quantification by Western blotting. An Odyssey infrared scanner (LI-COR, Lincoln, NE, USA) served for protein detection after incubation with primary antibodies at a dilution of 1:1000 (ADAM9: sc-23290, ADAM12: sc-25579, and ADAM19: sc-25988 from Santa Cruz Biotechnology, and ADAM10: AB936, and ADAM 17: MAB9302 from R&D Systems) and secondary antibodies at a dilution of 1:15 000 (Donkey-anti-goat Alexa Fluor 680, A21084, Invitrogen; Goat-anti- rabbit Alexa Fluor 680, A21109, Invitrogen; Goat-anti- mouse Alexa Fluor 680, A21058, Invitrogen; IRDye 800CW Donkey-anti-Rabbit, 926-32213, LI-COR Bioscience; IRDye 800CW Goat-anti-Mouse, 926-32210, LI-COR Bioscience; IRDye 800CW Goat-anti-Rabbit, 926-32213, LI-COR Bioscience). Results were standardized with GAPDH expression.

For immunohistochemistry (IHC), samples from 6 controls, 3 patients with severe esophagitis, 3 with BE, 5 with dysplastic BE, and 7 with esophageal adenocarcinoma were selected irrespective of their mRNA expression. After antigen retrieval from the formalin-fixed, paraffin-embedded samples, and after blocking, the glasses were incubated with primary (ADAM9: AB19024, dilution 1:400, Millipore; ADAM10: AB936, 1:750, R&D Systems; ADAM12: LS-B2756, 1:2000, LifeSpanBioSciences; ADAM17: HPA010738-100UL, 1:50, Sigma-Aldrich; and ADAM19: sc25988, 1:200, Santa Cruz Biotechnology) and secondary antibodies [ImmPRESS™ Reagent Kit peroxidase, Anti-Goat Ig and Universal Anti-Mouse/Rabbit Ig (Vector Laboratories, Burlingame, CA, USA)] and then coated. The staining was classified as 0=no staining, 1=mild staining, 2= medium and 3=strong, and analyzed by two of the researchers.

In Study II, immunohistochemical analysis of CIP2A and c-MYC expression was performed by a tissue microarray technique (TMA). Three representative regions chosen from surgical samples were sorted into multitissue blocks. Biopsy samples were prepared as paraffin blocks. Staining was performed with the Ventana BenchMark Series automated slide preparation system (Ventana Medical Systems, Tucson, AZ, USA). A rabbit polyclonal anti-human antibody served to detect CIP2A (1:100, Bethyl Laboratories Inc, Montgomery, TX, USA) and a mouse monoclonal antibody for c-MYC (1:150, Novocastra, Newcastle, UK). Staining intensity was classified into four categories (0=negative, 1=weak, 2=moderate, 3=strong), and staining extensiveness was also classified into four categories (0=negative; 1= weak, 0-30%; 2=moderate, 30-60%; 3=strong, 60-100%). The integration of these scores yielded an overall score used for analyses. Staining was scored independently by two researchers, with the highest score of the three samples chosen for analysis.

In Study III, immunohistochemical staining to detect caudal-related homeobox gene 2 (Cdx-2) and p53 was performed for 13 patients by Histola Research Ltd (Tampere, Finland) with the NCL-p53-DO-7 antibody for p53 (LeicaMicrosystems, Wetzlar, Germany) and the Cdx-88 antibody for Cdx-2 (Biogenex, Fremont, CA, USA).

4.2.7 Statistical analysis

Statistical analysis was conducted with SPSS software versions 14.0-22.0 (SPSS Inc., Chicago, IL, USA). A p-value ≤ 0.05 was considered statistically significant.

In Study I, the Kolmogorov-Smirnov test served for assessing the normality of the data. Student's t-test (paired/unpaired), the Mann-Whitney and Wilcoxon signed-rank tests were used accordingly. ANOVA with Dunnett's test for correction of multiple comparisons, and Kruskal-Wallis and Dunn tests for correction of multiple comparisons were also used accordingly. The ADAM expression trend during the control–esophagitis–metaplasia–dysplasia–EAC sequence was analyzed by the Jonckheere-Terpstra test.

Study II statistics comprised the chi-square test, Cox regression survival models, multinomial regression models, and the Pearson correlation coefficient.

Study III used Shapiro-Wilk's test (to assess normality of the data) and the Mann-Whitney test.

Study IV used an unpaired t-test for continuous variables and chi-square or Fisher's exact test for categorical variables. The standardized incidence ratio (SIR) was calculated in the Finnish Cancer registry.

5 Results

5.1 ADAM expression profile in GERD and in EAC

5.1.1 ADAM expression in cell lines

ADAMs 9 and 17 showed increased expression of mRNA in the EAC cell lines (ADAM17 in OE33 only) (Figure 4). The mRNA expression of the other ADAMs studied was diminished (Figure 4). The mature protein form at 75 kD of ADAM9 was increased in OE33 [integrated intensity 14.1, standard error of mean (SEM) 2.4] as compared to Het-1A (1.3, SEM 0.19), $p < 0.001$, whereas another mature form, observable at 80 kD, was decreased both in OE33 (integrated intensity 0.49, SEM 0.22 vs. Het-1A 2.6, SEM 0.44, $p = 0.0031$) and in OE19 (integrated intensity 0.18, SEM 0.15 vs. Het-1A 2.6, SEM 0.44, $p = 0.0026$). For ADAM10, both the precursor form at 80 kD and the mature protein form at 60 kD were increased in OE33 (integrated intensity for the precursor form 0.65, SEM 0.11 vs. Het-1A 0.073, SEM 0.027, $p = 0.0011$; and for the mature form 0.36, SEM 0.11 vs. Het-1A 0.0041, SEM 0.0075, $p < 0.001$), and in OE19 (integrated intensity for the precursor form 0.26, SEM 0.047 vs. Het-1A 0.073, SEM 0.027, $p = 0.0095$; and for the mature form 0.26, SEM 0.012 vs. Het-1A 0.0041, SEM 0.0075, $p < 0.001$). For the other ADAMs, no changes were detectable in their protein expression (ADAM12: a precursor form detected, ADAM17: a precursor and a mature form detected, ADAM19: small fragments detected).

ADAM mRNA expression in cell lines

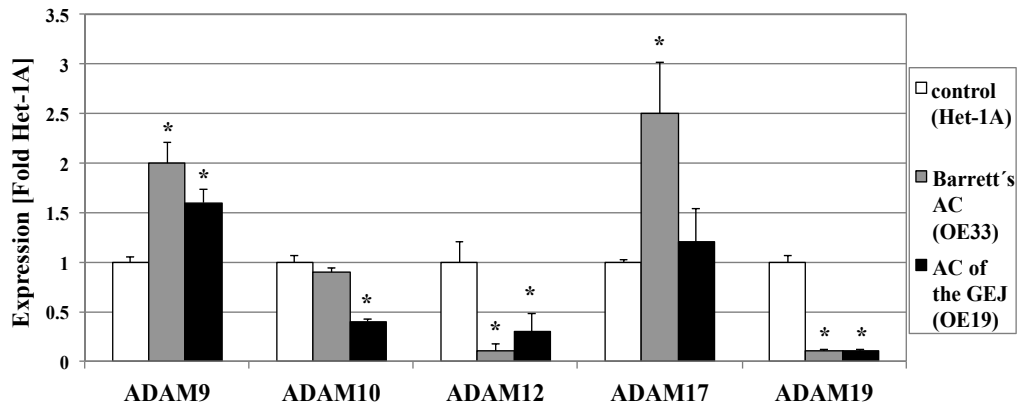


Figure 4 *ADAM mRNA expression in esophageal cell lines. Expression is reported as relative to that in Het-1A (expression = 1), and corrected with GAPDH-expression. * $p \leq 0.05$ between the EAC lines and Het-1A. Error bars indicate standard error of the mean. AC = adenocarcinoma, OE33 = cell line of Barrett's adenocarcinoma, OE19 = cell line of adenocarcinoma of the gastroesophageal junction. Reproduced and modified from Kauttu T, Mustonen H, Vainionpää S, Krogerus L, Ilonen I, Räsänen J, Salo J, Puolakkainen P. Disintegrin and metalloproteinases (ADAMs) expression in gastroesophageal reflux disease and in esophageal adenocarcinoma. *Clin Transl Oncol.* 19:58-66, 2017. With permission of Springer.*

5.1.2 ADAM expression in human samples

ADAM mRNA expression varied in different stages of GERD as shown in Figure 5. All the ADAMs studied exhibited differential mRNA expression across groups (ADAM9 $p=0.002$, ADAM10 $p=0.007$, ADAM12 $p<0.001$, ADAM17 $p=0.001$, ADAM19 $p=0.002$). For ADAMs 9, 12, and 19, a rising trend emerged in their mRNA expression during the progressive stages of GERD (ADAM9 $p=0.001$, ADAM 12 $p<0.001$, ADAM19 $p<0.001$). Neither ADAM10 nor ADAM17 mRNA showed such a trend.

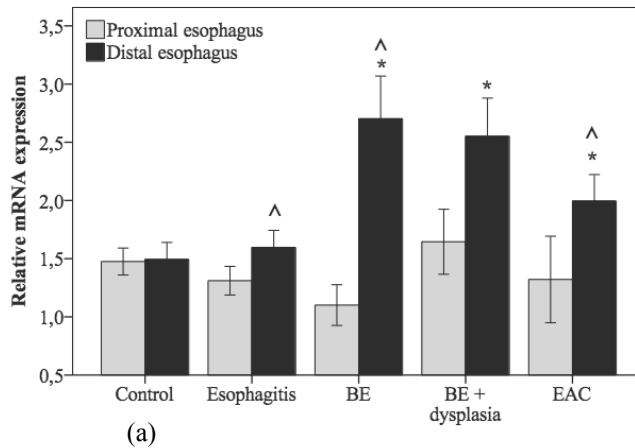
In the subgroup analyses, distal ADAM mRNA expression in severe esophagitis was increased in comparison to mild esophagitis for ADAM12 (median 281.0, range 29.8-3302.3 vs. median 14.6, range 5.2-67.6; $p=0.010$) ADAM17 (median 0.9, range 0.8-1.4 vs. median 0.8, range 0.3-1.4; $p=0.014$) and ADAM19 (median 5.9, range 3.5-32.3 vs. median 1.6, range 0.5-6.2; $p=0.006$). ADAM9 was increased in Siewert 1 tumors in comparison to Siewert 2 tumors (median 3.0, range 1.8-5.9 vs. median 1.6, range 0.8-4.2; $p=0.036$). Neither neoadjuvant treatment, nor cancer differentiation, nor dysplasia grade had any impact on ADAM expression (data not shown).

In the protein expression analysis by immunohistochemistry, for normal squamous epithelium, only ADAM19 showed mild-moderate cytoplasmic expression and, rarely, ADAM12 was localized to cytoplasmic granules centered apically. ADAMs 9, 10, or 17 were not distinctly expressed. In the glandular tissues, ADAM expression was more

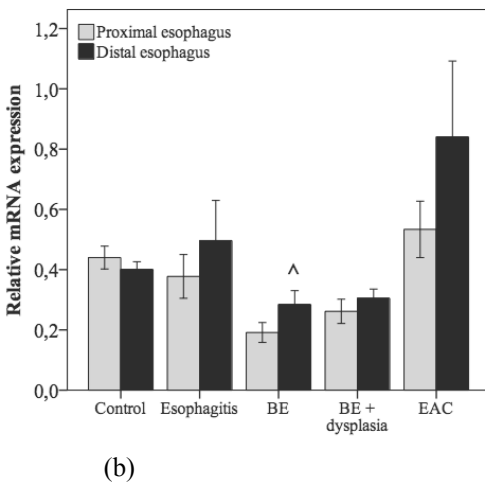
often evident. Expression was mostly cytoplasmic; nuclear expression was also detectable in some EAC samples.

ADAM9 protein was increased in EAC relative to that in controls (median 1, range 1–2 in EAC vs. median 0.5, range 0–1, $p=0.026$), but in BE or dysplastic BE, its expression did not differ from controls'. ADAM10 protein was also increased in EAC (median 2, range 1–2 in EAC vs. median 1, range 0–1 in controls, $p=0.021$), but no statistically significant increase was detectable for BE or dysplastic BE. Dysplastic BE showed more uniform ADAM10 distribution than did BE, with a predisposition for basal ADAM10 expression. ADAM12 protein was not differently expressed between patients and controls. ADAM17 protein was increased in BE (median 2, range 2–2 vs. median 0.5, range 0–1 in controls, $p=0.024$). ADAM19 protein was not differently expressed between patients and controls, although it was expressed at all stages. A shift occurred from its basal localization to a more apical staining pattern in EAC.

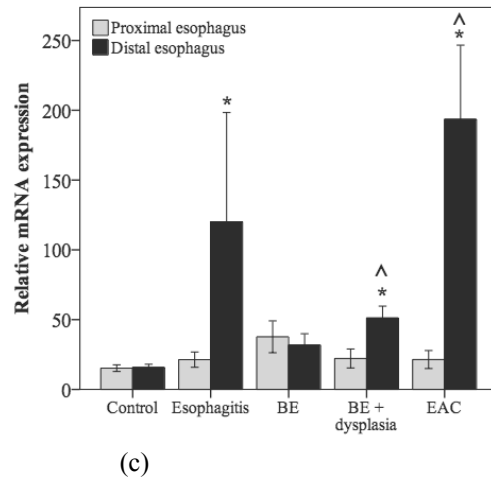
ADAM9



ADAM10



ADAM12



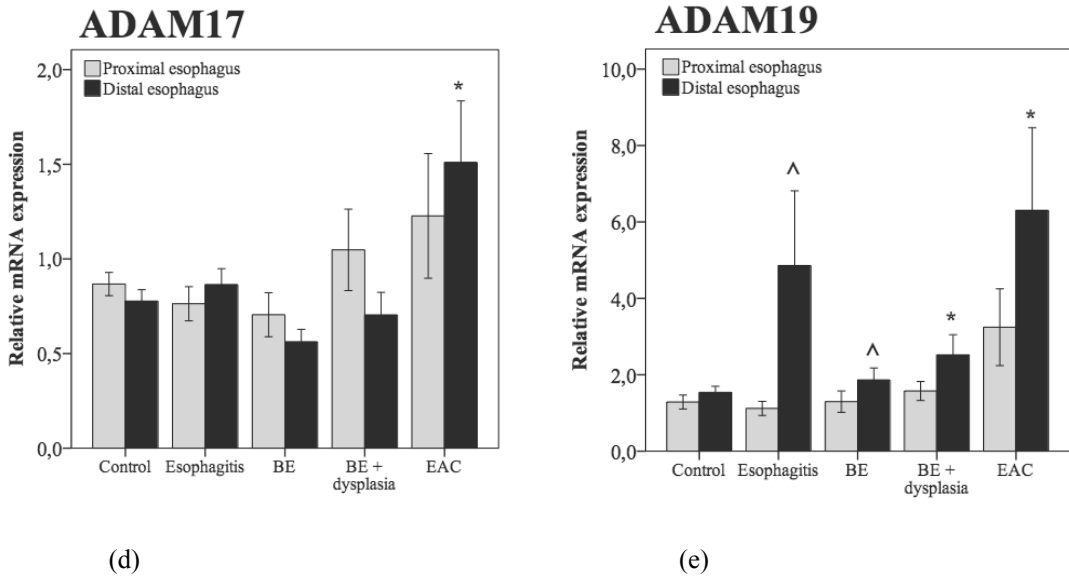
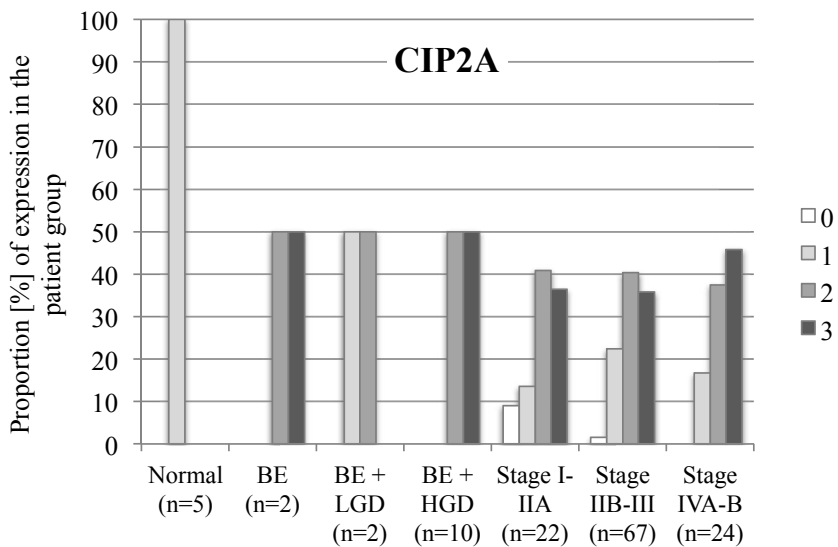


Figure 5 *ADAM* mRNA expression in human samples of distal and proximal esophagus, representing GERD and EAC pathology at different stages, (a) *ADAM9* (b) *ADAM10* (c) *ADAM12* (d) *ADAM17* (e) *ADAM19*. * = ≤ 0.05 in ANOVA / Dunnnett's or Kruskal-Wallis / Dunn's test comparisons between patients and controls, and ^ = $p \leq 0.05$ in paired t-test or Wilcoxon signed rank test comparisons between distal and proximal patient samples. Error bars indicate the standard error of mean. Values represent relative expression as compared to the expression in NCI-N87 cell line, corrected by GAPDH and beta actin expression. Reproduced and modified from Kauttu T, Mustonen H, Vainionpää S, Krogerus L, Ilonen I, Räsänen J, Salo J, Puolakkainen P. Disintegrin and metalloproteinases (*ADAMs*) expression in gastroesophageal reflux disease and in esophageal adenocarcinoma. *Clin Transl Oncol.* 19:58-66, 2017. With permission of Springer.

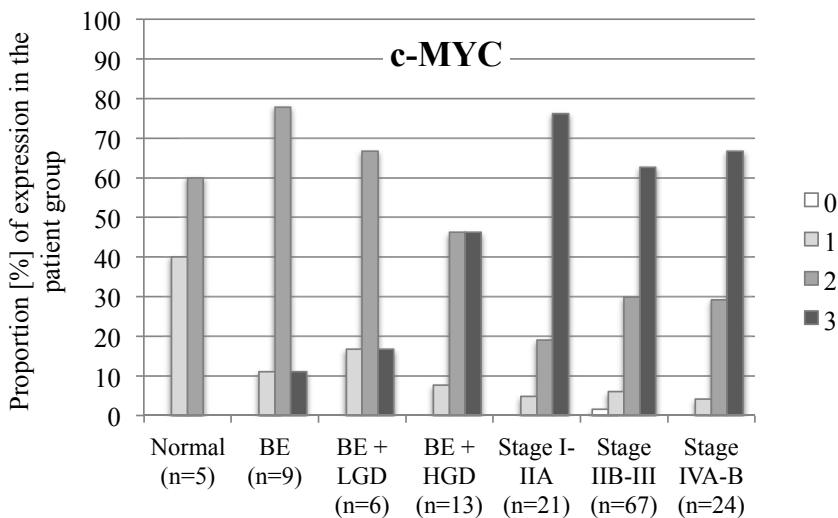
5.2 CIP2A and c-MYC expression in EAC

Immune staining scores of CIP2A and c-MYC proteins relative to EAC and BE stages are presented in Figure 6. CIP2A expression was mainly cytoplasmic. The staining grade of both CIP2A and c-MYC in BE and EAC differed from that in control samples ($p = 0.008$ and 0.030 , respectively). Staining grade of CIP2A and c-MYC correlated with each other ($R = 0.21$, $p = 0.018$).

Neither CIP2A nor c-MYC expression affected survival in Cox regression analysis. Among patients with the most advanced (stage IVA-B) tumors, CIP2A expression showed a trend towards poor prognosis ($p = 0.074$).



(a)



(b)

Figure 6 *CIP2A* (a) and *c-MYC* (b) expression in the normal esophageal squamous epithelium, in different stages of BE, and in different EAC stages. Data from Rantanen T, Kauttu T, Åkerla J, Honkanen T, Krogerus L, Salo J, Paavonen T, Oksala N. *CIP2A* expression and prognostic role in patients with esophageal adenocarcinoma. *Med Oncol.* 30:684, 2013.

5.3 Long-term effects of laser ablation for BE

Laser ablation for BE with previous antireflux surgery had resulted in histologic eradication of IM in 15 patients (83%). After a mean follow-up of 7.9 years (range 2.7–15.4 years), 10 patients (56%) had complete eradication of IM. Of those 15 patients with initial eradication of IM, 3 (20%) had a recurrence of macroscopic BE, and 5 (33%) had a recurrence of IM. A total of 6 patients (33%) had macroscopic BE, and 8 (44%) had IM detected histologically. The average change in BE length was -2.7 cm (range -6 to 4 cm). Neither dysplastic changes nor buried columnar tissue appeared. Fundoplication was determined as anatomically normal at endoscopy in 14 patients (82%). Of the 8 patients with IM detected at the control endoscopy, 3 had disrupted funduplications, and one had partial gastrectomy with Roux-en-Y reconstruction. 3 patients (17%) were taking PPI regularly, and 3 occasionally.

8-OHdG levels were increased both in the distal and proximal esophagus, compared to controls' (Figure 7 a, b). SOD activity was increased in the distal esophagus, compared to controls' (Figure 8 a), whereas MP activity and GSH level were normal (Figure 8 b, c). Microscopic esophagitis, presence of IM, or failure of fundoplication did not affect results. Two patients with microscopic esophagitis showed weak nuclear p53 expression typical of inflammation. One patient showed Cdx2 expression in IM.

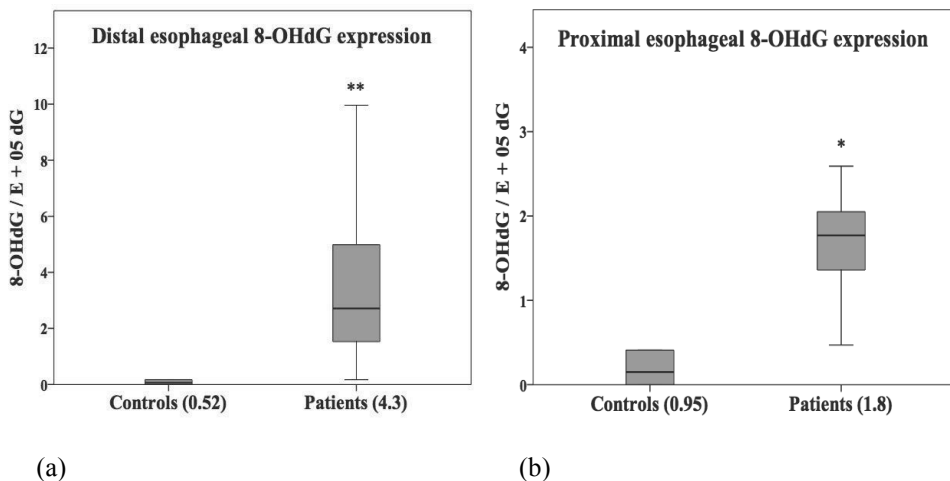


Figure 7 8-OHdG levels in the distal (a) and proximal esophagus (b) of patients treated with Nd-YAG laser ablation, and in controls. * $p < 0.01$, ** $p < 0.001$. The average 8-OHdG-level in each group is given in brackets. Reproduced and modified from Kauttu T, Räsänen J, Krogerus L, Sihvo E, Puolakkainen P, Salo JA. Long-term results of ablation with antireflux surgery for Barrett's esophagus: a clinical and molecular biologic study. *Surg Endosc.* 26:1892-7, 2012. With permission of Springer.

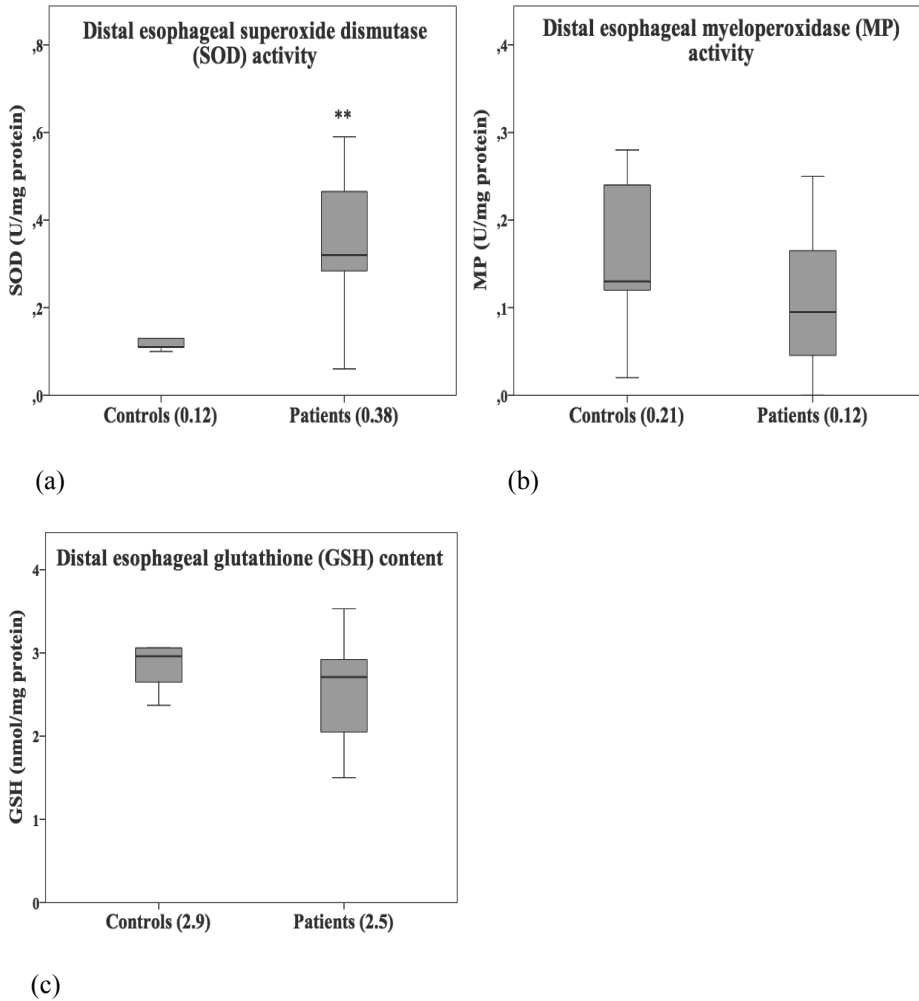


Figure 8 Activities of SOD (a) and MP (b), and GSH content (c) in the distal esophagus of patients treated with Nd-YAG laser ablation, and in controls. ** $p < 0.001$. The average SOD / MP / GSH -level in each group is given in brackets. Reproduced and modified from Kautu T, Räsänen J, Krogerus L, Sihvo E, Puolakkainen P, Salo JA. Long-term results of ablation with antireflux surgery for Barrett's esophagus: a clinical and molecular biologic study. *Surg Endosc.* 26:1892-7, 2012. With permission of Springer.

5.4 EAC after antireflux surgery

During 1987-2006, EAC incidence (as the standardized incidence ratio, SIR) after antireflux surgery was increased 9.2-fold (95% confidence interval 6.2-13.2) (men 9.3-fold increase, women, 8.6-fold increase) compared to rates in the general population. The annual number of EAC cases diagnosed in Finland during the study period increased (Figure 9).

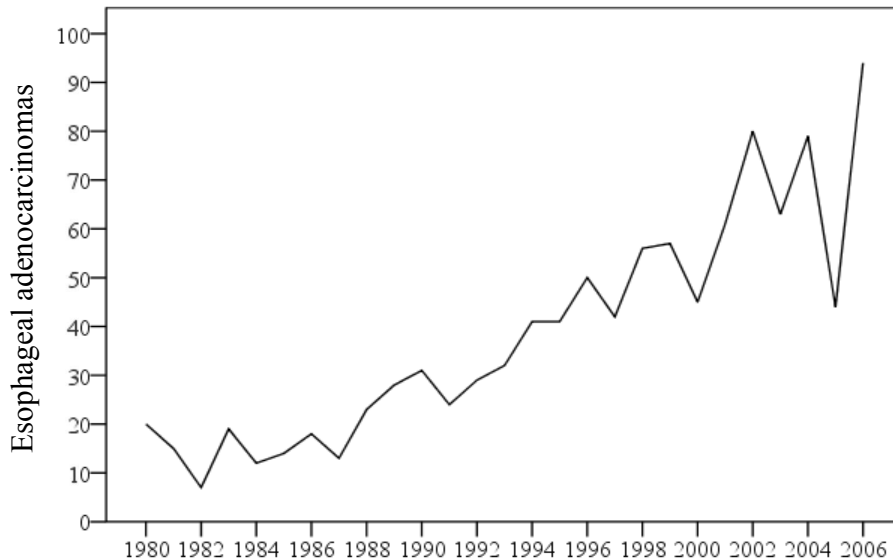


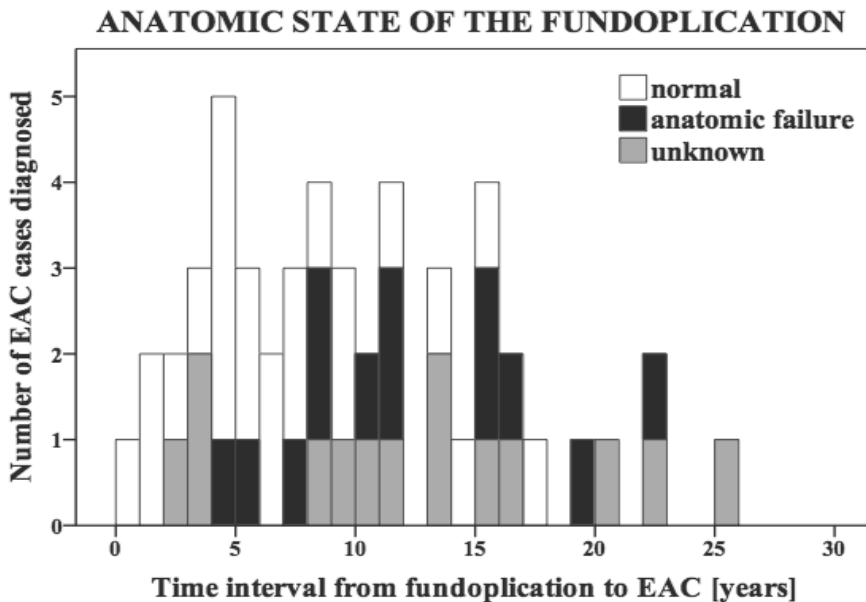
Figure 9 EAC cases diagnosed annually in Finland during 1980-2006.

Of the 53 EAC patients with a previous antireflux surgery, 39 were male. 19 patients (36%) were smokers, but information on smoking status was available for only 24 (45%). EAC was diagnosed on average at 10.1 years (range 0.5–25.6 years) after antireflux surgery; 32% of cases were diagnosed at 5 to 10 years after antireflux surgery, and 43% over 10 years after antireflux surgery. Less than half (40%) of the cases were diagnosed at endoscopic surveillance. Of the 38 patients with available GERD symptom data (72%), 89% had typical symptoms of heartburn or regurgitation, or both, and 79% had used either PPIs or H2RAs. BE was diagnosed before the antireflux surgery in 45% (one patient with non-specified dysplasia and one with HGD), and postoperatively or at EAC diagnosis in an additional 34%, leading to a total of 79% of the patients with histologically confirmed BE. Endoscopic esophagitis had been diagnosed in 41 (77%) and a hiatal hernia in 40 (75%) preoperatively.

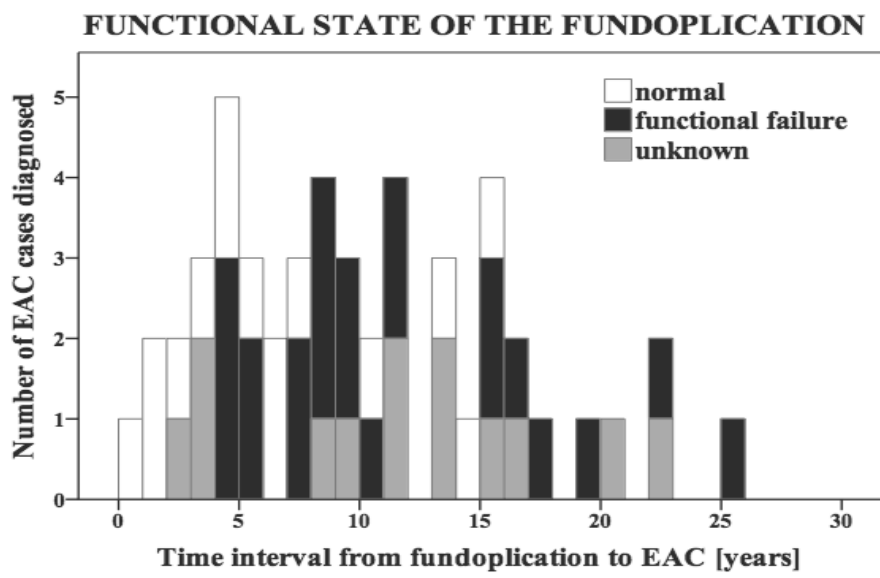
The type of antireflux surgery was fundoplication in 50 patients (15% laparoscopic, and 95%—among those 44 with available data—complete 360° funduplications) and partial gastrectomy with Roux-en-Y reconstruction was performed on four (one combined with a fundoplication). Reoperations had been necessary in four

patients due to failure of the primary fundoplication. Fifteen patients (28%) underwent cholecystectomy, whereas in Finland during 1987-2006, 10% of all the patients with antireflux surgery underwent cholecystectomy.

The state of the fundoplication was assessed by endoscopic findings, and anatomic failure was established with disruption, significant loosening or distal displacement of the fundoplication wrap. The assessment of antireflux function in all the patients was based on the combination of reflux indicators, and functional failure was established if the patient had disrupted anatomy, pathologic pH-monitoring, low LES-pressure at manometry, endoscopic esophagitis or regurgitation. Thirteen (26%) patients had anatomic failure, and they developed EAC later (mean 12.0 years) after antireflux surgery than did those 23 (46%) with an anatomically intact fundoplication (mean 7.0 years), $p=0.0069$ (Figure 10 a). Those 22 (44%) with a functional failure of the antireflux surgery also developed EAC later (mean 11.2 years) postoperatively than did those 15 (30%) with a functional anti-reflux barrier (mean 6.4 years), $p=0.015$ (Figure 10 b). Hiatal hernia or widening of the hiatus closure was detected in 22 (44%) patients. Mean time interval to EAC diagnosis in those patients with partial gastrectomy and Roux-en-Y reconstruction was 13.5 years (range 8-25 years). Of the patients, 40% used PPIs or H2RAs at least occasionally postoperatively, and medication use was associated with neither anatomic nor functional failure of the fundoplication.



(a)



(b)

Figure 10 EAC cases diagnosed in Finland annually vs. the time interval from fundoplication to EAC, grouped according to the anatomic condition (a) and functionality (b). Figure 10 b is reproduced and modified from Kauttu TM, Rantanen TK, Sihvo EI, Räsänen JV, Puolakkainen P, Salo JA. Esophageal adenocarcinoma arising after antireflux surgery: a population-based analysis. *Eur J Cardiothorac Surg.* 40(6):1450-4, 2011, by permission of Oxford University Press.

6 Discussion

The decelerating increase in EAC incidence [141] suggests that either the prevalence of EAC risk factors is stabilizing, or their treatment or prevention has been successful. Evidence of GERD treatment and BE ablation in EAC prevention is controversial [34, 35, 38-40, 206, 210]. Recently, surveillance of BE has resulted in a better prognosis [14, 15]. Indirect evidence of stabilized incidence and incidence-based mortality from local EAC also points towards the effectiveness of surveillance and treatment improvements [141]. Along with GERD, other important risk factors also contribute to EAC development, ones such as obesity and smoking. Overall prevalence of smoking has been declining [283], whereas overall body-mass index has been increasing [284]. Generally, people live longer, and the proportion of aged people increases, leading to increased EAC risk at population level. An accurate evaluation of GERD incidence trends is difficult, due to obscurity in the disease classification, but GERD incidence has increased, for example, over six-fold in the USA during 1975–2009 [141]. Whereas a wealth of evidence connects GERD to EAC, an important contradictory argument is that treatment of GERD does not seem prevent, or even effectively reduce, EAC risk. This is an important and unanswered question, and the answer is at least as complicated as is the spectrum of GERD.

Our understanding of the pathophysiologic mechanisms causing GERD has during recent decades become greatly enhanced. At the same time, a considerable shift has occurred in treatment, with PPIs becoming the first-line treatment, due to their effective symptom control. However, the severity of GERD symptoms does not necessarily correlate with disease severity, as GERD symptoms are not often associated with endoscopic findings. Only 41% to 57% of patients with erosive reflux disease are symptomatic [12, 64]. To be able to answer the question of the role of effective GERD treatment in EAC prevention, both enhanced knowledge of the actual effects of GERD treatment on the pathophysiology of the disease and knowledge of the molecular events during development of BE and EAC are essential. Of great importance is also an understanding of the interplay between various risk factors, which to date is still an issue scarcely studied.

6.1 ADAMs in GERD and EAC

Development of EAC is a multifactorial process in which many risk factors probably act synergistically. ADAMs cleave many molecules associated in the signaling events of the tumor microenvironment [20]. Their action may also lead to decreased signaling capacity, as shown in pancreatic cancer cells [285]. Most studies report an increased expression of ADAMs in cancer. Likewise, in our study, no ADAM showed decreased expression in EAC in human samples. In this first study exploring ADAM expression also in GERD and BE, no clear progressive increase for any ADAM was apparent during the stages from esophagitis to EAC.

ADAM9 emerged as the most consistently increased molecule in EAC. In BE and dysplastic BE, ADAM9 was also increased at mRNA level. ADAM9 has been increasingly expressed, for instance, in EAC (at mRNA level) and in gastric cancer, esophageal squamous cell carcinoma, non-small cell lung cancer, and prostate cancer [21, 22, 264, 269, 286]. Data mostly from cell lines indicate that ADAM9 promotes invasion and metastasis [287, 288]. Moreover, a gastric cancer cell-line study suggests a role for ADAM9 in gastric cancer progression and invasion, with hypoxia inducing its expression [289]. Data from human samples in non-small cell lung cancer, bladder cancer, and pancreatic ductal adenocarcinoma indicate that ADAM9 expression may be a prognostic marker associated with poorer prognosis [269, 290, 291]. Oxidative stress is implicated in the pathogenesis of GERD and EAC [251, 252], and ADAM9 may be a mediator of the invasiveness promoted by oxidative stress [265]. Recent studies show that ADAM9 may mediate the effects of microRNA 126 on cancer cell proliferation, migration, and invasion [286, 291]. Further studies of the role of ADAM9 in different stages of EAC development, and of its possible association with EAC stage and prognosis, are essential.

Some ADAMs were increased in EAC only at mRNA level (ADAM12, ADAM17, ADAM19), which may be explained either by the lack of power due to the small number of patients in our IHC analysis or by the inability of our detection methods to capture these proteins. The opposite was observed for ADAM10, which was overexpressed only at protein level. All these molecules were previously found increased in EAC at mRNA level, with ADAM12 expression correlating with tumor grade [22]. Recently, ADAM10 has been implicated in the mechanism for acquired resistance to the human epidermal growth factor receptor 2-antibody trastuzumab in EAC cell lines (OE19 and OE33) [292]. ADAM17 protein, detected by both western blotting and IHC, is increased in esophageal squamous cell carcinoma and also correlates with prognostic variables [293]. The participation of ADAMs in inflammation was manifested in our study, as ADAMs 12 and 19 showed mRNA alterations in both esophagitis and EAC and may affect EAC development through inflammatory pathways. In severe macroscopic esophagitis, their expression was even more pronounced. ADAM19 is increased also in two other inflammatory conditions of the digestive tract: ulcerative colitis and Crohn's disease [294]. ADAM12, on the other hand, is increased in the synovium of patients with osteoarthritis [295]. All these ADAMs showed increased expression in EAC, and this finding and its possible importance needs confirmation in further studies, with a greater number of protein samples. The role of ADAM12 and ADAM19 in inflammation-driven carcinogenesis seems especially interesting.

Our patient groups included relatively few samples, leading to possible bias. Patients were also older and had a male predominance in contrast to the gender ratio of controls. The effect of age and other risk factors for EAC, such as obesity and smoking, on ADAM expression were not recorded, and therefore cannot be excluded. Disparities between the ADAM mRNA and protein expression, however, may also be due to post-transcriptional modulation of ADAMs. An example of this is the regulation of ADAM9 expression by microRNA 126 [286, 291]. ADAM10 and ADAM19 are also targets of microRNA regulation in cancer invasion and metastasis [296, 297]. At post-translational level, ADAMs are regulated by differing localization, processing, and kinase/phosphatase

activity [20], underlining the importance of analyzing ADAM expression at both mRNA and protein levels. The possible roles of regulatory molecules such as ADAMS also need study in functional assays.

6.2 CIP2A in EAC

Along with ectodomain cleavage by proteases to activate signaling pathways, phosphorylation is a key regulatory element in cellular signaling. CIP2A, the inhibitor of protein phosphatase 2A, is an oncogene increased in many human cancers. In our study, it was abundantly expressed also in EAC, together with c-MYC. Their expression in the squamous mucosa was mild, while in BE and associated dysplasia, it was more pronounced. Few patients had BE or BE with dysplasia, and they were the patients who also had cancer. CIP2A expression in BE patients not progressing to cancer thus remains unknown. Because of the small number of BE patients with cancer, however, nor can any firm conclusions on their CIP2A expression be drawn. To assess this, a larger study comparing CIP2A expression between those BE patients who progress to EAC and those who do not would be needed. Squamous control tissue came also from the EAC patients, but tissue samples were very few, only 5, possibly leading to bias. CIP2A expression was mild in all the control samples. Previously, CIP2A expression has been found in only 20% of squamous tissue adjacent to esophageal squamous cell carcinoma, however [27].

CIP2A expression was not associated with EAC prognosis. We had, however, a relatively small number of patients in each subgroup. Overall CIP2A-immunopositivity was high at 97.3%. A weakness of this study is its possible selection bias due to more than half of the originally screened patients dropping out due to insufficient tissue material; this may have also affected results. Another weakness is the study's retrospective nature. CIP2A expression was not associated with stage, and stage was a strong prognostic factor. Patients with the most advanced disease (stages IVA-B) showed a trend towards even poorer prognosis based on positive CIP2A expression ($p = 0.074$).

Many downstream targets of CIP2A are involved in carcinogenesis [278, 298], some of them with possible importance in EAC, like the survival- and growth-promoting protein kinase B (AKT) pathway (in activation of NF- κ B) [299] and transcription factor E2F1, participating in both cellular progression and apoptosis, whose expression is associated with a positive effect on EAC survival [300]. Thus, the downstream effects of increased CIP2A expression in BE and EAC remain to be elucidated. The association of CIP2A expression with p53 [28, 279], one of the most promising predictors of neoplastic progression in BE [23], makes them candidates for further study together in BE. Our finding of frequent c-MYC expression in EAC is in line with previous findings (73-90%), whereas its overexpression has been reported to be less frequent in BE (37-50%) [274, 275], possibly reflecting the fact that our BE patients were those who developed EAC. The effect of c-MYC on EAC prognosis has been unknown, although its amplification has been detected in one patient progressing to high-grade dysplasia after photodynamic therapy [301].

6.3 Surgical treatment of GERD in preventing EAC – why does it fail?

Abnormal reflux in GERD results from altered anatomic and physiologic properties of the esophagus and the proximal stomach [11]. Although the level of gastric acid secretion in GERD is mainly normal, and in ERD bile reflux plays a synergistic role with acid [73], PPIs offer good symptom control and heal esophagitis quite effectively. The significance of PPI effects, besides their acid suppression, is thus far unknown. Often inadequate PPI use and the consumption of PPIs by many patients after fundoplication—although often without objective evidence of recurrent reflux—may present confounding factors in studies exploring the GERD treatment efficacy. Patients with NERD who are on PPI therapy have higher symptom scores than do those with ERD [302]; GERD symptom severity seems to be a poor predictor of ongoing disease severity. Post-treatment symptoms may result from esophageal hypersensitivity, through the process of peripheral or central sensitization [55]. The link between EAC and GERD has mostly been established in studies based on GERD symptoms or in studies of BE patients, with the significance of erosive esophagitis less well studied. Possible interactions between risk factors, like between genetic alterations and GERD that combined may contribute to esophageal carcinogenesis [103], have thus far gone largely unstudied.

In theory, fundoplication may be a better treatment method for GERD than is antireflux medication, because surgery reconstructs the defective antireflux barrier and also prevents duodenogastroesophageal reflux. In ERD and BE, bile reflux increases [63]. Fundoplication reduces TLESRs, and their association with reflux also in long-term follow-up (> 5 years postoperatively) [162]. However, no significant effect on cancer prevention has been observable, not even reduced risk in comparison to that with medical treatment [38-40]. No prospective randomized controlled trials have assessed the cancer risk after antireflux surgery; there is only one follow-up of a randomized controlled trial with insufficient power for analysis of EAC risk [38], and most of the studies have been retrospective cohort studies. In any one retrospective trial, important factors such as history of GERD, adequacy of medication use, other confounding risk factors (smoking, obesity, diet), and status of the fundoplication cannot be reliably determined. This was also a difficulty in our study, with incomplete information on factors related to GERD such as operative indications and inability to control for other risk factors. On the other hand, smaller case-control studies cannot be generalized to population level. Indications, operations, and results of antireflux surgery are variable, but it seems clear that at population level, antireflux surgery does not protect from EAC, a finding also supported by our study. According to one meta-analysis, antireflux surgery does not seem efficient for EAC prevention even in BE patients [189].

The failure of fundoplication seems important in the progression of BE postoperatively [173, 190, 191], and this was corroborated by our study with a significant number of functionally failed fundoplications. EAC also appeared earlier after antireflux surgery in patients with an intact antireflux barrier than in those with a defective one. The failure rate was high in our study: an anatomic failure was detectable in 26% and a functional failure in 44%. Although this might reflect ineffective reflux inhibition as a risk

factor for EAC development, it may also reflect an overall high failure rate of fundoplication at population level at the time of our study. The difficulty in identifying those patients with true postoperative reflux is the negative association of objective recurrent reflux with symptoms and postoperative medication use; neither of these seems to predict failure, as detected by pH study [175, 176]. However, some studies suggest that, after antireflux surgery, symptoms requiring treatment or antireflux medication are risk factors for malignant progression [193, 194]. At population level, in order to reliably detect all the patients with ongoing abnormal reflux, virtually all patients, regardless of their symptoms, would have to be examined.

Our study also suggests that BE (both preoperatively and in total) and erosive esophagitis might be risk factors for post-fundoplication EAC. Despite our lack of a control group, which is a clear limitation of our study, the prevalence of preoperative endoscopic erosive esophagitis (77%) was more frequent than described in GERD (39%) [63]. Erosive esophagitis has raised EAC risk 2- to 5-fold, but this risk may be mostly attributable to BE [303, 304]. Of the patients with erosive esophagitis, 9% have developed BE in a 5-year follow-up [305]. In our study, total BE prevalence (79%), diagnosed at any time in the course of GERD, was more than earlier studies have detected at the time of EAC (30-62%) [87, 306]. At EAC diagnosis, the tumor may have overgrown the segment of IM from which it originated. BE is known to be heterogenic, and dysplasia often patchy. Therefore, a biopsy sampling error may account for some of the EAC cases occurring early after antireflux surgery. There might also exist an irreversible threshold for malignant transformation even in microscopically normal-appearing BE. Indeed, based on preliminary communication regarding *in vitro* cell-line data, the progression of BE cells, induced by acid and bile, occurred in stages, whereby after passing a certain limit, progression occurred although exposure to acid and to bile ceased [245]. At least in cases of EAC appearing a few years after antireflux surgery, carcinogenesis is likely to have already begun. BE may also harbor inherent procarcinogenetic factors, such as a low level of apoptosis [307]. After fundoplication, proliferative activity of the esophageal mucosa remains increased [308]. Oxidative stress of the distal esophagus is only partially reversed after antireflux surgery, and the proximal esophageal mucosa shows a persistently defective antioxidant capacity [257, 309].

At present, no method allows determination of the phase in which treatment of GERD could halt development of EAC. Possibly, for certain individuals, fundoplication performed at a very early phase of GERD—which is normally not when antireflux surgery is performed—and remaining intact at long-term follow-up, might protect against EAC. Since many people with severe GERD and longstanding symptoms or mucosal changes do not progress to EAC, and given the propensity of funduplications to be slowly disrupted in the long term, the possible protective effect of fundoplication would be at best very low. Even with an intact fundoplication, other risk factors for EAC may drive carcinogenesis. Very long follow-up times of 20, rather than 10 years, are needed to detect the true occurrence of EAC after antireflux surgery, as supported by our study results. At population level, the 9-fold increased EAC risk after antireflux surgery during long follow-up clearly shows that this surgery is not protective against EAC.

For the obese, laparoscopic gastric bypass with Roux-en-Y reconstruction has been recommended, based on its combined effects on acid reduction and weight control. Large-scale studies would be necessary to find whether this operation has a cancer-preventive effect in the obese. Our small patient numbers having partial gastrectomy with Roux-en-reconstruction, together with incomplete information on weight data for the majority of patients, allowed no reliable comparisons. Theoretically, the bile diversion in the Roux-en-Y procedure might improve the inhibition of bile reflux produced by fundoplication. After partial gastrectomy and Roux-en-Y reconstruction (combined with vagotomy and either fundoplication or Hill's gastropexy), or after gastric bypass with Roux-en-Y reconstruction, regression of BE to the cardiac mucosa has been documented, with no progression to HGD or EAC detectable [167, 168].

Cholecystectomy has been suggested to promote gastroesophageal reflux, especially duodenogastroesophageal reflux. Cholecystectomy was indeed nearly three times as frequent in our study patients (28%) as in the general Finnish population (10%). More-recent studies claim, however, that, after cholecystectomy, GERD symptoms decrease rather than increase, and that manometry and impedance-pH-monitoring show no increase in gastroesophageal reflux or in LES pressure [310, 311].

6.4 Endoscopic eradication of BE

For patients with BE, its eradication combined with anti-reflux treatment is another method aiming at EAC prevention. BE eradication is indicated for patients with HGD or early cancer, but not in BE without dysplasia. It is currently recommended also for patients with LGD persisting after PPI therapy [124]. Despite negative margins with endoscopic resection, and subsequent ablation of BE, intestinal metaplasia and dysplasia tend to reappear, and EAC may develop. The long-term effects of endoscopic therapy remain somewhat controversial, with many studies suggesting good outcomes in terms of the eradication of both IM and dysplasia or neoplasia [30, 31, 210], and others suggesting that HGD recurs in 14%, IMC in 11%, and IM in nearly 70% of cases at 5 years [206]. If eradication results are improving with growing experience and combined EMR, as suggested [207], eradication of BE might again become a treatment option for high-risk, non-dysplastic BE patients in the future, given its reasonably mild adverse effects. Eradication may not be needed if BE surveillance proves effective, however. Evidence of favorable results in surveillance: enhanced survival and discovery of early-stage cancers, is now accumulating [15].

Milder pretreatment histology in ablation may lead to a smaller recurrence rate for IM, but results thus far are contradictory. BE progression status was associated with rate of IM recurrence in a large US registry study on RFA ablation, with older age, longer BE, and non-Caucasian race representing independent risk factors for recurrence—although the model did not include risk factors such as obesity and smoking [212]. In contrast, pretreatment histology did not affect a recurrence rate of 33% at two years in a US cohort study. [205]. A possible difference in recurrence rate between BE with or without neoplasia may be explainable by other existing risk factors such as obesity, reduced

female hormones, genetic factors, and already induced pro-carcinogenetic changes. Our recurrence rate of 20% for macroscopic BE and 33% for intestinal metaplasia at eight years is higher than that reported in most other studies, but with shorter follow-up times [30, 31, 210]. Of our 8 patients with IM found at follow-up, three had a disrupted fundoplication, and in two of these, eradication had initially failed. The patient with partial gastrectomy and Roux-en-Y reconstruction also had an initially failed BE eradication. Our study had a small number of patients, and other risk factors of BE progression could not be accounted for.

The origin of EAC after ablation–residual or reappearing IM or buried glands under the neosquamous mucosa–is unclear. The role of residual or reappearing IM at the SCJ is also unclear. Studies show a considerable frequency of intestinal metaplasia with or without dysplasia at the SCJ after ablation (24-47%) [31, 205]. Development of dysplasia or EAC in that IM region clearly suggests malignant potential. Findings of residual BE or IM as risk factors for subsequent dysplasia or neoplasia are controversial [206, 213]. In our study, Cdx2 expression in the squamous mucosa was present in only one patient (with residual IM), although Cdx2 supposedly plays a role in inducing BE [41].

Oxidative stress is involved in carcinogenesis and inflammation and is also increased in Barrett's esophagus [252, 254]. In our study, oxidative DNA damage, measured as 8-OHdG level, was increased both in the distal neosquamous and proximal squamous mucosa. Earlier, 8-OHdG levels have been found to be increased both in the BE and in the proximal esophagus of those patients [251], suggesting some already acquired or inherent characteristic in BE patients. In GERD patients, even after successful antireflux surgery, antioxidative capacity in the proximal esophagus, studied as GSH content and SOD activity, seems reduced [309]. In contrast to 8-OHdG, levels of MP and GSH were unchanged in our study, contrary to earlier findings of their altered expression in GERD [252, 254, 256]. SOD activity was increased in our patients' neosquamous mucosa. It has been increased in dysplastic BE [252] and increased or unchanged in BE [252, 254], but also, conversely, decreased in esophagitis and in BE, with SOD expression decreased in dysplastic BE and EAC [255, 256]. In a rat model, exogenous SOD has been protective of BE and EAC [312]. Interestingly, PPI treatment may raise the SOD level reduced in BE [313]. The increased SOD level in the neosquamous mucosa possibly may serve as a protective factor. Thus, evidence exists of both ongoing oxidative stress and of normalized parameters after ablation. A possible confounder in our analyses was the more proximal location of the distal and proximal esophageal control samples as compared to patient samples, because the esophageal acid exposure becomes greater more distally. MP and GSH levels were, however, normal even more distally than in controls.

We have shown that the ablation of BE leads to at least partially normalized oxidative stress in the neosquamous mucosa in a long follow-up. No characteristics suggesting malignant development emerged. Laser ablation is no longer used, but future studies with RFA are likely to clarify its potential benefit in treating benign BE. To further enhance the efficacy of BE surveillance and of patient selection for different treatment methods, a need clearly exists for molecular studies in addition to known clinical risk factors in finding predictive markers to identify patients at greatest risk for BE

progression. In these studies, the effect of EAC risk factors such as obesity, smoking, and male sex should also be taken into account by means of multivariate analysis.

7 Summary

EAC remains a lethal malignancy despite advances in its diagnosis and treatment. Among its risk factors, GERD, obesity, and smoking remain prevalent, and the population is growing older. Treatment of GERD or BE has not led to a decrease in EAC incidence. Few patients with GERD or BE exhibit malignant progression, which is likely to result from the interplay of various genetic and environmental factors and may be driven independent of already cured pathologic reflux. It is evident that treatment of GERD alone cannot halt the progression to EAC.

Despite extensive research, the molecular pathogenesis of the Barrett's metaplasia–dysplasia–EAC sequence has not been shown to feature any distinct pathway. Many molecular and genetic alterations show associations with EAC in individual studies. Yet it seems that it is rather a set of those alterations that predicts risk for EAC. We studied molecules being of possible importance for EAC development. Of these, ADAM9 emerged as the most consistently increased molecule in EAC, with increased mRNA expression appearing already in BE with or without dysplasia. ADAMs possess various signaling capabilities, and their altered expression in GERD, BE, and EAC suggests that larger-scale studies and functional assays are needed to elucidate their role in EAC development. Other molecules that we studied, the oncogenes CIP2A and c-MYC, although abundantly expressed in EAC, had no impact on EAC prognosis. The role of CIP2A in BE and in the progression of BE remains for further study.

Efforts to eliminate the cancer risk of BE by ablation have proven ineffective. With the techniques developed, and with the addition of endoscopic resection, results have improved, and EAC risk may be diminishing. IM tends to recur even with effective reflux inhibition, however, in a significant number of patients—33% in our study at long-term follow-up after BE laser ablation combined with antireflux surgery, but with no evidence of malignant development. Oxidative stress, an important factor in the derangement of tissue homeostasis predisposing for cancer, was in part normal and in part elevated. The elevated levels of 8-OHdG suggest some kind of similarity in tissue homeostasis between neosquamous mucosa and BE.

Antireflux surgery can effectively control GERD symptoms. A considerable number of funduplications tend to fail during long-term follow-up, however. In our detailed analysis of EAC cases after antireflux surgery, EAC occurred a long time after even successful antireflux surgery. With a well-working antireflux barrier, however, EAC occurred earlier postoperatively than with a failure. As our patient numbers were small, the role of chance or other risk factors can be neither evaluated nor excluded. The total proportion of BE diagnosed (79%) and the prevalence of endoscopic esophagitis preoperatively (77%) were high. Even though reflux inhibition may play a role in preventing GERD-associated malignancy, it cannot protect from other EAC risk factors or possibly lead to a halt in already initiated pro-carcinogenic pathways. Antireflux surgery should not be recommended as protective against EAC, since EAC risk remained elevated 9-fold.

8 Conclusions

1. The expression of members of the ADAM-molecule family was altered in esophagitis, in BE, in BE with dysplasia, and in EAC, although no clear progressive trend in ADAM expression appeared along this sequence. ADAM9 was most constantly overexpressed, and further studies on its possible role are necessary.
2. The oncogene CIP2A, along with c-MYC, was frequently expressed in EAC. Neither the expression of CIP2A nor that of c-MYC correlated with survival, however.
3. BE occurred in about one-third of the patients at the 8-year follow-up after BE laser ablation combined with antireflux surgery. IM occurred in 44% of the patients. No signs of malignant progression appeared, however. Oxidative DNA damage was elevated both in the distal and proximal esophagus.
4. EAC risk was approximately 9 times as high after antireflux surgery as in the general population. Endoscopic esophagitis prior to antireflux surgery, BE, and the failure of antireflux surgery were frequent findings. Antireflux surgery cannot be considered protective against EAC.

Acknowledgements

This study was carried out at the Department of General Thoracic and Esophageal Surgery, Heart and Lung Center and at the Department of Gastrointestinal Surgery, Abdominal Center, in Helsinki University Hospital. I wish to express my earnest gratitude to a number of people who have enabled this work:

To Acting Professor Karl Lemström, for providing me the opportunity for this thesis.

To my supervisor, Professor h.c. Jarmo A. Salo, for his always meticulous and trusting guidance. His extensive knowledge, dedication to research, and enthusiasm for science have been a splendid example. He always had time to instruct and advise me, and this devotion is greatly appreciated.

To my supervisor, Professor Pauli Puolakkainen, for his always inspiring and supportive guidance. He gave me the chance to participate in the design of the study, in the choice of molecules to be studied; this was an extraordinary opportunity for one of my status at that time. His instructions and trust have been splendid.

To Docents Juha Saarnio and Pauliina Salminen for their very constructive critical comments and instructions that have greatly enhanced the content of this thesis.

To Docent Harri Mustonen, for his great expertise in design and analysis of laboratory work and in statistics. His help has been enormous. He was always ready to provide assistance for which I am most grateful.

To Docent Jari Räsänen, for his guidance and teaching in design and implementation of research and in clinical matters, and for his readiness to help. His dedication of time and effort in providing me with study material is enormously appreciated.

To Docent Eero Sihvo, for his expert advice, help, and guidance during the research. I am most grateful for his devoting his time in instructing me and for providing me with study material.

To Acting Professor Tuomo Rantanen, for his great and swift cooperation. He has been a great example in research implementation, and most kindly helped me with any any types of questions in this thesis project.

To Docent Leena Krogerus, because her great expertise in the field of esophago-gastric pathology has been essential. She always found time for this research and took care to teach me well.

To Sanna Vainionpää, BS, for her great work and expertise in the laboratory, and for her always kind help.

To Ilkka Ilonen, MD, PhD, for his continuous assistance and encouragement.

To Professor Timo Paavonen for his guidance and cooperation.

To Assistant Professor Niku Oksala, and to Jonne Åkerla and Teemu Honkanen for their efficient cooperation.

To Professor Eero Pukkala, for his indispensable assistance in providing data analysis.

To Docent Markku Ahotupa, for his expertise and cooperation in providing laboratory analyses.

To Docent Perttu Arkkila for his cooperation, and to the doctors specializing in gastroenterology at Helsinki University Hospital for providing me with study material.

To Juha Kauppi, MD, PhD, for his assistance in providing study material and for his cooperation.

To Tarja Peräkylä, MD, PhD, for her assistance in providing study material.

To Docent Markku Luostarinen and Henna Söderström, MD, for providing illustrative material for this thesis.

To Yvonne Sundström, for her always skillful work and kindest assistance.

To Merja Räsänen, for her assistance in collecting study material.

To Arja Vermasvuori, for her accurate help on secretarial matters.

To Carolyn Norris, PhD, from Language Services, University of Helsinki, for her aid in the language editing.

To my parents, Päivikki and Teemu, for giving me a solid upbringing and teaching me to appreciate hard work. Thank you for your constant support. Also thanks to my brothers, Pyry and Topi, whose intelligence and abilities have challenged me so many times, and who have been great company all these years.

To Janne, for his great support and understanding. Your companionship has, among all other things, made this work so much easier.

To my great friends for bringing me so much joy!

This study was financially supported by the Helsinki University Hospital Research Funds, the Pirkanmaa Cultural Foundation, the Sigrid Jusélius Foundation, research funding of Tampere University Hospital and Seinäjoki Central Hospital, and the legacy fund of E. K. Savolainen. Many thanks to them for enabling this work.

References

1. Pennathur A, Gibson MK, Jobe BA, Luketich JD. Oesophageal carcinoma. *Lancet*. 381: 400-412, 2013.
2. Rustgi AK, El-Serag HB. Esophageal carcinoma. *N Engl J Med*. 371: 2499-2509, 2014.
3. Morson BC, Belcher JR. Adenocarcinoma of the oesophagus and ectopic gastric mucosa. *Br J Cancer*. 6: 127-130, 1952.
4. Dodge OG. Intraoesophageal adenocarcinoma. *Gut*. 1: 351-356, 1960.
5. Barrett NR. The oesophagus lined by columnar epithelium. *Gastroenterologia*. 86: 183-186, 1956.
6. Barrett NR. The lower esophagus lined by columnar epithelium. *Surgery*. 41: 881-894, 1957.
7. Raphael HA, Ellis FH, Jr., Dockerty MB. Primary adenocarcinoma of the esophagus: 18-year review and review of literature. *Ann Surg*. 164: 785-796, 1966.
8. Rubenstein JH, Shaheen NJ. Epidemiology, Diagnosis, and Management of Esophageal Adenocarcinoma. *Gastroenterology*. 149: 302-317, 2015.
9. Kapoor H, Agrawal DK, Mittal SK. Barrett's esophagus: recent insights into pathogenesis and cellular ontogeny. *Transl Res*. 166: 28-40, 2015.
10. Spechler SJ, Souza RF. Barrett's esophagus. *N Engl J Med*. 371: 836-845, 2014.
11. Boeckxstaens G, El-Serag HB, Smout AJ, Kahrilas PJ. Symptomatic reflux disease: the present, the past and the future. *Gut*. 63: 1185-1193, 2014.
12. Lee D, Lee KJ, Kim KM, Lim SK. Prevalence of asymptomatic erosive esophagitis and factors associated with symptom presentation of erosive esophagitis. *Scand J Gastroenterol*. 48: 906-912, 2013.
13. Balasubramanian G, Singh M, Gupta N, Gaddam S, Giacchino M, Wani SB, Moloney B, Higbee AD, Rastogi A, Bansal A, Sharma P. Prevalence and predictors of columnar lined esophagus in gastroesophageal reflux disease (GERD) patients undergoing upper endoscopy. *Am J Gastroenterol*. 107: 1655-1661, 2012.
14. Bhat SK, McManus DT, Coleman HG, Johnston BT, Cardwell CR, McMenamin U, Bannon F, Hicks B, Kennedy G, Gavin AT, Murray LJ. Oesophageal adenocarcinoma and prior diagnosis of Barrett's oesophagus: a population-based study. *Gut*. 64: 20-25, 2015.
15. Kastelein F, van Olphen SH, Steyerberg EW, Spaander MC, Bruno MJ, ProBar-study g. Impact of surveillance for Barrett's oesophagus on tumour stage and survival of patients with neoplastic progression. *Gut*. 65: 548-554, 2016.
16. Kastelein F, van Olphen S, Steyerberg EW, Sikkema M, Spaander MC, Looman CW, Kuipers EJ, Siersema PD, Bruno MJ, de Bekker-Grob EW, ProBar-study g. Surveillance in patients with long-segment Barrett's oesophagus: a cost-effectiveness analysis. *Gut*. 64: 864-871, 2015.
17. Bennett M, Mashimo H. Molecular markers and imaging tools to identify malignant potential in Barrett's esophagus. *World J Gastrointest Pathophysiol*. 5: 438-449, 2014.
18. Fouad YM, Mostafa I, Yehia R, El-Khayat H. Biomarkers of Barrett's esophagus. *World J Gastrointest Pathophysiol*. 5: 450-456, 2014.
19. Garton KJ, Gough PJ, Raines EW. Emerging roles for ectodomain shedding in the regulation of inflammatory responses. *J Leukoc Biol*. 79: 1105-1116, 2006.
20. Murphy G. The ADAMs: signalling scissors in the tumour microenvironment. *Nat Rev Cancer*. 8: 929-941, 2008.

21. Carl-McGrath S, Lendeckel U, Ebert M, Roessner A, Rocken C. The disintegrin-metalloproteinases ADAM9, ADAM12, and ADAM15 are upregulated in gastric cancer. *Int J Oncol.* 26: 17-24, 2005.
22. Baren JP, Stewart GD, Stokes A, Gray K, Pennington CJ, O'Neill R, Deans DA, Paterson-Brown S, Riddick AC, Edwards DR, Fearon KC, Ross JA, Skipworth RJ. mRNA profiling of the cancer degradome in oesophago-gastric adenocarcinoma. *Br J Cancer.* 107: 143-149, 2012.
23. Kastelein F, Biermann K, Steyerberg EW, Verheij J, Kalisvaart M, Looijenga LH, Stoop HA, Walter L, Kuipers EJ, Spaander MC, Bruno MJ, ProBar-study g. Aberrant p53 protein expression is associated with an increased risk of neoplastic progression in patients with Barrett's oesophagus. *Gut.* 62: 1676-1683, 2013.
24. Junttila MR, Puustinen P, Niemela M, Ahola R, Arnold H, Bottzauw T, Ala-aho R, Nielsen C, Ivaska J, Taya Y, Lu SL, Lin S, Chan EK, Wang XJ, Grenman R, Kast J, Kallunki T, Sears R, Kahari VM, Westermarck J. CIP2A inhibits PP2A in human malignancies. *Cell.* 130: 51-62, 2007.
25. Khanna A, Pimanda JE. Clinical significance of Cancerous Inhibitor of Protein Phosphatase 2A (CIP2A) in human cancers. *Int J Cancer.* 138: 525-532, 2016.
26. Li W, Ge Z, Liu C, Liu Z, Bjorkholm M, Jia J, Xu D. CIP2A is overexpressed in gastric cancer and its depletion leads to impaired clonogenicity, senescence, or differentiation of tumor cells. *Clin Cancer Res.* 14: 3722-3728, 2008.
27. Qu W, Li W, Wei L, Xing L, Wang X, Yu J. CIP2A is overexpressed in esophageal squamous cell carcinoma. *Med Oncol.* 29: 113-118, 2012.
28. Bockelman C, Koskensalo S, Hagstrom J, Lundin M, Ristimaki A, Haglund C. CIP2A overexpression is associated with c-Myc expression in colorectal cancer. *Cancer Biol Ther.* 13: 289-295, 2012.
29. Salo JA, Salminen JT, Kiviluoto TA, Nemlander AT, Ramo OJ, Farkkila MA, Kivilaakso EO, Mattila SP. Treatment of Barrett's esophagus by endoscopic laser ablation and antireflux surgery. *Ann Surg.* 227: 40-44, 1998.
30. Cotton CC, Wolf WA, Pasricha S, Li N, Madanick RD, Spacek MB, Ferrell K, Dellon ES, Shaheen NJ. Recurrent intestinal metaplasia after radiofrequency ablation for Barrett's esophagus: endoscopic findings and anatomic location. *Gastrointest Endosc.* 81: 1362-1369, 2015.
31. Phoa KN, Pouw RE, Bisschops R, Pech O, Rangunath K, Weusten BL, Schumacher B, Rembacken B, Meining A, Messmann H, Schoon EJ, Gossner L, Mannath J, Seldenrijk CA, Visser M, Lerut T, Seewald S, Ten Kate FJ, Ell C, Neuhaus H, Bergman JJ. Multimodality endoscopic eradication for neoplastic Barrett esophagus: results of an European multicentre study (EURO-II). *Gut.* 65: 555-562, 2016.
32. Phoa KN, van Vilsteren FG, Weusten BL, Bisschops R, Schoon EJ, Rangunath K, Fullarton G, Di Pietro M, Ravi N, Visser M, Offerhaus GJ, Seldenrijk CA, Meijer SL, ten Kate FJ, Tijssen JG, Bergman JJ. Radiofrequency ablation vs endoscopic surveillance for patients with Barrett esophagus and low-grade dysplasia: a randomized clinical trial. *JAMA.* 311: 1209-1217, 2014.
33. Broeders JA, Draaisma WA, Bredenoord AJ, Smout AJ, Broeders IA, Gooszen HG. Long-term outcome of Nissen fundoplication in non-erosive and erosive gastro-oesophageal reflux disease. *Br J Surg.* 97: 845-852, 2010.
34. Hvid-Jensen F, Pedersen L, Funch-Jensen P, Drewes AM. Proton pump inhibitor use may not prevent high-grade dysplasia and oesophageal adenocarcinoma in Barrett's oesophagus: a nationwide study of 9883 patients. *Aliment Pharmacol Ther.* 39: 984-991, 2014.
35. Singh S, Garg SK, Singh PP, Iyer PG, El-Serag HB. Acid-suppressive medications and risk of oesophageal adenocarcinoma in patients with Barrett's oesophagus: a systematic review and meta-analysis. *Gut.* 63: 1229-1237, 2014.

36. Gatenby PA, Ramus JR, Caygill CP, Charlett A, Winslet MC, Watson A. Treatment modality and risk of development of dysplasia and adenocarcinoma in columnar-lined esophagus. *Dis Esophagus*. 22: 133-142, 2009.
37. Hofstetter WL, Peters JH, DeMeester TR, Hagen JA, DeMeester SR, Crookes PF, Tsai P, Banki F, Bremner CG. Long-term outcome of antireflux surgery in patients with Barrett's esophagus. *Ann Surg*. 234: 532-538, 2001.
38. Spechler SJ, Lee E, Ahnen D, Goyal RK, Hirano I, Ramirez F, Raufman JP, Sampliner R, Schnell T, Sontag S, Vlahcevic ZR, Young R, Williford W. Long-term outcome of medical and surgical therapies for gastroesophageal reflux disease: follow-up of a randomized controlled trial. *JAMA*. 285: 2331-2338, 2001.
39. Tran T, Spechler SJ, Richardson P, El-Serag HB. Fundoplication and the risk of esophageal cancer in gastroesophageal reflux disease: a Veterans Affairs cohort study. *Am J Gastroenterol*. 100: 1002-1008, 2005.
40. Ye W, Chow WH, Lagergren J, Yin L, Nyren O. Risk of adenocarcinomas of the esophagus and gastric cardia in patients with gastroesophageal reflux diseases and after antireflux surgery. *Gastroenterology*. 121: 1286-1293, 2001.
41. Appelman HD, Streutker C, Vieth M, Neumann H, Neurath MF, Upton MP, Sagaert X, Wang HH, El-Zimaity H, Abraham SC, Bellizzi AM. The esophageal mucosa and submucosa: immunohistology in GERD and Barrett's esophagus. *Ann N Y Acad Sci*. 1300: 144-165, 2013.
42. Long JD, Orlando RC. Esophageal submucosal glands: structure and function. *Am J Gastroenterol*. 94: 2818-2824, 1999.
43. Hyun JJ, Bak YT. Clinical significance of hiatal hernia. *Gut Liver*. 5: 267-277, 2011.
44. Kumagai Y, Yagi M, Aida J, Ishida H, Suzuki S, Hashimoto T, Amanuma Y, Kusano M, Mukai S, Yamazaki S, Iida M, Ochiai T, Matsuura M, Iwakiri K, Kawano T, Hoshihara Y, Takubo K. Detailed features of palisade vessels as a marker of the esophageal mucosa revealed by magnifying endoscopy with narrow band imaging. *Dis Esophagus*. 25: 484-490, 2012.
45. Curcic J, Roy S, Schwizer A, Kaufman E, Forras-Kaufman Z, Menne D, Hebbard GS, Treier R, Boesiger P, Steingoetter A, Fried M, Schwizer W, Pal A, Fox M. Abnormal structure and function of the esophagogastric junction and proximal stomach in gastroesophageal reflux disease. *Am J Gastroenterol*. 109: 658-667, 2014.
46. Duffy MJ, Mullooly M, O'Donovan N, Sukor S, Crown J, Pierce A, McGowan PM. The ADAMs family of proteases: new biomarkers and therapeutic targets for cancer? *Clin Proteomics*. 8: 9, 2011.
47. Boeckxstaens GE. The lower oesophageal sphincter. *Neurogastroenterol Motil*. 17 Suppl 1: 13-21, 2005.
48. Roman S, Kahrilas PJ. Mechanisms of Barrett's oesophagus (clinical): LOS dysfunction, hiatal hernia, peristaltic defects. *Best Pract Res Clin Gastroenterol*. 29: 17-28, 2015.
49. Olefson S, Moss SF. Obesity and related risk factors in gastric cardia adenocarcinoma. *Gastric Cancer*. 18: 23-32, 2015.
50. Kilgore SP, Ormsby AH, Gramlich TL, Rice TW, Richter JE, Falk GW, Goldblum JR. The gastric cardia: fact or fiction? *Am J Gastroenterol*. 95: 921-924, 2000.
51. Glickman JN, Fox V, Antonioli DA, Wang HH, Odze RD. Morphology of the cardia and significance of carditis in pediatric patients. *Am J Surg Pathol*. 26: 1032-1039, 2002.
52. De Hertogh G, Van Eyken P, Ectors N, Tack J, Geboes K. On the existence and location of cardiac mucosa: an autopsy study in embryos, fetuses, and infants. *Gut*. 52: 791-796, 2003.

53. Langner C, Schneider NI, Plieschnegger W, Schmack B, Bordel H, Hofler B, Eherer AJ, Wolf EM, Rehak P, Vieth M. Cardiac mucosa at the gastro-oesophageal junction: indicator of gastro-oesophageal reflux disease? Data from a prospective central European multicentre study on histological and endoscopic diagnosis of oesophagitis (histoGERD trial). *Histopathology*. 65: 81-89, 2014.
54. Chandrasoma P, Wijetunge S, Demeester SR, Hagen J, Demeester TR. The histologic squamo-oxynitic gap: an accurate and reproducible diagnostic marker of gastroesophageal reflux disease. *Am J Surg Pathol*. 34: 1574-1581, 2010.
55. Herregods TV, Bredenoord AJ, Smout AJ. Pathophysiology of gastroesophageal reflux disease: new understanding in a new era. *Neurogastroenterol Motil*. 27: 1202-1213, 2015.
56. Hirschowitz BI. A critical analysis, with appropriate controls, of gastric acid and pepsin secretion in clinical esophagitis. *Gastroenterology*. 101: 1149-1158, 1991.
57. Roman S, Kahrilas PJ. The diagnosis and management of hiatus hernia. *BMJ*. 349: g6154, 2014.
58. Vakil N, van Zanten SV, Kahrilas P, Dent J, Jones R, Global Consensus G. The Montreal definition and classification of gastroesophageal reflux disease: a global evidence-based consensus. *Am J Gastroenterol*. 101: 1900-1920, 2006.
59. Rantanen TK, Sihvo EI, Rasanen JV, Salo JA. Gastroesophageal reflux disease as a cause of death is increasing: analysis of fatal cases after medical and surgical treatment. *Am J Gastroenterol*. 102: 246-253, 2007.
60. Nelson SP, Kothari S, Wu EQ, Beaulieu N, McHale JM, Dabbous OH. Pediatric gastroesophageal reflux disease and acid-related conditions: trends in incidence of diagnosis and acid suppression therapy. *J Med Econ*. 12: 348-355, 2009.
61. Rantanen T, Kiljander T, Salminen P, Ranta A, Oksala N, Kellokumpu I. Reflux symptoms and side effects among patients with gastroesophageal reflux disease at baseline, during treatment with PPIs, and after Nissen fundoplication. *World J Surg*. 37: 1291-1296, 2013.
62. Lacy BE, Weiser K, Chertoff J, Fass R, Pandolfino JE, Richter JE, Rothstein RI, Spangler C, Vaezi MF. The diagnosis of gastroesophageal reflux disease. *Am J Med*. 123: 583-592, 2010.
63. Koek GH, Sifrim D, Lerut T, Janssens J, Tack J. Multivariate analysis of the association of acid and duodeno-gastro-oesophageal reflux exposure with the presence of oesophagitis, the severity of oesophagitis and Barrett's oesophagus. *Gut*. 57: 1056-1064, 2008.
64. Lei WY, Yu HC, Wen SH, Liu TT, Yi CH, Wang CC, Hsu CS, Chen CH, Chen CL, Pace F. Predictive factors of silent reflux in subjects with erosive esophagitis. *Dig Liver Dis*. 47: 24-29, 2015.
65. Modlin IM, Hunt RH, Malfertheiner P, Moayyedi P, Quigley EM, Tytgat GN, Tack J, Heading RC, Holtman G, Moss SF, Vevey NCG. Diagnosis and management of non-erosive reflux disease--the Vevey NERD Consensus Group. *Digestion*. 80: 74-88, 2009.
66. Triantos C, Koukias N, Karamanolis G, Thomopoulos K. Changes in the esophageal mucosa of patients with non erosive reflux disease: How far have we gone? *World J Gastroenterol*. 21: 5762-5767, 2015.
67. Lundell LR, Dent J, Bennett JR, Blum AL, Armstrong D, Galmiche JP, Johnson F, Hongo M, Richter JE, Spechler SJ, Tytgat GN, Wallin L. Endoscopic assessment of oesophagitis: clinical and functional correlates and further validation of the Los Angeles classification. *Gut*. 45: 172-180, 1999.
68. Savarino E, Zentilin P, Mastracci L, Dulbecco P, Marabotto E, Gemignani L, Bruzzzone L, de Bortoli N, Frigo AC, Fiocca R, Savarino V. Microscopic esophagitis

- distinguishes patients with non-erosive reflux disease from those with functional heartburn. *J Gastroenterol.* 48: 473-482, 2013.
69. Bresadola V, Adani GL, Londero F, Leo CA, Cherchi V, Lorenzin D, Rossetto A, Vit G, Baccarani U, Terrosu G, Anna DD. Non-erosive and uncomplicated erosive reflux diseases: Difference in physiopathological and symptom pattern. *World J Gastrointest Pathophysiol.* 2: 42-48, 2011.
 70. Lord RV, DeMeester SR, Peters JH, Hagen JA, Elyssnia D, Sheth CT, DeMeester TR. Hiatal hernia, lower esophageal sphincter incompetence, and effectiveness of Nissen fundoplication in the spectrum of gastroesophageal reflux disease. *J Gastrointest Surg.* 13: 602-610, 2009.
 71. Savarino E, Tutuian R, Zentilin P, Dulbecco P, Pohl D, Marabotto E, Parodi A, Sammito G, Gemignani L, Bodini G, Savarino V. Characteristics of reflux episodes and symptom association in patients with erosive esophagitis and nonerosive reflux disease: study using combined impedance-pH off therapy. *Am J Gastroenterol.* 105: 1053-1061, 2010.
 72. Lee SW, Lee TY, Lien HC, Yang SS, Yeh HZ, Chang CS. Characteristics of symptom presentation and risk factors in patients with erosive esophagitis and nonerosive reflux disease. *Med Princ Pract.* 23: 460-464, 2014.
 73. Richter JE. Role of the gastric refluxate in gastroesophageal reflux disease: acid, weak acid and bile. *Am J Med Sci.* 338: 89-95, 2009.
 74. Martinucci I, de Bortoli N, Giacchino M, Bodini G, Marabotto E, Marchi S, Savarino V, Savarino E. Esophageal motility abnormalities in gastroesophageal reflux disease. *World J Gastrointest Pharmacol Ther.* 5: 86-96, 2014.
 75. Gawron AJ, Hirano I. Advances in diagnostic testing for gastroesophageal reflux disease. *World J Gastroenterol.* 16: 3750-3756, 2010.
 76. Spechler SJ, Sharma P, Souza RF, Inadomi JM, Shaheen NJ, American Gastroenterological A. American Gastroenterological Association technical review on the management of Barrett's esophagus. *Gastroenterology.* 140: e18-52, 2011.
 77. Chandrasoma P, Wijetunge S, DeMeester S, Ma Y, Hagen J, Zamis L, DeMeester T. Columnar-lined esophagus without intestinal metaplasia has no proven risk of adenocarcinoma. *Am J Surg Pathol.* 36: 1-7, 2012.
 78. Leodolter A, Nocon M, Vieth M, Lind T, Jaspersen D, Richter K, Willich S, Stolte M, Malfertheiner P, Labenz J. Progression of specialized intestinal metaplasia at the cardia to macroscopically evident Barrett's esophagus: an entity of concern in the ProGERD study. *Scand J Gastroenterol.* 47: 1429-1435, 2012.
 79. Sharma P, Dent J, Armstrong D, Bergman JJ, Gossner L, Hoshihara Y, Jankowski JA, Junghard O, Lundell L, Tytgat GN, Vieth M. The development and validation of an endoscopic grading system for Barrett's esophagus: the Prague C & M criteria. *Gastroenterology.* 131: 1392-1399, 2006.
 80. Ronkainen J, Aro P, Storskrubb T, Johansson SE, Lind T, Bolling-Sternevald E, Vieth M, Stolte M, Talley NJ, Agreus L. Prevalence of Barrett's esophagus in the general population: an endoscopic study. *Gastroenterology.* 129: 1825-1831, 2005.
 81. Yamamoto Y, Wang X, Bertrand D, Kern F, Zhang T, Duleba M, Srivastava S, Khor CC, Hu Y, Wilson LH, Blaszyk H, Rolshud D, Teh M, Liu J, Howitt BE, Vincent M, Crum CP, Nagarajan N, Ho KY, McKeon F, Xian W. Mutational spectrum of Barrett's stem cells suggests paths to initiation of a precancerous lesion. *Nat Commun.* 7: 10380, 2016.
 82. Anderson LA, Watson RG, Murphy SJ, Johnston BT, Comber H, Mc Guigan J, Reynolds JV, Murray LJ. Risk factors for Barrett's oesophagus and oesophageal adenocarcinoma: results from the FINBAR study. *World J Gastroenterol.* 13: 1585-1594, 2007.

83. Thrift AP, Kramer JR, Qureshi Z, Richardson PA, El-Serag HB. Age at onset of GERD symptoms predicts risk of Barrett's esophagus. *Am J Gastroenterol.* 108: 915-922, 2013.
84. Hak NG, Mostafa M, Salah T, El-Hemaly M, Haleem M, Abd El-Raouf A, Hamdy E. Acid and bile reflux in erosive reflux disease, non-erosive reflux disease and Barrett's esophagus. *Hepatogastroenterology.* 55: 442-447, 2008.
85. Sun D, Wang X, Gai Z, Song X, Jia X, Tian H. Bile acids but not acidic acids induce Barrett's esophagus. *Int J Clin Exp Pathol.* 8: 1384-1392, 2015.
86. Cook MB, Corley DA, Murray LJ, Liao LM, Kamangar F, Ye W, Gammon MD, Risch HA, Casson AG, Freedman ND, Chow WH, Wu AH, Bernstein L, Nyren O, Pandeya N, Whiteman DC, Vaughan TL. Gastroesophageal reflux in relation to adenocarcinomas of the esophagus: a pooled analysis from the Barrett's and Esophageal Adenocarcinoma Consortium (BEACON). *PLoS One.* 9: e103508, 2014.
87. Lagergren J, Bergstrom R, Lindgren A, Nyren O. Symptomatic gastroesophageal reflux as a risk factor for esophageal adenocarcinoma. *N Engl J Med.* 340: 825-831, 1999.
88. Bytzer P, Christensen PB, Damkier P, Vinding K, Seersholm N. Adenocarcinoma of the esophagus and Barrett's esophagus: a population-based study. *Am J Gastroenterol.* 94: 86-91, 1999.
89. Lada MJ, Nieman DR, Han M, Timratana P, Alsalahi O, Peyre CG, Jones CE, Watson TJ, Peters JH. Gastroesophageal reflux disease, proton-pump inhibitor use and Barrett's esophagus in esophageal adenocarcinoma: Trends revisited. *Surgery.* 154: 856-864, 2013.
90. Dulai GS, Guha S, Kahn KL, Gornbein J, Weinstein WM. Preoperative prevalence of Barrett's esophagus in esophageal adenocarcinoma: a systematic review. *Gastroenterology.* 122: 26-33, 2002.
91. Pohl H, Pech O, Arash H, Stolte M, Manner H, May A, Kraywinkel K, Sonnenberg A, Ell C. Length of Barrett's oesophagus and cancer risk: implications from a large sample of patients with early oesophageal adenocarcinoma. *Gut.* 65: 196-201, 2016.
92. Chandrasoma P, Wickramasinghe K, Ma Y, DeMeester T. Is intestinal metaplasia a necessary precursor lesion for adenocarcinomas of the distal esophagus, gastroesophageal junction and gastric cardia? *Dis Esophagus.* 20: 36-41, 2007.
93. Singh S, Sharma AN, Murad MH, Buttar NS, El-Serag HB, Katzka DA, Iyer PG. Central adiposity is associated with increased risk of esophageal inflammation, metaplasia, and adenocarcinoma: a systematic review and meta-analysis. *Clin Gastroenterol Hepatol.* 11: 1399-1412, 2013.
94. Whiteman DC, Sadeghi S, Pandeya N, Smithers BM, Gotley DC, Bain CJ, Webb PM, Green AC, Australian Cancer S. Combined effects of obesity, acid reflux and smoking on the risk of adenocarcinomas of the oesophagus. *Gut.* 57: 173-180, 2008.
95. Steffen A, Huerta JM, Weiderpass E, Bueno-de-Mesquita HB, May AM, Siersema PD, Kaaks R, Neamat-Allah J, Pala V, Panico S, Saieva C, Tumino R, Naccarati A, Dorronsoro M, Sanchez-Cantalejo E, Ardanaz E, Quiros JR, Ohlsson B, Johansson M, Wallner B, Overvad K, Halkjaer J, Tjonneland A, Fagherazzi G, Racine A, Clavel-Chapelon F, Key TJ, Khaw KT, Wareham N, Lagiou P, Bamia C, Trichopoulou A, Ferrari P, Freisling H, Lu Y, Riboli E, Cross AJ, Gonzalez CA, Boeing H. General and abdominal obesity and risk of esophageal and gastric adenocarcinoma in the European Prospective Investigation into Cancer and Nutrition. *Int J Cancer.* 137: 646-657, 2015.
96. O'Doherty MG, Freedman ND, Hollenbeck AR, Schatzkin A, Abnet CC. A prospective cohort study of obesity and risk of oesophageal and gastric adenocarcinoma in the NIH-AARP Diet and Health Study. *Gut.* 61: 1261-1268, 2012.
97. El-Serag H. Role of obesity in GORD-related disorders. *Gut.* 57: 281-284, 2008.

98. Duggan C, Onstad L, Hardikar S, Blount PL, Reid BJ, Vaughan TL. Association between markers of obesity and progression from Barrett's esophagus to esophageal adenocarcinoma. *Clin Gastroenterol Hepatol.* 11: 934-943, 2013.
99. Cook MB, Kamangar F, Whiteman DC, Freedman ND, Gammon MD, Bernstein L, Brown LM, Risch HA, Ye W, Sharp L, Pandeya N, Webb PM, Wu AH, Ward MH, Giffen C, Casson AG, Abnet CC, Murray LJ, Corley DA, Nyren O, Vaughan TL, Chow WH. Cigarette smoking and adenocarcinomas of the esophagus and esophagogastric junction: a pooled analysis from the international BEACON consortium. *J Natl Cancer Inst.* 102: 1344-1353, 2010.
100. Tramacere I, La Vecchia C, Negri E. Tobacco smoking and esophageal and gastric cardia adenocarcinoma: a meta-analysis. *Epidemiology.* 22: 344-349, 2011.
101. Xu Q, Guo W, Shi X, Zhang W, Zhang T, Wu C, Lu J, Wang R, Zhao Y, Ma X, He J. Association Between Alcohol Consumption and the Risk of Barrett's Esophagus: A Meta-Analysis of Observational Studies. *Medicine (Baltimore).* 94: e1244, 2015.
102. Levine DM, Ek WE, Zhang R, Liu X, Onstad L, Sather C, Lao-Sirieix P, Gammon MD, Corley DA, Shaheen NJ, Bird NC, Hardie LJ, Murray LJ, Reid BJ, Chow WH, Risch HA, Nyren O, Ye W, Liu G, Romero Y, Bernstein L, Wu AH, Casson AG, Chanock SJ, Harrington P, Caldas I, Debiram-Beecham I, Caldas C, Hayward NK, Pharoah PD, Fitzgerald RC, Macgregor S, Whiteman DC, Vaughan TL. A genome-wide association study identifies new susceptibility loci for esophageal adenocarcinoma and Barrett's esophagus. *Nat Genet.* 45: 1487-1493, 2013.
103. Wu IC, Zhao Y, Zhai R, Liu CY, Chen F, Ter-Minassian M, Asomaning K, Su L, Heist RS, Kulke MH, Liu G, Christiani DC. Interactions between genetic polymorphisms in the apoptotic pathway and environmental factors on esophageal adenocarcinoma risk. *Carcinogenesis.* 32: 502-506, 2011.
104. Verbeek RE, Spittuler LF, Peute A, van Oijen MG, Ten Kate FJ, Vermeijden JR, Oberndorff A, van Baal JW, Siersema PD. Familial clustering of Barrett's esophagus and esophageal adenocarcinoma in a European cohort. *Clin Gastroenterol Hepatol.* 12: 1656-1663, 2014.
105. van Nistelrooij AM, Dinjens WN, Wagner A, Spaander MC, van Lanschot JJ, Wijnhoven BP. Hereditary Factors in Esophageal Adenocarcinoma. *Gastrointest Tumors.* 1: 93-98, 2014.
106. Nordenstedt H, El-Serag H. The influence of age, sex, and race on the incidence of esophageal cancer in the United States (1992-2006). *Scand J Gastroenterol.* 46: 597-602, 2011.
107. El-Serag HB, Hashmi A, Garcia J, Richardson P, Alsarraj A, Fitzgerald S, Vela M, Shaib Y, Abraham NS, Velez M, Cole R, Rodriguez MB, Anand B, Graham DY, Kramer JR. Visceral abdominal obesity measured by CT scan is associated with an increased risk of Barrett's oesophagus: a case-control study. *Gut.* 63: 220-229, 2014.
108. Rokkas T, Pistiolas D, Sechopoulos P, Robotis I, Margantinis G. Relationship between *Helicobacter pylori* infection and esophageal neoplasia: a meta-analysis. *Clin Gastroenterol Hepatol.* 5: 1413-1417, 2007.
109. Chu YX, Wang WH, Dai Y, Teng GG, Wang SJ. Esophageal *Helicobacter pylori* colonization aggravates esophageal injury caused by reflux. *World J Gastroenterol.* 20: 15715-15726, 2014.
110. Engel LS, Chow WH, Vaughan TL, Gammon MD, Risch HA, Stanford JL, Schoenberg JB, Mayne ST, Dubrow R, Rotterdam H, West AB, Blaser M, Blot WJ, Gail MH, Fraumeni JF, Jr. Population attributable risks of esophageal and gastric cancers. *J Natl Cancer Inst.* 95: 1404-1413, 2003.
111. Sun L, Zhang Z, Xu J, Xu G, Liu X. Dietary Fiber Intake Reduces Risk for Barrett's Esophagus and Esophageal Cancer. *Crit Rev Food Sci Nutr.* 0, 2015.

112. Lagergren J, Bergstrom R, Adami HO, Nyren O. Association between medications that relax the lower esophageal sphincter and risk for esophageal adenocarcinoma. *Ann Intern Med.* 133: 165-175, 2000.
113. Galipeau PC, Li X, Blount PL, Maley CC, Sanchez CA, Odze RD, Ayub K, Rabinovitch PS, Vaughan TL, Reid BJ. NSAIDs modulate CDKN2A, TP53, and DNA content risk for progression to esophageal adenocarcinoma. *PLoS Med.* 4: e67, 2007.
114. Kastelein F, Spaander MC, Biermann K, Steyerberg EW, Kuipers EJ, Bruno MJ, Probar-study G. Nonsteroidal anti-inflammatory drugs and statins have chemopreventative effects in patients with Barrett's esophagus. *Gastroenterology.* 141: 2000-2008, 2011.
115. Nguyen T, Duan Z, Naik AD, Kramer JR, El-Serag HB. Statin Use Reduces Risk of Esophageal Adenocarcinoma in US Veterans With Barrett's Esophagus: a Nested Case-Control Study. *Gastroenterology.* 149: 1392-1398, 2015.
116. Nguyen T, Khalaf N, Ramsey D, El-Serag HB. Statin use is associated with a decreased risk of Barrett's esophagus. *Gastroenterology.* 147: 314-323, 2014.
117. Mathieu LN, Kanarek NF, Tsai HL, Rudin CM, Brock MV. Age and sex differences in the incidence of esophageal adenocarcinoma: results from the Surveillance, Epidemiology, and End Results (SEER) Registry (1973-2008). *Dis Esophagus.* 27: 757-763, 2014.
118. Hvid-Jensen F, Pedersen L, Drewes AM, Sorensen HT, Funch-Jensen P. Incidence of adenocarcinoma among patients with Barrett's esophagus. *N Engl J Med.* 365: 1375-1383, 2011.
119. Lagergren K, Lagergren J, Brusselsaers N. Hormone replacement therapy and oral contraceptives and risk of oesophageal adenocarcinoma: a systematic review and meta-analysis. *Int J Cancer.* 135: 2183-2190, 2014.
120. Sukocheva OA, Wee C, Ansar A, Hussey DJ, Watson DI. Effect of estrogen on growth and apoptosis in esophageal adenocarcinoma cells. *Dis Esophagus.* 26: 628-635, 2013.
121. Sikkema M, de Jonge PJ, Steyerberg EW, Kuipers EJ. Risk of esophageal adenocarcinoma and mortality in patients with Barrett's esophagus: a systematic review and meta-analysis. *Clin Gastroenterol Hepatol.* 8: 235-244, 2010.
122. Corley DA, Levin TR, Habel LA, Weiss NS, Buffler PA. Surveillance and survival in Barrett's adenocarcinomas: a population-based study. *Gastroenterology.* 122: 633-640, 2002.
123. Corley DA, Mehtani K, Quesenberry C, Zhao W, de Boer J, Weiss NS. Impact of endoscopic surveillance on mortality from Barrett's esophagus-associated esophageal adenocarcinomas. *Gastroenterology.* 145: 312-319, 2013.
124. Weusten B, Bisschops R, Coron E, Dinis-Ribeiro M, Dumonceau JM, Esteban JM, Hassan C, Pech O, Repici A, Bergman J, di Pietro M. Endoscopic management of Barrett's esophagus: European Society of Gastrointestinal Endoscopy (ESGE) Position Statement. *Endoscopy.* 49: 191-198, 2017.
125. Schlemper RJ, Riddell RH, Kato Y, Borchard F, Cooper HS, Dawsey SM, Dixon MF, Fenoglio-Preiser CM, Flejou JF, Geboes K, Hattori T, Hirota T, Itabashi M, Iwafuchi M, Iwashita A, Kim YI, Kirchner T, Klimpfinger M, Koike M, Lauwers GY, Lewin KJ, Oberhuber G, Offner F, Price AB, Rubio CA, Shimizu M, Shimoda T, Sipponen P, Solcia E, Stolte M, Watanabe H, Yamabe H. The Vienna classification of gastrointestinal epithelial neoplasia. *Gut.* 47: 251-255, 2000.
126. Kaye PV, Haider SA, Ilyas M, James PD, Soomro I, Faisal W, Catton J, Parsons SL, Ragnath K. Barrett's dysplasia and the Vienna classification: reproducibility, prediction of progression and impact of consensus reporting and p53 immunohistochemistry. *Histopathology.* 54: 699-712, 2009.

127. Zibadi S, Coppola D. Surgical and Molecular Pathology of Barrett Esophagus. *Cancer Control*. 22: 177-185, 2015.
128. Khor TS, Alfaro EE, Ooi EM, Li Y, Srivastava A, Fujita H, Park Y, Kumarasinghe MP, Lauwers GY. Divergent expression of MUC5AC, MUC6, MUC2, CD10, and CDX-2 in dysplasia and intramucosal adenocarcinomas with intestinal and foveolar morphology: is this evidence of distinct gastric and intestinal pathways to carcinogenesis in Barrett Esophagus? *Am J Surg Pathol*. 36: 331-342, 2012.
129. Shaheen NJ, Falk GW, Iyer PG, Gerson LB, American College of G. ACG Clinical Guideline: Diagnosis and Management of Barrett's Esophagus. *Am J Gastroenterol*. 111: 30-50, 2016.
130. Shakhathreh MH, Duan Z, Kramer J, Naik AD, Helm A, Hinojosa-Lindsey M, Chen GJ, El-Serag HB. The Incidence of Esophageal Adenocarcinoma in a National Veterans Cohort With Barrett's Esophagus. *Am J Gastroenterol*. 109: 1862-1868, 2014.
131. Bhat S, Coleman HG, Yousef F, Johnston BT, McManus DT, Gavin AT, Murray LJ. Risk of malignant progression in Barrett's esophagus patients: results from a large population-based study. *J Natl Cancer Inst*. 103: 1049-1057, 2011.
132. de Jonge PJ, van Blankenstein M, Looman CW, Casparie MK, Meijer GA, Kuipers EJ. Risk of malignant progression in patients with Barrett's oesophagus: a Dutch nationwide cohort study. *Gut*. 59: 1030-1036, 2010.
133. Wani S, Falk G, Hall M, Gaddam S, Wang A, Gupta N, Singh M, Singh V, Chuang KY, Boolchand V, Gavini H, Kuczynski J, Sud P, Reddymasu S, Bansal A, Rastogi A, Mathur SC, Young P, Cash B, Lieberman DA, Sampliner RE, Sharma P. Patients with nondysplastic Barrett's esophagus have low risks for developing dysplasia or esophageal adenocarcinoma. *Clin Gastroenterol Hepatol*. 9: 220-227, 2011.
134. Desai TK, Krishnan K, Samala N, Singh J, Cluley J, Perla S, Howden CW. The incidence of oesophageal adenocarcinoma in non-dysplastic Barrett's oesophagus: a meta-analysis. *Gut*. 61: 970-976, 2012.
135. Singh S, Manickam P, Amin AV, Samala N, Schouten LJ, Iyer PG, Desai TK. Incidence of esophageal adenocarcinoma in Barrett's esophagus with low-grade dysplasia: a systematic review and meta-analysis. *Gastrointest Endosc*. 79: 897-909, 2014.
136. Rastogi A, Puli S, El-Serag HB, Bansal A, Wani S, Sharma P. Incidence of esophageal adenocarcinoma in patients with Barrett's esophagus and high-grade dysplasia: a meta-analysis. *Gastrointest Endosc*. 67: 394-398, 2008.
137. Werbrout E, De Hertogh G, Sagaert X, Coremans G, Willekens H, Demedts I, Bisschops R. Oesophageal biopsies are insufficient to predict final histology after endoscopic resection in early Barrett's neoplasia. *United European Gastroenterol J*. 4: 663-668, 2016.
138. Nasr JY, Schoen RE. Prevalence of adenocarcinoma at esophagectomy for Barrett's esophagus with high grade dysplasia. *J Gastrointest Oncol*. 2: 34-38, 2011.
139. TNM Classification of Malignant Tumours. UICC. Wiley-Blackwell, New York 2009. 66-72.
140. Thrift AP, Whiteman DC. The incidence of esophageal adenocarcinoma continues to rise: analysis of period and birth cohort effects on recent trends. *Ann Oncol*. 23: 3155-3162, 2012.
141. Hur C, Miller M, Kong CY, Dowling EC, Nattinger KJ, Dunn M, Feuer EJ. Trends in esophageal adenocarcinoma incidence and mortality. *Cancer*. 119: 1149-1158, 2013.
142. Cen P, Banki F, Cheng L, Khalil K, Du XL, Fallon M, Amato RJ, Kaiser LR. Changes in age, stage distribution, and survival of patients with esophageal adenocarcinoma over three decades in the United States. *Ann Surg Oncol*. 19: 1685-1691, 2012.

143. Pennathur A, Farkas A, Krasinskas AM, Ferson PF, Gooding WE, Gibson MK, Schuchert MJ, Landreneau RJ, Luketich JD. Esophagectomy for T1 esophageal cancer: outcomes in 100 patients and implications for endoscopic therapy. *Ann Thorac Surg.* 87: 1048-1054, 2009.
144. Kauppi J, Rasanen J, Sihvo E, Huuhtanen R, Nelskyla K, Salo J. Open versus minimally invasive esophagectomy: clinical outcomes for locally advanced esophageal adenocarcinoma. *Surg Endosc.* 29: 2614-2619, 2015.
145. Thirunavukarasu P, Gabriel E, Attwood K, Kukar M, Hochwald SN, Nurkin SJ. Nationwide analysis of short-term surgical outcomes of minimally invasive esophagectomy for malignancy. *Int J Surg.* 25: 69-75, 2016.
146. Napier KJ, Scheerer M, Misra S. Esophageal cancer: A Review of epidemiology, pathogenesis, staging workup and treatment modalities. *World J Gastrointest Oncol.* 6: 112-120, 2014.
147. Villaflor VM, Allaix ME, Minsky B, Herbella FA, Patti MG. Multidisciplinary approach for patients with esophageal cancer. *World J Gastroenterol.* 18: 6737-6746, 2012.
148. Kauppi J, Gockel I, Rantanen T, Hansen T, Ristimaki A, Lang H, Sihvo E, Rasanen J, Junginger T, Salo JA. Cause of death during long-term follow-up for superficial esophageal adenocarcinoma. *Ann Surg Oncol.* 20: 2428-2433, 2013.
149. Vallbohmer D, Holscher AH, DeMeester S, DeMeester T, Salo J, Peters J, Lerut T, Swisher SG, Schroder W, Bollschweiler E, Hofstetter W. A multicenter study of survival after neoadjuvant radiotherapy/chemotherapy and esophagectomy for ypT0N0M0R0 esophageal cancer. *Ann Surg.* 252: 744-749, 2010.
150. Saddoughi SA, Reinersman JM, Zhukov YO, Taswell J, Mara K, Harmsen SW, Blackmon SH, Cassivi SD, Nichols F, 3rd, Shen KR, Wagle DA, Allen MS. Survival After Surgical Resection of Stage IV Esophageal Cancer. *Ann Thorac Surg.* 103: 261-266, 2017.
151. Siewert JR, Stein HJ. Classification of adenocarcinoma of the oesophagogastric junction. *Br J Surg.* 85: 1457-1459, 1998.
152. Hasegawa S, Yoshikawa T, Aoyama T, Hayashi T, Yamada T, Tsuchida K, Cho H, Oshima T, Yukawa N, Rino Y, Masuda M, Tsuburaya A. Esophagus or stomach? The seventh TNM classification for Siewert type II/III junctional adenocarcinoma. *Ann Surg Oncol.* 20: 773-779, 2013.
153. Buas MF, Vaughan TL. Epidemiology and risk factors for gastroesophageal junction tumors: understanding the rising incidence of this disease. *Semin Radiat Oncol.* 23: 3-9, 2013.
154. Lagergren J, Ye W, Lagergren P, Lu Y. The risk of esophageal adenocarcinoma after antireflux surgery. *Gastroenterology.* 138: 1297-1301, 2010.
155. Peters FT, Ganesh S, Kuipers EJ, Sluiter WJ, Klinkenberg-Knol EC, Lamers CB, Kleibeuker JH. Endoscopic regression of Barrett's oesophagus during omeprazole treatment; a randomised double blind study. *Gut.* 45: 489-494, 1999.
156. Miyashita T, Shah FA, Harmon JW, Marti GP, Matsui D, Okamoto K, Makino I, Hayashi H, Oyama K, Nakagawara H, Tajima H, Fujita H, Takamura H, Murakami M, Ninomiya I, Kitagawa H, Fushida S, Fujimura T, Ohta T. Do proton pump inhibitors protect against cancer progression in GERD? *Surg Today.* 43: 831-837, 2013.
157. Yates RB, Oelschlager BK. Surgical treatment of gastroesophageal reflux disease. *Surg Clin North Am.* 95: 527-553, 2015.
158. Hamdy E, El Nakeeb A, Hamed H, El Hemaly M, ElHak NG. Outcome of laparoscopic Nissen fundoplication for gastroesophageal reflux disease in non-responders to proton pump inhibitors. *J Gastrointest Surg.* 18: 1557-1562, 2014.

159. Herbella FA, Tedesco P, Nipomnick I, Fisichella PM, Patti MG. Effect of partial and total laparoscopic fundoplication on esophageal body motility. *Surg Endosc.* 21: 285-288, 2007.
160. Heider TR, Behrns KE, Koruda MJ, Shaheen NJ, Lucktong TA, Bradshaw B, Farrell TM. Fundoplication improves disordered esophageal motility. *J Gastrointest Surg.* 7: 159-163, 2003.
161. Gatenby PA, Bann SD. Antireflux surgery. *Minerva Chir.* 64: 169-181, 2009.
162. Kessing BF, Bredenoord AJ, Schijven MP, van der Peet DL, van Berge Henegouwen MI, Smout AJ. Long-term effects of anti-reflux surgery on the physiology of the esophagogastric junction. *Surg Endosc.* 29: 3726-3732, 2015.
163. Donahue PE, Larson GM, Stewardson RH, Bombeck CT. Floppy Nissen fundoplication. *Rev Surg.* 34: 223-224, 1977.
164. Broeders JA, Roks DJ, Ahmed Ali U, Watson DI, Baigrie RJ, Cao Z, Hartmann J, Maddern GJ. Laparoscopic anterior 180-degree versus nissen fundoplication for gastroesophageal reflux disease: systematic review and meta-analysis of randomized clinical trials. *Ann Surg.* 257: 850-859, 2013.
165. Tian ZC, Wang B, Shan CX, Zhang W, Jiang DZ, Qiu M. A Meta-Analysis of Randomized Controlled Trials to Compare Long-Term Outcomes of Nissen and Toupet Fundoplication for Gastroesophageal Reflux Disease. *PLoS One.* 10: e0127627, 2015.
166. Ma S, Qian B, Shang L, Shi R, Zhang G. A meta-analysis comparing laparoscopic partial versus Nissen fundoplication. *ANZ J Surg.* 82: 17-22, 2012.
167. Csendes A, Braghetto I, Burdiles P, Smok G, Henriquez A, Parada F. Regression of intestinal metaplasia to cardiac or fundic mucosa in patients with Barrett's esophagus submitted to vagotomy, partial gastrectomy and duodenal diversion. A prospective study of 78 patients with more than 5 years of follow up. *Surgery.* 139: 46-53, 2006.
168. Braghetto I, Korn O, Csendes A, Gutierrez L, Valladares H, Chacon M. Laparoscopic treatment of obese patients with gastroesophageal reflux disease and Barrett's esophagus: a prospective study. *Obes Surg.* 22: 764-772, 2012.
169. Reynolds JL, Zehetner J, Bildzukewicz N, Katkhouda N, Dandekar G, Lipham JC. Magnetic sphincter augmentation with the LINX device for gastroesophageal reflux disease after U.S. Food and Drug Administration approval. *Am Surg.* 80: 1034-1038, 2014.
170. Testoni PA, Vailati C, Testoni S, Corsetti M. Transoral incisionless fundoplication (TIF 2.0) with EsophyX for gastroesophageal reflux disease: long-term results and findings affecting outcome. *Surg Endosc.* 26: 1425-1435, 2012.
171. Rodriguez L, Rodriguez P, Gomez B, Ayala JC, Oksenberg D, Perez-Castilla A, Netto MG, Soffer E, Crowell MD. Long-term results of electrical stimulation of the lower esophageal sphincter for the treatment of gastroesophageal reflux disease. *Endoscopy.* 45: 595-604, 2013.
172. Salminen P, Hurme S, Ovaska J. Fifteen-year outcome of laparoscopic and open Nissen fundoplication: a randomized clinical trial. *Ann Thorac Surg.* 93: 228-233, 2012.
173. O'Riordan JM, Byrne PJ, Ravi N, Keeling PW, Reynolds JV. Long-term clinical and pathologic response of Barrett's esophagus after antireflux surgery. *Am J Surg.* 188: 27-33, 2004.
174. Rickenbacher N, Kotter T, Kochen MM, Scherer M, Blozik E. Fundoplication versus medical management of gastroesophageal reflux disease: systematic review and meta-analysis. *Surg Endosc.* 28: 143-155, 2014.

175. Galvani C, Fisichella PM, Gorodner MV, Perretta S, Patti MG. Symptoms are a poor indicator of reflux status after fundoplication for gastroesophageal reflux disease: role of esophageal functions tests. *Arch Surg.* 138: 514-518, 2003.
176. Lord RV, Kaminski A, Oberg S, Bowrey DJ, Hagen JA, DeMeester SR, Sillin LF, Peters JH, Crookes PF, DeMeester TR. Absence of gastroesophageal reflux disease in a majority of patients taking acid suppression medications after Nissen fundoplication. *J Gastrointest Surg.* 6: 3-9, 2002.
177. Salminen P. The laparoscopic Nissen fundoplication--a better operation? *Surgeon.* 7: 224-227, 2009.
178. Ciofica R, Riedl O, Neumayer C, Lechner W, Schwab GP, Gadenstatter M. The use of medication after laparoscopic antireflux surgery. *Surg Endosc.* 23: 1938-1946, 2009.
179. Iqbal M, Batch AJ, Spychal RT, Cooper BT. Outcome of surgical fundoplication for extraesophageal (atypical) manifestations of gastroesophageal reflux disease in adults: a systematic review. *J Laparoendosc Adv Surg Tech A.* 18: 789-796, 2008.
180. Isolauri J, Luostarinen M, Viljakka M, Isolauri E, Keyrilainen O, Karvonen AL. Long-term comparison of antireflux surgery versus conservative therapy for reflux esophagitis. *Ann Surg.* 225: 295-299, 1997.
181. Engstrom C, Cai W, Irvine T, Devitt PG, Thompson SK, Game PA, Bessell JR, Jamieson GG, Watson DI. Twenty years of experience with laparoscopic antireflux surgery. *Br J Surg.* 99: 1415-1421, 2012.
182. Spechler SJ. Does Barrett's esophagus regress after surgery (or proton pump inhibitors)? *Dig Dis.* 32: 156-163, 2014.
183. Jenkinson AD, Kadirkamanathan SS, Scott SM, Yazaki E, Evans DF. Relationship between symptom response and oesophageal acid exposure after medical and surgical treatment for gastro-oesophageal reflux disease. *Br J Surg.* 91: 1460-1465, 2004.
184. de Jonge PJ, Spaander MC, Bruno MJ, Kuipers EJ. Acid suppression and surgical therapy for Barrett's oesophagus. *Best Pract Res Clin Gastroenterol.* 29: 139-150, 2015.
185. Brown CS, Lapin B, Wang C, Goldstein JL, Linn JG, Denham W, Haggerty SP, Talamonti MS, Howington JA, Carbray J, Ujiki MB. Reflux control is important in the management of Barrett's Esophagus: results from a retrospective 1,830 patient cohort. *Surg Endosc.* 29: 3528-3534, 2015.
186. Nason KS, Wichienkuer PP, Awais O, Schuchert MJ, Luketich JD, O'Rourke RW, Hunter JG, Morris CD, Jobe BA. Gastroesophageal reflux disease symptom severity, proton pump inhibitor use, and esophageal carcinogenesis. *Arch Surg.* 146: 851-858, 2011.
187. Chang EY, Morris CD, Seltman AK, O'Rourke RW, Chan BK, Hunter JG, Jobe BA. The effect of antireflux surgery on esophageal carcinogenesis in patients with barrett esophagus: a systematic review. *Ann Surg.* 246: 11-21, 2007.
188. Zaninotto G, Parente P, Salvador R, Farinati F, Tieppo C, Passuello N, Zanatta L, Fassan M, Cavallin F, Costantini M, Mescoli C, Battaglia G, Ruol A, Ancona E, Rugge M. Long-term follow-up of Barrett's epithelium: medical versus antireflux surgical therapy. *J Gastrointest Surg.* 16: 7-14, 2012.
189. Corey KE, Schmitz SM, Shaheen NJ. Does a surgical antireflux procedure decrease the incidence of esophageal adenocarcinoma in Barrett's esophagus? A meta-analysis. *Am J Gastroenterol.* 98: 2390-2394, 2003.
190. Parrilla P, Martinez de Haro LF, Ortiz A, Munitiz V, Molina J, Bermejo J, Canteras M. Long-term results of a randomized prospective study comparing medical and surgical treatment of Barrett's esophagus. *Ann Surg.* 237: 291-298, 2003.

191. Zehetner J, DeMeester SR, Ayazi S, Costales JL, Augustin F, Oezcelik A, Lipham JC, Sohn HJ, Hagen JA, DeMeester TR. Long-term follow-up after anti-reflux surgery in patients with Barrett's esophagus. *J Gastrointest Surg.* 14: 1483-1491, 2010.
192. Csendes A, Burdiles P, Braghetto I, Smok G, Castro C, Korn O, Henriquez A. Dysplasia and adenocarcinoma after classic antireflux surgery in patients with Barrett's esophagus: the need for long-term subjective and objective follow-up. *Ann Surg.* 235: 178-185, 2002.
193. Lagergren J, Viklund P. Is esophageal adenocarcinoma occurring late after antireflux surgery due to persistent postoperative reflux? *World J Surg.* 31: 465-469, 2007.
194. Lofdahl HE, Lu Y, Lagergren P, Lagergren J. Risk factors for esophageal adenocarcinoma after antireflux surgery. *Ann Surg.* 257: 579-582, 2013.
195. Kothari S, Kaul V. Endoscopic Mucosal Resection and Endoscopic Submucosal Dissection for Endoscopic Therapy of Barrett's Esophagus-related Neoplasia. *Gastroenterol Clin North Am.* 44: 317-335, 2015.
196. Pimentel-Nunes P, Dinis-Ribeiro M, Ponchon T, Repici A, Vieth M, De Ceglie A, Amato A, Berr F, Bhandari P, Bialek A, Conio M, Haringsma J, Langner C, Meisner S, Messmann H, Morino M, Neuhaus H, Piessevaux H, Ruge M, Saunders BP, Robaszkiewicz M, Seewald S, Kashin S, Dumonceau JM, Hassan C, Deprez PH. Endoscopic submucosal dissection: European Society of Gastrointestinal Endoscopy (ESGE) Guideline. *Endoscopy.* 47: 829-854, 2015.
197. Blevins CH, Iyer PG. Endoscopic therapy for Barrett's oesophagus. *Best Pract Res Clin Gastroenterol.* 29: 167-177, 2015.
198. Hur C, Choi SE, Rubenstein JH, Kong CY, Nishioka NS, Provenzale DT, Inadomi JM. The cost effectiveness of radiofrequency ablation for Barrett's esophagus. *Gastroenterology.* 143: 567-575, 2012.
199. Orman ES, Li N, Shaheen NJ. Efficacy and durability of radiofrequency ablation for Barrett's Esophagus: systematic review and meta-analysis. *Clin Gastroenterol Hepatol.* 11: 1245-1255, 2013.
200. Odze RD, Lauwers GY. Histopathology of Barrett's esophagus after ablation and endoscopic mucosal resection therapy. *Endoscopy.* 40: 1008-1015, 2008.
201. Pouw RE, Gondrie JJ, Rygiel AM, Sondermeijer CM, ten Kate FJ, Odze RD, Vieth M, Krishnadath KK, Bergman JJ. Properties of the neosquamous epithelium after radiofrequency ablation of Barrett's esophagus containing neoplasia. *Am J Gastroenterol.* 104: 1366-1373, 2009.
202. Paulson TG, Xu L, Sanchez C, Blount PL, Ayub K, Odze RD, Reid BJ. Neosquamous epithelium does not typically arise from Barrett's epithelium. *Clin Cancer Res.* 12: 1701-1706, 2006.
203. Hornick JL, Mino-Kenudson M, Lauwers GY, Liu W, Goyal R, Odze RD. Buried Barrett's epithelium following photodynamic therapy shows reduced crypt proliferation and absence of DNA content abnormalities. *Am J Gastroenterol.* 103: 38-47, 2008.
204. Dvorak K, Ramsey L, Payne CM, Sampliner R, Fass R, Bernstein H, Prasad A, Garewal H. Abnormal expression of biomarkers in incompletely ablated Barrett's esophagus. *Ann Surg.* 244: 1031-1036, 2006.
205. Gupta M, Iyer PG, Lutzke L, Gorospe EC, Abrams JA, Falk GW, Ginsberg GG, Rustgi AK, Lightdale CJ, Wang TC, Fudman DI, Poneris JM, Wang KK. Recurrence of esophageal intestinal metaplasia after endoscopic mucosal resection and radiofrequency ablation of Barrett's esophagus: results from a US Multicenter Consortium. *Gastroenterology.* 145: 79-86, 2013.
206. Small AJ, Sutherland SE, Hightower JS, Guarner-Argente C, Furth EE, Kochman ML, Forde KA, Bewtra M, Falk GW, Ginsberg GG. Comparative risk of recurrence of dysplasia and carcinoma after endoluminal eradication therapy of high-grade dysplasia

- versus intramucosal carcinoma in Barrett's esophagus. *Gastrointest Endosc.* 81: 1158-1166, 2015.
207. Haidry RJ, Butt MA, Dunn JM, Gupta A, Lipman G, Smart HL, Bhandari P, Smith L, Willert R, Fullarton G, Di Pietro M, Gordon C, Penman I, Barr H, Patel P, Kapoor N, Hoare J, Narayanasamy R, Ang Y, Veitch A, Rangunath K, Novelli M, Lovat LB, on behalf of the UKRFAR. Improvement over time in outcomes for patients undergoing endoscopic therapy for Barrett's oesophagus-related neoplasia: 6-year experience from the first 500 patients treated in the UK patient registry. *Gut.* 64: 1192-1199, 2015.
 208. Haidry R, Lovat L. Long-term durability of radiofrequency ablation for Barrett's-related neoplasia. *Curr Opin Gastroenterol.* 31: 316-320, 2015.
 209. Shaheen NJ, Sharma P, Overholt BF, Wolfsen HC, Sampliner RE, Wang KK, Galanko JA, Bronner MP, Goldblum JR, Bennett AE, Jobe BA, Eisen GM, Fennerty MB, Hunter JG, Fleischer DE, Sharma VK, Hawes RH, Hoffman BJ, Rothstein RI, Gordon SR, Mashimo H, Chang KJ, Muthusamy VR, Edmundowicz SA, Spechler SJ, Siddiqui AA, Souza RF, Infantolino A, Falk GW, Kimmey MB, Madanick RD, Chak A, Lightdale CJ. Radiofrequency ablation in Barrett's esophagus with dysplasia. *N Engl J Med.* 360: 2277-2288, 2009.
 210. Phoa KN, Pouw RE, van Vilsteren FG, Sondermeijer CM, Ten Kate FJ, Visser M, Meijer SL, van Berge Henegouwen MI, Weusten BL, Schoon EJ, Mallant-Hent RC, Bergman JJ. Remission of Barrett's esophagus with early neoplasia 5 years after radiofrequency ablation with endoscopic resection: a Netherlands cohort study. *Gastroenterology.* 145: 96-104, 2013.
 211. Wolf WA, Pasricha S, Cotton C, Li N, Triadafilopoulos G, Muthusamy VR, Chmielewski GW, Corbett FS, Camara DS, Lightdale CJ, Wolfsen H, Chang KJ, Overholt BF, Pruitt RE, Ertan A, Komanduri S, Infantolino A, Rothstein RI, Shaheen NJ. Incidence of Esophageal Adenocarcinoma and Causes of Mortality After Radiofrequency Ablation of Barrett's Esophagus. *Gastroenterology.* 149: 1752-1761, 2015.
 212. Pasricha S, Bulsiewicz WJ, Hathorn KE, Komanduri S, Muthusamy VR, Rothstein RI, Wolfsen HC, Lightdale CJ, Overholt BF, Camara DS, Dellon ES, Lyday WD, Ertan A, Chmielewski GW, Shaheen NJ. Durability and predictors of successful radiofrequency ablation for Barrett's esophagus. *Clin Gastroenterol Hepatol.* 12: 1840-1847, 2014.
 213. Pech O, Behrens A, May A, Nachbar L, Gossner L, Rabenstein T, Manner H, Guenter E, Huijsmans J, Vieth M, Stolte M, Ell C. Long-term results and risk factor analysis for recurrence after curative endoscopic therapy in 349 patients with high-grade intraepithelial neoplasia and mucosal adenocarcinoma in Barrett's oesophagus. *Gut.* 57: 1200-1206, 2008.
 214. Gray NA, Odze RD, Spechler SJ. Buried metaplasia after endoscopic ablation of Barrett's esophagus: a systematic review. *Am J Gastroenterol.* 106: 1899-1908, 2011.
 215. Titi M, Overhiser A, Ulusarac O, Falk GW, Chak A, Wang K, Sharma P. Development of subsquamous high-grade dysplasia and adenocarcinoma after successful radiofrequency ablation of Barrett's esophagus. *Gastroenterology.* 143: 564-566, 2012.
 216. Anders M, Lucks Y, El-Masry MA, Quaas A, Rosch T, Schachschal G, Bahr C, Gauger U, Sauter G, Izbicki JR, Marx AH. Subsquamous extension of intestinal metaplasia is detected in 98% of cases of neoplastic Barrett's esophagus. *Clin Gastroenterol Hepatol.* 12: 405-410, 2014.
 217. Kohoutova D, Haidry R, Banks M, Bown S, Sehgal V, Butt MA, Graham D, Thorpe S, Novelli M, Rodriguez-Justo M, Lovat L. Esophageal neoplasia arising from subsquamous buried glands after an apparently successful photodynamic therapy or radiofrequency ablation for Barrett's associated neoplasia. *Scand J Gastroenterol.* 50: 1315-1321, 2015.

218. Hornick JL, Blount PL, Sanchez CA, Cowan DS, Ayub K, Maley CC, Reid BJ, Odze RD. Biologic properties of columnar epithelium underneath reepithelialized squamous mucosa in Barrett's esophagus. *Am J Surg Pathol.* 29: 372-380, 2005.
219. Illig R, Klieser E, Kiesslich T, Neureiter D. GERD-Barrett-Adenocarcinoma: Do We Have Suitable Prognostic and Predictive Molecular Markers? *Gastroenterol Res Pract.* 2013: 643084, 2013.
220. Palles C, Chegwidden L, Li X, Findlay JM, Farnham G, Castro Giner F, Peppelenbosch MP, Kovac M, Adams CL, Prenen H, Briggs S, Harrison R, Sanders S, MacDonald D, Haigh C, Tucker A, Love S, Nanji M, deCaestecker J, Ferry D, Rathbone B, Hapeshi J, Barr H, Moayyedi P, Watson P, Zietek B, Maroo N, Gay L, Underwood T, Boulter L, McMurtry H, Monk D, Patel P, Ragunath K, Al Dulaimi D, Murray I, Koss K, Veitch A, Trudgill N, Nwokolo C, Rembacken B, Atherfold P, Green E, Ang Y, Kuipers EJ, Chow W, Paterson S, Kadri S, Beales I, Grimley C, Mullins P, Beckett C, Farrant M, Dixon A, Kelly S, Johnson M, Wajed S, Dhar A, Sawyer E, Roylance R, Onstad L, Gammon MD, Corley DA, Shaheen NJ, Bird NC, Hardie LJ, Reid BJ, Ye W, Liu G, Romero Y, Bernstein L, Wu AH, Casson AG, Fitzgerald R, Whiteman DC, Risch HA, Levine DM, Vaughan TL, Verhaar AP, van den Brande J, Toxopeus EL, Spaander MC, Wijnhoven BP, van der Laan LJ, Krishnadath K, Wijmenga C, Trynka G, McManus R, Reynolds JV, O'Sullivan J, MacMathuna P, McGarrigle SA, Kelleher D, Vermeire S, Cleynen I, Bisschops R, Tomlinson I, Jankowski J. Polymorphisms near TBX5 and GDF7 are associated with increased risk for Barrett's esophagus. *Gastroenterology.* 148: 367-378, 2015.
221. Becker J, May A, Gerges C, Anders M, Schmidt C, Veits L, Noder T, Mayershofer R, Kreuser N, Manner H, Venerito M, Hofer JH, Lyros O, Ahlbrand CJ, Arras M, Hofer S, Heinrichs SK, Weise K, Hess T, Bohmer AC, Kosiol N, Kiesslich R, Izbicki JR, Holscher AH, Bollschweiler E, Malfertheiner P, Lang H, Moehler M, Lorenz D, Ott K, Schmidt T, Nothen MM, Hackelsberger A, Schumacher B, Pech O, Vashist Y, Vieth M, Weismuller J, Knapp M, Neuhaus H, Rosch T, Ell C, Gockel I, Schumacher J. The Barrett-associated variants at GDF7 and TBX5 also increase esophageal adenocarcinoma risk. *Cancer Med.* 5: 888-891, 2016.
222. Reid BJ, Prevo LJ, Galipeau PC, Sanchez CA, Longton G, Levine DS, Blount PL, Rabinovitch PS. Predictors of progression in Barrett's esophagus II: baseline 17p (p53) loss of heterozygosity identifies a patient subset at increased risk for neoplastic progression. *Am J Gastroenterol.* 96: 2839-2848, 2001.
223. Xu E, Gu J, Hawk ET, Wang KK, Lai M, Huang M, Ajani J, Wu X. Genome-wide methylation analysis shows similar patterns in Barrett's esophagus and esophageal adenocarcinoma. *Carcinogenesis.* 34: 2750-2756, 2013.
224. Mallick R, Patnaik SK, Wani S, Bansal A. A Systematic Review of Esophageal MicroRNA Markers for Diagnosis and Monitoring of Barrett's Esophagus. *Dig Dis Sci.* 61: 1039-1050, 2016.
225. Merlo LM, Shah NA, Li X, Blount PL, Vaughan TL, Reid BJ, Maley CC. A comprehensive survey of clonal diversity measures in Barrett's esophagus as biomarkers of progression to esophageal adenocarcinoma. *Cancer Prev Res (Phila).* 3: 1388-1397, 2010.
226. Maley CC, Galipeau PC, Finley JC, Wongsurawat VJ, Li X, Sanchez CA, Paulson TG, Blount PL, Risques RA, Rabinovitch PS, Reid BJ. Genetic clonal diversity predicts progression to esophageal adenocarcinoma. *Nat Genet.* 38: 468-473, 2006.
227. Schneider PM, Stoeltzing O, Roth JA, Hoelscher AH, Wegerer S, Mizumoto S, Becker K, Dittler HJ, Fink U, Siewert JR. P53 mutational status improves estimation of prognosis in patients with curatively resected adenocarcinoma in Barrett's esophagus. *Clin Cancer Res.* 6: 3153-3158, 2000.
228. Kimchi ET, Posner MC, Park JO, Darga TE, Kocherginsky M, Karrison T, Hart J, Smith KD, Mezhir JJ, Weichselbaum RR, Khodarev NN. Progression of Barrett's

- metaplasia to adenocarcinoma is associated with the suppression of the transcriptional programs of epidermal differentiation. *Cancer Res.* 65: 3146-3154, 2005.
229. Wang S, Zhan M, Yin J, Abraham JM, Mori Y, Sato F, Xu Y, Olaru A, Berki AT, Li H, Schulmann K, Kan T, Hamilton JP, Paun B, Yu MM, Jin Z, Cheng Y, Ito T, Mantzur C, Greenwald BD, Meltzer SJ. Transcriptional profiling suggests that Barrett's metaplasia is an early intermediate stage in esophageal adenocarcinogenesis. *Oncogene.* 25: 3346-3356, 2006.
230. Milano F, van Baal JW, Buttar NS, Rygiel AM, de Kort F, DeMars CJ, Rosmolen WD, Bergman JJ, J VAM, Wang KK, Peppelenbosch MP, Krishnadath KK. Bone morphogenetic protein 4 expressed in esophagitis induces a columnar phenotype in esophageal squamous cells. *Gastroenterology.* 132: 2412-2421, 2007.
231. Wang DH, Clemons NJ, Miyashita T, Dupuy AJ, Zhang W, Szczepny A, Corcoran-Schwartz IM, Wilburn DL, Montgomery EA, Wang JS, Jenkins NA, Copeland NA, Harmon JW, Phillips WA, Watkins DN. Aberrant epithelial-mesenchymal Hedgehog signaling characterizes Barrett's metaplasia. *Gastroenterology.* 138: 1810-1822, 2010.
232. Tamagawa Y, Ishimura N, Uno G, Yuki T, Kazumori H, Ishihara S, Amano Y, Kinoshita Y. Notch signaling pathway and Cdx2 expression in the development of Barrett's esophagus. *Lab Invest.* 92: 896-909, 2012.
233. Silberg DG, Swain GP, Suh ER, Traber PG. Cdx1 and cdx2 expression during intestinal development. *Gastroenterology.* 119: 961-971, 2000.
234. Suh E, Traber PG. An intestine-specific homeobox gene regulates proliferation and differentiation. *Mol Cell Biol.* 16: 619-625, 1996.
235. Burnat G, Rau T, Elshimi E, Hahn EG, Konturek PC. Bile acids induce overexpression of homeobox gene CDX-2 and vascular endothelial growth factor (VEGF) in human Barrett's esophageal mucosa and adenocarcinoma cell line. *Scand J Gastroenterol.* 42: 1460-1465, 2007.
236. Huo X, Zhang HY, Zhang XI, Lynch JP, Strauch ED, Wang JY, Melton SD, Genta RM, Wang DH, Spechler SJ, Souza RF. Acid and bile salt-induced CDX2 expression differs in esophageal squamous cells from patients with and without Barrett's esophagus. *Gastroenterology.* 139: 194-203, 2010.
237. Kong J, Crissey MA, Funakoshi S, Kreindler JL, Lynch JP. Ectopic Cdx2 expression in murine esophagus models an intermediate stage in the emergence of Barrett's esophagus. *PLoS One.* 6: e18280, 2011.
238. Vallbohmer D, DeMeester SR, Peters JH, Oh DS, Kuramochi H, Shimizu D, Hagen JA, Danenberg KD, Danenberg PV, DeMeester TR, Chandrasoma PT. Cdx-2 expression in squamous and metaplastic columnar epithelia of the esophagus. *Dis Esophagus.* 19: 260-266, 2006.
239. Moons LM, Bax DA, Kuipers EJ, Van Dekken H, Haringsma J, Van Vliet AH, Siersema PD, Kusters JG. The homeodomain protein CDX2 is an early marker of Barrett's oesophagus. *J Clin Pathol.* 57: 1063-1068, 2004.
240. Phillips RW, Frierson HF, Jr., Moskaluk CA. Cdx2 as a marker of epithelial intestinal differentiation in the esophagus. *Am J Surg Pathol.* 27: 1442-1447, 2003.
241. Lord RV, Brabender J, Wickramasinghe K, DeMeester SR, Holscher A, Schneider PM, Danenberg PV, DeMeester TR. Increased CDX2 and decreased PITX1 homeobox gene expression in Barrett's esophagus and Barrett's-associated adenocarcinoma. *Surgery.* 138: 924-931, 2005.
242. Coussens LM, Werb Z. Inflammation and cancer. *Nature.* 420: 860-867, 2002.
243. Mantovani A. Molecular pathways linking inflammation and cancer. *Curr Mol Med.* 10: 369-373, 2010.
244. Hanahan D, Weinberg RA. Hallmarks of cancer: the next generation. *Cell.* 144: 646-674, 2011.

245. Gibson MK, Dhaliwal AS, Clemons NJ, Phillips WA, Dvorak K, Tong D, Law S, Pirchi ED, Rasanen J, Krasna MJ, Parikh K, Krishnadath KK, Chen Y, Griffiths L, Colleypriest BJ, Farrant JM, Tosh D, Das KM, Bajpai M. Barrett's esophagus: cancer and molecular biology. *Ann N Y Acad Sci.* 1300: 296-314, 2013.
246. Fitzgerald RC, Onwuegbusi BA, Bajaj-Elliott M, Saeed IT, Burnham WR, Farthing MJ. Diversity in the oesophageal phenotypic response to gastro-oesophageal reflux: immunological determinants. *Gut.* 50: 451-459, 2002.
247. Lind A, Koenderman L, Kusters JG, Siersema PD. Squamous tissue lymphocytes in the esophagus of controls and patients with reflux esophagitis and Barrett's esophagus are characterized by a non-inflammatory phenotype. *PLoS One.* 9: e106261, 2014.
248. Milano F, Jorritsma T, Rygiel AM, Bergman JJ, Sondermeijer C, Ten Brinke A, vanHam SM, Krishnadath KK. Expression pattern of immune suppressive cytokines and growth factors in oesophageal adenocarcinoma reveal a tumour immune escape-promoting microenvironment. *Scand J Immunol.* 68: 616-623, 2008.
249. Hanahan D, Weinberg RA. The hallmarks of cancer. *Cell.* 100: 57-70, 2000.
250. Pani G, Galeotti T, Chiarugi P. Metastasis: cancer cell's escape from oxidative stress. *Cancer Metastasis Rev.* 29: 351-378, 2010.
251. Rasanen JV, Sihvo EI, Ahotupa MO, Farkkila MA, Salo JA. The expression of 8-hydroxydeoxyguanosine in oesophageal tissues and tumours. *Eur J Surg Oncol.* 33: 1164-1168, 2007.
252. Sihvo EI, Salminen JT, Rantanen TK, Ramo OJ, Ahotupa M, Farkkila M, Auvinen MI, Salo JA. Oxidative stress has a role in malignant transformation in Barrett's oesophagus. *Int J Cancer.* 102: 551-555, 2002.
253. Dvorak K, Payne CM, Chavarria M, Ramsey L, Dvorakova B, Bernstein H, Holubec H, Sampliner RE, Guy N, Condon A, Bernstein C, Green SB, Prasad A, Garewal HS. Bile acids in combination with low pH induce oxidative stress and oxidative DNA damage: relevance to the pathogenesis of Barrett's oesophagus. *Gut.* 56: 763-771, 2007.
254. Sihvo EI, Ruohtula T, Auvinen MI, Koivistoinen A, Harjula AL, Salo JA. Simultaneous progression of oxidative stress and angiogenesis in malignant transformation of Barrett esophagus. *J Thorac Cardiovasc Surg.* 126: 1952-1957, 2003.
255. Hermann B, Li Y, Ray MB, Wo JM, Martin RC, 2nd. Association of manganese superoxide dismutase expression with progression of carcinogenesis in Barrett esophagus. *Arch Surg.* 140: 1204-1209, 2005.
256. Jimenez P, Piazuelo E, Sanchez MT, Ortego J, Soteras F, Lanás A. Free radicals and antioxidant systems in reflux esophagitis and Barrett's esophagus. *World J Gastroenterol.* 11: 2697-2703, 2005.
257. Rantanen TK, Rasanen JV, Sihvo EI, Ahotupa MO, Farkkila MA, Salo JA. The impact of antireflux surgery on oxidative stress of esophageal mucosa caused by gastroesophageal reflux disease: 4-yr follow-up study. *Am J Gastroenterol.* 101: 222-228, 2006.
258. Rocks N, Paulissen G, El Hour M, Quesada F, Crahay C, Gueders M, Foidart JM, Noel A, Cataldo D. Emerging roles of ADAM and ADAMTS metalloproteinases in cancer. *Biochimie.* 90: 369-379, 2008.
259. Mochizuki S, Okada Y. ADAMs in cancer cell proliferation and progression. *Cancer Sci.* 98: 621-628, 2007.
260. Duffy MJ, McKiernan E, O'Donovan N, McGowan PM. Role of ADAMs in cancer formation and progression. *Clin Cancer Res.* 15: 1140-1144, 2009.
261. Darlavoix T, Seelentag W, Yan P, Bachmann A, Bosman FT. Altered expression of CD44 and DKK1 in the progression of Barrett's esophagus to esophageal adenocarcinoma. *Virchows Arch.* 454: 629-637, 2009.

262. Tselepis C, Perry I, Dawson C, Hardy R, Darnton SJ, McConkey C, Stuart RC, Wright N, Harrison R, Jankowski JA. Tumour necrosis factor-alpha in Barrett's oesophagus: a potential novel mechanism of action. *Oncogene*. 21: 6071-6081, 2002.
263. von Rahden BH, Stein HJ, Feith M, Puhlinger F, Theisen J, Siewert JR, Sarbia M. Overexpression of TGF-beta1 in esophageal (Barrett's) adenocarcinoma is associated with advanced stage of disease and poor prognosis. *Mol Carcinog*. 45: 786-794, 2006.
264. Sung SY, Kubo H, Shigemura K, Arnold RS, Logani S, Wang R, Konaka H, Nakagawa M, Mousses S, Amin M, Anderson C, Johnstone P, Petros JA, Marshall FF, Zhou HE, Chung LW. Oxidative stress induces ADAM9 protein expression in human prostate cancer cells. *Cancer Res*. 66: 9519-9526, 2006.
265. Mongaret C, Alexandre J, Thomas-Schoemann A, Bermudez E, Chereau C, Nicco C, Goldwasser F, Weill B, Batteux F, Lemare F. Tumor invasion induced by oxidative stress is dependent on membrane ADAM 9 protein and its secreted form. *Int J Cancer*. 129: 791-798, 2011.
266. Lendeckel U, Kohl J, Arndt M, Carl-McGrath S, Donat H, Rocken C. Increased expression of ADAM family members in human breast cancer and breast cancer cell lines. *J Cancer Res Clin Oncol*. 131: 41-48, 2005.
267. Yoshimura T, Tomita T, Dixon MF, Axon AT, Robinson PA, Crabtree JE. ADAMs (a disintegrin and metalloproteinase) messenger RNA expression in *Helicobacter pylori*-infected, normal, and neoplastic gastric mucosa. *J Infect Dis*. 185: 332-340, 2002.
268. Wang YY, Ye ZY, Li L, Zhao ZS, Shao QS, Tao HQ. ADAM 10 is associated with gastric cancer progression and prognosis of patients. *J Surg Oncol*. 103: 116-123, 2011.
269. Zhang J, Qi J, Chen N, Fu W, Zhou B, He A. High expression of a disintegrin and metalloproteinase-9 predicts a shortened survival time in completely resected stage I non-small cell lung cancer. *Oncol Lett*. 5: 1461-1466, 2013.
270. McGowan PM, McKiernan E, Bolster F, Ryan BM, Hill AD, McDermott EW, Evoy D, O'Higgins N, Crown J, Duffy MJ. ADAM-17 predicts adverse outcome in patients with breast cancer. *Ann Oncol*. 19: 1075-1081, 2008.
271. McGowan PM, Mullooly M, Caiazza F, Sukor S, Madden SF, Maguire AA, Pierce A, McDermott EW, Crown J, O'Donovan N, Duffy MJ. ADAM-17: a novel therapeutic target for triple negative breast cancer. *Ann Oncol*. 24: 362-369, 2013.
272. Jovov B, Que J, Tobey NA, Djukic Z, Hogan BL, Orlando RC. Role of E-cadherin in the pathogenesis of gastroesophageal reflux disease. *Am J Gastroenterol*. 106: 1039-1047, 2011.
273. Nesbit CE, Tersak JM, Prochownik EV. MYC oncogenes and human neoplastic disease. *Oncogene*. 18: 3004-3016, 1999.
274. Schmidt MK, Meurer L, Volkweis BS, Edelweiss MI, Schirmer CC, Krueel CD, Gurski RR. c-Myc overexpression is strongly associated with metaplasia-dysplasia-adenocarcinoma sequence in the esophagus. *Dis Esophagus*. 20: 212-216, 2007.
275. Tselepis C, Morris CD, Wakelin D, Hardy R, Perry I, Luong QT, Harper E, Harrison R, Attwood SE, Jankowski JA. Upregulation of the oncogene c-myc in Barrett's adenocarcinoma: induction of c-myc by acidified bile acid in vitro. *Gut*. 52: 174-180, 2003.
276. Vafa O, Wade M, Kern S, Beeche M, Pandita TK, Hampton GM, Wahl GM. c-Myc can induce DNA damage, increase reactive oxygen species, and mitigate p53 function: a mechanism for oncogene-induced genetic instability. *Mol Cell*. 9: 1031-1044, 2002.
277. Khanna A, Bockelman C, Hemmes A, Junttila MR, Wiksten JP, Lundin M, Junnila S, Murphy DJ, Evan GI, Haglund C, Westermarck J, Ristimaki A. MYC-dependent regulation and prognostic role of CIP2A in gastric cancer. *J Natl Cancer Inst*. 101: 793-805, 2009.

278. De P, Carlson J, Leyland-Jones B, Dey N. Oncogenic nexus of cancerous inhibitor of protein phosphatase 2A (CIP2A): an oncoprotein with many hands. *Oncotarget*. 5: 4581-4602, 2014.
279. Come C, Laine A, Chanrion M, Edgren H, Mattila E, Liu X, Jonkers J, Ivaska J, Isola J, Darbon JM, Kallioniemi O, Thezenas S, Westermarck J. CIP2A is associated with human breast cancer aggressivity. *Clin Cancer Res*. 15: 5092-5100, 2009.
280. Laihia JK, Jansen CT, Ahotupa M. Lucigenin and linoleate enhanced chemiluminescent assay for superoxide dismutase activity. *Free Radic Biol Med*. 14: 457-461, 1993.
281. Saville B. A scheme for the colorimetric determination of microgram amounts of thiols. *Analyst*. 83: 670-672, 1958.
282. Suzuki K, Ota H, Sasagawa S, Sakatani T, Fujikura T. Assay method for myeloperoxidase in human polymorphonuclear leukocytes. *Anal Biochem*. 132: 345-352, 1983.
283. Ng M, Freeman MK, Fleming TD, Robinson M, Dwyer-Lindgren L, Thomson B, Wollum A, Sanman E, Wulf S, Lopez AD, Murray CJ, Gakidou E. Smoking prevalence and cigarette consumption in 187 countries, 1980-2012. *JAMA*. 311: 183-192, 2014.
284. Yatsuya H, Li Y, Hilawe EH, Ota A, Wang C, Chiang C, Zhang Y, Uemura M, Osako A, Ozaki Y, Aoyama A. Global trend in overweight and obesity and its association with cardiovascular disease incidence. *Circ J*. 78: 2807-2818, 2014.
285. Damhofer H, Veenstra VL, Tol JA, van Laarhoven HW, Medema JP, Bijlsma MF. Blocking Hedgehog release from pancreatic cancer cells increases paracrine signaling potency. *J Cell Sci*. 128: 129-139, 2015.
286. Liu R, Gu J, Jiang P, Zheng Y, Liu X, Jiang X, Huang E, Xiong S, Xu F, Liu G, Ge D, Chu Y. DNMT1-microRNA126 epigenetic circuit contributes to esophageal squamous cell carcinoma growth via ADAM9-EGFR-AKT signaling. *Clin Cancer Res*. 21: 854-863, 2015.
287. Mazzocca A, Coppari R, De Franco R, Cho JY, Libermann TA, Pinzani M, Toker A. A secreted form of ADAM9 promotes carcinoma invasion through tumor-stromal interactions. *Cancer Res*. 65: 4728-4738, 2005.
288. Shintani Y, Higashiyama S, Ohta M, Hirabayashi H, Yamamoto S, Yoshimasu T, Matsuda H, Matsuura N. Overexpression of ADAM9 in non-small cell lung cancer correlates with brain metastasis. *Cancer Res*. 64: 4190-4196, 2004.
289. Kim JM, Jeung HC, Rha SY, Yu EJ, Kim TS, Shin YK, Zhang X, Park KH, Park SW, Chung HC, Powis G. The effect of disintegrin-metalloproteinase ADAM9 in gastric cancer progression. *Mol Cancer Ther*. 13: 3074-3085, 2014.
290. Grutzmann R, Luttes J, Sipos B, Ammerpohl O, Dobrowolski F, Alldinger I, Kersting S, Ockert D, Koch R, Kalthoff H, Schackert HK, Saeger HD, Kloppel G, Pilarsky C. ADAM9 expression in pancreatic cancer is associated with tumour type and is a prognostic factor in ductal adenocarcinoma. *Br J Cancer*. 90: 1053-1058, 2004.
291. Jia AY, Castillo-Martin M, Bonal DM, Sanchez-Carbayo M, Silva JM, Cordon-Cardo C. MicroRNA-126 inhibits invasion in bladder cancer via regulation of ADAM9. *Br J Cancer*. 110: 2945-2954, 2014.
292. Ebbing EA, Medema JP, Damhofer H, Meijer SL, Krishnadath KK, van Berge Henegouwen MI, Bijlsma MF, van Laarhoven HW. ADAM10-mediated release of heregulin confers resistance to trastuzumab by activating HER3. *Oncotarget*. 7: 10243-10254, 2016.
293. Liu HB, Zhu Y, Yang QC, Shen Y, Zhang XJ, Chen H. Expression and clinical significance of ADAM17 protein in esophageal squamous cell carcinoma. *Genet Mol Res*. 14: 4391-4398, 2015.

294. Franze E, Caruso R, Stolfi C, Sarra M, Cupi ML, Ascolani M, Sedda S, Antenucci C, Ruffa A, Caprioli F, MacDonald TT, Pallone F, Monteleone G. High expression of the "A Disintegrin And Metalloprotease" 19 (ADAM19), a sheddase for TNF-alpha in the mucosa of patients with inflammatory bowel diseases. *Inflamm Bowel Dis.* 19: 501-511, 2013.
295. Kerna I, Kisand K, Suutre S, Murde M, Tamm A, Kumm J, Tamm A. The ADAM12 is upregulated in synovitis and postinflammatory fibrosis of the synovial membrane in patients with early radiographic osteoarthritis. *Joint Bone Spine.* 81: 51-56, 2014.
296. Zhang J, Qin X, Sun Q, Guo H, Wu X, Xie F, Xu Q, Yan M, Liu J, Han Z, Chen W. Transcriptional control of PAX4-regulated miR-144/451 modulates metastasis by suppressing ADAMs expression. *Oncogene.* 34: 3283-3295, 2015.
297. Zhang Q, Yu L, Qin D, Huang R, Jiang X, Zou C, Tang Q, Chen Y, Wang G, Wang X, Gao X. Role of microRNA-30c targeting ADAM19 in colorectal cancer. *PLoS One.* 10: e0120698, 2015.
298. Khanna A, Pimanda JE, Westermarck J. Cancerous inhibitor of protein phosphatase 2A, an emerging human oncoprotein and a potential cancer therapy target. *Cancer Res.* 73: 6548-6553, 2013.
299. Abdel-Latif MM, Kelleher D, Reynolds JV. Molecular mechanisms of constitutive and inducible NF-kappaB activation in oesophageal adenocarcinoma. *Eur J Cancer.* 51: 464-472, 2015.
300. Evangelou K, Kotsinas A, Mariolis-Sapsakos T, Giannopoulos A, Tsantoulis PK, Constantinides C, Troupis TG, Salmas M, Kyroudis A, Kittas C, Gorgoulis VG. E2F-1 overexpression correlates with decreased proliferation and better prognosis in adenocarcinomas of Barrett oesophagus. *J Clin Pathol.* 61: 601-605, 2008.
301. Prasad GA, Wang KK, Halling KC, Buttar NS, Wongkeesong LM, Zinsmeister AR, Brankley SM, Westra WM, Lutzke LS, Borkenhagen LS, Dunagan K. Correlation of histology with biomarker status after photodynamic therapy in Barrett esophagus. *Cancer.* 113: 470-476, 2008.
302. Kusano M, Hosaka H, Kawamura O, Kawada A, Kuribayashi S, Shimoyama Y, Yasuoka H, Mizuide M, Tomizawa T, Sagawa T, Sato K, Yamada M. More severe upper gastrointestinal symptoms associated with non-erosive reflux disease than with erosive gastroesophageal reflux disease during maintenance proton pump inhibitor therapy. *J Gastroenterol.* 50: 298-304, 2015.
303. Lassen A, Hallas J, de Muckadell OB. Esophagitis: incidence and risk of esophageal adenocarcinoma—a population-based cohort study. *Am J Gastroenterol.* 101: 1193-1199, 2006.
304. Erichsen R, Robertson D, Farkas DK, Pedersen L, Pohl H, Baron JA, Sorensen HT. Erosive reflux disease increases risk for esophageal adenocarcinoma, compared with nonerosive reflux. *Clin Gastroenterol Hepatol.* 10: 475-480, 2012.
305. Ronkainen J, Talley NJ, Storskrubb T, Johansson SE, Lind T, Vieth M, Agreus L, Aro P. Erosive esophagitis is a risk factor for Barrett's esophagus: a community-based endoscopic follow-up study. *Am J Gastroenterol.* 106: 1946-1952, 2011.
306. Cijis TM, Verhoef C, Steyerberg EW, Koppert LB, Tran TC, Wijnhoven BP, Tilanus HW, de Jonge J. Outcome of esophagectomy for cancer in elderly patients. *Ann Thorac Surg.* 90: 900-907, 2010.
307. Wetscher GJ, Schwelberger H, Unger A, Offner FA, Profanter C, Glaser K, Klingler A, Gadenstaetter M, Klinger P. Reflux-induced apoptosis of the esophageal mucosa is inhibited in Barrett's epithelium. *Am J Surg.* 176: 569-573, 1998.
308. Rantanen T, Oksala N, Honkanen T, Rasanen J, Sihvo E, Mattila J, Paimela H, Paavonen T, Salo J. The effect of fundoplication on proliferative and anti-apoptotic activity of esophageal mucosa in gastroesophageal reflux disease: 4-year follow-up study. *J Dig Dis.* 12: 263-271, 2011.

309. Rasanen JV, Sihvo EI, Rantanen TK, Ahotupa MO, Farkkila MA, Harjula A, Salo JA. Gastroesophageal reflux patients' defective antioxidative capacity in the proximal esophageal mucosa before antireflux surgery and also after 4-year follow-up. *Ann Med.* 40: 74-80, 2008.
310. Gupta R, Kochhar G, Kumar A, Saha S, Andley M, Pusuluri R, Saurabh G, Kumar A. Evaluation of gastroesophageal reflux after laparoscopic cholecystectomy using combined impedance-pH monitoring. *Trop Gastroenterol.* 35: 222-226, 2014.
311. Lin OS, Kozarek RA, Arai A, Gan SI, Gluck M, Jiranek GC, Kowdley KV, Triadafilopoulos G. The association between cholecystectomy and gastroesophageal reflux symptoms: a prospective controlled study. *Ann Surg.* 251: 40-45, 2010.
312. Piazuolo E, Cebrian C, Escartin A, Jimenez P, Soteras F, Ortego J, Lanas A. Superoxide dismutase prevents development of adenocarcinoma in a rat model of Barrett's esophagus. *World J Gastroenterol.* 11: 7436-7443, 2005.
313. Thanan R, Ma N, Iijima K, Abe Y, Koike T, Shimosegawa T, Pinlaor S, Hiraku Y, Oikawa S, Murata M, Kawanishi S. Proton pump inhibitors suppress iNOS-dependent DNA damage in Barrett's esophagus by increasing Mn-SOD expression. *Biochem Biophys Res Commun.* 421: 280-285, 2012.

Original publications