

# Acute necrotizing pancreatitis treatment: Endoscopic sphincterotomy and minimal invasive step-up approach of liver hydatid cysts

✉ Murat Akaydin,<sup>1</sup> ✉ Tamer Akay,<sup>2</sup> ✉ Okan Demiray<sup>3</sup>

<sup>1</sup>Department of General Surgery, Academic Hospital, Istanbul, Turkey

<sup>2</sup>Department of General Surgery, Bandırma State Hospital, Balıkesir, Turkey

<sup>3</sup>Department of General Surgery, Health Sciences University Gaziosmanpaşa Taksim Training and Research Hospital, Istanbul, Turkey

## ABSTRACT

**Introduction:** Hydatid disease is a zoonosis that generally arises from echinococcus granulosus. Abdominal pain, cholangitis and jaundice may develop as a result of spontaneous rupture of the liver cyst into the biliary tract. Rarely, in some of these cases, pancreatitis may develop as a complication of hydatid cysts and there is no clear consensus on treatment options in patients with diffuse bile duct obstruction that occurs with a necrotizing pancreatitis clinic. The present study aims to establish a common consensus in patients presenting with liver cyst hydatid pancreatitis and jaundice clinic.

**Materials and Methods:** In a retrospective, clinical-based multicenter study, ERCP and minimally invasive approaches are presented in the treatment of four patients who developed liver bile duct obstruction and necrotizing pancreatitis from the liver hydatid cyst.

**Results:** All patients had abdominal pain and jaundice. Acute pancreatitis was detected in all cases using computed tomography. All patients underwent endoscopic sphincterotomy. Infected cystic material and germinal membranes were removed from the biliary tract. With endoscopic sphincterotomy, necrotizing pancreatitis clinic improved rapidly in three patients, while one patient progressed to necrotizing pancreatitis. All patients underwent laparoscopic cystectomy and cholecystectomy in combination. In patients who were followed up for necrotizing pancreatitis, the wall formation (encapsulation) period of necrosis was waited, and four weeks later, percutaneous drainage was applied to the walled necrosis areas. While the patients were discharged, Andazol® treatment was applied during the 6-month follow-up period.

**Conclusion:** One of the complications of ERCP is that it may increase the severity of pancreatitis. However, ERCP is the most important endoscopic intervention for the treatment of pancreatitis filled with common bile duct hydatid cyst to ensure safe and effective biliary tract drainage in the early period. In addition, percutaneous drainage provides safe and rapid recovery in necrotizing pancreatitis complications when the wall of necrosis phenomenon is expected.

**Keywords:** Acute pancreatitis; biliary rupture; endoscopic retrograde cholangiopancreatography (ERCP); hydatid cyst; percutaneous drainage.

## Introduction

Hydatid disease is a zoonosis that is caused generally by echinococcus granulosus or, rarely echinococcus multilocularis. In the human body, it is mostly localized in the

liver as intermediary carrier.<sup>[1]</sup> Development of these cystic lesions in the liver causes pressure on adjacent tissues and bile ducts and results in spontaneous rupture of the cyst into the biliary tract. Germinal membrane fragments



Received: 27.04.2020 Accepted: 30.05.2020

Correspondence: Tamer Akay, M.D., Department of General Surgery, Bandırma State Hospital, Balıkesir, Turkey

e-mail: op.dr.tamerakay@gmail.com



This work is licensed under a Creative Commons Attribution-NonCommercial 4.0 International License.

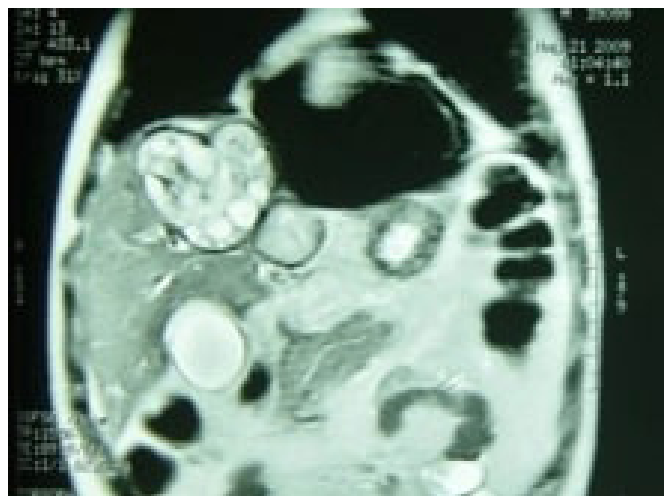
and scolices then obstruct bile ducts and complaints associated with this situation may lead to the initial diagnosis of the disease. The most important complaint is jaundice besides abdominal pain and fever related to cholangitis. Rarely in some of these cases, as a complication of hydatid diseases, germinal membrane fragments, scolices and daughter cysts obstruct distal part of the common bile duct and/or the pancreatic duct and result in pancreatitis. Acute hydatid pancreatitis is a rare complication of hydatid liver disease. Current literature information reports that acute pancreatitis usually occurs as edematous pancreatitis in hydatid cyst but necrotizing pancreatitis is rarely seen.<sup>[2]</sup>

In endemic countries, hydatid liver disease is considered an etiological factor for acute pancreatitis, and there is no clear consensus on treatment options in patients with a common bile duct obstruction, presenting with a necrotizing pancreatitis clinic.

### Materials and Methods

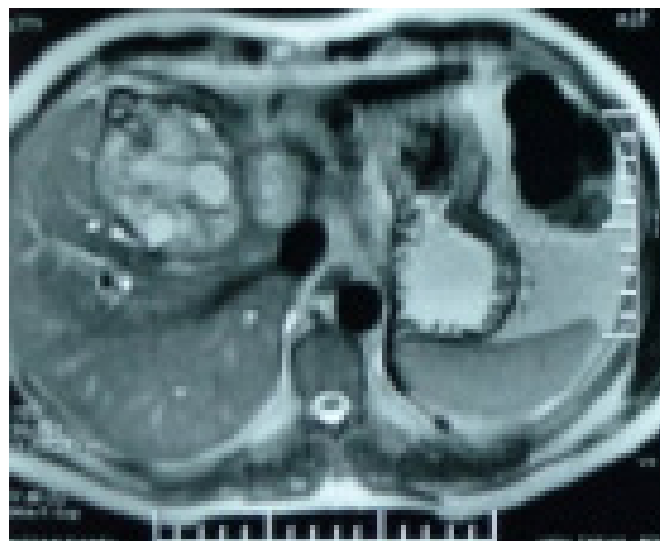
Over the past 10 years, 70 endoscopic retrograde cholangiopancreatography (ERCP) procedures have been performed to treat complications of liver hydatid cysts with ERCP. In 4 of these patients, hydatid necrotizing pancreatitis was detected as a result of hydatid cyst. All of the patients were male and the mean age was 39.25 (31–48 years). These patients were admitted due to common bile duct obstruction. All had abdominal pain and jaundice.

After performing the necessary imaging tests (USG, CT, MRI), endoscopic sphincterotomy was applied to the patients. Magnetic resonance imaging (MRI) in Figure 1

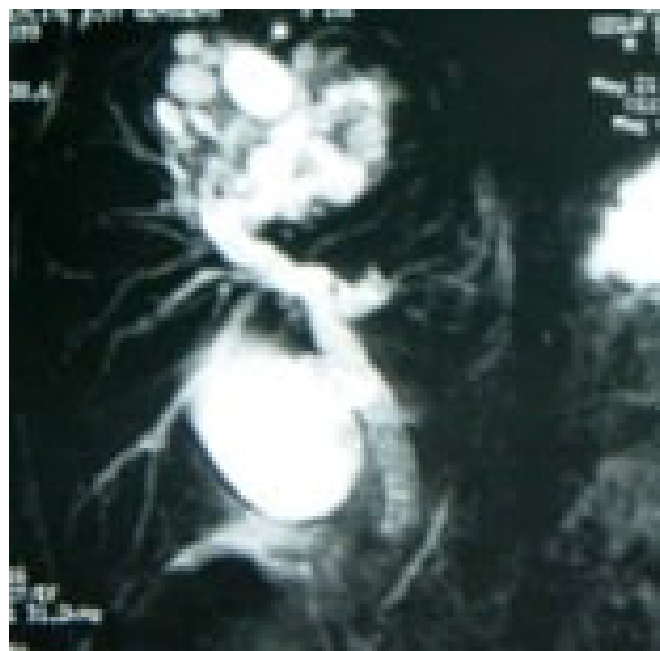

**Figure 1.** Magnetic resonance imaging (MRI) shows the liver cyst hydatid content in coronal section.

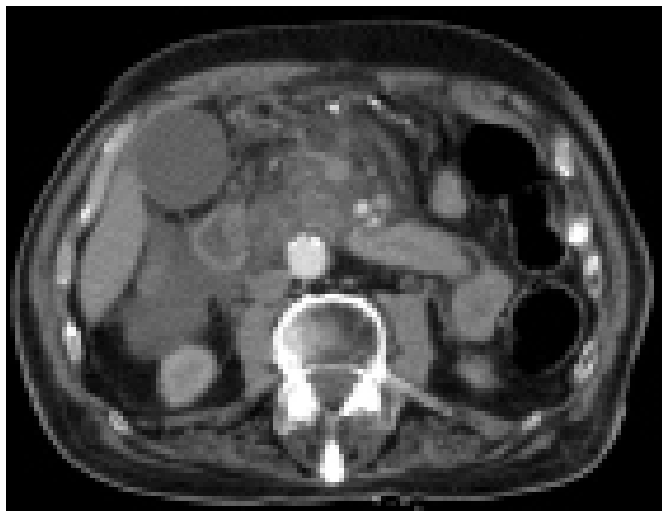shows the liver cyst hydatid content in coronal section and Figure 2 in axial section. Figure 3 shows the rupture of cyst contents into the biliary tract in magnetic resonance cholangiopancreatography (MRCP) image. Acute necrotizing pancreatitis was detected with ultrasonography (USG) and computed tomography (CT) in 3 cases, and necrotizing pancreatitis (developing after ERCP) in one patient after acute edematous pancreatitis. In Figure 4, an effusion extending from the peripancreatic area to the right perirenal fascia due to necrotizing pancreatitis was detected.



**Figure 2.** Magnetic resonance imaging (MRI) shows the liver cyst hydatid content in axial section.



**Figure 3.** Magnetic resonance cholangiopancreatography (MRCP) shows the rupture of cyst contents into the biliary tract.



**Figure 4.** An effusion extending from the peripancreatic area to the right perirenal fascia due to necrotizing pancreatitis was detected.

When all patients are diagnosed Andazol® (Albendazole to, Biofarma, Istanbul, Turkey) medical treatment (400 mg BID) was initiated. Patients underwent laparoscopic cystectomy after the necrotizing pancreatitis clinic subsided. Intraabdominal necrosis areas were not intervened before 4 weeks. Minimally invasive methods such as percutaneous drainage were applied after encapsulated areas were encapsulated.

Written consent was obtained from all patients with ERCP. The entire protocol was made with the approval of the local ethics committee.

## Results

In two patients, the fever was over 39 °C. Acute necrotizing pancreatitis developed in three patients before ERCP and one patient after sphincterotomy. Clinical features of the patients are shown in Table 1 and laboratory results before ERCP are shown in Table 2. All patients had high levels of liver function tests, alkaline phosphatase, serum amylase and total/direct bilirubin. Only two patients had leukocytosis.

All patients underwent ES (endoscopic sphincterotomy). Infected cystic material and membranes were removed from the biliary tract. Figure 5 shows the hydatid cysts in the choledocus in the ERCP procedure. Figure 6 shows hydatid germinative membranes of the cyst drained after papillotomy. The bile duct was between 7 and 21 millimeters in diameter. None of the patients had biliary drainage catheter placement after ES and choledochal drainage. Figure 7 shows the post-operative hydatid cyst material. No patients had ERCP-related mortality.

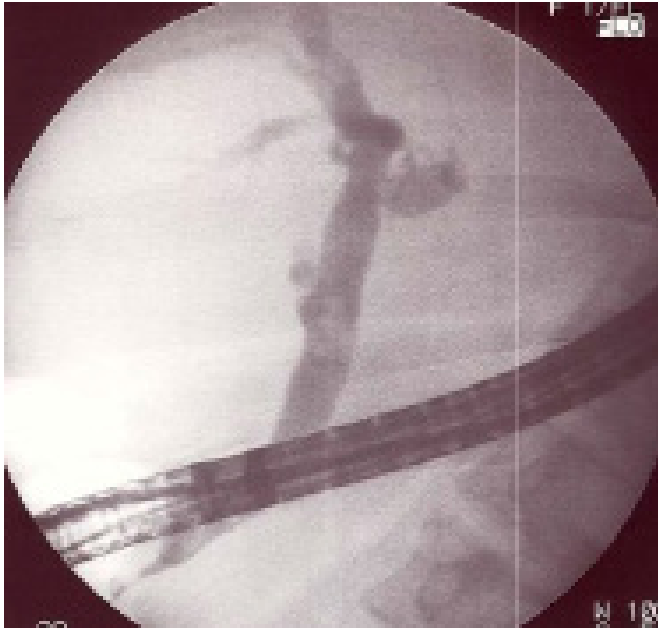After the necrotizing pancreatitis clinic regressed (followed

**Table 1. Clinical characteristics of the patients**

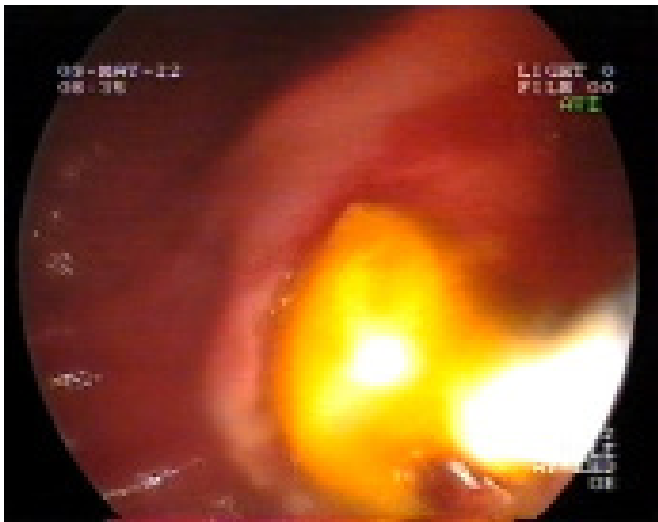
Patient	Time of pancreatitis	Gender	Age	Complaint	Duration	Cyst localization
1	Pre-ERCP period	Male	31	Jaundice, abdominal pain	34 days	Left liver lobe
2	Pre-ERCP period	Male	47	Jaundice, abdominal pain, fever	45 days	Right liver lobe
3	Pre-ERCP period	Male	48	Jaundice, abdominal pain	30 days	Both left and right lobes
4	Post-ERCP period	Male	31	Jaundice, abdominal pain, fever	55 days	Right liver lobe

**Table 2. Laboratory results of the patients**

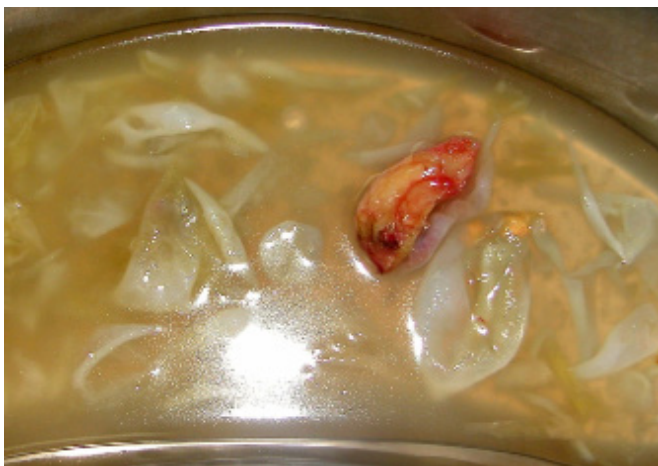Patient	WBC (K/uL)	AST (U/L)	ALT (U/L)	GGT (U/L)	AF (U/L)	Amylase (U/L)	Total bilirubin (mg/dL)	Direct bilirubin (mg/dL)
1	15000	357	335	459	369	2240	3.5	2.8
2	25000	184	353	430	302	1040	12.91	7.76
3	8050	107	148	305	549	646	4.85	2.51
4	9110	399	414	303	1079	622	4.00	2.16



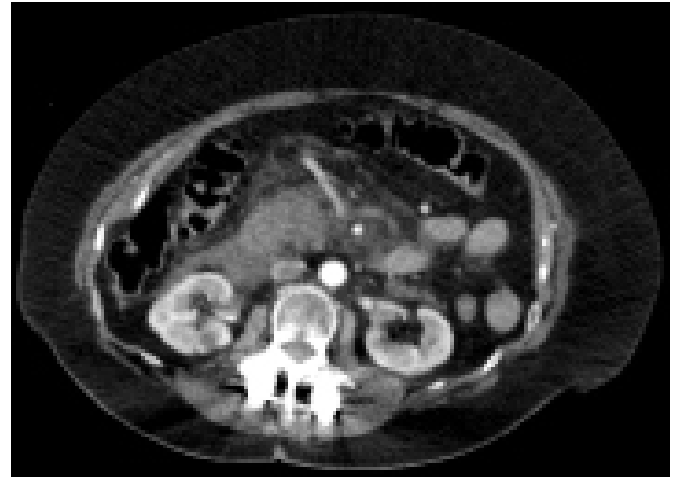
**Figure 5.** Cholangiography shows the hydatid cysts in the choledocus in the ERCP procedure.



**Figure 6.** The outflow of cyst hydatid germinative membranes drained after endoscopic sphincterotomy is demonstrated.



**Figure 7.** Postoperative hydatid cyst material is shown.



**Figure 8.** Percutaneous drainage catheter is selected for necrosis in the peripancreatic area.

by c reactive protein), laparoscopic cholecystectomy and cystectomy and omentopexy were performed for liver cysts. In patients who were followed up for necrotizing pancreatitis, the encapsulation time of necrosis was expected, and after 4 weeks percutaneous drainage was applied to these necrosis sites. In Figure 8, percutaneous drainage catheter is selected for necrosis in the peripancreatic area. While the patients were discharged, Andazol® treatment was applied during the 6-month follow-up period. There was no recurrence at the end of the six-month follow-up period.

## Discussion

Hydatid disease is a zoonosis that is caused generally by *Echinococcus granulosus* or, rarely *Echinococcus multilocularis* and prevalent in the Mediterranean basin, South America, North Africa, Middle Asia, and East Europe.<sup>[3]</sup> *E. granulosus* is a small tapeworm living in the small intestine of the dogs as definite hosts. Eggs of the parasite are passed in the feces and by swallowing ova of the parasite with unwashed and uncooked vegetables or by direct contact with infected dogs they settle down in small intestines of humans (intermediate carriers). Then the embryo is released and carried to the liver by portal circulation. The parasite chooses mammals like sheep, human and cows as intermediate carriers. Hydatid cysts grow in the organs affected. An outer laminated membrane and an inner germinal membrane develop over several months. Inside the cyst brood capsules containing protoscolices develop from the germinal membrane and when they are ingested by definitive hosts, they develop into the adult tapeworm.<sup>[4]</sup> Our country is among the endemic countries for cyst hydatid disease, and there are many cyst hydatid studies on behalf of our country in the literature.

The cysts may rupture into the peritoneal or thoracic cavity and cause anaphylactic shock or give rise to many other new cysts.<sup>[5]</sup> Liver is the most common site of hydatid cysts in human body (60–75%).<sup>[6]</sup> Less frequently they can be seen in the lungs (18–35%) and very rarely in the spleen, kidneys, brain, muscles, bone and pancreas. In our study, the cyst hydatid localizations of the patients we treated for hydatid disease are in the liver. In addition, the localization of hydatid cysts to the common bile duct, which is rarely seen, is included in our study.

Complaints of the patients are mainly related to the pressure of the growing cyst on adjacent tissues or organs.<sup>[7]</sup> As a result of complications associated with the specific organs, the cysts become symptomatic. Main symptom of the hydatid liver disease is pain associated with the pressure of the growing cyst. 5–17% of the hydatid liver cysts may rupture into the biliary tract spontaneously<sup>[8]</sup> resulting in jaundice, abdominal pain, fever, cholangitis and cyst abscess.<sup>[9]</sup> After rupture into the bile ducts, clinical situation mimics choledocholithiasis and cholangitis.<sup>[10]</sup> Patients in our study applied with the complaints of jaundice and abdominal pain, and two patients had high fever.

While hydatid pancreatitis may be the reason of first admission of the patient without a history of liver hydatid cysts to the hospital, it may also occur postoperatively.<sup>[11]</sup> It is more common where the hydatid disease is endemic. In the postoperative period of the patients with hydatid cyst ruptured into the biliary tract, bile leakage into the former cystic cavity is established quite often. Obstruction of the bile ducts with hydatid material may result in pancreatitis. Alternatively, some authors suggest that discharge of the infected material from the cyst into the bile duct may cause transient obstruction at the ampulla of Vater associated with allergic or inflammatory response and may lead to acute pancreatitis.<sup>[12]</sup> In our study, acute necrotizing pancreatitis developed in three patients before ERCP and one patient after sphincterotomy.

USG and CT are commonly used for the diagnosis of hydatid liver disease and serologic tests give information about the activity of cystic material.<sup>[13,14]</sup> MRI is also helpful in evaluation of the location and structures of the hydatid cyst. Before the common use of MRCP, ERCP has been shown to be the most efficient method rather than USG and CT in showing rupture into bile ducts.<sup>[15]</sup> MRCP is especially a very effective imaging modality in showing the width of bile ducts and hydatid materials inside.<sup>[16]</sup> In

patients presenting with jaundice and abdominal pain in our clinic, first of all, USG is performed, and then CT and MRI evaluation is performed upon detection of cystic lesion in the patient's liver (in case of suspected hydatid cyst), and ERCP procedure is performed in the common bile duct obstruction.

Although serology is reliable in confirming the diagnosis of hydatid cyst, a negative serological result does not exclude the diagnosis. In acute hydatid pancreatitis, laboratory tests mostly reveal marked increase in the serum concentrations of amylase and lipase.<sup>[17]</sup> In many sporadic cases, USG and CT scan evidenced acute edematous pancreatitis and it was reported that after the drainage of bile ducts with ES, pancreatitis resolved rapidly.<sup>[18]</sup> In our study, pancreatitis clinics regressed with ERCP in three of the patients, while ERCP related pancreatitis occurred in one patient, and treatment was planned according to the patient's clinic, not serological examinations.

Surgical treatment of the uncomplicated hydatid liver disease is total excision, if possible.<sup>[19]</sup> However, therapeutic endoscopic interventions come up in the patients with complicated disease. Thanks to the common use of ES, preoperative (cholangitis) and postoperative (bile leaks) complications of the hydatid disease heal quickly.<sup>[20,21]</sup> In our study, cystectomy and omentopexy procedure with laparoscopic cholecystectomy was performed after the necrotizing pancreatitis clinic regressed.

In the patients with hydatid pancreatitis, cystic membranes, scolices and infected bile are drained from the choledochus with early ES. After removal of the hydatid material with this intervention, cholangitis and acute pancreatitis symptoms were reported to get better promptly.<sup>[12]</sup> In our study, apart from post-ERCP pancreatitis, patients' clinics regressed, but complications of necrotizing pancreatitis (such as pancreatic abscess) could not be prevented.

Conservative management is basis of treatment and results in success in most cases of acute pancreatitis. Most cases of acute pancreatitis are self-limited and resolve without serious complications. However, severe acute pancreatitis is associated with the development of potentially life-threatening complications including pancreatic necrosis and pancreatic abscess. Infected pancreatic necrosis is primary indication for surgical intervention, and the goal of successful therapy is to identify patients who progress to infected necrosis.<sup>[22]</sup> In the PANTER study conducted

in 2010 (2005–2008), a surgical set-up approach for infected necrotizing pancreatitis reduced mortality or major complications compared to open necrosectomy; It was revealed that 35% of patients were successfully treated with only simple catheter drainage.<sup>[23]</sup> In our study, patients with necrotizing pancreatitis were treated only with percutaneous drainage and no recurrence was detected in their follow-up.

There is no general consensus on the duration of antiparasite treatments. The World Health Organization recommends the postoperative administration of albendazole for at least 1 month but the risk of peritoneal recurrences determines the continuation of the treatment; the longest period described in the literature was of 1 year.<sup>[24]</sup> The patients in the study were followed up for albendazole during the post-operative 6-month period and no recurrence was detected after this period.

In conclusion, one of the complications of ERCP is that it can increase the severity of pancreatitis. Despite this, ERCP is the most important endoscopic intervention for pancreatitis treatment, filled with common bile duct hydatid material to ensure safe and effective biliary tract drainage in the early period. In necrotizing pancreatitis, percutaneous drainage is important to ensure safe and rapid healing as a minimally invasive method when the encapsulation time of infected necrosis is complete.

## Disclosures

**Peer-review:** Externally peer-reviewed.

**Conflict of Interest:** None declared.

**Authorship Contributions:** Concept – M.A.; Design – O.D.; Supervision – T.A.; Materials – O.D.; Data collection and/or processing – M.A.; Analysis and/or interpretation – O.D.; Literature search – T.A.; Writing – T.A.; Critical review – M.A.

## References

- Bîrluțiu V, Bîrluțiu RM. The management of abdominal hydatidosis after the rupture of a pancreatic hydatid cyst: a case report. *J Med Case Rep* 2015;10:27. [\[CrossRef\]](#)
- Sıkar HE, Kaptanoğlu L, Kement M. An unusual appearance of complicated hydatid cyst: necrotizing pancreatitis. *Ulus Travma Acil Cerrahi Derg* 2017;23:81–3. [\[CrossRef\]](#)
- Katsinelos P, Chatzimavroudis G, Fasoulas K, Kamperis E, Katsinelos T, Terzoudis S, et al. Acute pancreatitis caused by impaction of hydatid membranes in the papilla of Vater: a case report. *Cases J* 2009;7:73–4.
- Al-Toma AA, Vermeijden RJ, Van De Wiel A. Acute pancreatitis complicating intrabiliary rupture of liver hydatid cyst. *Eur J Intern Med* 2004;15:65–7. [\[CrossRef\]](#)
- Kitchens WH, Liu C, Ryan ET, Castillo CF. Hepatic Hydatid Cyst: A Rare Cause of Recurrent Pancreatitis. *J Gastrointest Surg* 2014;18:2057–9. [\[CrossRef\]](#)
- Dziri C. Hydatid disease-continuing serious public health problem: introduction. *World J Surg* 2001;25:1–3. [\[CrossRef\]](#)
- Makni A, Jouini M, Kacem M, Safta ZB. Acute pancreatitis due to pancreatic hydatid cyst: a case report and review of the literature. *World Journal of Emergency Surgery* 2012;7:7.
- Erzurumlu K, Dervisoglu A, Polat C, Senyurek G, Yetim I, Hokelek M. Intrabiliary rupture: An algorithm in the treatment of controversial complication of hepatic hydatidosis *World J Gastroenterol* 2005;11:2472–6. [\[CrossRef\]](#)
- Cakir ÖÖ, Ataseven H, Demir A. Hydatid Acute Pancreatitis. *Türkiye Parazitoloj Derg* 2012;36:251–3. [\[CrossRef\]](#)
- Bilsel Y, Bulut T, Yamaner S, Buyukuncu Y, Bugra D, Akyuz A, et al. ERCP in the diagnosis and management of complications after surgery for hepatic echinococcosis. *Gastrointest Endosc* 2003;57:210–3. [\[CrossRef\]](#)
- Sáez-Royuela F, Yuguero L, López-Morante A, Pérez-Alvarez JC, Martín-Lorente JL, et al. Acute pancreatitis caused by hydatid membranes in the biliary tract: treatment with endoscopic sphincterotomy. *Gastrointest Endosc* 1999;49:793–6. [\[CrossRef\]](#)
- Wong LS, Braghioroli-Neto O, Xu M, Buckels JA, Mirza DF. Hydatid liver disease as a cause of recurrent pancreatitis. *J R Coll Surg Edinb* 1999;44:407–9.
- Galati G, Sterpetti AV, Caputo M, Adduci M, Lucandri G, et al. Endoscopic retrograde cholangiography for intrabiliary rupture of hydatid cyst. *Am J Surg* 2006;191:206–10. [\[CrossRef\]](#)
- Arifuddin R, Baichi M, Ulah A, Maliakkal B. Cystic echinococcus -A rare presentation of acute biliary obstruction and pancreatitis. *J Clin Gastroenterol* 2006;40:763–4. [\[CrossRef\]](#)
- Goumas K, Poulou A, Dandakis D, Tyrmpas I, Georgouli A, Sgourakis G, et al. Role of endoscopic intervention in biliary complications of hepatic hydatid cyst disease. *Scand J Gastroenterol* 2007;42:1113–9. [\[CrossRef\]](#)
- Kumar R, Reddy SN, Thulker S. Intrabiliary rupture of hydatid cyst: diagnosis with MRI and hepatobiliary isotope study. *Br J Radiol* 2002;75:271–4. [\[CrossRef\]](#)
- Suryawanshi P, Khan AQ, Jatal S. Primary hydatid cyst of pancreas with acute pancreatitis. *International Journal of Surgery Case Reports* 2011;2:122–4. [\[CrossRef\]](#)
- Zeytinlu M, Coker A, Yüzer Y, Ersöz G, Aydın A, Tekeşin O, et al. Hydatid acute pancreatitis. *Turk J Gastroenterol* 2004;15:229–32.
- Cicek B, Parlak E, Disibeyaz S, Oguz D, Cengiz C, et al. Endoscopic therapy of hepatic hydatid cyst disease in preoperative and postoperative settings. *Dig Dis Sci* 2007;52:931–5.
- Saritas U, Parlak E, Akoglu M, Sahin B. Effectiveness of endoscopic treatment modalities in complicated hepatic

- hydatid disease after surgical intervention. *Endoscopy* 2001;33:858–63. [\[CrossRef\]](#)
21. Emre A, Ozden I, Bilge O, Arici C, Alper A, Okten A, et al. Alveolar echinococcosis in Turkey. Experience from an endemic region. *Dig Surg* 2003;20:301–5. [\[CrossRef\]](#)
  22. Hollemans RA, Bollen TL, van Brunschot S, Bakker OJ, Ahmed Ali U, van Goor H, et al. Predicting Success of Catheter Drainage in Infected Necrotizing Pancreatitis. *Ann Surg* 2016;263:787–92. [\[CrossRef\]](#)
  23. Hollemans RA, Bakker OJ, Boermeester MA, Bollen TL, Bosscha K, Bruno MJ, et al. Superiority of Step-up Approach vs Open Necrosectomy in Long-term Follow-up of Patients With Necrotizing Pancreatitis. *Gastroenterology* 2019;156:1016–26.
  24. Juodeikis Z, Poskus T, Seinins D, Strupas K. Echinococcus multilocularis infection of the liver presenting as abdominal wall fistula. *BMJ Case Rep* 2014;2014:bcr2014203769.