

Intramedullary Screw Fixation for Midshaft Clavicle Fractures



Robert Thurston Bents, M.D., and Easton James Bents, B.S.

Abstract: Operative fixation for acute displaced midshaft clavicle fractures provides improved functional outcomes and patient satisfaction over nonoperative treatment. Although open reduction and plate fixation is most commonly used, intramedullary fixation produces similar patient outcomes with fewer symptomatic hardware or scar complications. The purpose of this Technical Note is to detail a straightforward and cost-efficient method of intramedullary clavicle fracture fixation using a headless cannulated screw.

The clavicle is the most frequently fractured bone in the body, with more than 80% of fractures occurring in the midshaft.¹ Minimally displaced fractures can be successfully managed nonoperatively, but there has been a recent trend toward operative fixation for displaced fractures.² A multicenter randomized controlled trial by the Canadian Orthopaedic Trauma Society showed that operative plate fixation of acute displaced clavicle fractures resulted in improved functional outcomes and lower rates of nonunion compared with nonoperative treatment.³

Operative fixation of displaced midshaft clavicle fractures is commonly performed with open reduction and plate fixation (PF).³ Although PF has been demonstrated to provide excellent immediate stability, there is a significant risk of complications, including hypertrophic or painful scars, skin numbness, brachial plexus injury, implant protrusion, and need for hardware removal.^{4,5}

Intramedullary (IM) fixation of midshaft clavicle fractures has been shown to provide similar long-term outcomes to PF in several studies.⁶⁻¹⁶ Early IM devices, however, were prone to migration or required second surgeries to remove the implant.¹⁷

Titanium elastic nail insertion is a challenging technique with a fairly high complication rate.¹⁸ Early descriptions of IM screw fixation used a posterolateral anterograde insertion point, which required significant radiation exposure and was technically demanding.^{19,20}

This Technical Note describes a minimally invasive fracture-site exposure with retrograde clavicle preparation and IM cannulated screw insertion. This simple and cost-effective method can be performed safely in an outpatient setting using a commonly available cannulated headless screw.

Surgical Technique (With Video Illustration)

Indications

Preoperative radiographic examination includes a standard anterior view of the clavicle and an upward angled cephalic view. Relative indications for acute IM clavicle fixation include healthy, active patients with midshaft vertical or short oblique fractures with more than 2 cm of shortening or displacement (Robinson classification 2B1). A typical midshaft short oblique fracture is depicted in [Figure 1](#). Fractures angulated over 30° are considered for fixation (Robinson 2A2). IM fixation is not used for comminuted or segmental fractures (Robinson 2B2), floating shoulders with concomitant glenoid neck fractures, or in patients with clavicles too small to accommodate IM.

Positioning

Following the induction of regional and general anesthetic, the patient is positioned in a modified beach-chair position with the back flexed approximately 30° ([Table 1](#)). The head is held by the secure holding device and slightly tilted away from the

From the Paragon Orthopedic Center, Grants Pass, Oregon, U.S.A.

Received August 26, 2023; accepted November 2, 2023.

Address correspondence to Robert Thurston Bents, M.D., Paragon Orthopedic Center, 702 S. W. Ramsey Ave., Suite #112, Grants Pass, Oregon, U.S.A. 97527. E-mail: bentsmd@mtashland.net

© 2023 THE AUTHORS. Published by Elsevier Inc. on behalf of the Arthroscopy Association of North America. This is an open access article under the CC BY-NC-ND license (<http://creativecommons.org/licenses/by-nc-nd/4.0/>).

2212-6287/231215

<https://doi.org/10.1016/j.eats.2023.11.012>

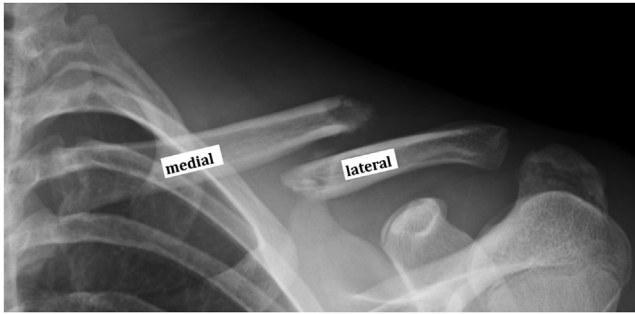


Fig 1. Preoperative 20° cephalic tilt radiograph of left clavicle showing a displaced short oblique midshaft clavicle fracture with 26 mm of shortening.

operative side. The entire posterior shoulder girdle should be free of metallic structures that would interfere with fluoroscopic imaging. Draping should allow exposure from the sternoclavicular joint to the posterolateral aspect of the shoulder well below the scapular spine (Fig 2). This will ensure adequate clearance for the posterior guidewire exit point.

The surgeon should coordinate positioning with the anesthesia team to ensure all lines and tubing are secured away from the posterior aspect of the shoulder to facilitate imaging. The radiology technologist should position the large C-arm unit on the contralateral side and place the collimator posterior and the image intensifier anterior to the patient (Video 1). It is imperative that images can be obtained in an anterior posterior (AP) or horizontal plane to check inferior/superior implant positioning (Fig 3A) and a vertical

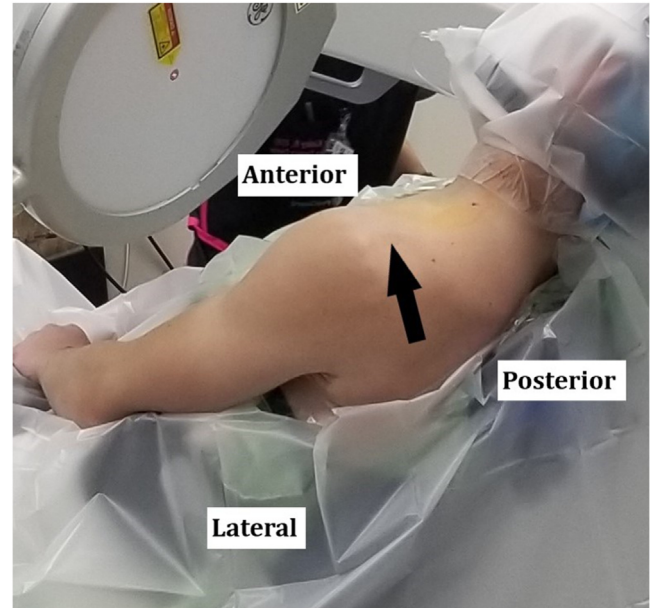


Fig 2. Intraoperative photograph of posterior left shoulder with the patient positioned in the beach-chair position. Draping should allow exposure from the sternum to well below the scapular spine to allow access to the posterior exit point of the guidewire (arrow).

caudal tilt view to visualize anterior/posterior positioning (Fig 3B).

Exposure

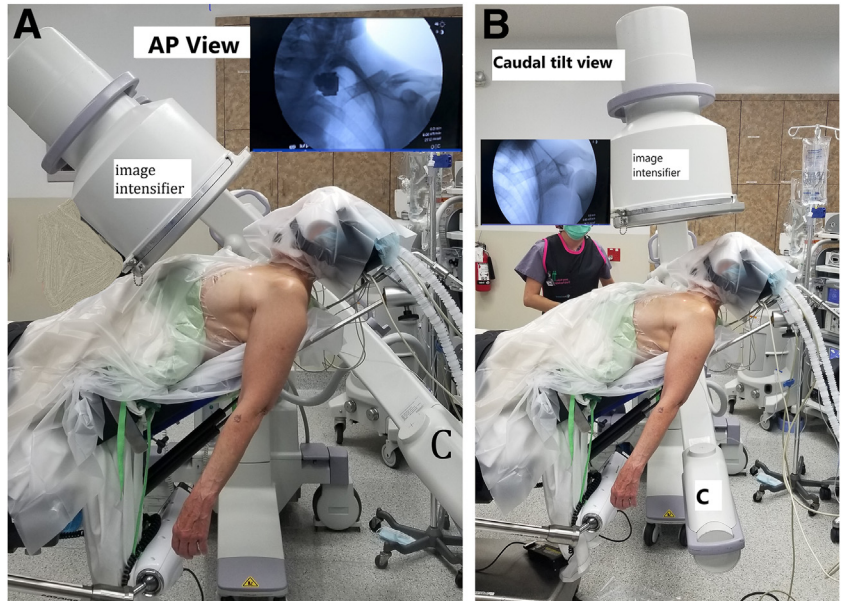
A 4-mm oblique incision is made in Langer's lines directly over the fracture site (Fig 4). The deltotracheal fascia is split and reflected in a single layer. The medial

Table 1. Steps, Pearls, and Pitfalls of Intramedullary Screw Fixation of Clavicle Fractures

Steps	Pearls	Pitfalls
Positioning	Modified beach-chair position Ensure draping allows full exposure	Confirm AP and caudal tilt views are attainable
Incision	3-5 cm incision in Langer's lines	Avoid supraclavicular nerves
Medial fragment preparation	Identify IM canal of medial clavicle Insert 1.6-mm gw into canal Advance 3.2-mm drill over gw Advance 4.5-mm tap over gw	Avoid aiming gw inferiorly Do not penetrate anterior cortex Use fluoroscopy to confirm gw direction
Lateral fragment preparation	Identify IM canal of lateral clavicle Advance gw out posterolateral clavicle Cannulated drill laterally over gw Advance tap laterally over gw Retract gw out to the lateral edge of fracture site	Use fluoroscopy Protect skin as gw exits posteriorly Drill and tap entire lateral IM canal Clamp gw outside lateral skin
Fracture reduction	Manually reduce fracture Advance gw across fracture site into previously drilled medial fragment canal	Use reduction forceps Use direct visualization and C-arm to confirm wire placement
Final preparation	Depth gauge from lateral side Countersink lateral cortex	Expect 85-95 mm length in female patients, 90-100 mm in male patients
Screw insertion	Insert 4.5-mm headless cannulated screw over gw, then remove gw	Check images to confirm depth of screw insertion
Closure	Close deltotracheal fascia and skin	Place shoulder immobilizer

AP, anteroposterior; gw, guidewire; IM, intramedullary.

Fig 3. External photograph of lateral left shoulder. (A) Anteroposterior fluoroscopic view (inset) is obtained by placing the image intensifier directly anterior to the chest wall and the collimator (C) posterior to the clavicle in a horizontal orientation. (B) Caudal tilt fluoroscopic view (inset) allows better visualization of the S-shape of the clavicle and is obtained by orienting the C-arm more vertically with the image intensifier more superior and the collimator (C) more inferior to the clavicle.



fragment of the clavicle is commonly displaced anterosuperior and easily located. Minimal soft-tissue stripping is needed to expose the IM canal at the fracture site. Lobster-claw reduction forceps are used to control the fragment and a blunt Hohmann retractor is

carefully placed under the clavicle to protect underlying structures.

Medial Fragment Preparation

The Synthes 4.5-mm Headless Compression Screw Set (DePuy Synthes, Warsaw, IN) is used for this technique. Once the IM canal has been identified, a 1.6-mm threaded guidewire is inserted in a retrograde fashion from medial to lateral using a battery powered drill (Fig 5A). The canal is more difficult to isolate in oblique fractures, and multiple fluoroscopic images are obtained to ensure guidewire orientation. The wire is inserted until resistance is felt at the anteromedial cortex, approximately 40 to 50 mm from the fracture site. The 3.2-mm cannulated drill is then inserted over the guidewire to the appropriate depth, again using AP and caudal tilt views to confirm position (Fig 5B). Care is taken to not penetrate the anterior clavicle cortex. The drill is removed and the 4.5-mm cannulated tap is inserted over the guidewire to the appropriate depth (Fig 5C). The tap and guidewire are removed.

Lateral Fragment Preparation

The lateral fragment is commonly displaced inferiorly and medially. It may be helpful to use reduction forceps to pull the lateral fragment anterolaterally from under the medial fragment. Once the lateral fracture site is exposed, the 1.6-mm guidewire is directed laterally into the IM canal (Fig 6A). It is imperative to follow the IM canal and direct the wire posterior to the acromioclavicular joint well above the scapular spine. The AP or cephalic fluoroscopic views should confirm horizontal guidewire positioning within the canal and the caudal tilt view will show a top-down image of the guidewire

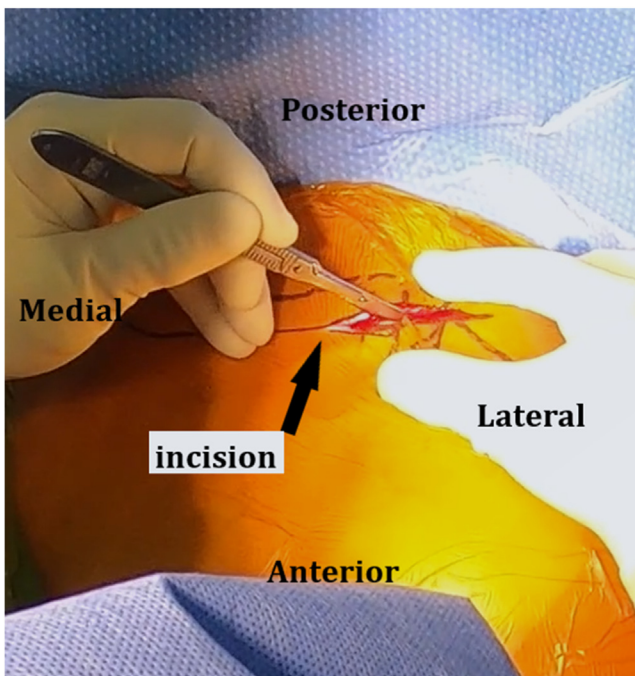


Fig 4. External photograph of anterior left shoulder. A 4-cm oblique incision is made in Langer's lines directly over the midshaft clavicle fracture site. Dissection is carried down through the deltotracheal fascia (not shown).

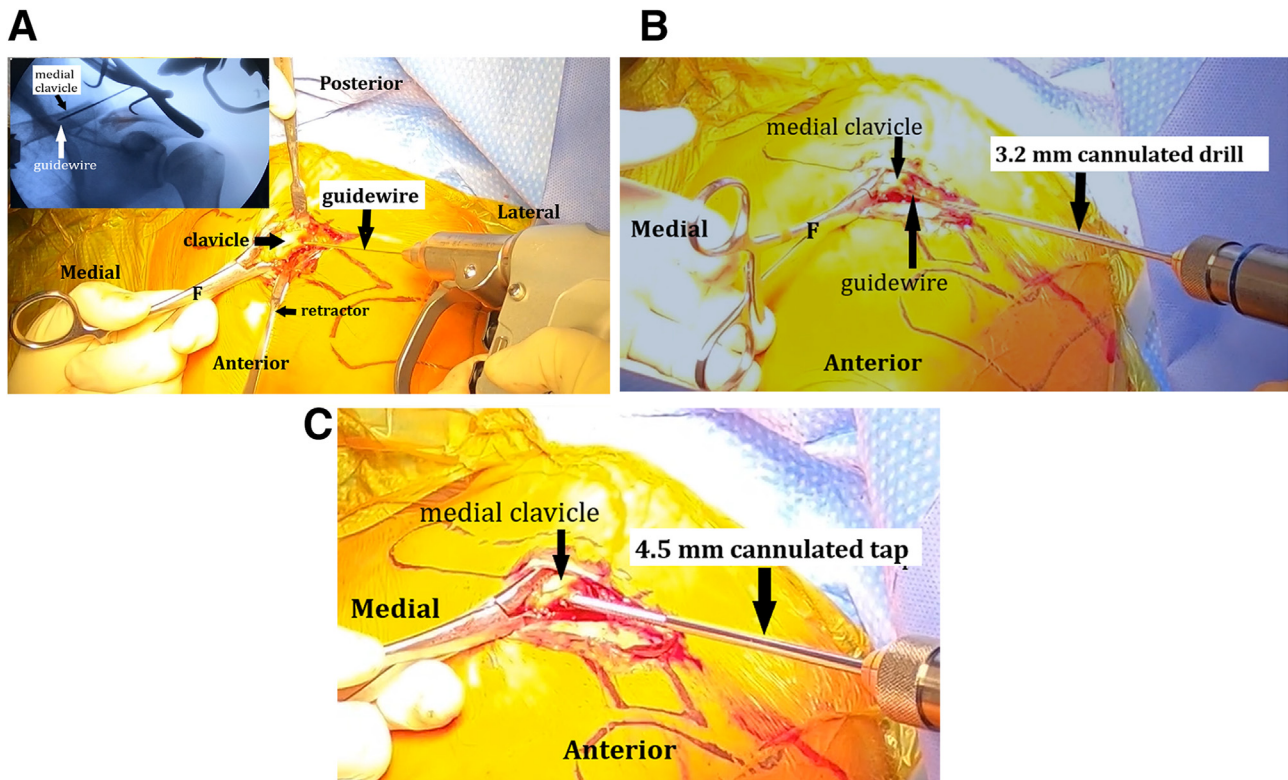


Fig 5. External photograph of anterior left shoulder. (A) The left shoulder medial clavicle fragment is identified and secured with reduction forceps (F). Small Hohmann retractors are used to protect the underlying structures. The 1.6-mm guidewire is advanced into the intramedullary canal using fluoroscopy (inset) to ensure appropriate orientation. The guidewire should abut but not penetrate the anteromedial cortex. (B) The 3.2-mm cannulated drill is inserted over the guidewire to the medial cortex. (C) The 4.5-mm cannulated tap is inserted over the guidewire to the appropriate depth and both are removed.

exiting the posterolateral clavicle cortex (Fig 6B, inset). As the skin is tented a retractor is placed to facilitate guidewire exit out of the skin (Fig 6B). The guidewire is advanced laterally approximately 3 cm and controlled with a Kocher clamp. The 3.2-mm cannulated drill is then inserted from medial to lateral over the guidewire through the posterior cortex (Fig 6C) and the 4.5-mm tap is then inserted in a similar fashion (Fig 6D). The tap is removed.

Fracture Reduction and Fixation

The guidewire is advanced laterally until the medial tip remains at the lateral edge of the fracture site. The fracture is then reduced under direct visualization, using reduction forceps to control each fragment. Small butterfly fragments can be secured with cerclage sutures. The guidewire is then advanced back medially across the fracture site into the predrilled medial fragment to provide provisional fixation (Fig 7). In most cases, the fracture fragments will interdigitate to guide reduction and provide rotational stability. Fluoroscopy is used to confirm fracture reduction and guidewire placement (Fig 8 A and B). A depth gauge is used to determine screw length (Fig 9A), and a countersink is

used to complete preparation of the posterolateral cortex (Fig 9B). The average length of screw for the average female patient is 85 to 95 mm versus 90 to 100 mm for male patients. A 95-mm long 4.5-mm Synthes Headless Compression Screw is then inserted over the guidewire until the outer threads are fully engaged to minimize potential hardware prominence. The guidewire is removed, and final fluoroscopic images are obtained (Fig 10 A and B) confirming final screw position.

Closure and Postoperative Protocol

The wound edges are infiltrated with a long-acting local anesthetic. The deltatrapezial fascia is closed using buried knots to prevent skin irritation. The dermis and skin are closed carefully for a cosmetic incision (Fig 11). Sterile dressings are applied, and the arm is placed in a shoulder immobilizer. The patient begins passive range of motion on postoperative day 1 but limits forward flexion to under 90° for 4 weeks to prevent rotational stress on the fracture site. The immobilizer is discontinued after 6 weeks, and radiographs are obtained at that time showing IM screw in place with fully united fracture (Fig 12).

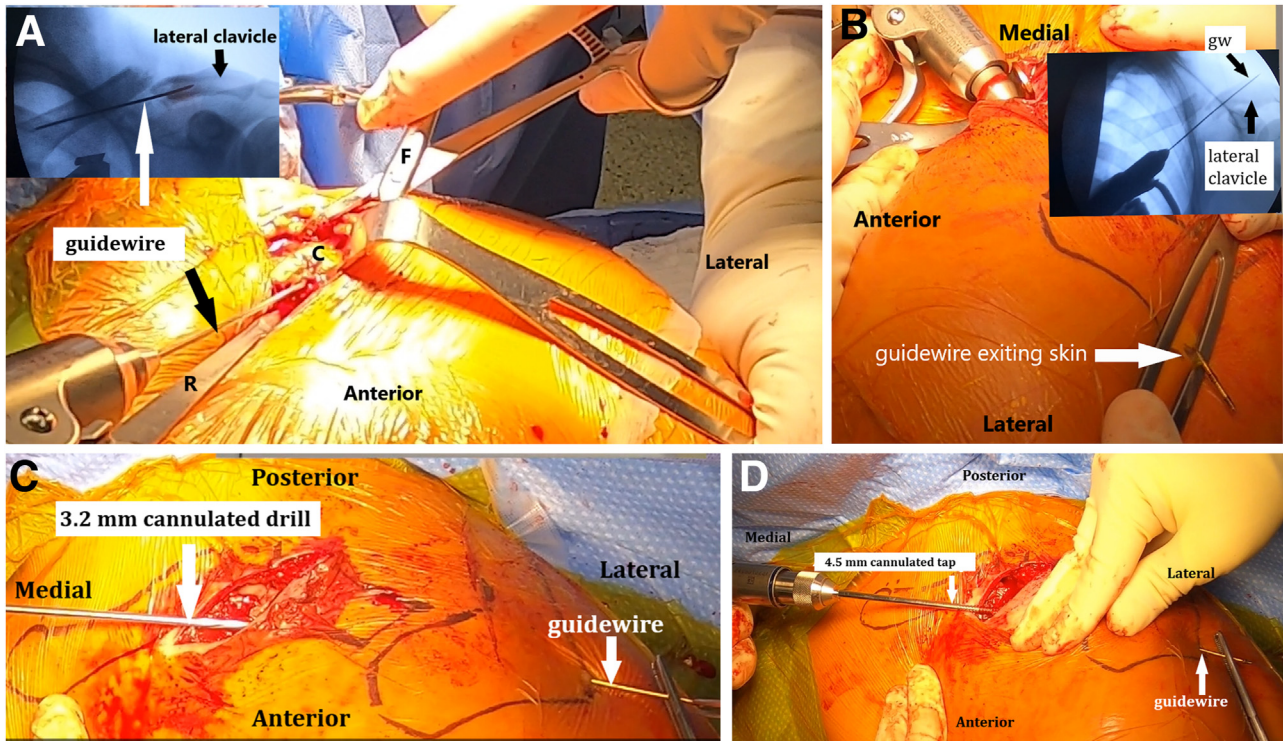


Fig 6. External photograph of anterior left shoulder. (A) The lateral clavicle fragment (C) is secured with reduction forceps (F) with a Hohmann retractor (R), elevating the fragment out of the wound. The 1.6-mm guidewire (gw) is inserted into the intramedullary canal and orientation is checked fluoroscopically (inset). (B) External posterolateral photograph of the left shoulder. The gw is advanced out of the posterolateral clavicle (inset) and a retractor secures the skin as the gw exits posterolaterally. (C) The gw is secured with a clamp laterally and the 3.2-mm cannulated drill is advanced into the intramedullary canal and out the posterolateral clavicle. (D) The 4.5-mm cannulated tap is advanced through the lateral intramedullary canal.

Discussion

Clavicle fractures have historically been treated non-operatively but Hill et al.,²¹ showed that displaced midshaft clavicle fractures with initial shortening of

more than 20 mm had a greater risk of nonunion and inferior patient outcomes. A landmark study by McKee et al.³ demonstrated lower rates of nonunion and improved outcomes in displaced fractures treated with PF when compared with nonoperatively treated fractures. PF, however, has been noted to have a fairly high incidence of implant-related complications, ranging from 9% to 64%.⁵

IM fixation provides a less-invasive alternative to PF with similar functional outcomes.⁹ A recent meta-analysis by Zhao et al.,¹³ reviewed 13 studies comparing IM with PF showed outcomes from IM were superior to PF with reduced operating time, less blood loss and fewer major complications. Hussain et al.⁶ showed equivalent long-term functional outcomes between the 2 groups but patients receiving PF had a 2.43 times greater risk of infection and 1.95 times greater risk of cosmetic complaints.

IM fixation has been described using a wide range of devices, including K-wires, Rockwood pins (DePuy Synthes, Warsaw, IN), Hagie pins (Smith & Nephew, Memphis, TN), Knowles pins (Zimmer Biomet, Warsaw, IN), Herbert screws (Zimmer Biomet) Sonoma CRx devices (Arthrex, Naples, FL), Titanium Elastic Nails (DePuy Synthes), cannulated screws (DePuy

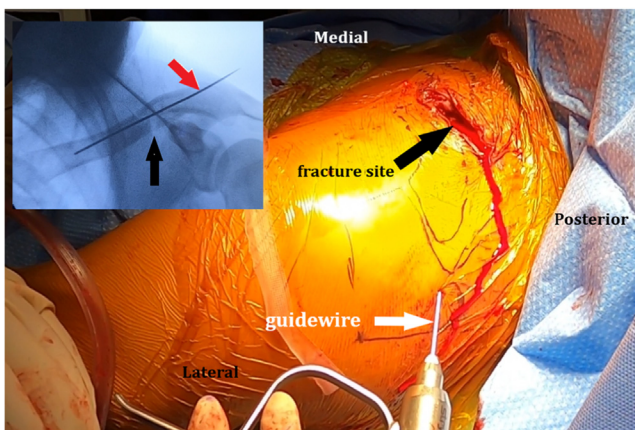


Fig 7. External photograph of posterolateral left shoulder. The fracture site is reduced manually and the guidewire is reinserted into the predrilled medial fragment as shown. Fluoroscopic images (inset) confirm anatomic fracture reduction (black arrow) with the guidewire exit point at the posterolateral clavicle (red arrow).

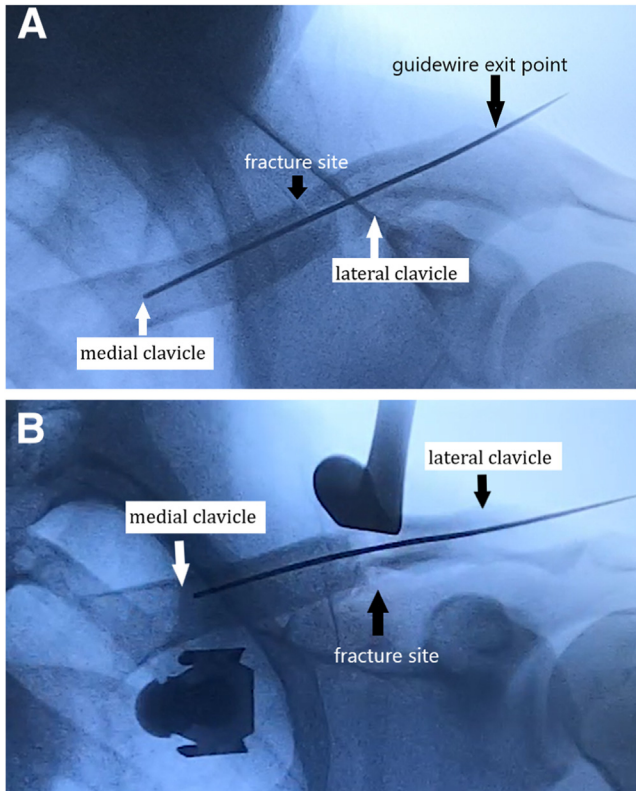


Fig 8. Fluoroscopic caudal tilt (A) and anteroposterior views (B) of the left clavicle showing anatomic fracture-site reduction with the guidewire within the lateral and medial intramedullary canal. The guidewire is noted to extend sufficiently into the medial canal and exit the posterolateral clavicle.

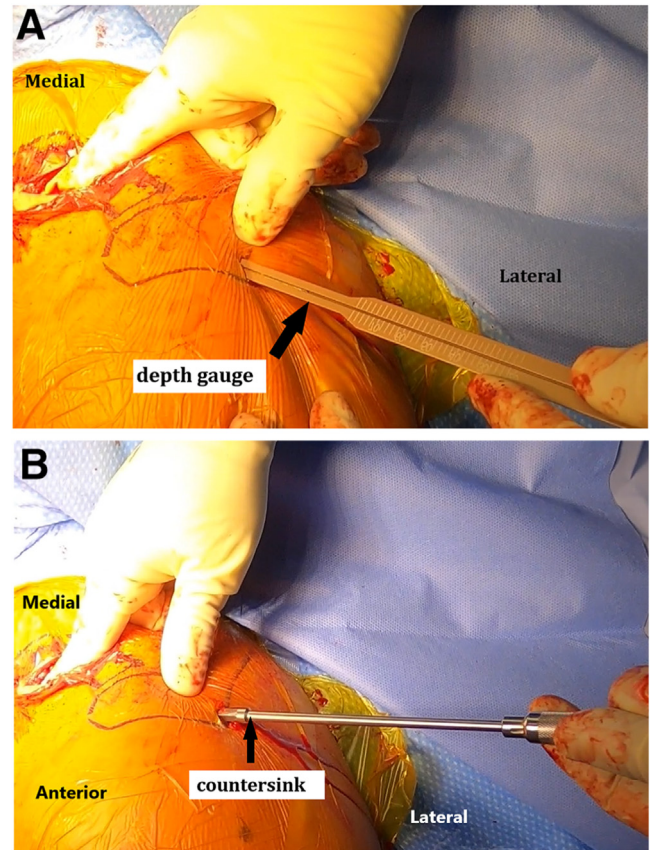


Fig 9. External photograph of lateral left shoulder. (A) The depth gauge is placed over the wire to the posterolateral edge of the left clavicle. (B) The countersink is placed over the wire to adequately prepare the lateral cortex.

Synthes), and Answer Clavicle Pins (BAAT Medical BV, Hengelo, The Netherlands).^{6,10-12,14-20,22-30}

Early descriptions of IM devices noted specific risks for implant related complications.²⁸ Rockwood and Hagie pins commonly caused lateral skin irritation and required second surgeries to remove the implant.^{6,12,14} Titanium elastic nails have been reported to have a 36% reoperation rate for hardware irritation or migration.¹⁸ A recent study involving the Answer Clavicle Pin showed 3 of 20 patients had device-related complications.²² The Sonoma CRx device has been noted to provide similar patient outcomes to PF but has had several reports of hardware failure.²⁷

Several studies reported excellent results with IM fixation using headed cannulated screws.^{19,23} Previous reports, however, described a closed reduction and outside-in anteroagrade approach with a percutaneous posterolateral clavicle entry point.^{19,20} This method required significant radiation exposure and had a steep learning curve, especially in long oblique fractures or in smaller patients.²⁶ A more recent report of 2 cases

described open reduction and retrograde preparation and insertion of a headless compression screw.²⁶ Our described technique similarly allows direct fracture visualization and retrograde preparation of the IM canal, which simplifies the procedure and minimizes radiation exposure. The lateral threaded portion is countersunk which minimizes the risk of hardware protrusion or screw migration.

The advantages of our IM technique over PF are summarized in Table 2 and include less soft-tissue damage, smaller incisions, lower chance of supraclavicular nerve damage, decreased operative time, less prominent hardware and lower cost than precontoured plates.²⁹ The average cost of this commonly available screw is less than \$300 USD at our center compared with nearly \$2,000 USD for a commercially available contoured plate. The IM headless compression screw technique provides fracture compression and healing, a low complication rate, and a cosmetic scar, leading to high patient satisfaction in patients with acute displaced midshaft clavicle fractures.

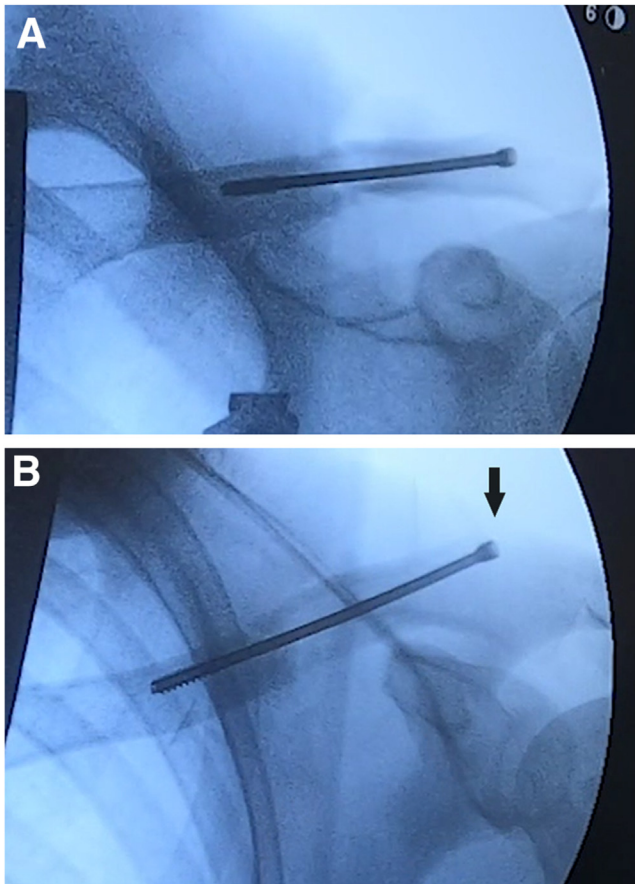


Fig 10. Intraoperative fluoroscopic views. Anteroposterior (A) and caudal tilt (B) images confirm final anatomic fracture reduction and screw placement.

Disclosures

The authors report no conflicts of interest in the authorship and publication of this article. Full ICMJE author disclosure forms are available for this article online, as [supplementary material](#).

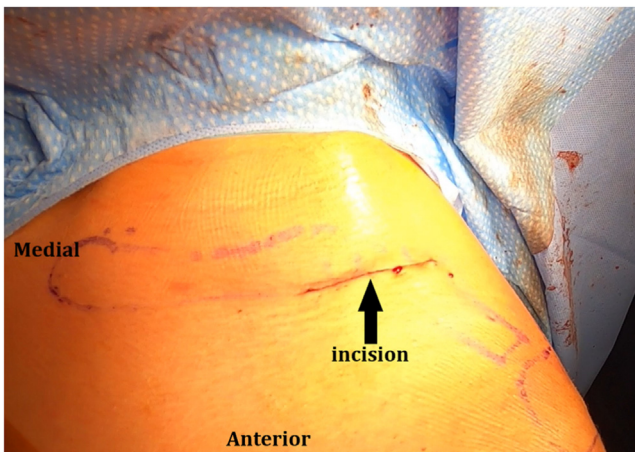


Fig 11. External photograph of anterior left shoulder. The deltotracheal fascia and skin are closed with a 4-cm cosmetic incision.

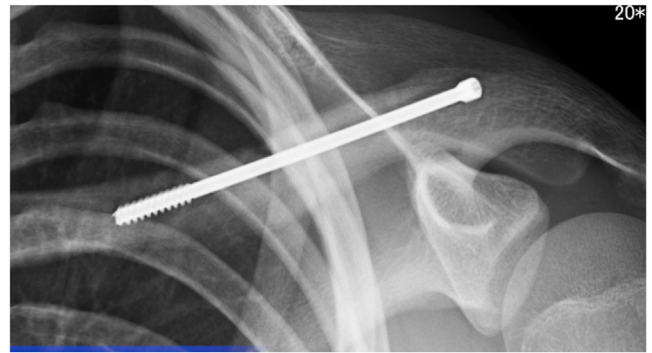

Fig 12. Six-week postoperative caudal tilt radiograph of the left clavicle showing anatomic fracture healing in this patient.

Table 2. Advantages and Disadvantages of Intramedullary Screw Fixation for Clavicle Fractures

Advantages	Disadvantages
Smaller, more cosmetic incision	Not suitable for comminuted or segmental fractures
No prominent hardware	Difficult in smaller-sized clavicles
Less soft-tissue dissection	Requires skilled radiology technologist and large C-arm unit
Lower cost than plate fixation	Less familiar than standard ORIF techniques
Lower rate of infection	Less rotational stability than plate fixation
Similar long-term outcomes	
Decreased operative time	

ORIF, open reduction internal fixation.

References

1. Wright M, Della Rocca GJ. American Academy of Orthopaedic Surgeons Clinical Practice Guideline Summary on the Treatment of Clavicle Fractures. *J Am Acad Orthop Surg* 2023;31:977-983.
2. Sepehri A, Guy P, Roffey DM, O'Brien PJ, Broekhuysen HM, Lefaivre KA. Assessing the change in operative treatment rates for acute midshaft clavicle fractures. *JBJS Open Access* 2023;8.
3. Canadian Orthopaedic Trauma Society. Nonoperative treatment compared with plate fixation of displaced midshaft clavicular fractures. A multicenter, randomized clinical trial. *J Bone Joint Surg Am* 2007;89:1-10.
4. Cao Z, Hou Y, Su X, Teng M, Ji W, Li M. Brachial plexus injury after clavicle fracture operation: A case report and literature review. *BMC Surg* 2021;337-342.
5. Wijdicks FJG, Van der Meijden OAJ, Millett PJ, Verleisdonk EJMM, Houwert RM. Systematic review of the complications of plate fixation of clavicle fractures. *Arch Orthop Trauma Surg* 2012;132:617-625.
6. Hussain N, Sermer C, Prusick PJ, Banfield L, Atrey A, Bhandari M. Intramedullary nailing versus plate fixation for the treatment displaced midshaft clavicular fractures: A systematic review and meta-analysis. *Sci Rep* 2016; 349-362.
7. Fuglesang HFS, Flugsrud GB, Randsborg PH, Oord P, Benth JS, Utvåg SE. Plate fixation versus intramedullary nailing of completely displaced midshaft fractures of the

- clavicle: A prospective randomised controlled trial. *Bone Joint J* 2017;8:1095-1101.
8. Xiao H, Gao H, Zheng T, Zhao J, Tian Y. Plate fixation versus intramedullary fixation for midshaft clavicle fractures: Meta-analysis of complications and functional outcomes. *J Int Med Res* 2016;44:201-215.
 9. Houwert RM, Wijdicks FJ, Steins Bisschop C, Verleisdonk EJ, Kruyt M. Plate fixation versus intramedullary fixation for displaced mid-shaft clavicle fractures: A systematic review. *Int Orthop* 2012;36:579-585.
 10. Kleweno CP, Jawa A, Wells JH, et al. Midshaft clavicular fractures: comparison of intramedullary pin and plate fixation. *J Shoulder Elbow Surg* 2011;20:1114-1117.
 11. Ju W, Mohamed SO, Qi B. Comparison of plate fixation vs. intramedullary fixation for the management of midshaft clavicle fractures: A systematic review and meta-analysis of randomised controlled trials. *Exp Ther Med* 2020;20:2783-2793.
 12. Houwert RM, Smeeing DPJ, Ahmed Ali U, Hietbrink F, Kruyt MC, van der Meijden OA. Plate fixation or intramedullary fixation for midshaft clavicle fractures: A systematic review and meta-analysis of randomized controlled trials and observational studies. *J Shoulder Elbow Surg* 2016;25:1195-1203.
 13. Zhao JX, Zhao YP, Mao Z, et al. Intramedullary nailing versus plating fixation for the treatment of midshaft clavicular fractures: A meta-analysis of randomized controlled trials. *Injury* 2023;54:S70-S77 (suppl 2).
 14. Li L, Yang X, Xing F, Jiang J, Tang X. Plate fixation versus intramedullary nail or Knowles pin fixation for displaced midshaft clavicle fractures: A meta-analysis of randomized controlled trials. *Medicine* 2020;99:e22284.
 15. Saha P, Datta P, Ayan S, Garg AK, Bandyopadhyay U, Kundu S. Plate versus titanium elastic nail in treatment of displaced midshaft clavicle fractures: A comparative study. *Indian J Orthop* 2014;48:587-593.
 16. Park JS, Ko SH, Hong TH, et al. Plate fixation versus titanium elastic nailing in midshaft clavicle fractures based on fracture classifications. *J Orthop Surg (Hong Kong)* 2020;28:230-235.
 17. Strauss EJ, Egol KA, France MA, Koval KJ, Zuckerman JD. Complications of intramedullary Hagie pin fixation for acute midshaft clavicle fractures. *J Shoulder Elbow Surg* 2007;16:280-284.
 18. Frigg A, Rillmann P, Perren T, Gerber M, Ryf C. Intramedullary nailing of clavicular midshaft fractures with the titanium elastic nail: problems and complications. *Am J Sports Med* 2009;37:352-359.
 19. Chuang TY, Ho WP, Hsieh PH, Lee PC, Chen CH, Chen YJ. Closed reduction and internal fixation for acute midshaft clavicular fractures using cannulated screws. *J Trauma* 2006;60:1315-1320.
 20. Chen PY, Lin CC, Wang CC, Tsai CL. Closed reduction with intramedullary fixation for midclavicular fractures. *Orthopedics* 2004;27:459-462.
 21. Hill JM, McGuire MH, Crosby LA. Closed treatment of displaced middle-third fractures of the clavicle gives poor results. *J Bone Joint Surg Br* 1997;79:537-539.
 22. Hoogervorst P, Konings P, Hannink G, et al. Functional outcomes, union rate, and complications of the Anser Clavicle Pin at 1 year: A novel intramedullary device in managing midshaft clavicle fractures. *JSES Int* 2020;4:272-279.
 23. Proubasta I, Itarte J, Lamas C, Caceres E. Midshaft clavicular non-unions treated with the Herbert cannulated bone screw. *J Orthop Surg* 2004;1271-1275.
 24. Hoogervorst P, van Dam T, Verdonshot N, Hannink G. Functional outcomes and complications of intramedullary fixation devices for Midshaft clavicle fractures: A systematic review and meta-analysis. *BMC Musculoskelet Disord* 2020;21:395-399.
 25. Smekal V, Irenberger A, Attal R El, Oberladstaetter J, Krappinger D, Kralinger F. Elastic stable intramedullary nailing is best for mid-shaft clavicular fractures without comminution: Results in 60 patients. *Injury* 2011;42:324-329.
 26. Elgawadi MH, Sharafeldin AG. Intramedullary headless compression screw fixation for midshaft fractures of the clavicle: A case report study. *Int J Surg Case Rep* 2021;48-50.
 27. King PR, Lamberts RP. Management of clavicle shaft fractures with intramedullary devices: A narrative review. *Expert Rev Med Devices* 2020;17:807-815.
 28. Eichinger JK, Balog TP, Grassbaugh JA. Intramedullary fixation of clavicle fractures: Anatomy, indications, advantages, and disadvantages. *J Am Acad Orthop Surg* 2016;24:455-464.
 29. Hanselman AE, Murphy TR, Bal GK, McDonough EB. Operative cost comparison: Plating versus intramedullary fixation for clavicle fractures. *Orthopedics* 2016;39:e877-e882.
 30. Xu B, Lin Y, Wang Z, et al. Is intramedullary fixation of displaced midshaft clavicle fracture superior to plate fixation? Evidence from a systematic review of discordant meta-analyses. *Int J Surg* 2017;43:155-162.