

# Getting Athletes Back on the Field

## Management of Clavicle Fractures and Return to Play



Wade Gobbell, MD, Christopher M. Edwards, BS,  
Samuel R. Engel, MA, Katherine J. Coyner, MD, MBA\*

### KEYWORDS

• Clavicle • Fracture • Athlete • Return to sport

### KEY POINTS

- Defining return to sport timelines for athletes with clavicle fractures depends on time to radiographic union, level of competition, type of sport, and injury timing within the season.
- Fixation of clavicle fractures in contact athletes may necessitate the use of fixation constructs with higher biomechanical strengths, including larger superior plates or dual plating.
- Postinjury or postoperative rehabilitation timelines should be guided by restoration of functional range of motion, strength, and sport-specific exercises.

### INTRODUCTION

Clavicle fractures are common injuries at all levels of sports participation, with the mechanism usually involving a medially directed blow to the lateral shoulder. Treatment may be conservative or surgical, with either option necessitating significant time away from sports participation. Given the prevalence of clavicle fractures among athletes and the significant impact they can have on collegiate and professional careers, it is imperative that orthopedic sports medicine physicians can competently diagnose and manage these injuries to enable athletes to safely and efficiently return to a high level of play. One must be equipped with a data-driven approach to counsel athletes and their families, coaches, and/or agents on the timeline for return to sport, their expectations for performance after return, and the risk of returning to play prior to fracture union. This review will cover broadly clavicle injuries in sports, the diagnosis

---

UConn Health Department of Orthopedic Surgery, 263 Farmington Avenue, Farmington, CT 06030, USA

\* Corresponding author.

E-mail address: [coyner@uconn.edu](mailto:coyner@uconn.edu)

Clin Sports Med 42 (2023) 649–661

<https://doi.org/10.1016/j.csm.2023.05.006>

0278-5919/23/© 2023 Elsevier Inc. All rights reserved.

[sportsmed.theclinics.com](https://www.sportsmed.theclinics.com)

and management of clavicle fractures in athletes, and guidelines for return to play. We will review findings of both recent and historical studies and share our approach to rehabilitating athletes after operative treatment of clavicle fractures. The technical aspects of open reduction and internal fixation (ORIF) of clavicle fractures will be described in detail in other chapters within this text.

### ***Epidemiology of Sports-Related Clavicle Fractures***

---

Clavicle fractures represent 4% of fractures for all age groups based on a study of more than 2000 cases at a large urban hospital.<sup>1</sup> Other studies have reported clavicle fracture prevalence between 2.6% and 10%.<sup>2,3</sup> Isolated clavicle fractures comprise more than 40% of all fractures involving the shoulder girdle.<sup>3</sup>

Approximately 30% to 50% of clavicle fractures are attributable to sports participation.<sup>4-6</sup> Clavicle fractures are the most prevalent of all fractures among athletes, contributing close to 10% of all sport-related fractures.<sup>4,7</sup> At the 2004 National Football League Combine, clavicle injuries were the fourth most common injury reported by elite college football players.<sup>8</sup> Clavicle fractures are common among both adults and adolescents, but patients between 10 and 19 years of age have the highest risk of injury.<sup>5,6,9</sup> Multiple studies have found that male athletes are disproportionately affected by clavicle fractures and are up to 3 times more likely to sustain a clavicle fracture than women.<sup>6,9</sup> Overall, clavicle fractures have the highest prevalence in football followed by soccer, snowboarding, bicycling, wrestling, and snow skiing as demonstrated by a study of over 2000 fractures.<sup>9</sup> Another study found that male athletes in high school were most likely to sustain clavicle fractures in ice hockey followed by lacrosse, football, and wrestling.<sup>10</sup> For female athletes, the high school sports with the highest rate of clavicle fracture were soccer followed by lacrosse and basketball.<sup>10</sup>

Clavicle fractures are prevalent in winter sports and are the third most common injury to recreational snowboarders, representing 6.5% of over 5500 reported injuries.<sup>11,12</sup> Interestingly, clavicle fracture rates for snowboarding are much higher than those for skiing despite both sports having similar participation risks.<sup>13</sup>

For both professional and recreational cyclists participating in road, mountain, or trail biking, clavicle fractures are the most prevalent among acute injuries.<sup>14-18</sup> Clavicle fractures were the most common traumatic injury among Tour de France participants over 7 years.<sup>19</sup> An analysis of all clavicle fractures assessed at an emergency department over a 10-year period identified cycling as the most common source of injury with an increase in incidence during the study period.<sup>20</sup> One study has even demonstrated that the increase in bicycle use among commuters in New York City is correlated with increased clavicle fracture incidence.<sup>21</sup>

### **ANATOMY AND BIOMECHANICS**

The clavicle is a sigmoid-shaped bone that lies horizontally between the sternum and acromion. It serves as an important connection between the axial skeleton and upper limbs. The clavicle articulates medially with the sternum at the sternoclavicular (SC) joint and laterally with the acromion at the acromioclavicular (AC) joint. The AC joint enables gliding movement of the shoulder. The AC ligament connects the clavicle and acromion process of the scapula and restricts motion (see Perry and colleagues' article, "[Acromioclavicular Joint Anatomy and Biomechanics: the Significance of Posterior Rotational and Translational Stability](#)," in this issue for a detailed review). The SC joint facilitates several movements including protraction-retraction, depression-elevation, and rotation. The SC joint is stabilized by the anterior and posterior SC joint ligaments

in addition to the anterior interclavicular ligament and posterior costoclavicular ligament (see Gobbell and colleagues' article, "[Atraumatic Sternoclavicular Joint Instability: Prevalence, Etiology, and Management](#)," in this issue for a detailed review). The trapezius and deltoid muscles attach along the lateral surface of the clavicle. The sternocleidomastoid, pectoralis major, subclavius, and sternohyoid muscles attach along the medial surface of the clavicle. Below the middle third of the clavicle are the subclavian and axillary vessels, as well as the nerves of the brachial plexus.

Epidemiological studies have found the most common mechanism of fracture to be direct fall onto the shoulder.<sup>1,22,23</sup> Biomechanical studies of the forces involved in clavicle fractures demonstrated that a direct injury may exceed the critical buckling load of the bone at a compressive force equal to the individual's body weight.<sup>23</sup> Athletes are prone to clavicle fractures from contact with playing surfaces during competition and contact with other players resulting in a direct blow to the shoulder.<sup>23</sup>

Most clavicle fractures involve the middle third of the bone.<sup>3,24</sup> When grouping sports-related and other traumatic mechanisms, approximately 70% to 80% of fractures are mid-diaphyseal, 48% have any displacement, and 19% are comminuted.<sup>3,25</sup>

### **Classification of Clavicle Fractures**

There are numerous methods for classification of clavicle fractures, and the most frequently used systems are outlined in this section. Currently, most practitioners follow the methodology published by Allman, but it is not uncommon to hear references to other systems such as Neer and Robinson. For this reason, we thought it was relevant to include the following information for reference.

The Allman Classification system classifies fractures of the clavicle into three groups. Group 1 represents fractures of the middle third and are the most common form. Group 2 fractures are distal to coracoclavicular ligament, and nonunion is common in these cases. Group 3 fractures are located at the proximal end of the clavicle.<sup>26</sup>

The Neer Classification is similarly grouped into three types. Type 1 involves the middle third and represents approximately 80% of fractures. Type 2 involves the distal end and accounts for 15% of fractures. Type 3 or medial third clavicle fractures account for only 5% of fractures.<sup>27</sup>

The Robinson Classification consists of three broad categories with further subdivision. Type 1 are fractures of the medial fifth and can be undisplaced (a) or displaced (b). Type 1a1 and 1a2 are nondisplaced extra-articular and intra-articular, respectively. Similarly, Type 1b1 and 1b2 are displaced extra-articular and intra-articular, respectively. Type 2 are fractures of the middle three-fifths of the clavicle. Type 2a1 are nondisplaced cortical alignment fractures, whereas Type 2a2 are angulated cortical alignment fractures. Type 2b are displaced fractures and can be simple, wedge comminution (b1) or multifragmented and segmental (b2). Type 3 fractures involve the lateral fifth of the clavicle and can be nondisplaced extra-articular (a1), nondisplaced intra-articular (a2), displaced extra-articular (b1), or displaced intra-articular (b2).<sup>2</sup>

## **DIAGNOSIS AND MANAGEMENT**

### ***History and Physical Examination***

Clavicle fractures occur during acute injuries or trauma. Patients will present with localized pain, swelling, crepitus, deformity, and occasionally, tenting of the skin. When evaluating a patient for clavicle fracture, clinicians should acknowledge the possibility of vascular or neurological damage due to the proximity of vascular structures and the brachial plexus as it may impact the decision to elect surgical or nonsurgical

treatment. Assessing the structural integrity of the AC and SC joints is also important. In most cases, there will be a deformity directly over the location of the fracture although this is less common with lateral and nondisplaced medial fractures. The fracture may be mobile and may be associated with crepitus.

In addition to musculoskeletal testing, thorough neurologic examination should be performed for both motor and sensory nerves. In particular, the medial branch of the supraclavicular nerve is at the highest risk of injury.<sup>24</sup> A purely sensory nerve injury to this branch results in numbness of the skin overlying the clavicle. While uncommon, brachial plexus injuries can occur due to acute elongation of nerve fibers or compression from bone fragments or soft-tissue edema.<sup>28</sup>

The lungs and subclavian artery can also be involved in cases of traumatic fracture. It is estimated that pneumothorax may occur in 3% of midclavicular fractures and hemothorax in 1% of midclavicular fractures.<sup>24</sup> These pathologies are often detected during the primary trauma survey with diagnosis confirmed by radiographs. Injury to the subclavian artery is another rare complication of the clavicle fracture that can be life-threatening. Penetrating or blunt trauma can cause rupture, pseudoaneurysm, dissection, or thrombosis.<sup>29</sup> Evaluation of the subclavian artery can be performed using the brachial-brachial index as well as vascular ultrasound or computed tomography (CT) scan.

### ***Diagnostic Imaging***

---

Radiographic evaluation for all clavicle fractures should include an anteroposterior radiograph as well as an apical oblique radiograph with 15° to 40° of cephalic angulation.<sup>30</sup> For evaluation of the AC joint and clavicle, the Zanca view requires 10° to 15° of cephalic angulation to remove the overlap between the AC joint and acromion.<sup>30</sup> Upright positioning as compared to supine positioning better demonstrates clavicle fracture displacement and shortening.<sup>31</sup> Weighted views can help identify inconspicuous fractures but are rarely performed because they provide limited information for management and increase patient discomfort.<sup>32</sup> CT angiogram should be performed when neurological or vascular damage is suspected, especially for proximal fractures. CT can also be useful for preoperative planning to assess the degree of displacement, comminution, and shortening of the clavicle.

### ***Management***

---

Detailed discussion of treatment of clavicle fractures is found in other chapters within this text and will be only briefly included here. Above all, absolute and relative indications for surgery should inform treatment decisions. While a trial of conservative treatment in nonathletes may help most patients avoid surgery and its associated risks, the stakes are higher for an athlete. Time sidelined by injury equates to at least loss of a hobby for the recreational athlete and, at worst, loss of salary/career opportunities for the professional. The higher union rate (95% vs 64% at 1 year for distal one-third fractures) and faster time to radiographic union (mean 28.4 vs 16.4 weeks for midshaft fractures) for surgical treatment quantify its improved reliability compared with conservative management.<sup>33,34</sup>

When opting for surgical management, fracture location and orientation will guide implant choice. The increased load placed on the fixation construct by the contact athlete compared to the general population would indicate the use of more robust hardware such as larger plates or dual plate constructs.

Minimizing time from injury to surgery not only facilitates fracture reduction intraoperatively but also accelerates the recovery timeline. Regardless of surgical or nonsurgical treatment, a period of rest and immobilization is prescribed before physical

therapy begins. Although there is no clear consensus on duration or type of immobilization with nonoperative treatment, a period of immobilization of at least 3 to 4 weeks is typically recommended to allow fracture union.<sup>35</sup> With surgical treatment, active-assisted range-of-motion exercises may begin after 1 week in our postoperative protocol. To maintain the chronological advantage of surgical stabilization in the early healing stages, we recommend surgery within the first 1 to 2 weeks after injury.

## RETURN TO PLAY

The detrimental effects of a clavicle fracture can be underappreciated. Although approximately 80% of patients return to their preinjury level of sports participation, return to sport times vary widely depending on the election of surgical management and rehabilitation protocols.<sup>36</sup> For athletes with a clavicle fracture, minimizing the time away from sports participation must be balanced with the safety of return to play. Important factors to consider include the age and skeletal maturity of the patient, the severity and complexity of the fracture, and the type and level of sport the patient participates in, as well as his or her position(s). Before clearing an athlete for sports participation, it is important to ensure there is evidence of complete healing of the clavicle based on radiographs and clinical assessment. Evidence of healing based on radiographs is demonstrated by consolidation or callus at the fracture site. The adequacy of clinical healing is marked by minimal tenderness to palpation, complete range of motion, and normal strength when compared to the contralateral side.

For patients who undergo surgical management, a period of immobilization following surgery is recommended followed by a gradually progressive course of physical therapy. Many protocols call for 2 to 3 weeks of immobilization with physical therapy and strengthening starting around 6 weeks postoperatively.<sup>33,37</sup> Other recommendations are more aggressive, mandating only 10 days of immobilization in a sling, followed by range-of-motion exercises, and strengthening and gradual return to sport starting at 6 weeks postoperatively.<sup>38</sup> In general, earlier rehabilitation is associated with earlier return to play, but individualized protocols should be designed based on fracture characteristics and patient factors.

The type of sport in which the patient participates factors significantly in the return-to-sport time, with contact sports generally taking the longest. Return to sport may be recommended as early as 3 to 6 weeks for noncontact sports and 8 to 12 weeks for contact sports.<sup>14,39</sup> For professional cyclists treated with plate fixations of clavicle fractures, the return time to activity and competition can be as early as 10 days and 3 weeks, respectively.<sup>14</sup> Vora and colleagues found that 17 National Football League (NFL) players who sustained clavicle fractures experienced a 3.5-month return to competition, albeit without impact on subsequent performance.<sup>40</sup>

Return to sport with conservatively managed clavicle fractures is dependent on time to union prior to commencing range-of-motion exercises, and refracture risk is incurred with early return. In a study of clavicle fractures among NFL athletes over 5 seasons, 4 out of 7 displaced midshaft clavicle fractures treated without surgery went on to refracture within 1 year of the initial injury.<sup>41</sup> As a result, athletes may experience delayed return times and lose opportunities to participate in competition. The 4 athletes who sustained a refracture in this cohort lost a mean of 1.5 seasons as a result of their original and subsequent injuries.<sup>41</sup>

Early operative stabilization of the fracture site facilitates earlier initiation of range of motion and return to competition.<sup>24</sup> In a retrospective review of 54 athletes, Ranalletta and colleagues found that operative treatment of clavicle fractures enabled early and safe return to sport at a mean of 68 days, with over 90% of patients returning to the

same level of sport.<sup>42</sup> Similarly, Meisterling and colleagues reviewed 29 athletes who underwent surgical treatment for midshaft clavicle fractures and found the average time for return to sport was 83 days.<sup>43</sup> Over 20% of patients were participating in sports before 6 weeks, without increased risk of complication for the accelerated return.<sup>43</sup>

In a systematic review of clavicle fractures treated conservatively and operatively, Robertson and Wood found that approximately 80% of athletes will have the capacity to play at their preinjury level of activity.<sup>36</sup> However, return rates to preinjury level of play for conservatively managed displaced midshaft fractures were significantly lower than those for operatively managed fractures. For patients who received operative treatment, there was no significant difference between the return rates to preinjury level of play for plate fixation versus intramedullary nailing. The study also found a statistically significant 12-week difference in return times for conservatively managed displaced midshaft fractures as compared to operatively managed fractures (21.5 vs 9.4 weeks, respectively), but no difference between conservatively managed nondisplaced midshaft fractures and operatively managed fractures.<sup>36</sup>

Assessing clavicle fractures treated by ORIF in NFL players, two separate studies found that 50% and 44% of players were able to return to play in the same 18-week season.<sup>41,44</sup> In the athletes with displaced midshaft clavicle fractures, 4 of 13 athletes were able to return to football during the same season. In the surgical group, 3 athletes returned at a mean of 8 weeks postoperatively, while 1 conservatively treated athlete returned at 10 weeks after injury and sustained a refracture 1 week after return.<sup>41</sup>

Jack and colleagues found that clavicle fractures managed operatively returned at  $211 \pm 145$  days on average.<sup>44</sup> In another study by the same authors, conservatively managed clavicle fractures returned after a mean  $245 \pm 120$  days.<sup>45</sup> Because the authors defined return to sport as return to game participation, the large standard deviation was likely due to the time within the season that the injury occurred. This difference of almost 5 weeks can significantly impact an individual's ability to return within an 18-week regular season.

Other studies have found similar relationships between surgical treatment and quicker return to play. One study of 188 clavicle fractures in professional road cyclists found an average return time of 54 days for surgically treated fractures versus 59 days for conservatively managed fractures.<sup>17</sup> Looking at the safety of return to play in National Hockey League ice hockey players, researchers found that the average time from injury to return to sport was 65 days in the operative group and 98 days in the nonoperative group.<sup>46</sup>

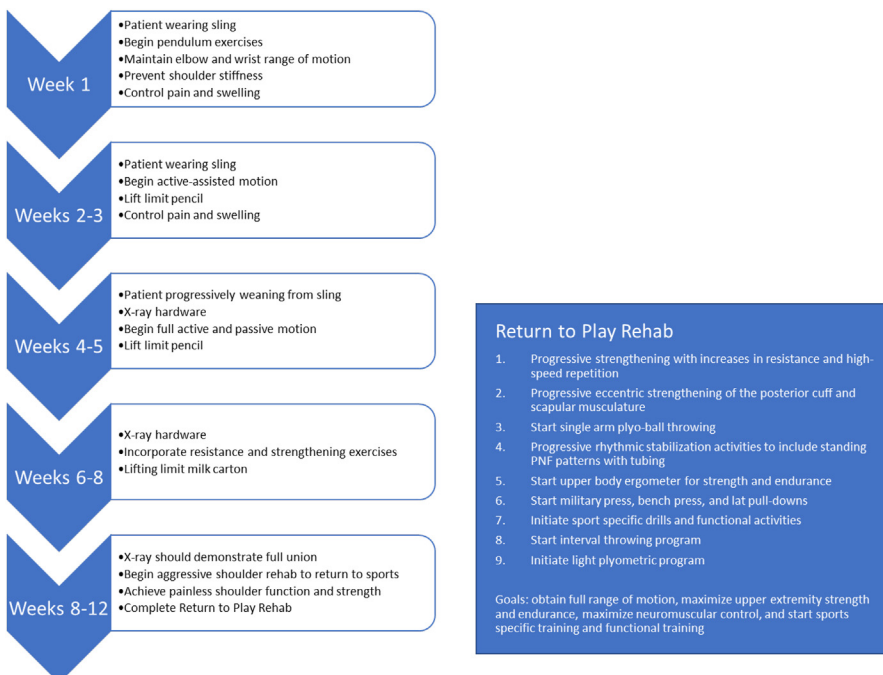
Implant choice for fixation of the clavicle is discussed in depth in other chapters, but here, we highlight considerations for return to play. Time to return to play and return rates were shown to be similar between midshaft fractures treated with plate and those treated with intramedullary fixation.<sup>36</sup> A systematic review and meta-analysis of biomechanical studies showed that superior plating had higher stiffness and greater load to failure in bending and torsion than intramedullary fixation, with no differences in rotational strength.<sup>47</sup> The bending failure torque was greater for the clavicle after removal of the intramedullary device than after removal of the plate and screws.<sup>47</sup> Another biomechanical study showed no significant differences in bending, torsional, or axial compression strength of dual mini-fragment plate fixation compared with larger anterior or superior plating.<sup>48</sup>

After healing is demonstrated by radiographic and clinical indices, hardware management varies by fixation method. If pinning is elected, routine removal of intramedullary pins is recommended after radiographic union.<sup>49</sup> Otherwise plate and screw

constructs are usually left in place unless there is irritation. In that case, the hardware can be removed after complete fracture healing. Return to play after intramedullary pin removal may occur after 4 weeks assuming stable radiographic appearance of the fracture site.<sup>49</sup> A systematic review and meta-analysis found that refracture after hardware removal was more common with plate and screw fixation than with intramedullary fixation.<sup>50</sup> There is no published consensus regarding return to play after plate and screw removal, but the risk of refracture is rate-limiting. The authors recommend return to play once the surgical incision has appropriately healed assuming radiographs show adequate union after hardware removal; this may be as early as 2 weeks for noncontact sports and 4 weeks for contact athletes. Risk factors for refracture after removal of clavicle plate and screws have been found to include female sex and lower body mass index<sup>51</sup> and simple or segmental fracture patterns.<sup>52</sup> Other than fracture pattern, neither study determined any radiographic parameters conferring increased risk for refracture after hardware removal.

### OUR APPROACH TO REHAB AFTER ORIF

Goals for the immediate postoperative period include maintaining stability of the fracture and pain control. The use of a sling for immobilization and the judicious use of narcotic medication is recommended for the first week. A progressive rehab course is initiated by week 2, with the ultimate objective of regaining normal shoulder range of motion, restoring normal upper-extremity strength and endurance, and allowing the patient to return to at least the preinjury level of sports participation. The following protocol (Fig. 1) is composed of general guidelines that may be adjusted by the



**Fig. 1.** An overview of the rehabilitation program for operative management of clavicle fractures.

athletic trainer or physical therapist based on individual patient progression and capabilities. Radiographic healing should also be monitored throughout the rehabilitation process.

Ultimately, safe return to sport for the patient requires adequate strength, flexibility, and endurance. Return following ORIF of the clavicle requires complete fracture union to minimize risk of reinjury and return of strength and shoulder motion on functional testing. Symptoms such as pain, swelling, or instability should be closely monitored by the patient throughout rehabilitation and as he or she reinitiates sport activities.

After ORIF, we recommend an intensive 12-week protocol for complete recovery of strength and range of motion. Physical therapy should be initiated within the first week postoperatively. Many of the early stages can be performed at home after being taught proper form.

### ***Week 1***

---

The patient is in a sling that may be removed for pendulum exercises. The patient should have no active shoulder motion but can perform elbow and wrist range-of-motion exercises without resistance. The goals for this phase of rehabilitation include maintaining elbow and wrist range of motion, preventing shoulder stiffness, and controlling pain and swelling. It is imperative that the repair is protected.

### ***Weeks 2 to 3***

---

The patient should continue to wear the sling, but it may be removed for exercises. The patient can begin active-assisted motion and should continue pendulum exercises. The rope and pulley can be used for flexion and scaption. The patient should not lift anything heavier than a pencil in the operative hand. Goals for this phase include initiating shoulder range of motion and preventing pain. The repair should continue to be protected.

### ***Weeks 4 to 5***

---

The patient should progressively wean from sling. If radiographs demonstrate no change to the hardware, the patient may begin full active and passive motion. However, there is no lifting of anything heavier than a pencil.

### ***Weeks 6 to 8***

---

If radiographs are showing signs of union, the patient may begin to slowly incorporate resistance and strengthening exercises. Lifting limitations are a carton of milk.

### ***Weeks 8 to 12***

---

Once radiographs demonstrate union and 2 weeks of resistance exercises have been performed, the patient should work on aggressive shoulder rehab to return to sports. Once painless shoulder function has been achieved and strength has returned, an athlete may return to play when he or she has completed the return-to-play rehab. This consists of the following steps.

1. Progressive strengthening with increases in resistance and high-speed repetition
2. Progressive eccentric strengthening of the posterior cuff and scapular musculature
3. Start single arm plyo-ball throwing
4. Progressive rhythmic stabilization activities to include standing PNF patterns with tubing
5. Start upper-body ergometer for strength and endurance
6. Start military press, bench press, and lat pull-downs

7. Initiate sport-specific drills and functional activities
8. Start an interval throwing program
9. Initiate a light plyometric program

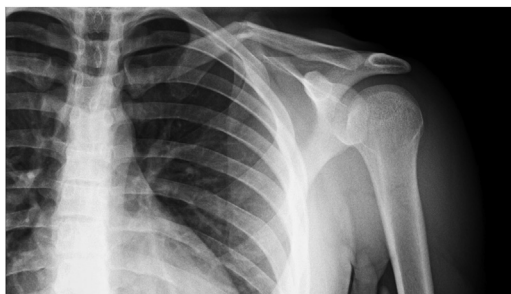The goals of this final phase are obtaining full range of motion, maximizing upper-extremity strength and endurance, maximizing neuromuscular control, and starting sports-specific training and functional training.

More aggressive rehabilitation protocols have been described in the literature. A case report of a football player demonstrated safe return to the field in 6 weeks following surgical treatment and accelerated rehabilitation.<sup>53</sup> The authors initiated early and progressive rehabilitation focused on strength and range of motion, as well as maintaining cardiovascular fitness. Weekly radiographs were obtained to monitor healing. By week 4, the athlete was working on advanced strengthening exercises and participating in noncontact practices. By week 5, he demonstrated full strength and range of motion and was cleared for full contact.<sup>53</sup> Further studies should be conducted to demonstrate the effectiveness and reliability of an accelerated approach. The safety of expedited rehabilitation protocols has not been directly compared to more conservative approaches, and rehabilitation should always be individualized to the patient and sport.

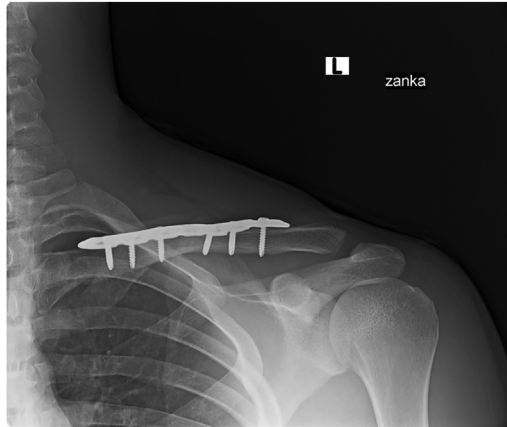
## CASE PRESENTATION

A 22-year-old collegiate football player sustained a displaced, middle one-third left clavicle fracture when landing on his shoulder after diving for a successful touchdown reception. This injury occurred during the season opener. He had no skin compromise or clinical evidence of neurologic injury. Radiographs were obtained, showing a displaced, angulated Type 1 clavicle fracture (**Fig. 2**), and he was scheduled for ORIF on postinjury day #2. The timing of the injury during the college football “Week 0” allowed potential return to football during the same season, and the cited evidence regarding higher rates of return to play and lower refracture rate influenced our decision to recommend surgery. We also considered that his position as a wide receiver and that the injury affected his nondominant upper extremity would impart more stability than the same injury in the dominant arm of a throwing athlete. In this case, the inferior cortex was found to be intact intraoperatively. A 3.5-mm plate was contoured to the superior surface of the clavicle. He was placed in a sling and placed in the standard postoperative protocol. He attended daily therapy sessions with the team athletic trainers.

Radiographs at 8 weeks postoperatively showed fracture union (**Fig. 3**), and he demonstrated full strength and range of motion in therapy. He participated in receiving



**Fig. 2.** Anteroposterior clavicle view showing left clavicle fracture.



**Fig. 3.** Anteroposterior clavicle radiograph at 8 weeks postoperatively, showing reduction and fixation with a 3.5-mm superior plate and screws and consolidation at the fracture site.

drills prior to return to game situations. He was cleared for return to football for the team's final 4 games of the regular season. He ultimately returned to his previous level of performance, catching two passes for 67 yards receiving in the team's end-of-season bowl game at just under 4 months postoperatively.

## SUMMARY

Clavicle fractures are some of the most common fractures among athletes. The type of sport is directly related to fracture risk, with athletes participating in football, soccer, snowboarding, bicycling, wrestling, and snow skiing having the highest risk of clavicle injury. Surgical versus nonoperative treatment of clavicle fractures in the athlete is determined primarily from physical examination and imaging studies, with special consideration of the importance of attempting return to sport within the same season, if feasible. Surgical strategies for successful early return to sport and prevention of reinjury include early timing of surgery, maximizing the biomechanical strength of the fixation construct, and a graduated progression through rehabilitation protocols. Guidelines for return to athletic competition are influenced by radiographic and clinical evidence of fracture healing, restoration of functional range of motion and strength, and sport-specific drills.

## CLINICS CARE POINTS

### Pearls

- For displaced fractures, surgical intervention results in higher rates of return to play, shorter return-to-play times, and lower incidence of refracture than nonoperative treatment.
- Use of a 3.5-mm superior contoured plate or a dual-plate construct has been shown to provide superior resistance to bending and torsional forces compared with intramedullary fixation.
- When plate removal is indicated, refracture risk is higher than that of intramedullary implant removal but remains low overall.

### Pitfalls

- While pressure to accelerate return to play may be applied by the athlete and his or her parents, coaches, and/or agents, resumption of contact before radiographic and clinical healing carries an increased risk of reinjury that diminishes with increased time from stabilization.
- Conservative treatment avoids risks of surgery on the front end but results in increased risks of symptomatic nonunion and refracture, which double loss of playing time and may ultimately require surgery.

### DISCLOSURE

K.J.C. reports speaking fees from Arthrex, Inc. and Smith & Nephew and research support from Arthrex, Inc. and Food and Drug Administration (FDA) outside the submitted work. The other authors have no disclosures.

### REFERENCES

1. Nordqvist A, Petersson C. The incidence of fractures of the clavicle. *Clin Orthop Relat Res* 1994;300:127–32.
2. Robinson CM. Fractures of the clavicle in the adult. Epidemiology and classification. *J Bone Joint Surg Br* 1998;80(3):476–84.
3. Postacchini F, Gumina S, De Santis P, et al. Epidemiology of clavicle fractures. *J Shoulder Elbow Surg* 2002;11(5):452–6.
4. Court-Brown CM, Wood AM, Aitken S. The epidemiology of acute sports-related fractures in adults. *Injury* 2008;39(12):1365–72.
5. DeFroda SF, Lemme N, Kleiner J, et al. Incidence and mechanism of injury of clavicle fractures in the NEISS database: Athletic and non athletic injuries. *J Clin Orthop Trauma* 2019;10(5):954–8.
6. Van Tassel D, Owens BD, Pointer L, et al. Incidence of clavicle fractures in sports: analysis of the NEISS Database. *Int J Sports Med* 2014;35(1):83–6.
7. Aitken SA, Watson BS, Wood AM, et al. Sports-related fractures in South East Scotland: an analysis of 990 fractures. *J Orthop Surg* 2014;22(3):313–7.
8. Kaplan LD, Flanigan DC, Norwig J, et al. Prevalence and variance of shoulder injuries in elite collegiate football players. *Am J Sports Med* 2005;33(8):1142–6.
9. Twomey-Kozak J, Whitlock KG, O'Donnell JA, et al. Epidemiology of Sports-Related Clavicle Fractures in the United States: Injuries From 2015 to 2019. *Orthop J Sports Med* 2022;10(10). <https://doi.org/10.1177/23259671221126553>. 23259671221126553.
10. McCarthy MM, Bihl JH, Frank RM, et al. Epidemiology of Clavicle Fractures Among US High School Athletes, 2008-2009 Through 2016-2017. *Orthop J Sports Med* 2019;7(7). <https://doi.org/10.1177/2325967119861812>. 2325967119861812.
11. Ishimaru D, Ogawa H, Wakahara K, et al. Hip pads reduce the overall risk of injuries in recreational snowboarders. *Br J Sports Med* 2012;46(15):1055–8.
12. Oberle L, Pierpoint L, Spittler J, et al. Epidemiology of Clavicle Fractures Sustained at a Colorado Ski Resort. *Orthop J Sports Med* 2021;9(5). 23259671211006722.
13. Kim S, Endres NK, Johnson RJ, et al. Snowboarding injuries: trends over time and comparisons with alpine skiing injuries. *Am J Sports Med* 2012;40(4):770–6.
14. van der Ven DJC, Timmers TK, Broeders IAMJ, et al. Displaced Clavicle Fractures in Cyclists: Return to Athletic Activity After Anteroinferior Plate Fixation. *Clin J Sport Med* 2019;29(6):465–9.

15. Fancourt HS, Vrancic S, Neeman T, et al. Serious cycling-related fractures in on and off-road accidents: A retrospective analysis in the Australian Capital Territory region. *Injury* 2022;53(10):3233–9.
16. Bigdon SF, Hecht V, Fairhurst PG, et al. Injuries in alpine summer sports - types, frequency and prevention: a systematic review. *BMC Sports Sci Med Rehabil* 2022;14(1):79.
17. Konarski A, Walmsley M, Jain N. Return to competition following clavicle fractures in professional road cyclists. *J Orthop* 2022;34:100–3.
18. Edler C, Droste JN, Anemüller R, et al. Injuries in elite road cyclists during competition in one UCI WorldTour season: a prospective epidemiological study of incidence and injury burden. *Phys Sportsmed* 2023;51(2):129–38.
19. Haeberle HS, Navarro SM, Power EJ, et al. Prevalence and Epidemiology of Injuries Among Elite Cyclists in the Tour de France. *Orthop J Sports Med* 2018; 6(9). 2325967118793392.
20. Herteleer M, Winckelmans T, Hoekstra H, et al. Epidemiology of clavicle fractures in a level 1 trauma center in Belgium. *Eur J Trauma Emerg Surg* 2018;44(5): 717–26.
21. Kugelman D, Paoli A, Mai D, et al. Urban Cycling Expansion is Associated with an Increased Number of Clavicle Fractures. *Bull Hosp Jt Dis* 2020;78(2):101–7.
22. Nowak J, Mallmin H, Larsson S. The aetiology and epidemiology of clavicular fractures. A prospective study during a two-year period in Uppsala, Sweden. *Injury* 2000;31(5):353–8.
23. Stanley D, Trowbridge EA, Norris SH. The mechanism of clavicular fracture. A clinical and biomechanical analysis. *J Bone Joint Surg Br* 1988;70(3):461–4.
24. Rowe CR. An atlas of anatomy and treatment of midclavicular fractures. *Clin Orthop Relat Res* 1968;58:29–42.
25. Aitken SA. The epidemiology of fractures of the upper limb, lower limb and pelvis in adults. University of Edinburgh; 2013.
26. Allman FL Jr. Fractures and ligamentous injuries of the clavicle and its articulation. *J Bone Joint Surg Am* 1967;49(4):774–84.
27. Neer CS 2nd. Fractures of the distal third of the clavicle. *Clin Orthop Relat Res* 1968;58:43–50.
28. Fozzato S, Petrucci QA, Passeri A, et al. Brachial plexus paralysis in a patient with clavicular fracture, medico-legal implications. *Acta Biomed* 2022;93(4):e2022285.
29. Buchanan DAS, Owen D, Angliss R, et al. Acute subclavian artery occlusion with associated clavicle fracture managed with bypass graft alone. *BMJ Case Rep* 2018;2018. bcr2018224719.
30. Sandstrom CK, Gross JA, Kennedy SA. Distal clavicle fracture radiography and treatment: a pictorial essay. *Emerg Radiol* 2018;25(3):311–9.
31. Backus JD, Merriman DJ, McAndrew CM, et al. Upright versus supine radiographs of clavicle fractures: does positioning matter? *J Orthop Trauma* 2014; 28(11):636–41.
32. Yap JJ, Curl LA, Kvitne RS, et al. The value of weighted views of the acromioclavicular joint. Results of a survey. *Am J Sports Med* 1999;27(6):806–9.
33. Canadian Orthopaedic Trauma Society. Nonoperative treatment compared with plate fixation of displaced midshaft clavicular fractures. A multicenter, randomized clinical trial. *J Bone Joint Surg Am* 2007;89(1):1–10.
34. Hall JA, Schemitsch CE, Vicente MR, et al. Operative Versus Nonoperative Treatment of Acute Displaced Distal Clavicle Fractures: A Multicenter Randomized Controlled Trial. *J Orthop Trauma* 2021;35(12):660–6.

35. Postacchini R, Gumina S, Farsetti P, et al. Long-term results of conservative management of midshaft clavicle fracture. *Int Orthop* 2010;34(5):731–6.
36. Robertson GA, Wood AM. Return to sport following clavicle fractures: a systematic review. *Br Med Bull* 2016;119(1):111–28.
37. Robinson CM, Goudie EB, Murray IR, et al. Open reduction and plate fixation versus nonoperative treatment for displaced midshaft clavicular fractures: a multi-center, randomized, controlled trial. *J Bone Joint Surg Am* 2013;95(17):1576–84.
38. McKee RC, Whelan DB, Schemitsch EH, et al. Operative versus nonoperative care of displaced midshaft clavicular fractures: a meta-analysis of randomized clinical trials. *J Bone Joint Surg Am* 2012;94(8):675–84.
39. Pujalte GG, Housner JA. Management of clavicle fractures. *Curr Sports Med Rep* 2008;7(5):275–80.
40. Vora D, Baker M, Pandarinath R. Impact of Clavicle Fractures on Return to Play and Performance Ratings in NFL Athletes. *Clin J Sport Med* 2019;29(6):459–64.
41. Morgan RJ, Bankston LS Jr, Hoenig MP, et al. Evolving management of middle-third clavicle fractures in the National Football League. *Am J Sports Med* 2010;38(10):2092–6.
42. Ranalletta M, Rossi LA, Piuze NS, et al. Return to sports after plate fixation of displaced midshaft clavicular fractures in athletes. *Am J Sports Med* 2015;43(3):565–9.
43. Meisterling SW, Cain EL, Fleisig GS, et al. Return to athletic activity after plate fixation of displaced midshaft clavicle fractures. *Am J Sports Med* 2013;41(11):2632–6.
44. Jack RA 2nd, Sochacki KR, Navarro SM, et al. Performance and Return to Sport After Clavicle Open Reduction and Internal Fixation in National Football League Players. *Orthop J Sports Med* 2017;5(8). 2325967117720677.
45. Jack RA 2nd, Sochacki KR, Navarro SM, et al. Performance and Return to Sport After Nonoperative Treatment of Clavicle Fractures in National Football League Players. *Orthopedics* 2017;40(5):e836–43.
46. Hebert-Davies J, Agel J. Return to elite-level sport after clavicle fractures. *BMJ Open Sport Exerc Med* 2018;4(1):e000371.
47. Hulsmans MH, van Heijl M, Houwert RM, et al. Surgical fixation of midshaft clavicle fractures: A systematic review of biomechanical studies. *Injury* 2018;49(4):753–65.
48. Ferguson DP, Baker HP, Dillman D, et al. Dual mini-fragment plate fixation of midshaft clavicle fractures is biomechanically equivalent to anatomic pre-contoured plating [published online ahead of print, 2022 Apr 12]. *Eur J Orthop Surg Traumatol* 2022. <https://doi.org/10.1007/s00590-022-03268-1>.
49. Fritz EM, van der Meijden OA, Hussain ZB, et al. Intramedullary Fixation of Midshaft Clavicle Fractures. *J Orthop Trauma* 2017;31(Suppl 3):S42–4.
50. Houwert RM, Smeeing DP, Ahmed Ali U, et al. Plate fixation or intramedullary fixation for midshaft clavicle fractures: a systematic review and meta-analysis of randomized controlled trials and observational studies. *J Shoulder Elbow Surg* 2016;25(7):1195–203.
51. Tsai SW, Ma HH, Hsu FW, et al. Risk factors for refracture after plate removal for midshaft clavicle fracture after bone union. *J Orthop Surg Res* 2019;14(1):457.
52. Park HY, Kim SJ, Sur YJ, et al. Refracture after locking compression plate removal in displaced midshaft clavicle fractures after bony union: a retrospective study. *Clin Shoulder Elb* 2021;24(2):72–9.
53. Rabe SB, Oliver GD. Clavicular fracture in a collegiate football player: a case report of rapid return to play. *J Athl Train* 2011;46(1):107–11.