

Gordon I. Groh
Editor

Clavicle Injuries

A Case-Based Guide to
Diagnosis and Treatment

 Springer

Clavicle Injuries

Gordon I. Groh
Editor

Clavicle Injuries

A Case-Based Guide to Diagnosis
and Treatment

 Springer

Editor

Gordon I. Groh
Mission Orthopedics
Mission Health
One Hospital Drive
Asheville, NC, USA

ISBN 978-3-319-52236-4 ISBN 978-3-319-52238-8 (eBook)
DOI 10.1007/978-3-319-52238-8

Library of Congress Control Number: 2017933978

© Springer International Publishing AG 2018

This work is subject to copyright. All rights are reserved by the Publisher, whether the whole or part of the material is concerned, specifically the rights of translation, reprinting, reuse of illustrations, recitation, broadcasting, reproduction on microfilms or in any other physical way, and transmission or information storage and retrieval, electronic adaptation, computer software, or by similar or dissimilar methodology now known or hereafter developed.

The use of general descriptive names, registered names, trademarks, service marks, etc. in this publication does not imply, even in the absence of a specific statement, that such names are exempt from the relevant protective laws and regulations and therefore free for general use.

The publisher, the authors and the editors are safe to assume that the advice and information in this book are believed to be true and accurate at the date of publication. Neither the publisher nor the authors or the editors give a warranty, express or implied, with respect to the material contained herein or for any errors or omissions that may have been made. The publisher remains neutral with regard to jurisdictional claims in published maps and institutional affiliations.

Printed on acid-free paper

This Springer imprint is published by Springer Nature
The registered company is Springer International Publishing AG
The registered company address is: Gewerbestrasse 11, 6330 Cham, Switzerland

Preface

A surgical textbook devoted only to clavicle injuries would have been unthinkable in the twentieth century. Clavicle injuries were common but had long been understood to be predominately treated nonsurgically. The results of these injuries were uniformly reported to be good and any debate centered on the type and duration of immobilization.

The close of the twentieth century saw the rise of evidence-based medicine and a reinvestigation of the previously published reports of clavicle injuries. Investigators compared their results to historical controls and found considerable divergence in fracture healing and other variables. Current investigators have drawn attention to the considerable heterogeneity of earlier reports, which often included pediatric populations which demonstrate better results in fracture healing than adult populations.

Evidence-based medicine included the emergence of outcome measurements across the orthopedic spectrum. While these measures are imperfect, they attempt to infuse a component into our treatment process which was missing in medical treatment. These measures continue to push the boundaries of orthopedic treatment and introduce new concepts. Emerging concepts include clavicle malunion with resultant scapular dyskinesis—an oxymoron from historical reports which viewed all clavicle fractures with union as success.

This textbook emerges from the ashes of twentieth-century expert opinion and relies on biomechanics, anatomy, radiography, evidence-based medicine, and outcome studies to reach the conclusions relayed in each chapter. The state of the art of treatment of clavicle injuries is not static by any means and considerable debate exists regarding the diagnosis and proper treatment of these injuries. This debate is a healthy sign of the orthopedic community, where diversity of opinions based on science leads to a relentless improvement in patient outcomes.

Although the textbook is centered on science and data, it would be foolhardy to ignore the power of a story in human existence and medical treatment. Oral stories have dominated human existence and are as powerful as the mastery of fire in the development of civilizations. The importance of a story has been strongly interwoven in medicine by the use of case conferences, reviews, and didactic sessions. Although data is a strong lure, often the story of a medical treatment is the hook

which engages changes in behavior and treatment. In keeping with this oral tradition, we have sought to augment the scientific principles of each chapter and include selective cases at the end of each chapter.

In the lineage of human history, failures are considered orphans. This textbook has reached success and by some definition springs from many fathers. Springer publishing of course is the original source of this creation and has been wonderful in my first stint as a book editor. I am indebted to Kristopher Spring at Springer for the confidence in placing me at the helm of the publication. Patrick Carr has accompanied the text from its recruitment phase through production with guidance that insured equanimity among the authors and insured delivery of a quality work on time—a difficult task which Patrick handled adeptly.

The editing world brims with horror stories of multiauthor texts and the difficulties in gaining an acceptance and producing a book chapter. Happily, this was far from the truth in this text. I asked many of my professional friends to produce a chapter and leaned heavily on them for suggestions of other sources. The authors of each chapter are recognized experts in their field and have each produced elegant works which required only the lightest touch of editing. The quality of work produced may have spoiled me forever as an editor going forward.

The seminal event in my professional life was my time as a fellow for Dr. Charles A. Rockwood, Jr. Dr. Rockwood provided an environment which produced innovation and education. Although incredibly prescient about a number of topics, he extolled the value of investigation and the scientific process. Being identified as a Rockwood Fellow is still one of my proudest academic achievements and biggest influences. The corollary of training with Dr. Rockwood has been the blessing to have many mentors and friends from the fellowship in my life, including Dr. Carl Basamania, Dr. Wayne Burkhead, Dr. Federico Grassi, Dr. Michael Simoni, Dr. Gerald Williams, and Dr. Michael Wirth. My life is much richer due to their teaching and friendship.

Family of course is the other ingredient in this creation. I am fortunate to have both of my parents (Don and June Groh) extremely vigorous and involved in their 80s. They forged a spirit of aspiration in lockstep with the value of hard work which has served well throughout my life. My academic interests I attribute to my uncle and aunt (Nancy and John E. Groh, PhD) who helped guide my trajectory and have always shown interest in my endeavors.

All of this would ring hollow if Susan, my wife of 25 years, had not burst into my life. She has always had the utmost confidence in me, even when what I was doing seemed counterintuitive. She endured a fellowship in hand surgery after I had completed a shoulder fellowship and provided a pathway to achieve an MBA via the Kenan-Flagler School of Business at the University of North Carolina, Chapel Hill. She is the glue which holds our family together and produced the three most precious gifts—our children Griffin, Parker, and Bailey. It is a joy to watch my children achieve and flourish—I am extremely proud of each of them. My wife and children have been my anchor through my life and have freely given their time, love, and understanding. I love, honor, and cherish each of them and acknowledge how truly fortunate I am.

Contents

1	Anatomy of the Clavicle and Its Articulations	1
	Firas I. Kawtharani and Samer S. Hasan	
2	Biomechanics of the Clavicle.....	19
	Sergio Gutiérrez, Ioannis P. Pappou, Jazmine Aira, Peter Simon, and Mark A. Frankle	
3	Evaluation of Clavicle Injuries	33
	John G. Horneff III, Surena Namdari, and Gerald R. Williams	
4	Imaging of the Clavicle	53
	Harry G. Greditzer IV, Ian D. Hutchinson, and Hollis G. Potter	
5	Anesthesia for Clavicle Fractures.....	87
	Joshua Dooley and Gavin Martin	
6	Nonoperative Clavicle Fractures	95
	Michael R. Koerner and Kyle J. Jeray	
7	Midshaft Clavicle Injuries: Operative Management.....	111
	Mark A. Mighell, Jonathan Clark, and Rafael Serrano-Riera	
8	Acromioclavicular Joint Injuries.....	123
	Kyle P. Lavery, Stephen D. Daniels, and Laurence D. Higgins	
9	Sternoclavicular Joint Injuries	145
	Gordon I. Groh	
10	Distal Clavicle and Medial Clavicle Fractures	165
	Michael D. McKee and Justin L. Hodgins	
11	Outcomes of Clavicle Injuries.....	189
	Nathan T. Formaini and Jonathan C. Levy	
12	Pediatric Clavicle Injuries.....	205
	Katherine C. Faust, Robert K. Lark, and Fraser J. Leversedge	

13 Sports-Related Clavicle Injuries..... 215
G. Bradley Bookatz and Spero G. Karas

14 Complications of Clavicle Fractures 223
Scott P. Stephens and Michael A. Wirth

Index..... 237

Contributors

Jazmine Aira, MS Foundation for Orthopaedic Research and Education, Tampa, FL, USA

G. Bradley Bookatz, MD Department of Orthopaedic Surgery, Munster Community Hospital, Munster, IN, USA

Jonathan Clark, MD Shoulder and Elbow Service, Florida Orthopaedic Institute, Tampa, FL, USA

Stephen D. Daniels, BS Division of Sports Medicine, Department of Orthopedic Surgery, Brigham and Women's Hospital, Boston, MA, USA

Joshua Dooley, MD Department of Anesthesiology, Duke University Hospital, Durham, NC, USA

Katherine C. Faust, MD Department of Orthopaedic Surgery, Duke University, Durham, NC, USA

Nathan T. Formaini, DO Armstrong Orthopedic Associates, Kittanning, PA, USA

Mark A. Frankle, MD Florida Orthopaedic Institute, Tampa, FL, USA

Harry G. Greditzer IV, MD, MSc Department of Radiology and Imaging, Hospital for Special Surgery, New York, NY, USA

Gordon I. Groh, MD Mission Orthopedics, Mission Health, One Hospital Drive, Asheville, NC, USA

Sergio Gutiérrez, PhD Foundation for Orthopaedic Research and Education, Tampa, FL, USA

Samer S. Hasan, MD, PhD Mercy Health—Cincinnati SportsMedicine and Orthopaedic Center, Cincinnati, OH, USA

Laurence D. Higgins, MD, MBA Division of Sports Medicine, Department of Orthopedic Surgery, Brigham and Women's Hospital, Boston, MA, USA

Justin L. Hodgins, MD Upper Extremity Reconstruction and Trauma, St. Michael's Hospital, University of Toronto, Toronto, ON, Canada

John G. Horneff III, MD Department of Orthopaedic Surgery, The Rothman Institute, The Sidney Kimmel Medical College at Thomas Jefferson University, Philadelphia, PA, USA

Ian D. Hutchinson, MD Department of Sports and Shoulder Surgery, Hospital for Special Surgery, New York, NY, USA

Kyle J. Jeray, MD Greenville Health System, Greenville, SC, USA

Spero G. Karas, MD Division of Sports Medicine, Department of Orthopedic Surgery, Emory University, Atlanta, GA, USA

Firas I. Kawtharani, MD Mercy Health—Cincinnati Sports Medicine and Orthopaedic Center, Cincinnati, OH, USA

Michael R. Koerner, MD Greenville Health System, Greenville, SC, USA

Robert K. Lark, MD Department of Orthopaedic Surgery, Duke University, Durham, NC, USA

Kyle P. Lavery, MD Division of Sports Medicine, Department of Orthopaedic Surgery, Massachusetts General Hospital, Boston, MA, USA

Fraser J. Leversedge, MD Department of Orthopaedic Surgery, Duke University, Durham, NC, USA

Jonathan C. Levy, MD Holy Cross Orthopedic Institute, Fort Lauderdale, FL, USA

Gavin Martin, MB, ChB, DA, FRCA Department of Anesthesiology, Duke University, Durham, NC, USA

Michael D. McKee, MD Division of Orthopaedics, Department of Surgery, St. Michael's Hospital, University of Toronto, Toronto, ON, Canada

Mark A. Mighell, MD Florida Orthopaedic Institute, Tampa, FL, USA

Surena Namdari, MD, MSc Department of Orthopaedic Surgery, The Rothman Institute, The Sidney Kimmel Medical College at Thomas Jefferson University, Philadelphia, PA, USA

Ioannis P. Pappou, MD Florida Orthopaedic Institute, Tampa, FL, USA

Hollis G. Potter, MD Department of Radiology and Imaging, Hospital for Special Surgery, Weill Medical College of Cornell University, New York, NY, USA

Rafael Serrano-Riera, MD Orthopaedic Trauma Service, Florida Orthopaedic Institute, Tampa, FL, USA

Peter Simon, PhD Foundation for Orthopaedic Research and Education, Tampa, FL, USA

Scott P. Stephens, MD Fondren Orthopedic Group, Houston, TX, USA

Gerald R. Williams MD Department of Orthopaedic Surgery, The Rothman Institute, The Sidney Kimmel Medical College at Thomas Jefferson University, Philadelphia, PA, USA

Michael A. Wirth, MD University of Texas Health Science Center at San Antonio, San Antonio, TX, USA

Chapter 1

Anatomy of the Clavicle and Its Articulations

Firas I. Kawtharani and Samer S. Hasan

Background

The clavicle is a unique bone that connects the axial skeleton to the shoulder girdle via the sternum medially and the scapula laterally. Consequently, the clavicle functions as a strut and also provides an anchor point for glenohumeral, acromioclavicular, and scapulothoracic motion [1]. It also provides a mechanical barrier that protects crucial neurovascular structures. The clavicle is a mostly subcutaneous bone and, consequently, is vulnerable to traumatic injuries, such as fractures and separations. Additionally, it is subject to various gender, ethnic, and side-specific variations, which has implications for surgical repair of fractures and separations [2]. In the following chapter, we will attempt to expand on the basic and clinical anatomy of this complex bone.

Osteology of the Clavicle

The clavicle is a long and slender bone with a double curve or “S” shape. Its medial two-thirds is rather wide and tubular, convex anteriorly, and articulates with the clavicular notch of the sternal manubrium at the sternoclavicular joint. The lateral one-third is flattened, concave anteriorly, and articulates with the acromion process of the scapula to form the acromioclavicular joint. The clavicle has a medial and a lateral process, each with an articular surface. Bony anatomic landmarks characterize the shaft such as the rhomboid fossa, which is present medially in one-third of the population, precisely on the inferior surface of the clavicle where the

F.I. Kawtharani, M.D. (✉) • S.S. Hasan, M.D., Ph.D.
Mercy Health—Cincinnati SportsMedicine and Orthopaedic Center,
10663 Montgomery Rd., Cincinnati, OH 45242, USA
e-mail: firas.kawtharani@gmail.com; s1663h@yahoo.com

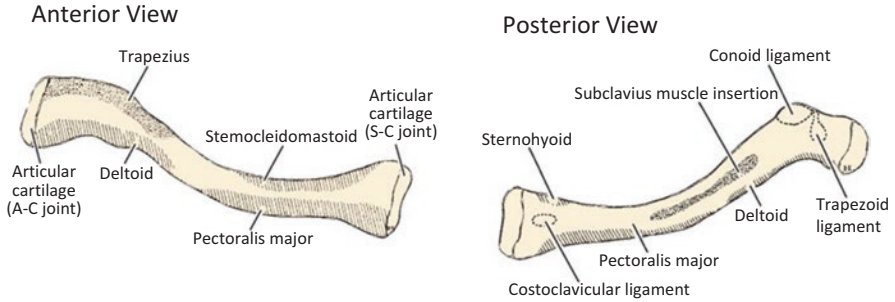


Fig. 1.1 Illustration depicting the bony anatomy of the clavicle, with anterior and posterior views showing both articular ends and the important muscle and ligament attachments along its length. (Borrowed from Rockwood C, Matsen F, Wirth M, Lippitt S. *The Shoulder*, Volume 1, page 33–100, 4th edition. Saunders; Philadelphia, PA. 2009)

costoclavicular ligaments insert [3]. In a smaller percentage of individuals, the clavicle contains an articular surface that engages the first rib. The subclavian groove is located in the middle inferior shaft where the subclavius muscle has a fleshy insertion [4]. The lateral aspect of the clavicle may carry a coracoclavicular process containing bony impressions for the conoid and trapezoid ligaments (Fig. 1.1) [5].

The average length of the clavicle is around 15 cm, but this varies according to laterality, gender, ethnicity, and body height [6]. Overall, the clavicle is longer, wider, and thicker in men [7]. Mathieu et al. [8] defined the hourglass morphology of the clavicle using anatomical and two-dimensional CT (computed tomography) study. The study demonstrated intramedullary canal narrowing in the middle of the clavicle, in addition to a more pronounced medial curvature and larger epiphyseal diameter in men, in the axial plane. The left clavicle is wider and longer than the right one at most intervals [7]. The cortex of the clavicle is thinnest on the dorsal side at the acromial end and on the ventral side of the sternal end [2]. The importance of understanding the three-dimensional morphology of the clavicle as a prelude to establishing consistent therapeutic criteria for various clavicular pathologies cannot be understated.

Muscular Attachments

Several muscles attach to the clavicle along its length. The platysma is a thin broad muscle that originates in the subcutaneous tissue around the clavicle and attaches to the base of the mandible and angle of mouth. It is superficial to the cervical fascia. Although the platysma does not originate or attach on the clavicle, it must be divided when surgically approaching the middle one-third of the clavicle, such as during open reduction and internal fixation using a plate and screws construct. The superior surface of the clavicle is smooth and subcutaneous. The clavicular head of the pectoralis major muscle originates anteriorly on the medial two-thirds. Posterior to the pectoralis major, the clavicular head of the sternocleidomastoid originates at the

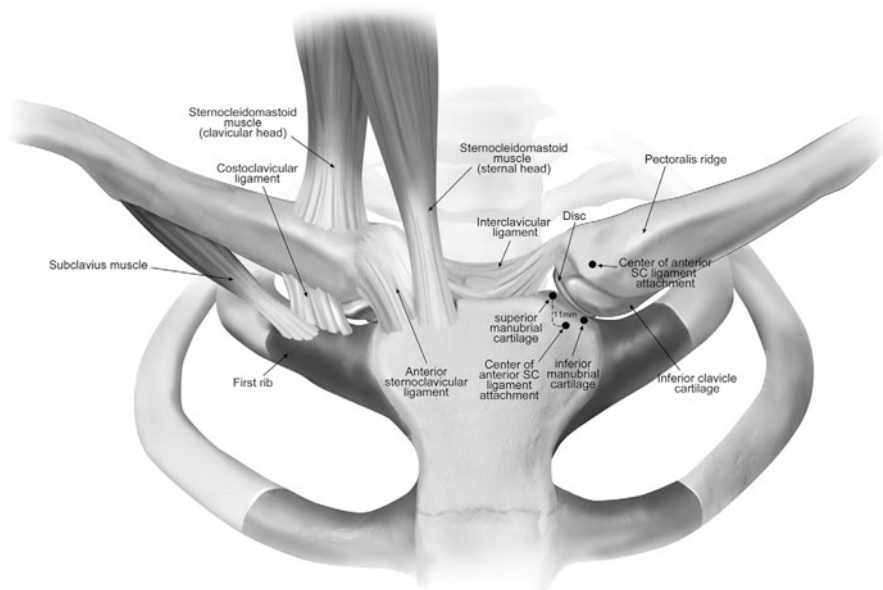


Fig. 1.2 Illustration depicting the anatomy of the medial clavicle and the sternoclavicular joint and demonstrating the robust ligamentous structures around the joint including the sternoclavicular, costoclavicular, and interclavicular ligaments. The subclavius muscle is seen inserting on the inferior surface of the clavicle along its groove. (Borrowed from Lee JT, Campbell KJ, Michalski MP, Wilson KJ, Spiegl UJ, Wijdicks CA, Millett PJ. Surgical anatomy of the sternoclavicular joint: a qualitative and quantitative anatomical study. *J Bone Joint Surg Am*, 96(19): e166, 2014)

middle one-third of the clavicle. Toward the lateral end of the clavicle, the origin of the deltoid muscle spans the whole anterior surface from superior to the inferior.

The only muscle that inserts on the superior surface of the clavicle is the upper portion of the trapezius muscle, which attaches posteriorly at the lateral end of the clavicle. In contrast to the superior surface of the clavicle, its inferior surface is rough, owing to a number of ligamentous attachments. Two muscles attach to the inferior surface the clavicle, the sternohyoid, and the subclavius muscles. The sternohyoid muscle originates on the most medial end of the inferior clavicle, its origin continues over the posterior surface of the sternoclavicular ligament and the sternum. In the middle one-third of the clavicle, the subclavius muscle inserts in a groove known as the subclavius groove, which serves as an attachment site of the clavipectoral fascia (Fig. 1.2) [4].

Ligamentous Attachments

Medially, and posterior to the sternohyoid muscle origin, there is often a rough depression referred to as the rhomboid fossa which, as discussed earlier, serves as the attachment site of the costoclavicular ligament. Laterally on the inferior surface

of the clavicle, the conoid and trapezoid ligaments form the coracoclavicular ligaments. The conoid tubercle serves as the attachment of the conoid ligament. Directly lateral to the conoid tubercle is the trapezoid line that serves as an attachment to the trapezoid ligament [5]. We will elaborate further on these important static stabilizers in the section on the anatomy of the acromioclavicular joint.

Neurovascular Anatomy

The anterior curve of the medial two-thirds of the clavicle provides a rigid arch under which the great vessels emerge as they exit the mediastinum toward the axilla. The subclavian and axillary vessels, the brachial plexus, and the lung are all located immediately posterior to the medial third of the clavicle. Hence the clavicle also functions as a bony protector of the neurovascular structures at the thoracic outlet.

Robinson et al. [9] used high definition photography of sagittal cadaveric sections to identify the neurovascular structures in closest proximity to the clavicle. On the medial aspect, the subclavian vein was at 4.8 mm from the posterior cortex of the clavicle. In the middle one-third of the clavicle, the brachial plexus was the closest structure, lying at an average of 15.2 mm from the posterior and inferior cortices. The subclavian vessels and the brachial plexus trunks and divisions were located more than two centimeters from the lateral clavicle.

Vascular Structures

The axillary vein joins the subclavian vein behind the medial one-third of the clavicle. The external jugular vein joins the subclavian vein at its confluence with the internal jugular vein at the level of the omohyoid fascia. Distal to that junction, the external jugular vein is joined on its lateral aspect by the transverse cervical and scapular veins and on its medial aspect by the anterior jugular vein. This confluence usually lies behind the angle formed by the sternocleidomastoid muscle and the clavicle [10]. The subclavian artery takes the same path as the brachial plexus lying in an anterior and inferior position progressing into the arm through the interval between the anterior and middle scalene muscles. It is divided into three segments in relation to the insertion of the scalenus anterior muscle. The vertebral artery branches out in the first segment, and the costocervical trunk and thyrocervical trunk branch out in the second segment. No branches are found in the third segment. The thyrocervical trunk gives rise to the transverse scapular artery and the suprascapular artery, which are mostly found in dissections involving the shoulder girdle (Fig. 1.3) [11].

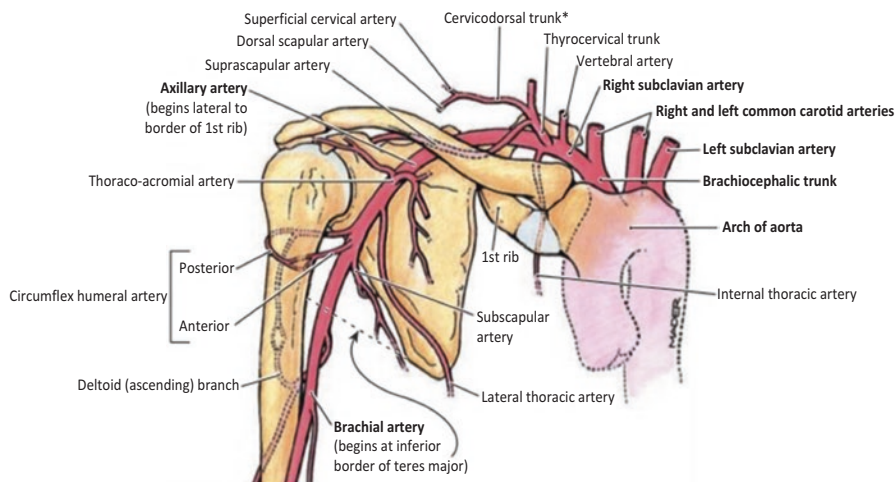


Fig. 1.3 Schematic representation of the main vascular branches of the subclavian artery arising around the clavicle. The subclavian artery continues as the axillary artery distally to supply the entire upper extremity. (Borrowed from Netter FH. Atlas of Human Anatomy, page 430, 6th edition. Saunders, Philadelphia, PA. 2014)

Neurological Structures

The brachial plexus lies posterior and superior to the subclavian artery at the level of the clavicle (Fig. 1.4). It forms from C5 through T1 cervical roots and exits the neck through the interval between the anterior and middle scalene. The five cervical roots form three trunks that separate into the anterior and posterior divisions. As the brachial plexus crosses beneath the clavicle it gives rise to three cords. The medial cord derives from the eighth cervical and first thoracic roots and forms a branch of the median nerve, the medial pectoral nerve, the entire ulnar nerve, and the medial cutaneous nerve. A lateral cord deriving from the fifth, sixth, and seventh cervical roots forms the lateral pectoral nerve, musculocutaneous nerve, and another branch of the median nerve. Both the medial and lateral cords are anterior whereas the posterior cord of the plexus forms the upper and lower subscapular, thoracodorsal, axillary, and radial nerves. The medial cord passes between the first rib and medial third of the clavicle. It is vulnerable to compression in this location so much so that severe trauma can lead to proximal ulnar neuropraxia [12].

Supraclavicular Nerves

The supraclavicular nerves emerge from C3 and C4 nerve roots of the cervical plexus and divide more distally into medial, intermediate, and lateral rami. Havet et al. [13] conducted a cadaveric study on the anatomy of the supraclavicular nerves

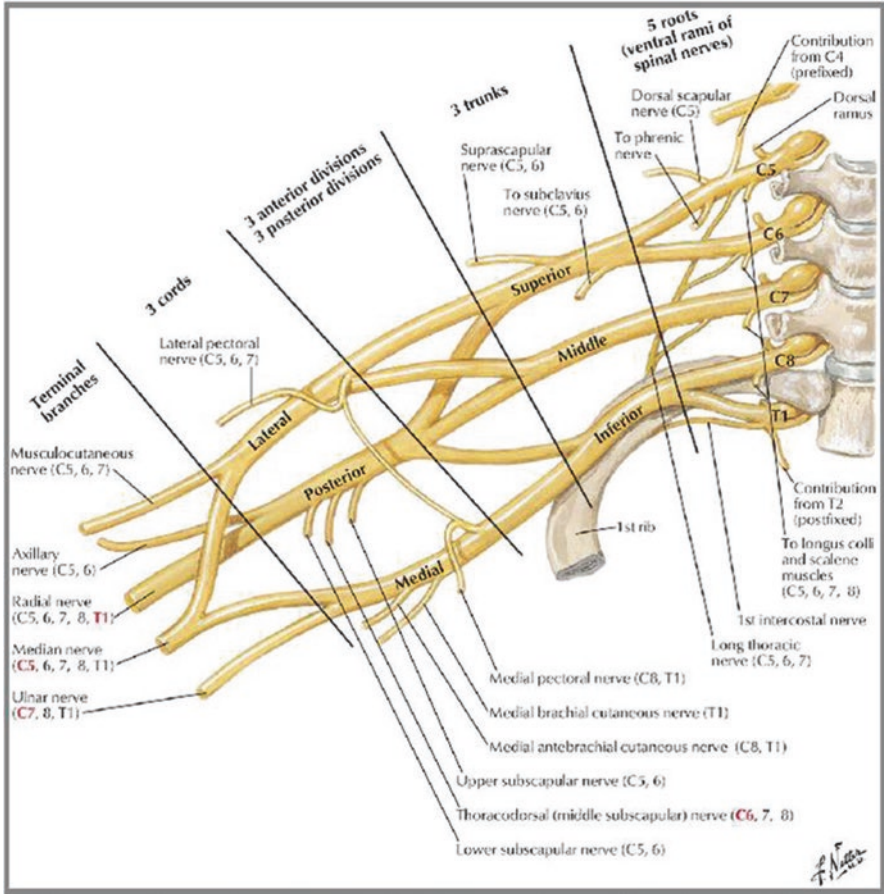


Fig. 1.4 Diagram of the brachial plexus, highlighting its complexity and formation from roots, trunks, divisions, cords, and branches. The clavicle serves as a solid barrier protecting the plexus from traumatic injury. (Borrowed from Agur AM, Dalley AF. *Grant's Atlas of Anatomy*, page 488, 13th edition. Lippincott, Williams and Wilkins. 2013)

describing the path of the intermediate and lateral rami from a common trunk behind the posterior border of the sternocleidomastoid. The intermediate ramus courses below platysma and divides into two or three terminal branches. The lateral ramus courses in a frontal plane toward the acromion process crossing the anterior belly of the trapezius. This ramus is probably the nerve that supplies the acromioclavicular joint as reported by Ebraheim et al. [14]. In about 6–10% of cases, the shaft of the clavicle has an accessory osseous canal, called the *canalis nervi supraclavicularis*, which allow a ramus of the medial supraclavicular nerve to traverse to the chest [15].

Information regarding the anatomy of the supraclavicular nerves may help in preventing potential injury to these branches during surgery about the clavicle, especially during open reduction and internal fixation of midshaft clavicle fractures.

The supraclavicular nerves are pure sensory nerves that supply sensation over the clavicle, the anteromedial shoulder, and the proximal chest. Although the precise locations of the principal rami and terminal branches are variable, there are safe zones extending 2.7 cm from the medial end of the clavicle and 1.9 cm from the lateral end that are devoid of any suprascapular nerve branches, according to a cadaveric study by Nathe et al. [16]. Nevertheless, preserving branches of the supraclavicular nerve remains a major challenge during the surgical approach to the clavicle because these lie in close proximity to its anterior surface. Even when the branches are identified they are often injured from repetitive stretch due to retraction or manipulation. As a result, incisional and chest wall numbness are reported in 10–29% of patients following plating of clavicular fractures [16].

Blood Supply to the Clavicle

The main blood supply of the clavicle is periosteal involving mainly the anterior and superior surfaces [13]. A secondary blood supply is intramedullary and canalicular, but this is of secondary importance. The prominent periosteal perfusion underscores the importance of minimizing dissection and avoiding periosteal stripping during the treatment of clavicle fractures, whether by intra-medullary or plate fixation.

Clavicle Biomechanics

The clavicle serves as a point of insertion for two muscles: the trapezius and subclavius and the point of origin for four muscles: the deltoid, pectoralis, sternocleidomastoid, and sternohyoid. However, the biomechanical role of the clavicle, in terms of overall shoulder motion and strength is not entirely understood. Proponents of total clavicular resection during tumor surgery or after multiple failed fracture surgeries point to the absence of substantial functional deficits postoperatively, if claviclectomy is performed with careful muscle repair.

However, the clavicle functions as a strut that allows shoulder motions such as cross body adduction and internal rotation, and also serves as a bony arch that protects major neurovascular structures. In fact, the clavicle rotates 45° with full shoulder abduction but for only 5°–8° relative to the acromion due to the synchronous scapuloclavicular motion [17]. By assuming the role of a strut, the clavicle permits the scapulohumeral and the scapulothoracic muscles to work at their optimal lever arms, thereby improving muscle efficiency and minimizing energy expenditure and muscle fatigue.

In addition, the clavicle serves a suspensory role that prevents the shoulder from drooping down due to the weight of the arm and avoids the recruitment of stabilizing muscles such as the trapezius from overcompensating to level both shoulder girdles. Thus, it largely contributes to the superior shoulder suspensory complex

from which the upper extremity is suspended [18]. As a result, the clavicle is clearly an integral part of the kinetic chain responsible for an effective throwing mechanism starting with the hips and abdominal core muscles moving to the scapula, which is partly stabilized by the clavicle, and ending with a well-centered glenohumeral shoulder motion [19].

Embryology and Fetal Development

Prenatal Development

The clavicle is the first bone to ossify in the developing embryo. In the embryonic period, the mesenchymal cells of the clavicular blastema separate into medial and lateral groups and then differentiate into osteoblasts following the fifth week of gestation [20]. Thereafter, primary ossification begins. The clavicle undergoes intra-membranous ossification initially, in contrast to axial long bones, which undergo endochondral ossification. The medial and lateral ossification centers fuse during week 7 of gestation. Subsequently, longitudinal growth of the clavicle becomes cartilaginous similar to axial long bones; acromial and sternal ossification centers lead to the formation of the acromioclavicular and sternoclavicular joints [20]. By studying cadaveric transverse and coronal sections, Ogata and Uthoff [21] confirmed these observations and noted that by week 8 of gestation, which corresponds to the beginning of the fetal period, the endochondral ossification and longitudinal growth of the clavicle has already commenced and the S-shaped morphology of the clavicle has been established [21]. These authors also determined that the less prominent medial growth center contributed more to overall clavicle length and curvature than the lateral growth center.

Periosteal bone formation is another determinant of clavicle development. It results in an increase in girth or cross-sectional area and subsequent remodeling of the clavicle. Garzon-Alvarado et al. [22] took a novel approach to the study of embryonic clavicle development and redefined it according to interplay between systemic, local biochemical, and mechanical factors. The first phase happens during the fifth week of gestation whereby mesenchymal cells forming the blastema at the center of the clavicle are prepared for ossification. The second phase during the sixth and seventh week dictates progression of ossification from the center to periphery following the same model whereby local mechanical and biochemical cues at the sternal and acromial ends promote cartilage formation and endochondral ossification.

Post-natal Development

As mentioned above, most of the longitudinal growth of the clavicle derives from the medial epiphysis, through the process of endochondral ossification [21]. The ossification of the medial growth plate starts at approximately 18 years of age and fuses with the remainder of the clavicle between the ages of 22 and 25 years.

The lateral epiphysis ossification is more vaguely defined and often confused with a lateral clavicle fracture owing to a poorly demarcated border with the shaft of the clavicle.

Joints: Acromioclavicular (AC) and Sternoclavicular (SC) Joints

The Acromioclavicular Joint

Anatomical and Functional Considerations

The acromioclavicular, or AC, joint is the sole articulation between the clavicle and the scapula, excepting the rare true coracoclavicular joint arising in less than 1% of the population. The acromioclavicular joint is a synovial diarthrodial joint with a meniscal homologue that usually degenerates by the fourth decade. The acromioclavicular joint height is 9 mm and its antero-posterior width is 19 mm, but this is variable in size. The width of the acromioclavicular joint is between 1 and 3 mm. Park et al. [23] used ultrasonography to demonstrate that the joint space is minimal during cross-body adduction and active compression maneuvers so that these appear to be the most specific in diagnosing acromioclavicular pathology. The acromioclavicular joint is inclined 50° in the axial plane and 12° in the coronal plane whereby the distal clavicle is oriented posterior and lateral while the acromion is medial and anterior [24]. Colegate-Stone et al. [25] analyzed cadaveric, CT, and radiographic data to classify the 3-D morphology of the AC joint as either flat, oblique, or curved. The volume of the acromioclavicular joint is quite small, given its linear measurements. According to Edelson et al. [26], the joint may accept 0.5–1.2 mL of fluid when injected under sonographic guidance (Fig. 1.5).

The acromioclavicular joint contains a meniscoid fibrocartilaginous disk. This disk composed of 75% water, 20% collagen, and 15% proteoglycan. Emura et al. [27] classified the acromioclavicular joint according to the intra-articular disk morphology (Fig. 1.6): type 1 has a complete articular disk, type 2 has an incomplete disk deficient inferiorly, and type 3 has no disk. The latter type may have an ellipsoid configuration that prevents rotational movement. The articular hyaline cartilage turns into fibrocartilage with age. The inferior part of the AC joint is weaker and more prone to degeneration [28].

The principal static stabilizers of the acromioclavicular joint are the AC ligaments and the joint capsule. The AC ligaments, mainly the superior and posterior components, resist movement in the axial plane including posterior displacement as well as rotation [24]. Posterior translation can lead to abutment against the scapular spine. The capsule and mainly its inferior part represent the primary restraint to anterior translation [5]. The acromioclavicular joint capsule inserts 2.8 mm from the medial edge of the acromion and 3.5 mm from the lateral edge of the clavicle [24].

The capsuloligamentous attachments about the AC joint have implications for AC joint resection arthroplasty or Mumford procedure, especially when this is

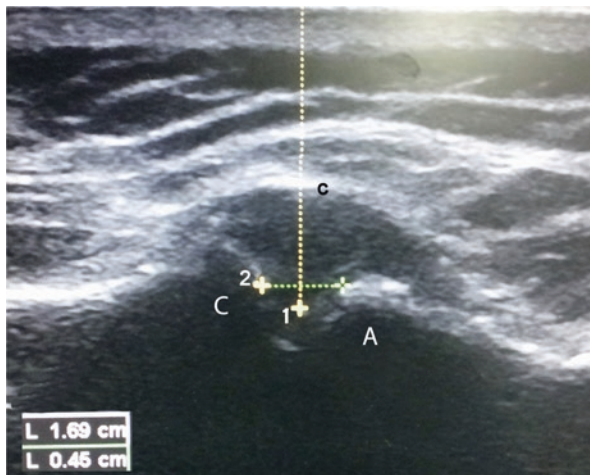


Fig. 1.5 Ultrasound image displaying the width and depth of the acromioclavicular (AC) joint. The AC joint was found to absorb around 1 mL of fluid upon repeated injections under ultrasound guidance. (Borrowed from Edelson G, Saffuri H, Obid E, Lipovsky E, Ben-David D. Successful injection of the acromioclavicular joint with use of ultrasound: anatomy, technique, and follow-up. *J Shoulder Elbow Surg*, 23(10): e243–250, 2014)

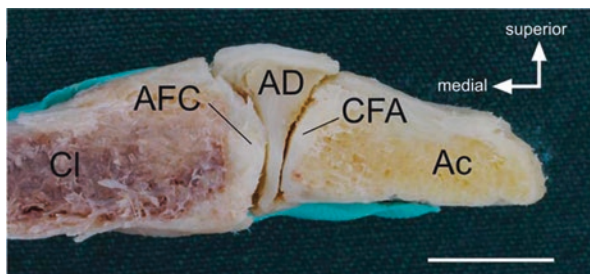


Fig. 1.6 Coronal cadaveric section showing a complete intra-articular disk that separates the convex clavicular and acromial ends. (Borrowed from Emura K, Arakawa T, Miki A, Terashima T. Anatomical observations of the human acromioclavicular joint. *Clin Anat*, 27(7): 1046–1052, 2014)

performed arthroscopically and without subsequent capsular imbrication or repair. Generous AC joint resection may lead to destabilization of the joint. Stine and Vangsness [24] have recommended limiting the amount of lateral clavicle resection during the Mumford procedure, by excising 2–3 mm from the acromial side and 3–4 mm from the clavicular side. Furthermore, the coracoacromial (CA) ligament does not contribute to stability of the acromioclavicular joint.

In addition to the static capsuloligamentous stabilizers, the deltoid, trapezius, and serratus anterior muscles represent the principal dynamic stabilizers of the AC joint [29]. The superior AC ligament blends with the deltotrachezial fascia to provide further dynamic stability.

The acromioclavicular joint is located subcutaneously and is subject to high impact loading during trauma. Consequently, injury to the acromioclavicular joint is exceedingly common and represents 9–12% of all shoulder girdle injuries, and up to 40–50% of shoulder injuries in athletes [17].

AC Joint Biomechanics and Kinematics

Scapular clearance for arm elevation is only possible through motion mainly rotation exerted at the level of the AC and SC joints. With full forward elevation there is a 5°–8° of true rotation at the AC joint [5].

AC Joint Neurovascular Anatomy

The acromial artery, a branch deriving from the deltoid artery, constitutes the main blood supply for the acromioclavicular joint after it perforates through the clavicopectoral fascia. The artery is named as such because branches from this artery perfuse the acromion as well. The lateral pectoral nerve, lateral ramus of the supraclavicular nerve [14], axillary nerve, and suprascapular nerves all contribute variably to innervating the acromioclavicular joint.

The Coracoclavicular Ligaments and Surgical Considerations

The distance between coracoid and clavicle ranges between 1.1 and 1.3 cm. The coracoclavicular ligaments, whose precise function and morphology have been carefully described, help maintain this distance. The conoid inserts at 2.5 cm posteromedial and the trapezoid at 4.5 cm anterolateral with respect to the lateral end of the clavicle (Fig. 1.7) [30]. The trapezoid covers the posterior half of the coracoid's dorsal surface while the conoid originates more posterior on the base. According to Harris et al. [31] the clavicular insertion of the conoid ligament was found to be twice as wide as its coracoid insertion, giving rise to its inverted cone shape. The trapezoid was three times thicker at its clavicular end but shows less narrowing of its width than the conoid [32]. Bursae can exist between these ligaments. The average length of the trapezoid ligament is 14–16 mm while the coronoid ligament is 10–11 mm [33].

Understanding the anatomy of the AC joint and coracoclavicular ligaments has implications for the diagnosis and treatment of AC joint separations. AC joint separations have been described and classified radiographically by Rockwood et al. (Fig. 1.8), and this classification remains commonly employed worldwide [34]. A recent study by Eschler et al. [35] confirmed anatomically the Rockwood classification. Acromioclavicular ligamentous disruptions, or type II injuries, resulted in

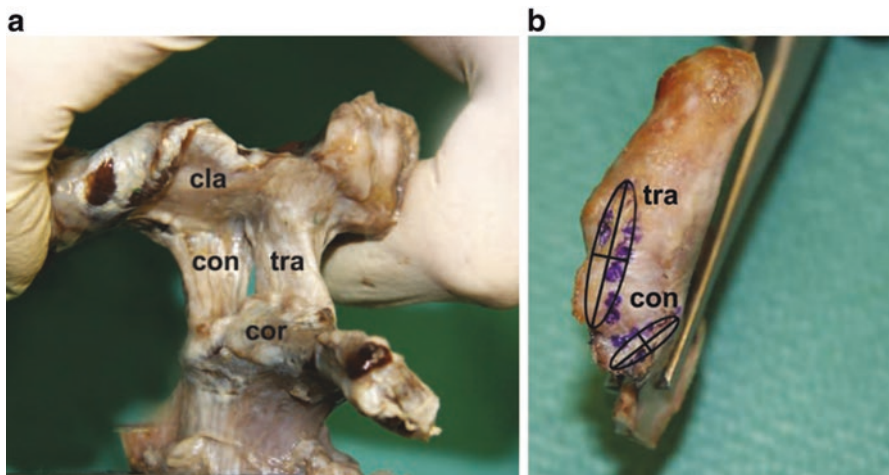


Fig. 1.7 (a) Cadaveric photo in the coronal plane showing grossly the posteromedial and anterolateral insertions of the conoid and trapezoid ligaments, respectively, on the coracoid process. (b) Cadaveric photo of the superior aspect of the coracoid process revealing the more prominent anterolateral footprint of the trapezoid in comparison to the more narrow posteromedial conoid footprint. (Borrowed from Salzman GM, Paul J, Sandmann GH, Imhoff AB, Schöttle PB. The coracoid insertion of the coracoclavicular ligaments. An anatomic study. *Am J Sports Med*, 36(12): 2392–2397, 2008)

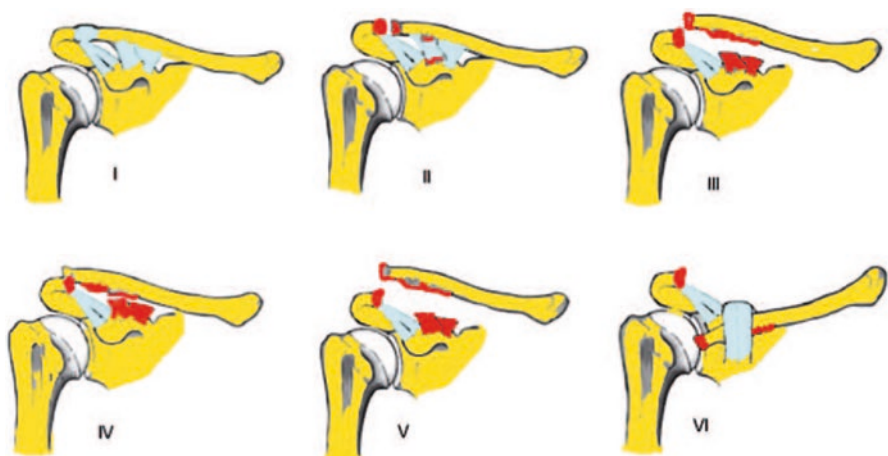


Fig. 1.8 Schematic representation of the Rockwood classification of AC joint separations. (I) AC sprain; (II) AC capsular disruption with coracoclavicular (CC) sprain; (III) Complete CC ligamentous injury with superior displacement, from 25 to 100%; (IV) Complete CC injury with posterior clavicular displacement through the deltatrapezial fascia; (V) Complete CC injury with superior displacement more than 100%; (VI) Complete CC injury with inferior clavicular (subcoracoid) displacement. (Borrowed from Rockwood CA. Injuries to the acromioclavicular joint. In: Rockwood CA, Freen DP, eds. *Fractures in adults*, vol 1, 2nd ed. Philadelphia: JB Lippincott, 1984:860)

widening of the acromioclavicular joint from 3.12 to 8.6 mm whereas the coracoclavicular distance remained stable. In contrast, type III injuries leading to disruption of the coracoclavicular ligaments resulted in dramatic increases in both the acromioclavicular and coracoclavicular distances to 16.7 mm and 20.6 mm, respectively. Thus in the absence of the acromioclavicular ligaments the coracoclavicular ligaments assume the role of resisting horizontal and vertical joint motion. The conoid ligament resists anterior and superior loading while the trapezoid ligament resists posterior loading [32].

The precise attachment sites of the conoid and trapezoid ligaments on the clavicle have important implications regarding the anatomic reconstruction of these ligaments. Rios et al. [36] defined the exact point of attachment of the conoid and trapezoid ligaments on the clavicle as a ratio of point of ligament insertion over the length of the clavicle. These ratios for conoid and trapezoid ligament attachments remained constant at 0.17 and 0.31, respectively, across gender, and are helpful for surgical planning.

As described elsewhere in this book the anatomic reconstruction of the coracoclavicular ligaments has been favored over non-anatomic repairs, such as the modified Weaver–Dunn procedure due to its superior biomechanical conformation [37]. In fact, the clavicle bone mass density and load to failure increases from lateral to medial in the clavicle therefore, far lateral fixation is prone to failure especially by graft pullout. Non-anatomic methods of coracoclavicular reconstruction are more prone to failure either because of suboptimal or excessively rigid fixation or because of inferior construct biomechanics. Anatomic techniques that respect the correct orientation, footprints, and chronicity of the injury whether performed open or arthroscopically should provide optimal outcomes. Furthermore, Nüchtern et al. [38] have advocated acromioclavicular joint reconstruction at the time of coracoclavicular ligament reconstruction in order to compensate for the rotational stiffness resulting from solely addressing the coracoclavicular ligaments.

The Sternoclavicular Joint

The sternoclavicular (SC) joint is the only true joint connecting the axial skeleton to the shoulder girdle. The sternoclavicular joint lacks inherent bony stability with less than half of the medial clavicle articulating with the manubrium. Consequently, a thick capsule and ligamentous structures provide joint stability. The joint is oriented posteromedially in the axial plane, and medially toward the superior end in the coronal plane. The clavicular end of the joint is convex in the coronal plane and concave in the transverse plane. It is more prominent than the sternal end in both the antero-posterior and medio-lateral dimensions, and extends superiorly and posteriorly relative to the sternum (Fig. 1.2) [4].

The anterior capsule of the sternoclavicular joint is formed from a medial sternal soft spot, a middle anterior sternoclavicular ligament covering the intra-articular disk and a lateral clavicular soft spot. The intra-articular disk of the sternoclavicular

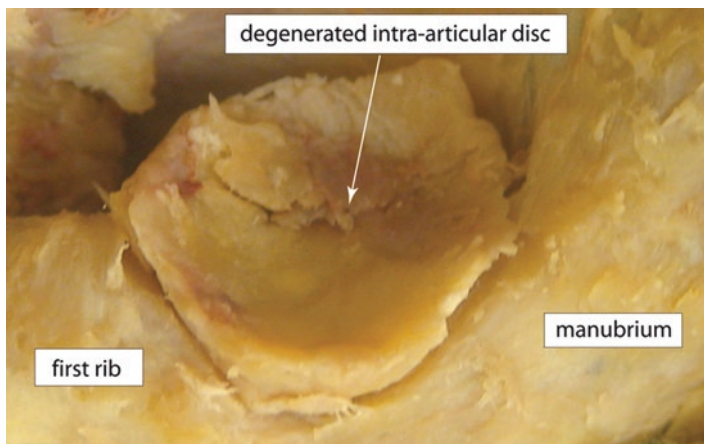


Fig. 1.9 Photograph of a cadaveric shoulder displaying the often ill-defined and degenerated intra-articular disk of the sternoclavicular joint. (Borrowed from van Tongel A, MacDonald P, Leiter J, Pouliart N, Peeler J. A cadaveric study of the structural anatomy of the sternoclavicular joint. *Clin Anat*, 25(7): 903–910, 2012)

joint is present in 97% of individuals (Fig. 1.9). It is firmly suspended between the interclavicular ligament superiorly and the first rib inferiorly and it rarely ruptures or dislocates [39]. Posteriorly, the capsule is thick and uniform and forms a strong barrier that provides stability and separates the joint from the adjacent neurovascular structures [40].

The sternoclavicular joint relies as well on the costoclavicular, interclavicular ligaments and the intra-articular disk for additional stability. In addition to the posterior capsular sternoclavicular ligament, the costoclavicular ligament (Fig. 1.2) is robust and important in resisting joint displacement [4]. Furthermore, Tubbs et al. [41] stressed the importance of the interclavicular ligament (Fig. 1.2). The authors reported that the ligament had a mean length of 2.1 cm and a mean width and thickness of respectively 7.2 and 3.6 mm preventing upward displacement of the clavicle. However, this ligament may be absent in up to 10% of the population [41].

The sternoclavicular joint moves between 30° and 35° in the coronal plane, 35° in the axial plane, and permits 50° of rotation along the clavicle axis [42]. Sternoclavicular elevation occurs mainly between 30° and 90° of arm elevation whereas rotation occurs after 70°–80° of elevation. The dependence on soft tissue restraints for stability renders the sternoclavicular joint vulnerable to dislocations. Sternoclavicular joint dislocations account for 2–3% of all dislocations across the shoulder girdle; most of these are anterior and result from indirect joint loading.

Although less common, posterior sternoclavicular dislocations are far more serious, because of the proximity of the joint to the neurovascular structures. Merriman et al. [43] measured the critical distance between the medial clavicle and the closest retrosternal neurovascular structures using three-dimensional study of contrast-enhanced CT scans and found gender-based differences. At the sternoclavicular joint,

the safety distance from the major vessels for the medial segment (first 10 mm of the medial clavicle) was 3.5 mm for males and 2.4 mm for females whereas for the lateral segment (next 10 mm) the safety distance was 3.3 mm for males versus 1.7 mm for females. These measurements have implications for sternoclavicular joint arthroplasty and for reconstruction for chronic sternoclavicular joint dislocation. Han et al. [44] reported on the presence of two structures that they named “SI” for soft tissue structure inferior and “SL” for soft tissue structure lateral in reference to their location with respect to the head of the clavicle, the strap muscles being situated more posteriorly. The interval between these structures provides a useful avascular plane away from vital mediastinal structures. “SI” and “SL” are continuous with the joint and with each other but may be occupied by fibrocartilage and disk. These structures may be identified preoperatively using CT scan with 1–2 mm thin cuts.

Neurovascular Anatomy of the Sternoclavicular Joint

The clavicular branch of the thoracoacromial artery is the essential blood supply of the sternoclavicular joint (Fig. 1.3), with supplemental contributions from the internal thoracic and the suprascapular arteries. The joint is innervated through a branch from the nerve to the subclavius, with additional contribution from the medial supraclavicular nerve.

Summary

The clavicle is a unique bone with unique embryonic development that serves a vital biomechanical role, both as a strut connecting the axial and appendicular skeletons and as a bony arch to protect the neurovascular supply to the upper extremity. Its subcutaneous location and potential for high impact loading makes the clavicle vulnerable to injuries including fractures along its length and dislocations or separations at both sternal and acromial ends. The remaining chapters will focus on identifying and treating this various injuries.

References

1. Matsumura N, Nakamichi N, Ikegami H, Naqura T, Imanishi N, Aiso S, Toyama Y. The function of the clavicle on scapular motion: a cadaveric study. *J Shoulder Elb Surg.* 2013;22(3):333–9.
2. Andemahr J, Jubel A, Elsner A, Johann J, Prokop A, Rehm KE, Keobke J. Anatomy of the clavicle and the intramedullary nailing of midclavicular fractures. *Clin Anat.* 2007;20(1): 48–56.
3. Rogers NL, Flournoy LE, McCormick WF. The rhomboid fossa of the clavicle as a sex and age estimator. *J Forensic Sci.* 2000;45(1):61–7.

4. Lee JT, Campbell KJ, Michalski MP, Wilson KJ, Spiegl UJ, Wijdicks CA, Millett PJ. Surgical anatomy of the sternoclavicular joint: a qualitative and quantitative anatomical study. *J Bone Joint Surg Am.* 2014;96(19):e166.
5. Mazzocca AD, Arciero RA, Bicos J. Evaluation and treatment of acromioclavicular joint injuries. *Am J Sports Med.* 2007;35(2):316–29.
6. Bernat A, Huysmans T, Van Glabbeek F, Sijbers J, Gielen J, Van Tongel A. The anatomy of the clavicle: a three-dimensional cadaveric study. *Clin Anat.* 2014;27(5):712–23.
7. Wisanuyotin T, Tidchom C, Chaisiwamonthol K, Chowchuen P, Paholpak P, Sirichativapee W, Kosuwan W, Jeeravipoolvarn P. Geometry of the clavicle and reliability of measurement using PACS. *Surg Radiol Anat.* 2014;36(6):573–7.
8. Mathieu PA, Marcheix PS, Hummel V, Valleix D, Mabit C. Anatomical study of the clavicle: endomedullary morphology. *Surg Radiol Anat.* 2014;36(1):11–5.
9. Robinson L, Persico F, Lorenz E, Seligson D. Clavicular caution: an anatomic study of neurovascular structures. *Injury.* 2014;45(12):1867–9.
10. Watterson PA, Taylor GI, Crock JG. The venous territories of muscles: anatomical study and clinical implications. *Br J Plast Surg.* 1988;41(6):569–85.
11. Knudsen FW, Andersen M, Krag C. The arterial supply of the clavicle. *Surg Radiol Anat.* 1989;11(3):211–4.
12. Shin AY, Spinner RJ, Steinman SP, Bishop AT. Adult traumatic brachial plexus injuries. *J Am Acad Orthop Surg.* 2005;13(6):382–96.
13. Havet E, Duparc F, Tobenas-Dujardin AC, Muller JM, Fréger P. Morphometric study of the shoulder and subclavicular innervation by the intermediate and lateral branches of supraclavicular nerves. *Surg Radiol Anat.* 2007;29(8):605–10.
14. Ebraheim NA, Whitehead JL, Alla SR, Moral MZ, Castillo S, McCollough AL, Yeasting RA, Liu J. The suprascapular nerve and its articular branch to the acromioclavicular joint: an anatomic study. *J Shoulder Elb Surg.* 2011;20(2):13–7.
15. Prescher A. Anatomical basics, variations, and degenerative changes of the shoulder joint and shoulder girdle. *Eur J Radiol.* 2000;35(2):88–102.
16. Nathe T, Tseng S, Yoo B. The anatomy of the supraclavicular nerve during surgical approach to the clavicular shaft. *Clin Orthop Relat Res.* 2011;469(3):890–4.
17. Simovitch R, Sanders B, Ozbaydar M, Lavery K, Warner JJ. Acromioclavicular joint injuries: diagnosis and management. *J Am Acad Orthop Surg.* 2009;17(4):207–19.
18. Owens BD, Goss TP. The floating shoulder. *J Bone Joint Surg Br.* 2006;88(11):1419–24.
19. Kibler W, Kelly IV JD. Shoulder injury in the overhead athlete. *Sports Med Arthrosc Rev.* 2009;20(1):1.
20. Gardner E. The embryology of the clavicle. *Clin Orthop Relat Res.* 1968;58:9–16.
21. Ogata S, Uthoff HK. The early development and ossification of the human clavicle—an embryologic study. *Acta Orthop Scand.* 1990;61(4):330–4.
22. Garzon-Alvarado DA, Gutiérrez ML, Calixto LF. A computational model of clavicle bone formation: a mechano-biochemical hypothesis. *Bone.* 2014;61:132–7.
23. Park GY, Park JH, Bae JH. Structural changes in the acromioclavicular joint measured by ultrasonography during provocative tests. *Clin Anat.* 2009;22(5):580–5.
24. Stine IA, Vangsness Jr CT. Analysis of the capsule and ligament insertions about the acromioclavicular joint: a cadaveric study. *Arthroscopy.* 2009;25(9):968–74.
25. Colegate-Stone T, Allom R, Singh R, Elias DA, Standing S, Sinha J. Classification of the morphology of the acromioclavicular joint using cadaveric and radiological analysis. *J Bone Joint Surg Br.* 2010;92(5):743–6.
26. Edelson G, Saffuri H, Obid E, Lipovsky E, Ben-David D. Successful injection of the acromioclavicular joint with use of ultrasound: anatomy, technique, and follow-up. *J Shoulder Elb Surg.* 2014;23(10):e243–50.
27. Emura K, Arakawa T, Miki A, Terashima T. Anatomical observations of the human acromioclavicular joint. *Clin Anat.* 2014;27(7):1046–52.
28. Hatta T, Sano H, Zuo J, Yamamoto N, Itoi E. Localization of degenerative changes of the acromioclavicular joint: a cadaveric study. *Surg Radiol Anat.* 2013;35(2):89–94.

29. Mall NA, Foley E, Chalmers PN, Cole BJ, Romeo AA, Bach Jr BR. Degenerative joint disease of the acromioclavicular joint: a review. *Am J Sports Med.* 2013;41(11):2684–92.
30. Salzmann GM, Paul J, Sandmann GH, Imhoff AB, Schöttle PB. The coracoid insertion of the coracoclavicular ligaments. An anatomic study. *Am J Sports Med.* 2008;36(12):2392–7.
31. Harris RI, Vu DH, Sonnabend DH, Goldberg JA, Walsh WR. Anatomic variance of the coracoclavicular ligaments. *J Shoulder Elb Surg.* 2001;10(6):585–8.
32. Saccomano MF, De Iseo C, Milano G. Acromioclavicular joint instability: anatomy, biomechanics and evaluation. *Joints.* 2014;2(2):87–92.
33. Katsumi K. The coracoclavicular ligaments: an anatomic study. *Surg Radiol Anat.* 2010;32(7):683–8.
34. Rockwood CA. Injuries to the acromioclavicular joint. In: Rockwood CA, Freen DP, editors. *Fractures in adults, vol. 1.* 2nd ed. Philadelphia: JB Lippincott; 1984. p. 860.
35. Eschler A, Rösler K, Rotter R, Gradl G, Mittlmeier T, Gierer P. Acromioclavicular joint dislocations: radiological correlation between Rockwood classification system and injury patterns in human cadaver species. *Arch Orthop Trauma Surg.* 2014;134(9):1193–8.
36. Rios CG, Arciero RA, Mazzocca AD. Anatomy of the clavicle and coracoid process for reconstruction of the coracoclavicular ligaments. *Am J Sports Med.* 2007;35(5):811–7.
37. Geaney LE, Beitzel K, Chowaniec DM, Cote MP, Apostolakos J, Arciero RA, Mazzocca AD. Graft fixation is highest with anatomic tunnel positioning in acromioclavicular reconstruction. *Arthroscopy.* 2013;29(3):434–9.
38. Nüchtern JV, Sellenschloh K, Bishop N, Jauch S, Briem D, Hoffmann M, Lehmann W, Püeschel K, Morlock MM, Rueger JM, Großterlinden LG. Biomechanical evaluation of 3 stabilization methods on acromioclavicular joint dislocations. *Am J Sports Med.* 2013;41(6):1387–94.
39. Emura K, Arakawa T, Terashima T, Miki A. Macroscopic and histological observations on the human sternoclavicular joint disc. *Anat Sci Int.* 2009;84(3):182–8.
40. van Tongel A, MacDonald P, Leiter J, Pouliart N, Peeler J. A cadaveric study of the structural anatomy of the sternoclavicular joint. *Clin Anat.* 2012;25(7):903–10.
41. Tubbs RS, Loukas M, Slattery JB, McEvoy WC, Linganna S, Shoja MM, Oakes WJ. Surgical and clinical anatomy of the interclavicular ligament. *Surg Radiol Anat.* 2007;29(5):357–60.
42. Bontempo NA, Mazzocca AD. Biomechanics and treatment of acromioclavicular and sternoclavicular joint injuries. *Br J Sports Med.* 2010;44(5):361–9.
43. Merriman JA, Villacis D, Wu B, Patel D, Yi A, Hatch 3rd GF. Does patient sex affect the anatomic relationships between the sternoclavicular joint and posterior vascular structures? *Clin Orthop Relat Res.* 2014;472(11):3495–506.
44. Han DH, Nam YS, Ahn MI, Wang YP, Park SA. Under-recognized soft-tissue structures inferior and lateral to the head of the clavicle: anatomy with computer tomography correlation. *Clin Anat.* 2010;23(7):803–10.
45. Netter FH. *Atlas of human anatomy.* 4th ed. Philadelphia: Saunders; 2006.

Chapter 2

Biomechanics of the Clavicle

Sergio Gutiérrez, Ioannis P. Pappou, Jazmine Aira, Peter Simon,
and Mark A. Frankle

Introduction

The clavicle is an S-shaped bone that acts as the only osseous link between the upper extremity skeleton and the thorax. In animals that do not bear weight on their forelimbs, it is absent. In such animals, the scapula is stabilized to the thorax by numerous powerful muscles. The absence of a clavicle improves running and agility on four limbs. In brachiating animals however, including man, it serves as a solid strut to position the upper limb away from the trunk and enhance more global positioning and use of the limb.

Some consider the clavicle to be expendable. Although children with congenital absence of the clavicle [1] and malunions [2] adapt surprisingly well and patients with tumors or infections treated by clavicular resection sometimes function adequately, adults with malunited clavicles often report difficulty with overhead activities requiring strength or dexterity [3]. Patients with total claviclectomy have decreased strength and patient-reported outcomes in the aclavicate limbs [4]. It is clear that the evolutionary process has determined an important function for the clavicle and we should always strive to preserve the length and alignment of the clavicle.

S. Gutiérrez, Ph.D. (✉) • J. Aira, M.S. • P. Simon, Ph.D.
Foundation for Orthopaedic Research and Education,
4115 West Spruce Street, Tampa, FL, USA
e-mail: serggut@gmail.com

I.P. Pappou, M.D. • M.A. Frankle, M.D.
Florida Orthopaedic Institute, Tampa, FL, USA

Anatomy

The clavicle is classified as a long bone that is on average 151.8 ± 11.7 mm long, 143.9 ± 8.4 mm long in females, and 160 ± 8.5 mm long in males. They are typically longer if they originate from a male or from the left side of the body [5]. The clavicle is named for its S-shaped curvature, with an apex anteromedially and an apex posterolaterally, similar to the musical symbol clavicular (Fig. 2.1).

The larger medial curvature allows more space for passage of neurovascular structures from the neck into the upper extremity through the costoclavicular interval. The transition from medial to lateral curvature occurs at approximately two-thirds the length of the bone as measured from its sternal end, a site that roughly corresponds to both the medial limit of attachment of the coracoclavicular ligaments and the entrance point of the main nutrient artery of the clavicle.

Males have significantly greater medial curvatures than females, most likely due to their greater size. Similarly, left-sided clavicles tend to be longer and have a greater medial curvature. On the other hand, it appears that the lateral curvature of the clavicle is not affected by either gender or anatomical side. Longer clavicles do not necessarily confer larger lateral curvatures (Table 2.1). The curvature of the IM canal represents the curvature an IM device should be shaped to in order to fit inside properly [5].

The clavicle is made up of dense trabecular bone lacking a well-defined medullary canal. In cross-section, the clavicle changes gradually between an expanded prismatic medial end, a tubular midportion, and a flat lateral aspect. In addition to the variation in cross-sectional shape, the diameter of the clavicle and IM canal experience significant

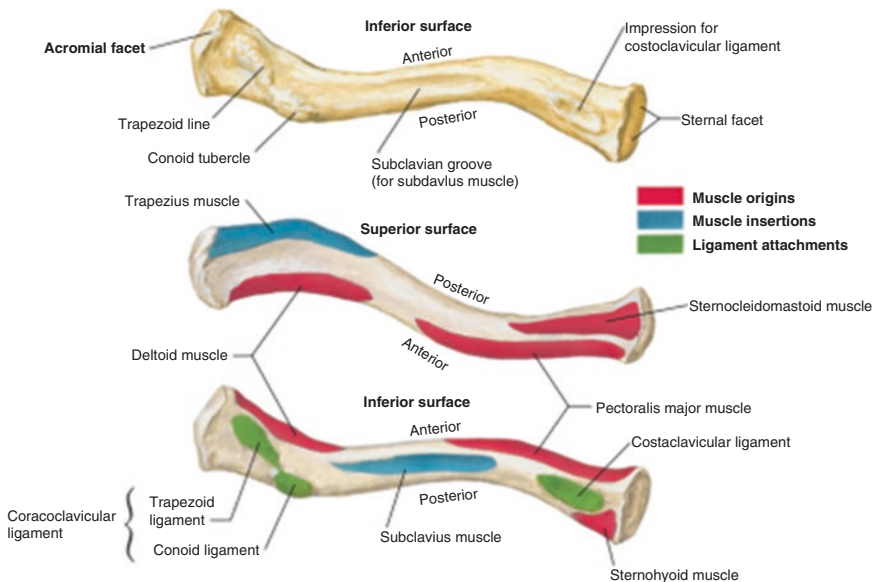


Fig. 2.1 Left clavicle, bony anatomy, and muscle attachments viewed from superiorly and inferiorly

Table 2.1 Radius of curvature and standard deviation of the clavicle when grouped for gender and anatomical side from a 104 sample size clavicle morphometry study

Radius of curvature (mm) ± SD				
	Females—Right	Females—Left	Females	Overall
Medial	83.51 ± 11.82	91.13 ± 15.90	87.54 ± 14.51	91.21 ± 14.4
Lateral	31.86 ± 12.08	34.68 ± 12.57	33.35 ± 12.31	32.51 ± 11.1
	Males—Right	Males—Left	Males	Overall
Medial	93.63 ± 15.03	96.65 ± 11.06	94.99 ± 13.34	91.21 ± 14.4
Lateral	31.51 ± 11.23	31.90 ± 7.77	31.69 ± 9.73	32.51 ± 11.1

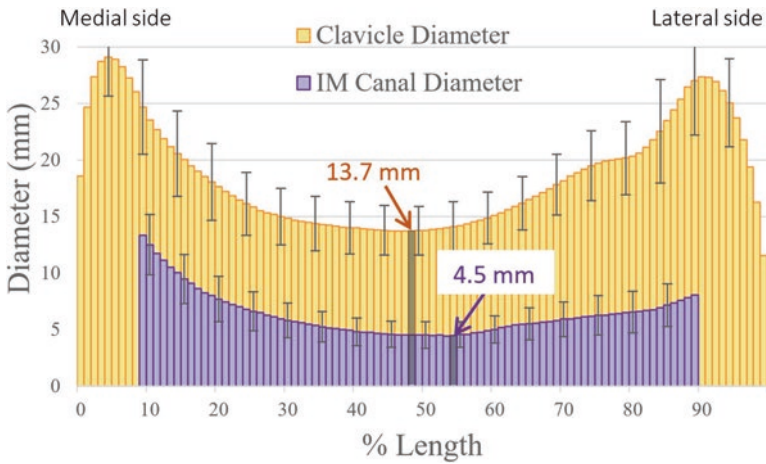


Fig. 2.2 Average clavicle and IM canal diameter as a function of percent clavicle length starting from the medial end from a 104 sample size clavicle morphometry study

change in size. A recent clavicle morphometry study has found that the medial and lateral ends of the bone are the widest regions with an average diameter of 28 mm, while the midportion is significantly narrower, at 13.7 mm. The IM canal also shares this ‘hourglass’ shape, with a smallest diameter of 4.5 mm; however, it is important to note that the location of the narrowest diameter for both clavicle and IM canal occurs at different locations along the midportion (5% clavicle length difference). This offset was observed across all groups (male/female, right/left) and suggests that one may not estimate the location of narrowest region of the IM canal based on external visualization of the clavicle alone (Fig. 2.2). The size and location of the smallest diameter of the IM canal is of special interest as it is the limiting region for IM device design and must be understood for proper implant fit.

Furthermore, clavicle and IM canal are not perfectly congruent. There exists an eccentricity of the IM canal center with respect to the clavicle because cortical thickness and shape are not consistent throughout any given cross-section. This finding also allows us to understand proper IM device fitting inside the canal, as the eccentricity tells us how close the device is to the surface of the bone and how thin the cortex is at any point around it [5] (Fig. 2.3).

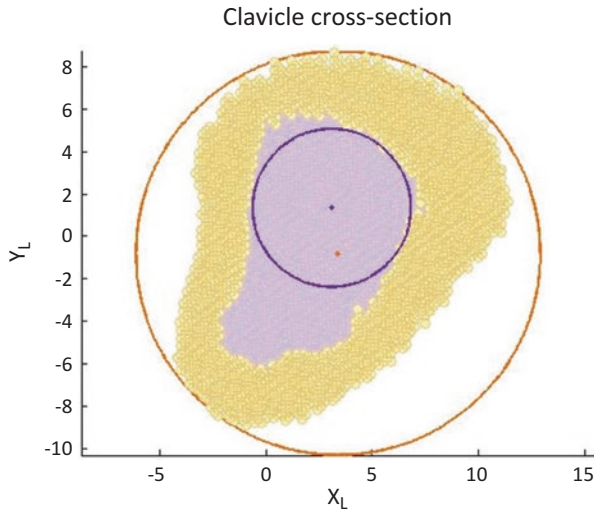


Fig. 2.3 Clavicle cross-section illustrating IM canal eccentricity. The *purple circle* is the largest circular space that could potentially fit an IM device

The above-mentioned peculiarities of the clavicle, namely its curvature, narrowing offset between clavicle and IM canal, and IM canal eccentricity become important when intramedullary fixation of the clavicle is being considered. Since a 3-D morphometric analysis is a requisite for noting these features, a pre-operative CT scan and canal analysis would be warranted in pre-operative planning and implant selection for fracture treatment with an IM device.

As viewed in Fig. 2.1, several muscles attach to the clavicle. The muscles that contribute to shoulder motion are the deltoid, trapezius, and pectoralis. The subclavius muscle serves mainly as a protective layer between the clavicle and the neurovascular structures.

In view of the intimate relationship of the clavicle to the brachial plexus, the subclavian artery and vein, and the apex of the lung, it is surprising that injury to these structures in association with fracture of the clavicle is so uncommon. Brachial plexus palsy may develop weeks or years after injury as a result of compromise of the costoclavicular space by hypertrophic callus, with or without malalignment of the fracture fragments. Narrowing of the costoclavicular space because of malunion or nonunion can also lead to dynamic narrowing of the thoracic outlet. Prolonged compression of vascular structures can likewise be problematic. The course of the neurovascular structures makes it such that medially it is safer to drill superior to inferior and laterally anterior to posterior (Fig. 2.4) [6].

The scapula is a broad thin bone that serves as the origin or insertion for at least 18 different muscles. It also supports the upper extremity through its articulation with the humerus at the glenoid. The glenoid is a narrow, shallow concavity that relies on the surrounding labrum, ligaments, and muscle-tendon units for stability. The acromial and coracoid processes have enlarged during the evolutionary process,

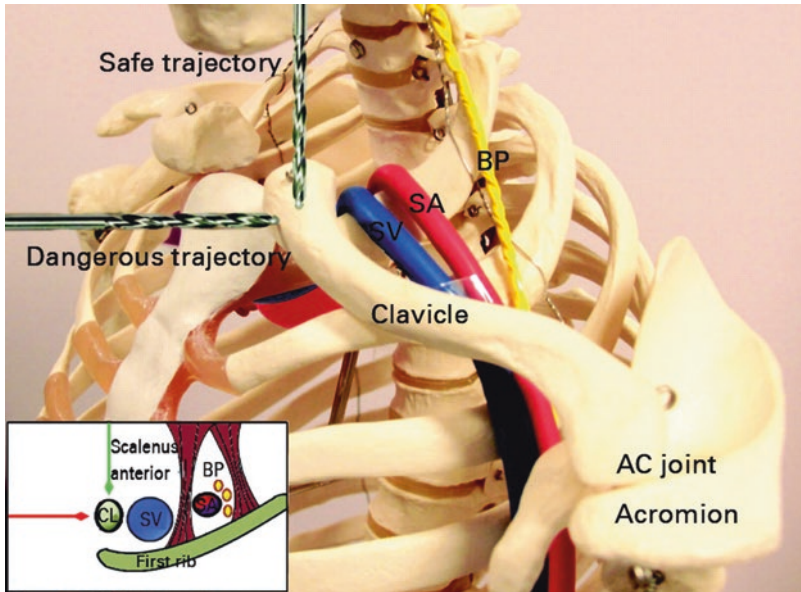


Fig. 2.4 Relationship of neurovascular structures to clavicle and safe drilling trajectories. From Sinha et al.

presumably to provide an origin for more powerful and mechanically efficient upper extremity musculature as well as to give the inherently unstable glenohumeral joint a measure of stability.

Clavicle Contribution to Motion of the Shoulder Girdle

The clavicle articulates on the medial end with the sternum and laterally with the acromion. The sternoclavicular (SC) and acromioclavicular (AC) joints are both diarthrodial articulations (hyaline articular cartilage-covered and synovium-lined mobile joints) with intervening fibrocartilage disks. Both joints lack inherent osseous articular stability and are maintained by strong ligaments. The acromioclavicular joint is unusual in that negligible motion occurs through the joint and yet degenerative arthritis is common, particularly after trauma. The function of the acromioclavicular articulation is unclear. Patients with acromioclavicular or coracoclavicular fusion or coracoclavicular screw fixation have full or nearly full shoulder motion. Most of motion between the shoulder girdle and the axial skeleton must therefore occur at the (SC) joint; a recent study in healthy asymptomatic volunteers documents some motion in the AC joint (19° of scapular tilting maximally) [7]. Motion at the SC joint is commonly thought to be 35° of elevation-depression, 35° of protraction-retraction, and 50° of rotation, as reported by Inman [8].

Ligament-cutting studies in cadavers suggest that the coracoclavicular ligaments limit superior displacement of the clavicle and the acromioclavicular ligaments limit posterior displacement [9]. The capsuloligamentous covering of the acromioclavicular ligament is most stout superiorly. Because one of the complications of distal clavicular excision is posterior displacement of the clavicle with impingement on the scapular spine, many surgeons emphasize preservation of the acromioclavicular ligaments, particularly superiorly.

Forces Seen by the Clavicle and Relation to Fracture

Clavicle fractures are common injuries (2.6–5% of all fractures), with 80% of the fractures occurring in the diaphysis [10]. The chapter will concentrate on the mechanics pertinent to mid-shaft injuries as they are the most common. It is not surprising that the middle third is the most common site of clavicular fracture, since the midportion is the thinnest and narrowest portion of the bone; it represents a transitional region of the bone, both in curvature and in cross-sectional anatomy, which makes it a mechanically weak area, and it is the only area of the clavicle that is not supported by ligamentous or muscular attachments. It is possible that this anatomy was selected during evolution because clavicular fracture protects the brachial plexus during difficult births (shoulder dystocia).

Mechanics of Clavicle Malunion

Clavicular malunion (Fig. 2.5) [11] is emerging as a clinical syndrome identified by shortening, deformity of the shoulder girdle (including the scapula), pain, and fatigue with overhead activity and weakness in strength testing [3, 11, 12]. The forces contributing to persistence or worsening of deformity after fracture include the weight of the shoulder as transmitted to the distal fragment of the clavicle, primarily through the coracoclavicular ligaments, and the deforming forces of the attached muscles and ligaments. The medial fragment is elevated by the clavicular head of the sternocleidomastoid muscle, which inserts onto the posterior aspect of the medial portion of the clavicle. The pectoralis major contributes to adduction and inward rotation of the shoulder.

A study simulating the effect of clavicle shortening on upper extremity muscles found that shortening of the clavicle decreases the moment-generating capacity as well as the total force-generating capacity of the shoulder girdle muscles, especially elevation moments of the upper extremity muscles during abduction and internal rotation [13]. Flexion moments were affected less through physiologic range of motion. Additionally, shortening of the clavicle increases coronal angulation of the clavicle at the sternoclavicular joint thus providing a basic science support to the clinical syndrome of malunion.

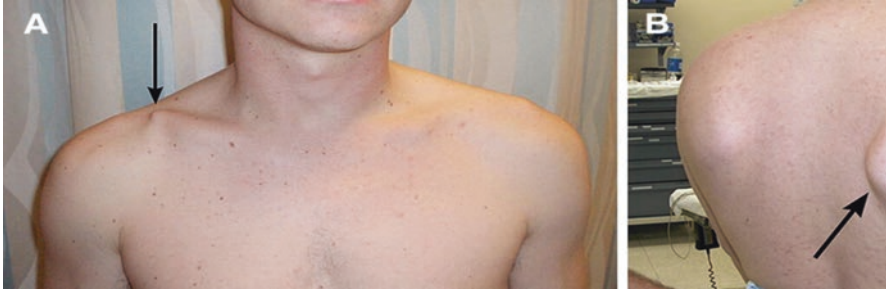

Fig. 2.5 Anterior (a) and posterior (b) view of clavicle malunion. Shortening, drooping of the shoulder girdle and scapular winging of inferior-medial border of clavicle is evident. From Ristevski et al.

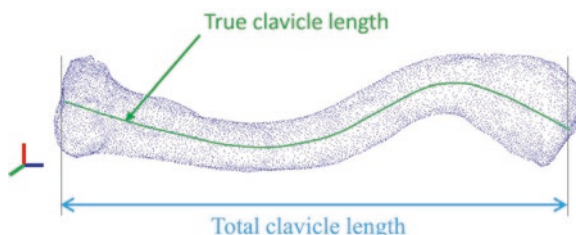
A cadaveric study found that shortening of the clavicle produces change to the resting position of the shoulder girdle quite similar to the clinically observed malunions. Moreover, the motion of the shoulder girdle is progressively affected with increasing amounts of shortening [14].

Complications from Clavicle Fractures, Nonoperative Treatment

Traditionally, treatment has been conservative, due to influential historic literature with high rates of healing [15, 16]. More recent literature suggests that the results of nonoperative treatment are worse than what was previously thought. Inferior outcomes and higher risks of nonunion are documented when there is significant displacement (i.e., >2 cm or no cortical contact) and other risk factors such as comminution, z deformity, increasing age, female sex, and smoking [2, 3, 12, 16–18].

In a systematic review of 2144 clavicle fractures, a nonunion rate of 15% with nonoperative management was found [19]. Displacement and comminution were the primary risk factors contributing to nonunion. Operative treatment resulted in a relative risk reduction of 86% for nonunion. It is possible that a displacement of 2 cm noted on X-ray may be underestimating fracture severity. Because of the clavicle's signature S-shape, the dimensions of the bone are often misrepresented on two-dimensional film. A recent three-dimensional clavicle morphometry study investigated the difference between total clavicle length and true clavicle length [5]. Total clavicle length is a straight end-to-end measurement in the frontal plane, while true length is the length of the bone if it were straight (Fig. 2.6). The study found an average of 1.5 cm difference between these two types of measurements. True length of the clavicle is a superior estimation of the bone's length as it takes into account the curvatures in 3-D space, and suggests a longer region of bone overlap not appreciable on X-ray.

Fig. 2.6 The difference between two types of clavicle length measurement: true length in green, total length in blue



Operative Versus Nonoperative Management of Midshaft Clavicular Fractures

The first randomized controlled trial (RCT) in 2007 demonstrated earlier healing rates (16 versus 28 weeks) and lower nonunion rates (3% versus 11%) for ORIF compared to nonoperative management [20]. In addition, operative treatment resulted in better DASH scores and fewer symptomatic malunions. However, there was a 12% complication rate with surgical management—mainly symptomatic hardware.

Virtanen in 2012 reported on an RCT of 60 patients with 1 year average follow up [21]. Nonunion rates were 0% for ORIF versus 24% for sling. Complication rates were 7% for ORIF versus 12% for sling, none were major. The patients with nonunions [6] and malunions [2] in the sling group had worse DASH scores.

Robinson in 2013 reported a significantly reduced nonunion rate and better outcome scores after ORIF compared to nonoperative treatment (1% compared to 16%) [16]. When nonunion patients were excluded from analysis however, there were no differences in functional outcome between operative and nonoperative treatment. Improved outcomes resulted from the prevention of nonunion. Due to the cost and implant-related complications, the authors did not support routine primary ORIF for the treatment of displaced midshaft clavicular fractures.

Indications

Open or impending open injuries, neurologic or vascular compromise, unstable or displaced floating shoulder injury, and posteriorly displaced medial clavicular fractures or sternoclavicular injuries constitute absolute indications.

Relative indications for surgical treatment include widely displaced fractures with shortening >2 cm or significant comminution, unacceptable cosmesis, multiply injured trauma patients, predicted functional deficits, and painful nonunion or malunion.

Surgical Techniques

Plate Fixation

Open reduction and internal fixation can be done with a superior or anterior-inferior plate position. Newer plate technology allows for pre-contoured plates that are lower profile and allow locking fixation if necessary [22].

The surgical approach should allow for cosmesis and prevent wound complications. A full-thickness skin and subcutaneous layer should be created down to the platysma, which is then incised longitudinally along the clavicle and then the muscle insertions of the pectoralis major, trapezius, and deltoid on the clavicle are released as required. This will allow for a full thickness fascial layer over the plate at the time of closure.

Superior plate fixation allows the plate to be placed on the tension surface of the bone and requires less muscle origin release. Anterior-inferior plating allows for reduced plate prominence and less plate irritation. In addition, screw length is increased and there is less risk of neurovascular injury during drilling during lateral screw placement [6]. Reconstruction plates are malleable allowing contouring to the patient's anatomy but are weak in comparison to dynamic compression plates. Standalone semi-tubular plates should be avoided.

Anatomically contoured plates fit most of the time and are lower profile which lessens the chance of needed plate removal, but they are more expensive [22]. In cases of comminution, the use of mini-fragment screws can be useful to allow for reduction and lagging of small butterfly fragment and an anatomic reduction. The plate is then placed as a neutralization plate.

The biomechanics on plating position are mixed. Some studies favor superior plating, others anterior plating and finally results may differ in the same study depending on loading conditions [23–25].

Intramedullary Fixation

Intramedullary devices for clavicle fracture fixation may result in shorter operating room time, less narcotic use, fewer complications, and less symptomatic hardware [26]. However, intramedullary devices are biomechanically inferior to plates [27], especially with increasing comminution. Cannulated screws, flexible nails, and clavicle-specific pins for the treatment of these fractures have been reported. The use of small diameter smooth pins is contraindicated. A systematic review comparing plate fixation versus intramedullary devices for displaced clavicle fractures did not show differences in functional outcome or complication rates [26].

Surgical Treatment of Malunion/Nonunion

Malunion and/or nonunion of a clavicle fracture have adverse effects on the functional result; risk factors were discussed. The goal in the treatment of malunions and nonunions of the clavicle is to restore clavicular length and anatomy. This may require an osteotomy as well as possible tricortical interposition graft. Lag screws should be used if possible to allow for compression across the fracture nonunion site.

The clavicular length is evaluated preferably on a computed tomography of both clavicles or at a minimum on anteroposterior and oblique radiographs of both clavicles. If there is greater than 2 cm of shortening, then an osteotomy with interposition bone grafting should be considered to restore the appropriate length.

Plate fixation of clavicle nonunions and malunions provides high union rates and improvement in shoulder function. Plates and nails have been used successfully [12, 28–30]. We favor plates due to higher torsional rigidity.

Biomechanical Considerations for Nailing and Plating

Intramedullary Nailing

Intramedullary nailing of this curved bone deserves some special consideration. A nail can be introduced through a medial entry point, a lateral entry point, and finally through the fracture site. If a nail is introduced through the fracture site, then it must be advanced through the medial or lateral end of the bone to allow reduction of the fracture and then reinsertion to the desired depth.

The unique features of the clavicle, especially its curvature, narrowing offset between clavicle and IM canal, and IM canal eccentricity influence the design of the IM device in both size and shape. The implant must be flexible enough to adapt to the S-shape of the clavicle, thin enough to pass through the narrow middle portion but also strong enough to allow clavicle healing and minimize interfragmentary motion below the nonunion threshold.

The unique curvatures of the IM canal also dictate implant insertion, as they represent the safest trajectory an IM device would take as it is being introduced into the canal (Fig. 2.7) [31]. Due to the clavicle shape the implant will predictably exit the anterior cortex medially and the posterior cortex laterally [31].

Therefore, different types of implant can be utilized [32]:

- (a) Titanium nails/K wires/Cannulated screws: These implants are typically introduced through a medial entry site or more commonly through the fracture, out the anterior medial cortex and retrograded into place.
- (b) “Locking” nails: Examples are the older Hagie and Rockwood nails and the newer Sonoma nail. These nails are introduced through the fracture, exit out the posterior lateral cortex and then advanced antegrade and engage the medial cortex. The Hagie and Rockwood nail use a similar philosophy of compressing

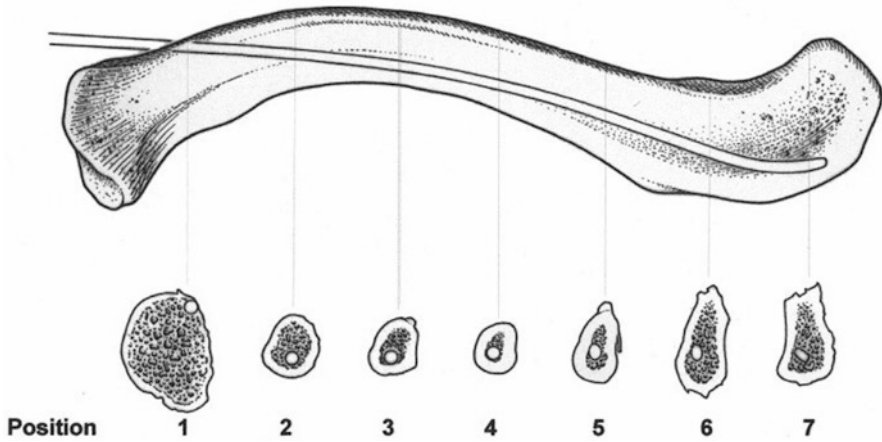


Fig. 2.7 Position of the TEN within the clavicular canal. Contact point and the cortical thickness next to the respective positions become clear. The medial and lateral portions of the bone are the danger zones for nail perforation, while in the middle third a relative narrowing is present. From Andermahr et al.

the fracture using a lateral nut and fixation into the medial end. The Sonoma nail affords true locking screws laterally and the medial fragment is engaged with deployable spikes. The reader is referred to the manufacturer websites for further details on the surgical technique.

Plating

Surgeons have used DCP plates and reconstruction plates, locking and non-locking variations. Due to the biomechanical advantages of locking and the ease of use afforded by pre-contoured plates they are dominating the implant use at this time. It should be noted that pre-contoured plates do not always fit well and hence intraoperative further contouring may be necessary and the surgeon should have the necessary tools available [22]. There is significant debate over superior versus anterior plate position.

Clinical studies support anterior plating as advantageous in terms of secondary operations for removal of hardware [33]. Otherwise, the literature offers mixed results of biomechanical advantage of superior versus the other location [23–25, 34]. Union rates are similar. Since union rates and biomechanical results appear relatively equivalent, we prefer anterior plate position to minimize irritation by hardware and secondary removal of hardware. Three studies suggest that unicortical screws may offer sufficient fixation strength with locking plates [34–36], but it is our preference to use bicortical screws.

Nails Versus Plates

In a systematic review of 2144 clavicle fractures, the nonunion rate was slightly higher for intramedullary nails 1.6% for 364 fractures versus 2.5% for 635 plated fractures (pooled data) [19]. Other comparative studies have shown similar results, i.e., slightly higher rates of nonunion for nailing, but overall very satisfactory results for nailing [26]. Nails have also been used for repair of clavicle malunions [28].

Biomechanical comparison of nailing versus plating demonstrates better stability for plating [28]. The reason that nailing has a higher nonunion rate than plating is perhaps not only device-related but biology-related; the hematoma which typically affords excellent healing after IM nailing of long bones is removed during the process of reduction and introduction of the device for a clavicle fracture. Therefore, in highly comminuted fractures we prefer plating. Nailing is very successful for simpler fracture patterns. One should also consider that most of the intramedullary implants are designed to be removed postoperatively after union; however, this procedure can be typically done with sedation/local anesthetic avoiding general anesthetics.

Conclusion

The clavicle is an important osseous link of the upper extremity to the axial skeleton. Preservation of length and anatomy is important for optimal function of the upper extremity. The most frequent fracture location is in the mid-diaphysis, the isthmus, where the bone is the narrowest. Operative treatment has shown superior results in displaced fractures. Nailing and plating are both acceptable methods of treatment with a different subset of complications and reoperations. This chapter should help the surgeon be more cognizant of the type of implant he/she uses and the biomechanical/clinical considerations.

References

1. Van Tongel A, Piepers I, De Wilde L. The significance of the clavicle on shoulder girdle function. *J Shoulder Elb Surg/Am Shoulder Elb Surg* [et al]. 2015;24(9):e255–9.
2. Nowak J, Holgersson M, Larsson S. Can we predict long-term sequelae after fractures of the clavicle based on initial findings? A prospective study with nine to ten years of follow-up. *J Shoulder Elb Surg/Am Shoulder Elb Surg* [et al]. 2004;13(5):479–86.
3. McKee MD, Pedersen EM, Jones C, Stephen DJ, Kreder HJ, Schemitsch EH, et al. Deficits following nonoperative treatment of displaced midshaft clavicular fractures. *J Bone Joint Surg Am*. 2006;88(1):35–40.
4. Rubright J, Kelleher P, Beardsley C, Paller D, Shackford S, Beynonn B, et al. Long-term clinical outcomes, motion, strength, and function after total claviclectomy. *J Shoulder Elb Surg/Am Shoulder Elb Surg* [et al]. 2014;23(2):236–44.

5. Aira J. Image-based 3D morphometric analysis of the clavicle intramedullary (IM) canal. Tampa: University of South Florida; 2016.
6. Sinha A, Edwin J, Sreeharsha B, Bhalai V, Brownson P. A radiological study to define safe zones for drilling during plating of clavicle fractures. *J Bone Joint Surg Br.* 2011;93(9):1247–52.
7. Ludewig PM, Phadke V, Braman JP, Hassett DR, Cieminski CJ, LaPrade RF. Motion of the shoulder complex during multiplanar humeral elevation. *J Bone Joint Surg.* 2009;91(2):378–89.
8. Inman VT, deC M Saunders JB, Abbott LC. Observations on the function of the shoulder joint. *J Bone Joint Surg.* 1944;26(1):1–30.
9. Fukuda K, Craig EV, An KN, Cofield RH, Chao EY. Biomechanical study of the ligamentous system of the acromioclavicular joint. *J Bone Joint Surg.* 1986;68(3):434–40.
10. Robinson CM. Fractures of the clavicle in the adult. Epidemiology and classification. *J Bone Joint Surg Br.* 1998;80(3):476–84.
11. Ristevski B, Hall JA, Pearce D, Potter J, Farrugia M, McKee MD. The radiographic quantification of scapular malalignment after malunion of displaced clavicular shaft fractures. *J Shoulder Elb Surg/Am Shoulder Elb Surg* [et al]. 2013;22(2):240–6.
12. McKee MD, Wild LM, Schemitsch EH. Midshaft malunions of the clavicle. *J Bone Joint Surg Am.* 2003;85-A(5):790–7.
13. Patel B, Gustafson PA, Jastifer J. The effect of clavicle malunion on shoulder biomechanics; a computational study. *Clin Biomech (Bristol, Avon).* 2012;27(5):436–42.
14. Hillen RJ, Burger BJ, Pöll RG, van Dijk CN, Veeger DHEJ. The effect of experimental shortening of the clavicle on shoulder kinematics. *Clin Biomech (Bristol, Avon).* 2012;27(8):777–81.
15. Neer II. CS. Nonunion of the clavicle. *J Am Med Assoc.* 1960;172:1006–11.
16. Robinson CM, Goudie EB, Murray IR, Jenkins PJ, Ahktar MA, Read EO, et al. Open reduction and plate fixation versus nonoperative treatment for displaced midshaft clavicular fractures: a multicenter, randomized, controlled trial. *J Bone Joint Surg.* 2013;95(17):1576–84.
17. Hill JM, McGuire MH, Crosby LA. Closed treatment of displaced middle-third fractures of the clavicle gives poor results. *J Bone Joint Surg Br.* 1997;79(4):537–9.
18. Wick M, Muller EJ, Kollig E, Muhr G. Midshaft fractures of the clavicle with a shortening of more than 2 cm predispose to nonunion. *Arch Orthop Trauma Surg.* 2001;121(4):207–11.
19. Zlowodzki M, Zelle BA, Cole PA, Jeray K, McKee MD. Treatment of acute midshaft clavicle fractures: systematic review of 2144 fractures: on behalf of the Evidence-Based Orthopaedic Trauma Working Group. *J Orthop Trauma.* 2005;19(7):504–7.
20. Society COT. Nonoperative treatment compared with plate fixation of displaced midshaft clavicular fractures. A multicenter, randomized clinical trial. *J Bone Joint Surg.* 2007;89(1):1–10.
21. Virtanen KJ, Remes V, Pajarinen J, Savolainen V, Björkenheim J-M, Paavola M. Sling compared with plate osteosynthesis for treatment of displaced midshaft clavicular fractures: a randomized clinical trial. *J Bone Joint Surg.* 2012;94(17):1546–53.
22. Huang JI, Toogood P, Chen MR, Wilber JH, Cooperman DR. Clavicular anatomy and the applicability of precontoured plates. *J Bone Joint Surg.* 2007;89(10):2260–5.
23. Celestre P, Roberston C, Mahar A, Oka R, Meunier M, Schwartz A. Biomechanical evaluation of clavicle fracture plating techniques: does a locking plate provide improved stability? *J Orthop Trauma.* 2008;22(4):241–7.
24. Partal G, Meyers KN, Sama N, Pagenkopf E, Lewis PB, Goldman A, et al. Superior versus anteroinferior plating of the clavicle revisited: a mechanical study. *J Orthop Trauma.* 2010;24(7):420–5.
25. Iannotti MR, Crosby LA, Stafford P, Grayson G, Goulet R. Effects of plate location and selection on the stability of midshaft clavicle osteotomies: a biomechanical study. *J Shoulder Elb Surg.* 2002;11(5):457–62.
26. Houwert RM, Wijdicks F-J, Steins Bisschop C, Verleisdonk E-J, Kruijt M. Plate fixation versus intramedullary fixation for displaced mid-shaft clavicle fractures: a systematic review. *Int Orthop.* 2012;36(3):579–85.

27. Golish SR, Oliviero JA, Francke EI, Miller MD. A biomechanical study of plate versus intramedullary devices for midshaft clavicle fixation. *J Orthop Surg Res.* 2008;3:28.
28. Smekal V, Deml C, Kamelger F, Dallapozza C, Krappinger D. Corrective osteotomy in symptomatic midshaft clavicular malunion using elastic stable intramedullary nails. *Arch Orthop Trauma Surg.* 2010;130(5):681–5.
29. Hillen RJ, Eygendaal D. Corrective osteotomy after malunion of mid shaft fractures of the clavicle. *Strategies Trauma Limb Reconstr.* 2007;2(2–3):59–61.
30. McKee MD, Wild LM, Schemitsch EH. Midshaft malunions of the clavicle. Surgical technique. *J Bone Joint Surg.* 2004;86-A(Suppl 1):37–43.
31. Andermahr J, Jubel A, Elsner A, Johann J, Prokop A, Rehm KE, et al. Anatomy of the clavicle and the intramedullary nailing of midclavicular fractures. *Clin Anat (New York).* 2007;20(1):48–56.
32. Eichinger JK, Balog TP, Grassbaugh JA. Intramedullary fixation of clavicle fractures: anatomy, indications, advantages, and disadvantages. *J Am Acad Orthop Surg.* 2016;24:455–64.
33. Collinge C, Devinney S, Herscovici D, DiPasquale T, Sanders R. Anterior-inferior plate fixation of middle-third fractures and nonunions of the clavicle. *J Orthop Trauma.* 2006;20(10):680–6.
34. Croley JS, Morris RP, Amin A, Lindsey RW, Gugala Z. Biomechanical comparison of bicortical, unicortical, and unicortical far-cortex-abutting screw fixations in plated comminuted midshaft clavicle fractures. *J Hand Surg Am.* 2016;41(6):703–11.
35. Bravman JT, Taylor ML, Baldini T, Vidal AF. Unicortical versus bicortical locked plate fixation in midshaft clavicle fractures. *Orthopedics.* 2015;38(5):e411–6.
36. Hamman D, Lindsey D, Drago J. Biomechanical analysis of bicortical versus unicortical locked plating of mid-clavicular fractures. *Arch Orthop Trauma Surg.* 2011;131(6):773–8.

Chapter 3

Evaluation of Clavicle Injuries

John G. Horneff III, Surena Namdari, and Gerald R. Williams

The approach to evaluating clavicle injuries should hinge on the general principles of all orthopaedic injury evaluation. Injuries to the clavicle are often the result of acute trauma that can be high in energy. In addition, the proximal location of the clavicle within the upper extremity places it extremely close to the head, neck, and chest, which, if also injured, can lead to rapid decompensation of a patient. Therefore, as with any patient who sustains a traumatic injury, the treating provider should first ensure proper trauma triage stabilization of airway, breathing, and circulation along with proper immobilization of the cervical spine if there is any concern for injury to these areas. Once the patient is stabilized following this primary survey, the more detailed examination of any clavicle injury can begin.

Serving as the strut between the scapula of the upper extremity to the sternum of the chest wall, the clavicle can be injured at either one of its articulations or anywhere along its shaft. The proper treatment for these various locations can differ substantially and, as such, it is important to recognize where the injury has occurred to the clavicle before deciding on a treatment plan. In order to organize the approach to clavicle injury evaluation, this chapter examines clavicle injuries as they progress from the medial articulation of the sternoclavicular (SC) joint to the lateral articulation of the acromioclavicular (AC) joint.

J.G. Horneff III, M.D. • S. Namdari, M.D., M.Sc. (✉) • G.R. Williams, M.D.
Department of Orthopaedic Surgery, The Rothman Institute, The Sidney Kimmel
Medical College at Thomas Jefferson University, Philadelphia, PA 19107, USA
e-mail: jghorneff3@gmail.com; Surena.Namdari@rothmaninstitute.com;
Gerald.williams@rothmaninstitute.com

Sternoclavicular Dislocation

The sternoclavicular (SC) joint is the most medial articulation of the clavicle as it joins the sternum to the chest wall. SC dislocations are one of the rarest injuries to the shoulder girdle representing 1% of all joint dislocations and only 3% of all shoulder girdle dislocations [1, 2]. Dislocations can occur in either an anterior or a posterior direction with anterior dislocations being much more common. Nettles and Linscheid reported one of the first series on 60 SC dislocations and found anterior dislocations to be much more common than posterior by a ratio of 20:1 [2, 3]. More recently, Rockwood found anterior dislocations to also be more common than posterior but at a much smaller ratio of 3:1 [2, 4–6]. Many authors feel that the true ratio is hard to determine due to the fact that anterior dislocations can often go unreported and untreated [2]. Posterior dislocations, however, can place the mediastinal structures at risk and, as such, are followed and treated more aggressively.

Grading

Disruption of the sternoclavicular joint requires injury to the various ligamentous structures that serve to stabilize the joint. The sternoclavicular and costoclavicular ligaments are the two most important structures. As with any ligamentous structures, the injury to the ligaments of the SC joint can range from a simple sprain to a complete tear. These injuries are graded into three categories [7]:

First degree injury: Sprain involving stretch or incomplete tear of the sternoclavicular and costoclavicular ligaments.

Second degree injury: Subluxation of the medial clavicle in either the anterior or the posterior direction with a complete breach of the sternoclavicular ligament and only partial tearing of the costoclavicular ligament.

Third degree injury: Complete tear of the sternoclavicular and costoclavicular ligaments with subsequent dislocation of the medial clavicle from the manubrium.

History

Most sternoclavicular dislocations are a result of a high-energy trauma such as a motor vehicle accident, fall from height, or contact sports. The energy imparted on the SC joint to cause dislocation can be either direct or indirect in nature. Many consider the history of a high-energy mechanism to be a requirement for SC dislocations due to the overwhelming ligamentous stability of the SC joint. Eighty percent (80%) of SC dislocations are motor vehicle collisions or sport-related contact [2–10]. There are reports of atraumatic spontaneous SC dislocations in the setting of ligamentous laxity seen with conditions such as Ehlers Danlos syndrome, but those conditions are outside the scope of this chapter [11].

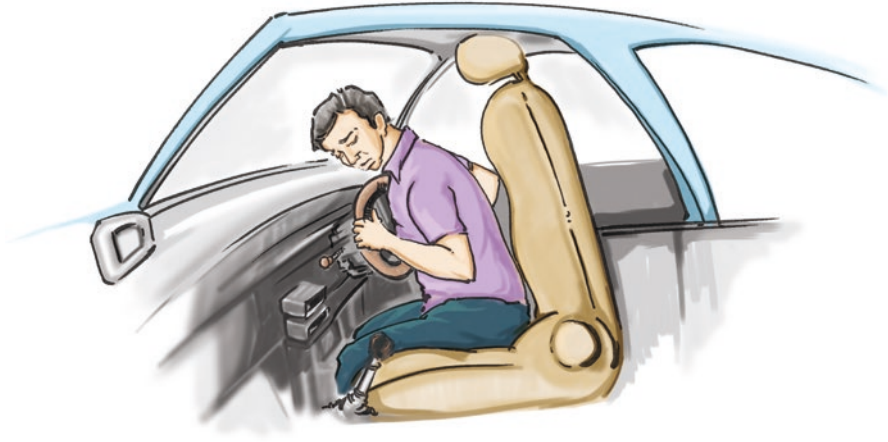

Fig. 3.1 Direct force mechanism for posterior SC dislocation

Direct Force

For direct force injuries, energy is directed at the medial clavicle with the resultant dislocation occurring in the posterior direction (Fig. 3.1). Examples of this mechanism include a patient who strikes his clavicle against the steering column in a motor vehicle accident or an athlete who receives a direct blow to the clavicle from another player. Patients with such a mechanism may have ecchymosis or abrasions to the skin overlying the area of contact, which can give further clues to the nature of the injury. It is nearly impossible for a direct force injury to cause an anterior dislocation.

Indirect Force

Indirect force injuries are much more common with the energy force directed to the lateral aspect of the clavicle as it is near the glenohumeral joint. With indirect force injuries, the medial clavicle can be dislocated either anteriorly or posteriorly. The direction of the dislocation is opposite of the force vector that was experienced by the patient. For example, if the patient experiences an anteriorly directed force to the posterior aspect of the shoulder, the medial clavicle dislocates posteriorly as the lateral clavicle is driven forward (Fig. 3.2). The opposite occurs if the shoulder experiences a posteriorly directed force with the medial clavicle dislocating anteriorly. Patients who sustain these types of injuries can have ecchymosis and abrasions over the anterolateral aspect of the shoulder girdle where the site of impact occurred. Lastly, some patients may only be able to recall a direct lateral blow to the shoulder with a medial directed force. Such a mechanism will typically have some sort of anterior or posterior component to the force as well, but the patient is unable to recall secondary to the speed and energy of the impact.

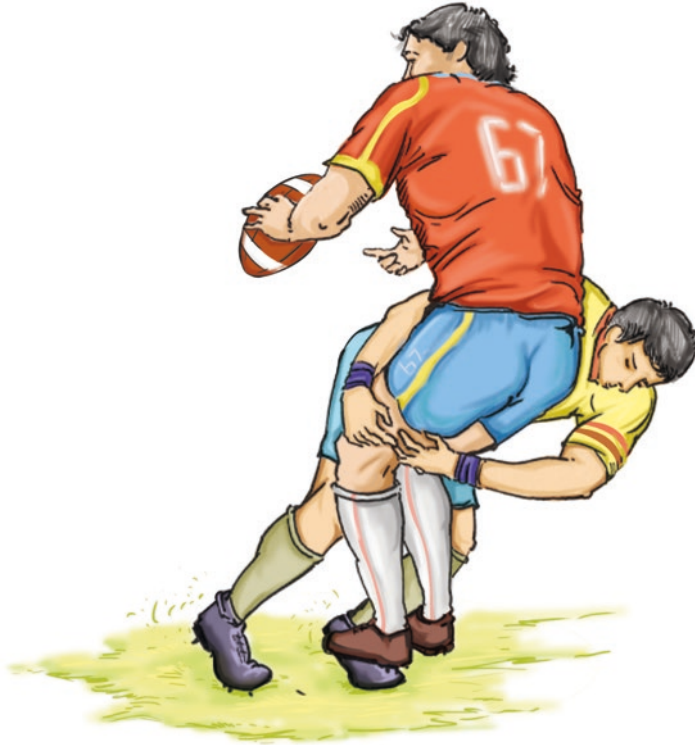

Fig. 3.2 Indirect force mechanism for posterior SC dislocation

Physical Examination

Physical examination of a patient with a suspected SC joint dislocation should be conducted in the seated or semi-reclined position. This is the best position to evaluate any patient with a suspected clavicle injury as it allows gravity to pull down the weight of the arm and accentuate any deformity.

Anterior Dislocation

Inspection of an anterior dislocation will present with a prominent medial clavicle. The integrity of the skin overlying this anterior prominence should be taken into consideration to ensure that the injury is not open from concurrent laceration or at risk of becoming open from excessive pressure on the skin. Signs of “at-risk” skin include taut, blanched, or even necrotic skin changes. If the skin displays any of these signs, the urgency to reduce the clavicle and save the soft tissue is increased. Palpation of the prominence will often be painful but can help the clinician

delineate between a palpable medial clavicle and soft tissue swelling. Lying the patient supine and moving the ipsilateral extremity in an extended position will often exacerbate the anterior deformity. Anterior dislocations of the SC joint can often be reduced with gentle posteriorly directed pressure over the medial end of the clavicle. Such a reduction may be possible upon presentation, but there is a risk of recurrent dislocation as anterior SC dislocations tend to be more unstable than their posterior counterparts.

Posterior Dislocation

Inspection of a posterior dislocation may be less obvious than an anterior dislocation. Patients with a posterior SC dislocation may still display an anterior prominence as the soft tissue swells over the underlying dislocation. Palpation of this anterior fullness can help discern between a prominent medial clavicle, corner of the sternum, or/and swollen soft tissue [3, 12]. As with an anterior dislocation, movement of the ipsilateral upper extremity can also result in increased pain but is less able to accentuate the deformity as posterior dislocations tend to be a fixed deformity. The most concerning aspect of examining a patient with a posterior SC dislocation is the appreciation of the mediastinal structures that lie posterior to the SC joint. The trachea, esophagus, great vessels, and brachial plexus are all in close vicinity to the SC joint. Ponce et al. performed a radiographic anatomical study measuring the distance between the posterior SC joint and the adjacent mediastinal structures [13] (Fig. 3.3). The authors found that many of the important cardiopulmonary structures all lay within 3 cm of the posterior SC joint with such structures as the carotid artery and brachiocephalic vein as close as 1 mm of the articulation [13]. It is important for the treating clinician to appreciate this anatomy and have serious concern for any symptoms such as venous congestion, dysphagia, dyspnea, or hoarseness. These symptoms can be a result of compromised structures of the mediastinum and increases the urgency for immediate closed versus open reduction.

Radiographic Evaluation

Plain Radiography

Although the SC joint is readily visible on routine anteroposterior (AP) chest radiographs, the interpretation of its position is often hard to discern. Standard AP chest radiographs are typically part of the trauma primary survey and, on occasion, can suggest displacement of the medial clavicle when compared to the contralateral side. Overlap of the ribs and vertebrae, however, make accuracy of diagnosis quite low [2, 12]. McCulloch et al. looked at a series of three SC dislocations and reported that a difference in the craniocaudal position of the medial clavicles that measured greater than 50% the width of the clavicular heads was suggestive of dislocation.

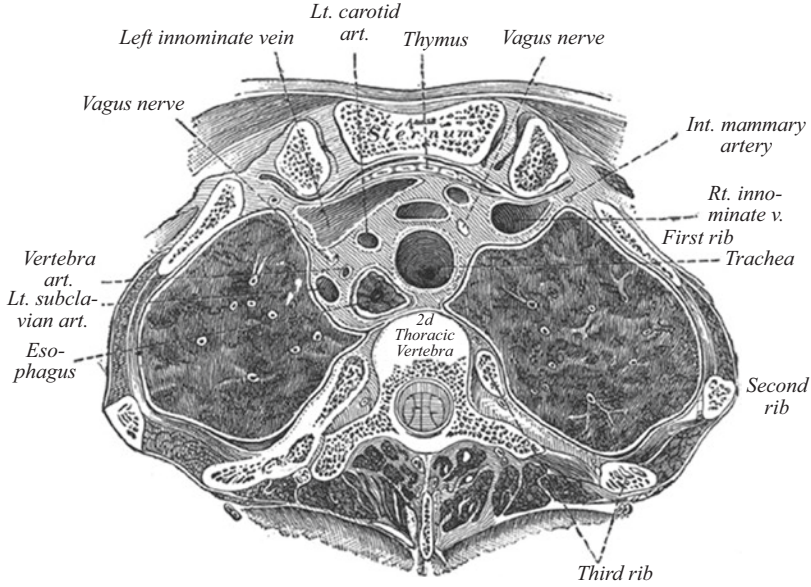


Fig. 3.3 Axial mediastinal posterior to SC joint

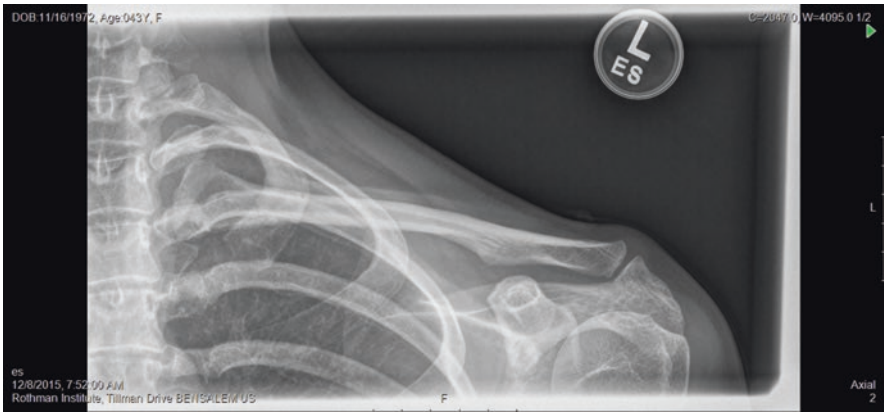

Fig. 3.4 Radiograph of serendipity view showing anterior SC dislocation

The authors acknowledged that when the diagnosis remains unclear, adjunctive imaging is indicated [14].

For plain radiography, the most common adjunctive imaging option is the “serendipity” view as described originally by Rockwood in 1975 (Fig. 3.4). For this view, the patient lies supine with the X-ray tube aimed directly at the manubrium at a 40°–45° cephalic tilt (Fig. 3.5). The X-ray cassette must be large enough to accommodate the medial halves of both clavicles [12]. On the film, a horizontal line can

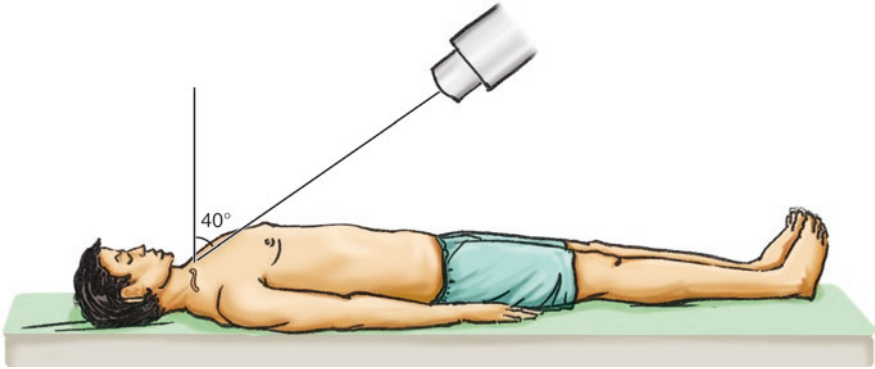


Fig. 3.5 Serendipity view patient positioning

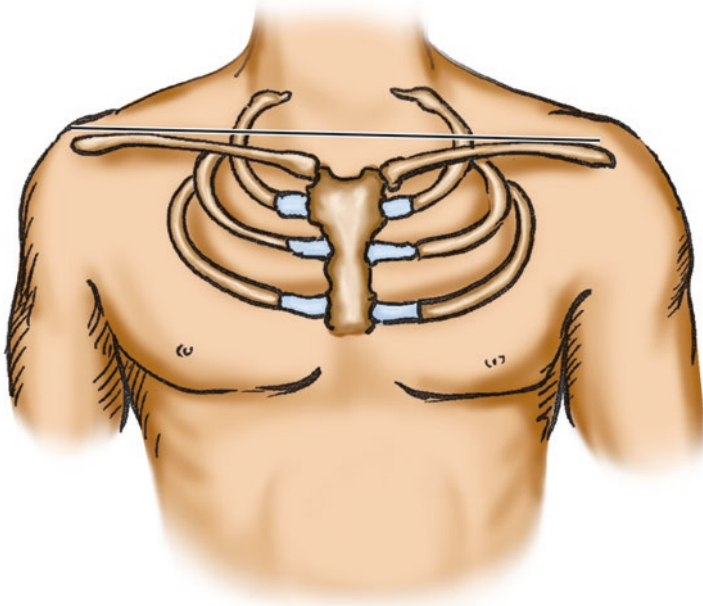
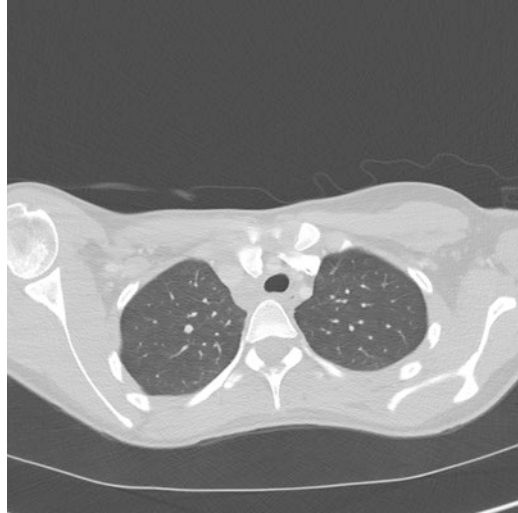

Fig. 3.6 Serendipity view with horizontal reference line showing dislocation

be drawn along the axes of both clavicles. In the case of an anterior dislocation, the medial half of the affected clavicle will project above the horizontal line drawn along the axis of the unaffected clavicle. If the patient has a posterior dislocation, then the medial half of the affected clavicle will project below this line (Fig. 3.6). Since it is impossible to accurately project the X-ray beam perpendicular to the anteroposterior plane, this view affords the clinician the view closest to this perspective.

Fig. 3.7 CT scan axial cut showing SC dislocation



Computed Tomography

Computed tomography (CT) scans are capable of achieving the axial images that are perpendicular to the anteroposterior plane that makes them unequivocally the best technique to identify an SC dislocation (Fig. 3.7). This has made CT the modality of choice for evaluating the anatomic detail of SC joint and its surrounding soft tissues [15]. In addition to providing multiple axial images that are perpendicular to the plane of dislocation, CT scans are also better able to discern between sprains, dislocations, and medial clavicle fractures [6]. Besides becoming the gold standard for SC dislocation diagnosis, many authors support the use of the CT scan in the operating room during the time of reduction. Sullivan et al. reported on two cases of posterior SC dislocation in which an intraoperative O-arm was used to verify reduction [16]. The added benefit of performing a CT scan with intravenous (IV) contrast enhancement allows for higher quality assessment of the mediastinal vasculature that may be compromised with such an injury.

Magnetic Resonance Imaging

Magnetic resonance imaging (MRI) can also be used as an imaging technique for SC dislocations. Its most useful application is in the treatment of children and young adults for determining the diagnosis between SC dislocation and medial clavicle physeal injury [12, 17]. Like the CT scan, the MRI also gives great detail of the surrounding soft tissues, gives structures within the mediastinum, and has the capability of being used with IV contrast. However, the speed of the CT scan compared to MRI makes the CT scan a more favorable imaging modality in the acute setting.

Clavicle Fracture

Unlike SC dislocations, fractures of the clavicle are a much more common injury. Fractures of the clavicle account for 2.6–5% of all fractures [18–21]. The most common region of the clavicle fractured is the middle third with 85% of fractures occurring in this portion [22, 23]. The lateral and medial clavicles are less commonly fractured at 15–21% and 3–5%, respectively [21, 24, 25]. Like SC dislocations, clavicle fractures are often the result of a high-speed fall or violent collision as seen with motor vehicle collisions, cycling accidents, and contact sports. Historically, fractures of the clavicle were considered to have a good healing prognosis. Neer initially reported a 99% union rate in over 2000 midshaft clavicle fractures treated nonoperatively [26]. Rowe similarly reported a low-nonunion rate of only 0.8% in his series of over 500 nonoperative clavicle fractures [22]. In recent years, the paradigm has shifted toward operative treatment of clavicle fractures; this is especially true regarding fractures with significant displacement or shortening. McKee et al. found a nonunion rate of nearly 15% amongst 200 clavicle fractures treated nonoperatively compared to 0% in those treated with surgery [27]. Other studies have demonstrated similar rates of nonunion much higher than originally reported [28–30]. Given the increased concern for nonunion, proper evaluation of clavicle fractures has become more imperative.

Grading

The original classification system of clavicle fractures was created by Allman who based grouping on the position of the fracture along the shaft of the clavicle:

- Group I: Fracture of the middle third of the clavicle
- Group II: Fracture of the lateral third of the clavicle
- Group III: Fracture of the medial third of the clavicle.

For fractures in Group I, further description has simply divided fractures as non-displaced and displaced. Similarly, medial fractures in Group III are further divided into only two types: anteriorly displaced and posteriorly displaced. This classifies them similarly to SC dislocations as previously discussed. For Group II fractures, the concern of a high-nonunion rate led Neer to divide these lateral clavicle fractures even further. This classification has since been modified by Craig and Rockwood to classify fracture patterns based on their relationship to the nearby coracoclavicular (CC) ligaments and acromioclavicular (AC) joint (Fig. 3.8):

- Type I: Fracture lateral to the CC ligaments but medial to the AC joint
- Type II: Medial fracture fragment detached from CC ligaments with trapezoidal ligament attached to lateral fragment

Type IIA: Both conoid and trapezoid attached to the lateral fragment

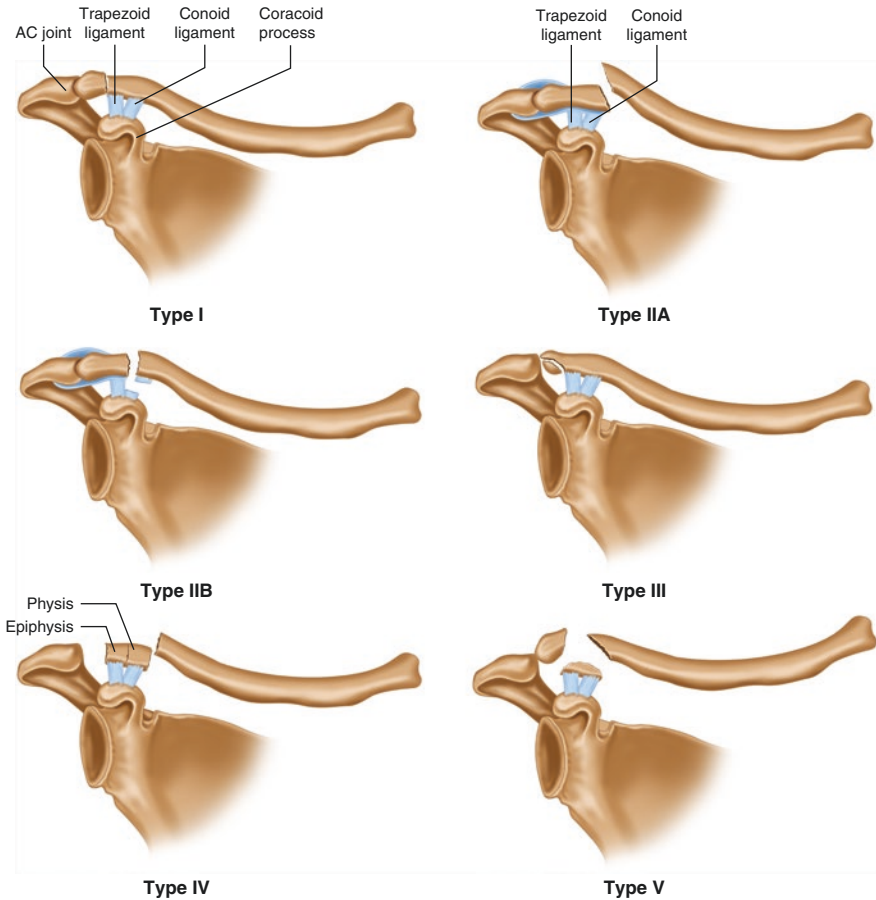


Fig. 3.8 Lateral clavicle fracture classification

Type II B: Conoid detached from medial fragment

Type III: Fracture lateral to the CC ligaments with extension into the AC joint

Type IV: Physeal fracture with epiphysis and physis adjacent to the AC joint but displacement between metaphysis and physis

Type V: Comminuted fracture with a small inferior fracture fragment attached to the CC ligaments

History

The majority of clavicle fractures occur due to a direct blow to the shoulder. This is typically the result of a high-energy mechanism with being thrown from a bicycle serving as one of the most common etiologies. Typically, the patient's ipsilateral



Fig. 3.9 Direct superior impact for lateral clavicle fracture

upper extremity is adducted at the time of impact allowing for the force of impact to occur directly to the superior aspect of the shoulder (Fig. 3.9). Stanley et al. looked at the mechanism of over 100 clavicle fractures and found that 87% were a result of a fall directly onto the shoulder, 7% were caused by a direct blow to the point of the shoulder, and 6% resulted from a fall on an outstretched hand [31]. Even among those patients who described their injury as involving an outstretched limb, the authors suggested the secondary impact occurring directly at the shoulder. For most patients, the history of a high-energy fall will correlate with injury findings. Low-energy mechanisms, such as a fall from standing height, are less likely to cause a clavicle fracture except for in the elderly, osteoporotic, or pathologic setting.

Physical Examination

Physical examination of the clavicle is best performed with the patient in the standing or seated position to allow gravity to exaggerate the deformity of the shoulder girdle. Patients will typically have swelling, ecchymosis, and potentially an abrasion overlying the area of the fracture. The integrity of the skin should be carefully considered, as a sharp end of a fracture fragment can tent the overlying soft tissue. Any open lacerations, blanching, or necrosis of the skin should raise concern for an open fracture and increase the urgency for irrigation and reduction to reduce the risk of infection. Despite its superficial location in relation to the skin, open fractures of the clavicle are a rare injury. When they do occur, they typically are a result of a high-energy mechanism such as a motor vehicle collision. Taitsman et al. examined 20 patients with open clavicle fractures and found that the vast majority had an associated high-energy injury including closed head trauma, pneumothorax, vertebral fractures, or scapulothoracic dissociation [32].

The deformity of medial and lateral clavicle fractures may be little more than a prominence of the fragments at the fracture site. In the case of severely displaced midshaft fractures or lateral fractures with disruption of the CC ligaments, the shoulder may present as inferiorly displaced, shortened, and anteriorly rotated. Some authors have described this posturing as shoulder “ptosis.” [21, 33, 34] The

forward rotation of the shoulder girdle can often be appreciated by standing behind the patient and observing a slight prominence of the inferior border of the scapula as it rotates forward with the unsupported distal clavicle. Lastly, as mentioned at the beginning of this chapter regarding all clavicle injuries, a thorough neurovascular examination of the ipsilateral upper extremity should be conducted as injuries to the subclavian vessels and brachial plexus can also result from the mechanism of injury.

Radiographic Evaluation

Plain Radiography

Unlike SC dislocations, clavicle fractures are more easily appreciated on routine AP chest radiographs acquired during a primary survey. A well performed AP chest radiograph should include both clavicles, allowing the injured clavicle to be compared to the contralateral normal. If possible, the radiograph should be performed with the patient in an upright position to accentuate the deformity of the fracture just as one would do on physical examination. Supplementation of the AP radiograph with a 20°–60° cephalic tilt radiograph involving both clavicles can help better define the displacement, comminution, and rotation of the fracture fragments (Fig. 3.10). On both views, the length of the affected and normal clavicle can be compared to determine the degree of shortening. Shortening of 2 cm or more is considered a relative indication for internal fixation [35]. Regardless of which view is obtained, it is best to include both clavicles in the radiograph to better determine the degree of shortening and deformity. Jones et al. found that standard plain unilateral radiographs of the clavicle were insufficient as both inter- and intraobserver agreement on the degree of shortening was weak [36]. The authors suggested views of the contralateral clavicle to assist in the decision making for surgical indication. Interestingly, Smekal et al. compared various views of the clavicle to the gold standard of CT scan and found that a posteroanterior thorax radiograph involving both

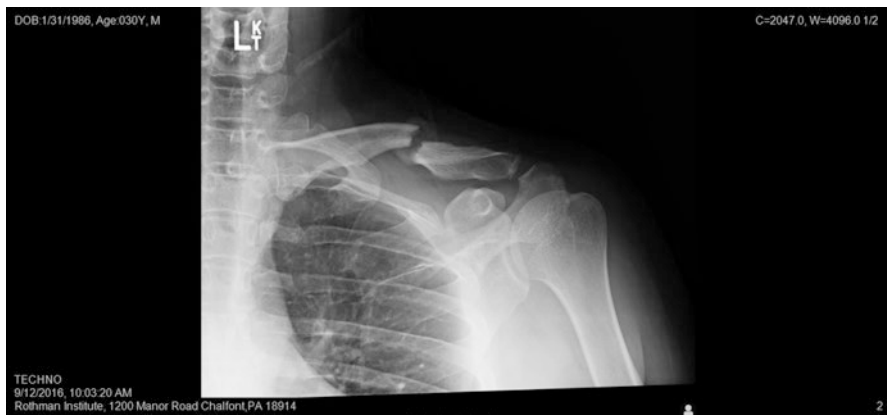

Fig. 3.10 Radiograph of clavicle fracture with cephalic tilt

clavicles provided the highest agreement with CT [21, 37]. The authors of this chapter recommend that multiple views of the clavicle be performed with preferable inclusion of the contralateral clavicle if there are questionable indications for surgery.

For medial clavicle fractures, plain radiography is a difficult imaging modality to provide the most accurate assessment. Therefore, like the closely related SC dislocation, a “serendipity” view may be performed. If ambiguity still remains, then CT scan is recommended.

Lastly, for lateral clavicle fractures, an AP chest radiograph involving both clavicles can likely demonstrate the fracture. As an adjunct to this, the Zanca view that involves a 15° cephalic tilt centered over the AC joint can help decrease the overlap of the upper thoracic ribs and better define the fracture pattern. The use of 5–10 lb weights in the ipsilateral upper extremity can be utilized as a stress view to exaggerate the deformity [21]; however, this technique is uncommonly used by the authors in clinical practice.

Computed Tomography

With the exception of medial clavicle fractures, the need for CT scan in the diagnosis and evaluation of most clavicle fractures is unnecessary (refer to the section on computed tomography for sternoclavicular dislocations for the technique and evaluation of medial clavicle fractures).

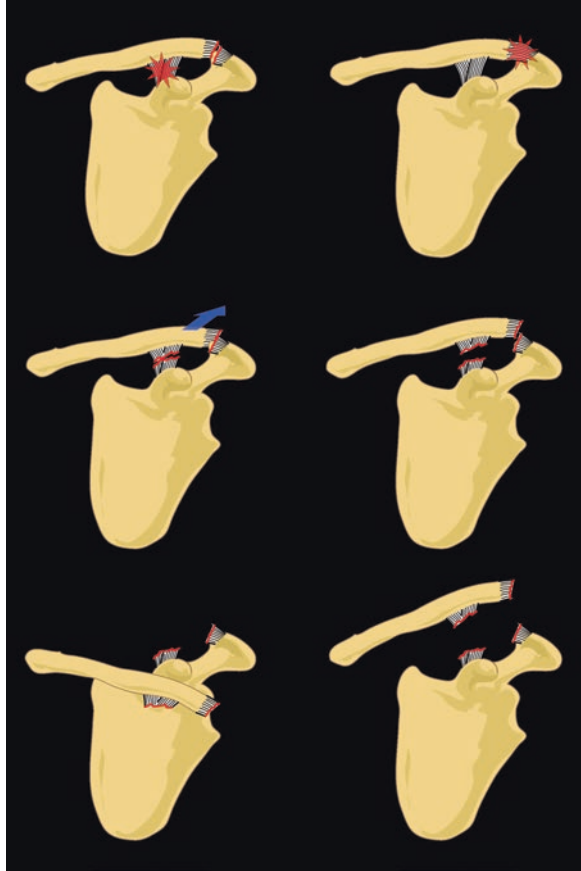
Acromioclavicular Dislocation

Acromioclavicular (AC) joint injuries constitute a third to half of all athletic shoulder injuries [38–41]. Overall, AC joint injuries account for almost 10% of all injuries to the shoulder girdle [42]. Depending on the severity of the injury, a dislocation of the AC joint or “shoulder separation” can involve damage to the AC joint capsule, coracoclavicular (CC) ligaments, or even the nearby trapezius and deltoid muscle tissue. The degree of medial clavicle displacement relative to the acromion is dependent on the degree of injury to these AC and CC ligaments. Although the evaluation of AC joint injuries is approached very similar to other injuries involving the clavicle, their subsequent treatment remains one of the most controversial topics in orthopaedic surgery.

Grading

The original classification of AC joint injuries was created by Tossy et al. and Allman in the 1960s [43, 44]. Two decades later, Rockwood modified the classification [45]. Based strongly on static plain radiographic findings, there is criticism in

Fig. 3.11 Rockwood classification of AC separations



this classification system as many treating clinicians believe that the dynamic physical examination is necessary to determine the proper treatment plan. Regardless, the Rockwood Classification is often quoted when describing AC injuries in the literature and clinical setting (Fig. 3.11).

Type I: Sprain of the AC ligaments. No injury to the CC ligaments. No radiographic abnormality.

Type II: Tear of the AC ligaments. Sprain of the CC ligaments. Slight elevation of the clavicle relative to the coracoid on radiographs. No increase in CC distance on stress view.

Type III: Tear of the AC ligaments. Tear of the CC ligaments. CC distance is increased 25–100%.

Type IV: Tear of the AC ligaments. Tear of the CC ligaments. Clavicle is displaced posteriorly on the axillary view.

Type V: Tear of the AC ligaments. Tear of the CC ligaments. CC distance is increased 100–300% with concern of disruption of the trapezial and deltoid fascia.

Type VI: Tear of the AC ligaments. Tear of the CC ligaments. Distal clavicle is displaced inferiorly either subacromial or subcoracoid.

History

Like a lateral clavicle fracture, the majority of AC injuries occur from a direct blow to the lateral point of the shoulder with the arm typically in the adducted position [38, 42]. This direct force injury drives the acromion inferiorly and medially relative to the lateral clavicle. This is an important concept to realize as many patients will think that their deformity is caused by the clavicle “sticking up.” Instead, it is the superolateral impact on the acromion that drives the acromion downward while the sternoclavicular joint ligaments maintain the position of the clavicle [46]. The weight of the ipsilateral upper extremity to gravity will continue to keep the acromion displaced inferior to the clavicle with some mild upward pull on the clavicle from an unopposed trapezius. For the rare inferior clavicular dislocation (Type VI), it is believed that the severe force is directed more onto the distal clavicle rather than the acromion while the arm is abducted rather than adducted [47].

Like the prior clavicle injuries described in this chapter, injuries to the AC joint are typically the result of a high-energy mechanism with motor vehicle collisions, bicycle accidents, falls from height, and contact sports as the leading causes. Obtaining a complete history from the patient can help to determine the amount of energy imparted on the patient at the time of injury. This information along with radiographs are helpful in determining the degree of injury to the stabilizing soft tissues as they fail systematically in the following order: (1) AC ligaments and capsule, (2) CC ligaments, (3) deltotrapezial fascia.

Physical Examination

Physical examination for AC joint injuries should also be performed with the patient in the standing or seated position to allow gravity to exaggerate the deformity of the shoulder girdle. Depending on the degree of injury, there may be little swelling or an obvious deformity. For Type I injuries where there is no displacement between the clavicle and acromion, there is often tenderness to palpation over the AC joint with possible mild swelling and ecchymosis. Moving the patient’s ipsilateral upper extremity may cause an exacerbation of pain. For Type II injuries, the AC ligaments are disrupted leading to increased instability of the AC joint in the anteroposterior plane. Gentle palpation and examiner-guided movement in this direction will elicit pain. Since the CC ligaments remain intact, there should be no instability in the superoinferior plane, but slight prominence of the distal clavicle may be noted. A Type III injury is the first type to involve disruption of both the AC and CC ligaments. Patients will have a noticeable prominence of the distal clavicle that is painful upon palpation. The patient will typically hold the arm in an adducted and elevated position via support from the contralateral arm or a sling to help relieve the painful stress at the AC joint. Since both the AC and CC ligaments are disrupted, the lateral clavicle will be passively unstable to both horizontal and vertical stress. The most important physical exam finding for a Type III injury is the ability to reduce the AC joint with upward

support on the ipsilateral elbow. If this is not possible, the concern for a Type IV or V injury. Type IV and V injuries will examine quite similar to a Type III with the following exceptions: (1) no reduction possible with manipulation of the arm and (2) the distal clavicle is tenting the skin as it violates the deltopectoral fascia posteriorly (Type IV) or superiorly (Type V). Lastly, the rare Type VI will often present much differently than all the prior types. Since the distal clavicle is dislocated inferiorly, the superior aspect of the shoulder will have a flat appearance with a slight prominence of the acromion and a void just medially beneath the soft tissue as the clavicle rests beneath the coracoid. The high energy necessary to create a Type VI should raise the concern for a neurovascular injury as the lateral clavicle presses down on structures below. As with all injuries, examination of the head, neck, chest, and ipsilateral extremity should be performed to rule out concurrent injuries.

Radiographic Evaluation

Plain Radiography

Routine anteroposterior radiographs are best performed with the patient in an upright position to accentuate the deformity of the fracture. Since the AC joint is more superficial than the glenohumeral joint, a reduced penetration strength X-ray will likely allow better visualization of the clavicle and acromion. As previously described for SC joint dislocations and clavicle fractures, it is best to capture both AC joints on one single radiographic image whenever possible to allow for bilateral comparison. In 1971, Zanca recognized that standard AP images would often have overlap of the scapular spine on the AC joint [48]. After assessing 1000 radiographs in the standard AP projection, he recommended a cephalic tilt of 10° – 15° to the X-ray beam, which eliminated this overlap [48] (Fig. 3.12). This “Zanca” view is

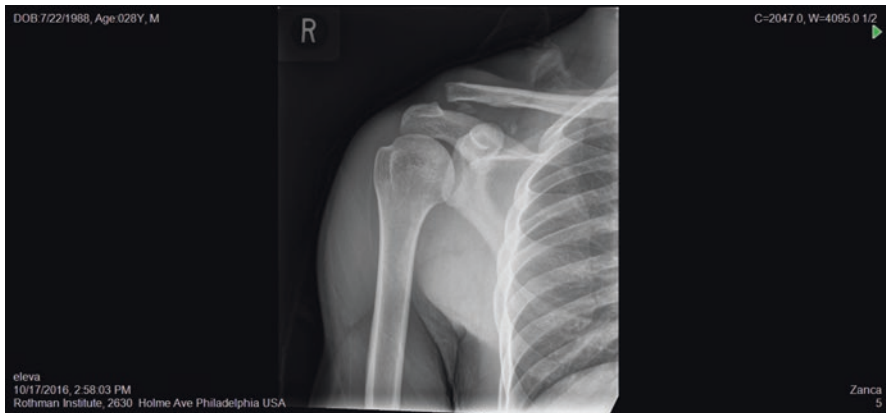


Fig. 3.12 Radiograph Zanca view of AC separation

now part of the standard series of radiographs for evaluating AC joint injuries. This view allows for assessment of even the subtlest displacement or fracture fragment. For assessing anteroposterior displacement, especially in Type IV injuries, an axillary view is recommended. Lastly, the Stryker notch view is helpful when there is concern for a concomitant coracoid fracture. This view places the coracoid on profile and is best suited for when AP films display an AC dislocation but with a normal CC distance. This view is performed with the patient placing the ipsilateral hand on top of the head and the beam tilted 10° – 15° cephalad.

Computed Tomography and Other Advanced Imaging

Unlike the more medially based clavicle injuries, the plain radiograph films described earlier are often suitable for diagnosing and evaluating AC joint injuries. In addition to being easy to obtain and most cost-effective, plain radiographs alone are considered sufficient. Any advanced imaging obtained, such as in the setting of the polytrauma patient, can certainly be used to supplement decision making.

References

1. Cave EF. Fractures and other injuries. Chicago: Year Book Medical Publishers; 1958. p. 258–9.
2. Kalandiak SP, Spencer EE Jr, Wirth MA, Rockwood CA. Acute repair and reconstruction of sternoclavicular dislocation. In: Williams GR, Ramsey ML, Wiesel BB, editors. Orthopaedic techniques in shoulder and elbow surgery. Philadelphia: Wolters Kluwer; 2016. p. 240–51.
3. Nettles JL, Linscheid R. Sternoclavicular dislocations. *J Trauma*. 1968;8(2):158–64.
4. Rockwood CA, Wirth MA. Disorders of the sternoclavicular joint. In: Rockwood CA, Matsen FA, editors. The shoulder. 2nd ed. Philadelphia: WB Saunders; 1998. p. 555–609.
5. Groh GI, Wirth MA, Rockwood CA. Treatment of posterior sternoclavicular dislocations. *J Shoulder Elb Surg*. 2011;20(1):107–13.
6. Groh GI, Wirth MA. Management of traumatic sternoclavicular joint injuries. *J Am Acad Orthop Surg*. 2011;19(1):1–7.
7. Medvecky MJ, Zuckerman JD. Sternoclavicular joint injuries and disorders. *Instr Course Lect*. 2000;49:397–406.
8. Mehta JC, Sachdev A, Collins JJ. Retrosternal dislocation of the clavicle. *Injury*. 1973; 5(1):79–83.
9. Waskowitz WJ. Disruption of the sternoclavicular joint: an analysis and review. *Am J Orthop*. 1961;3:176–9.
10. Van Lancker HP, Martineau PA. The diagnosis and treatment of shoulder injuries in contact and collision athletes. *Orthop Trauma*. 2012;26(1):1–11.
11. Qureshi SA, Shah AK, Pruzansky ME. Using the semitendinosus tendon to stabilize sternoclavicular joints in a patient with Ehlers-Danlos syndrome: a case report. *Am J Orthop (Belle Mead NJ)*. 2005;34(7):315–8.
12. Dutta AK, Wirth MA, Rockwood CA. Sternoclavicular joint injuries. In: Bucholz RW, Court-Brown CM, Heckman JD, Tornetta P, editors. Rockwood and Green's fractures in adults. 7th ed. Philadelphia: Lippincott, Williams, & Wilkins; 2010. p. 1243–75.
13. Ponce BA, Kundukulam JA, Pfluger R, et al. Sternoclavicular joint surgery: how far does danger lurk below? *J Shoulder Elb Surg*. 2013;22(7):993–9.

14. McCulloch P, Henley BM, Linnau KF. Radiographic clues for high-energy trauma: three cases of sternoclavicular dislocation. *Am J Roentgenol.* 2001;176(6):1534.
15. Restrepo CS, Martinez S, Lemos DF, et al. Imaging appearances of the sternum and sternoclavicular joints. *Radiographics.* 2009;29(3):839–59.
16. Sullivan JP, Warne BA, Wolf BR. Use of an O-arm intraoperative computed tomography scanner for closed reduction of posterior sternoclavicular dislocation. *J Shoulder Elb Surg.* 2012;21(3):e17–20.
17. Ozer UE, Yalcin MB, Kanberoglu K, Bagatur AE. Retrosternal displacement of the clavicle after medial physeal fracture in an adolescent: MRI. *J Pediatr Orthop B.* 2014;23(4):375–8.
18. Jeray KJ. Acute midshaft clavicular fracture. *J Am Acad Orthop Surg.* 2007;15(4):239–48.
19. Postacchini F, Gumina S, DeSantis P, Albo F. Epidemiology of clavicle fractures. *J Shoulder Elb Surg.* 2002;11(5):452–6.
20. Nordqvist A, Petersson C. The incidence of fractures of the clavicle. *Clin Orthop Relat Res.* 1994;300:127–32.
21. McKee M. Clavicle fractures. In: Bucholz RW, Court-Brown CM, Heckman JD, Tornetta P, editors. *Rockwood and Green's fractures in adults.* 7th ed. Philadelphia: Lippincott, Williams, & Wilkins; 2010. p. 1106–43.
22. Rowe CR. An atlas of anatomy and treatment of midclavicular fractures. *Clin Orthop Relat Res.* 1968;58:29–42.
23. Robinson CM. Fractures of the clavicle in the adult: epidemiology and classification. *J Bone Joint Surg Br.* 1998;80(3):476–84.
24. Robinson CM, Cairns DA. Primary nonoperative treatment of displaced lateral fractures of the clavicle. *J Bone Joint Surg Am.* 2004;86-A(4):778–82.
25. Khan LA, Bradnock TJ, Scott C, Robinson CM. Fracture of the clavicle. *J Bone Joint Surg Am.* 2009;91(2):447–60.
26. Neer C. Nonunion of the clavicle. *JAMA.* 1960;172:1006–11.
27. McKee RC, Whelan DB, Schemitsch EH, McKee MD. Operative versus nonoperative care of displaced midshaft clavicular fractures: a meta-analysis of randomized clinical trials. *J Bone Joint Surg Am.* 2012;94(8):675–84.
28. McKnight B, Heckmann N, Hill JR, et al. Surgical management of midshaft clavicle nonunions is associated with a higher rate of short-term complications compared with acute fractures. *J Shoulder Elb Surg.* 2016;25(9):1412–7.
29. Hill JM, McGuire MH, Crosby LA. Closed treatment of displaced middle-third fractures of the clavicle gives poor results. *J Bone Joint Surg Br.* 1997;79(4):537–9.
30. Zlowdowski M, Zelle BA, Cole PA, et al. Treatment of acute midshaft clavicle fractures: systematic review of 2144 fractures: on behalf of the Evidence-Based Orthopaedic Trauma Working Group. *J Orthop Trauma.* 2005;19(7):504–7.
31. Stanley D, Trowbridge EA, Norris SH. The mechanism of clavicular fracture. A clinical and biomechanical analysis. *J Bone Joint Surg Br.* 1988;70(3):461–4.
32. Taitsman LA, Nork SE, Coles CP, Barei DP, Agel J. Open clavicle fractures and associated injuries. *J Orthop Trauma.* 2006;20(6):396–9.
33. Owens BD, Goss TP. The floating shoulder. *J Bone Joint Surg Br.* 2006;88(11):1419–24.
34. Rikli D, Regazzoni P, Renner N. The unstable shoulder girdle: early functional treatment utilizing open reduction and internal fixation. *J Orthop Trauma.* 1995;9(2):93–7.
35. Thormodsgard TM, Stone K, Ciraulo DL, Camuso MR, Desjardins S. An assessment of patient satisfaction with nonoperative management of clavicular fractures using the disabilities of the arm, shoulder, and hand outcome measure. *J Trauma.* 2011;71(5):1126–9.
36. Jones GL, Bishop JY, Lewis B, Pedroza AD; MOON Shoulder Group. Intraobserver and interobserver agreement in the classification and treatment of midshaft clavicle fractures. *Am J Sports Med.* 2014;42(5):1176–81.
37. Smekal V, Demi C, Irenberger A, et al. Length determination in midshaft clavicle fractures: validation of measurement. *J Orthop Trauma.* 2008;22(7):458–62.

38. Simovitch R, Sanders B, Ozbaydar M, Lavery K, Warner JJP. Acromioclavicular joint injuries: diagnosis and management. *J Am Acad Orthop Surg.* 2009;17(4):207–19.
39. Kaplan LD, Flanigan DC, Norwig J, Jost P, Bradley J. Prevalence and variance of shoulder injuries in elite collegiate football players. *Am J Sports Med.* 2005;33(8):1142–6.
40. Dragoo JL, Braun HJ, Bartlinski SE, Harris AH. Acromioclavicular joint injuries in National Collegiate Athletic Association football: data from the 2004-2005 through 2008-2009 National Collegiate Athletic Association Injury Surveillance System. *Am J Sports Med.* 2012;40(9):2066–71.
41. Stucken C, Cohen SB. Management of acromioclavicular joint injuries. *Orthop Clin North Am.* 2015;46(1):57–66.
42. Galatz LM, Hollis RF, Williams GR. Acromioclavicular joint injuries. In: Buchholz RW, Court-Brown CM, Heckman JD, Tornetta P, editors. *Rockwood and Green's fractures in adults.* 7th ed. Philadelphia: Lippincott, Williams, & Wilkins; 2010. p. 1210–42.
43. Tossy JD, Mead NC, Sigmond HM. Acromioclavicular separations: useful and practical classification for treatment. *Clin Orthop Relat Res.* 1963;28:111–9.
44. Allman FL. Fractures and ligamentous injuries of the clavicle and its articulation. *J Bone Joint Surg.* 1967;49(4):774–84.
45. Williams GR, Nguyen VD, Rockwood CA. Classification and radiographic analysis of acromioclavicular dislocations. *Appl Radiol.* 1989;18(2):29–34.
46. Rios CG, Arciero RA, Mazzocca AD. Anatomy of the clavicle and coracoid process for reconstruction of the coracoclavicular ligaments. *Am J Sports Med.* 2007;35(5):811–7.
47. McPhee IB. Inferior dislocation of the outer end of the clavicle. *J Trauma.* 1980;20(8):709–10.
48. Zanca P. Shoulder pain: involvement of the acromioclavicular joint (Analysis of 1,000 cases). *Am J Roentgenol Radium Ther Nucl Med.* 1971;112(3):493–506.

Chapter 4

Imaging of the Clavicle

Harry G. Greditzer IV, Ian D. Hutchinson, and Hollis G. Potter

Introduction

The shoulder girdle is composed of three synovial articulations: the glenohumeral, the acromioclavicular (AC), and the sternoclavicular (SC) joints. The clavicle serves as the bridge between the AC and SC joints. The purpose of this chapter is to discuss imaging of the clavicle including the AC and SC joints. Radiography is the most frequently used modality in the initial assessment of clavicular fractures as well as injuries to both AC and SC joints. Radiography is ideal for the initial evaluation of clavicular fractures with only mild displacement; however, there are significant limitations in the assessment of posteriorly displaced clavicular fractures and in AC and SC joint examination due to the inability of radiographs to delineate the requisite soft tissues. Thus, magnetic resonance imaging (MRI), and to a lesser degree computed tomography (CT), are often warranted to complete a comprehensive radiological assessment of these injuries. At the present time, ultrasound has limited utility in the acute setting and is mainly used to guide therapeutic and/or diagnostic injections of both the SC and AC joints.

H.G. Greditzer IV, M.D., M.Sc. (✉)
Department of Radiology and Imaging, Hospital for Special Surgery,
New York, NY 10021, USA
e-mail: GreditzerH@HSS.EDU

I.D. Hutchinson, M.D.
Department of Sports and Shoulder Surgery, Hospital for Special Surgery,
New York, NY 10021, USA
e-mail: hutchinsoni@hss.edu

H.G. Potter, M.D.
Department of Radiology and Imaging, Hospital for Special Surgery, Weill Medical College
of Cornell University, New York, NY 10021, USA
e-mail: potterh@hss.edu

Radiography of the Clavicle

There are numerous classification systems used to describe clavicular fractures. Commonly, fractures are divided by anatomic location, into thirds, by the Allman classification [1]. However, despite its popularity, the Allman classification does not take into account the presence of comminution or displacement of fracture fragments. The Neer modification of the Allman classification subdivided distal clavicular fractures based on the integrity of the coracoclavicular ligament (CC) and AC joint [2]. Craig subsequently adjusted the classification system, to include medial fractures, degree of comminution, displacement and joint involvement [3]. A more useful classification was proposed by Robinson, who divided the fractures into three basic types with further subdivision based on displacement, angulation, intra-articular extension, and comminution [4]. Regardless of the classification system used, it is important for the orthopedic surgeon to carefully scrutinize the images, to identify all abnormalities present and then determine appropriate treatment.

Imaging of the clavicle usually begins with standard radiography like most other orthopaedic trauma. Radiographs should always be taken in two projections, as this is necessary to evaluate the fracture pattern, presence of comminution, or displacement. To further delineate the displacement of the fracture, a standard anteroposterior (AP) view and a cephalic tilt (axial) view are necessary. It is essential that the radiographs include both the acromioclavicular (AC) and sternoclavicular (SC) joints to avoid missing associated injuries [5]. Furthermore, it is prudent to pay close attention to the upper lung fields to avoid missing associated rib fractures or a pneumothorax, which are not infrequent (Fig. 4.1).

The standard AP view of the clavicle is taken with the patient upright or sitting, with arms at the sides, chin raised, and looking straight ahead. The posterior shoulder should be in contact with image receptor (IR) or tabletop, without rotation

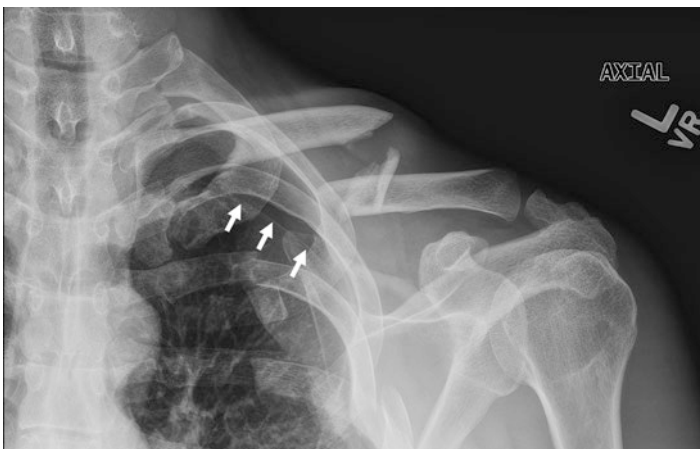

Fig. 4.1 AP axial radiograph of the left clavicle demonstrates a comminuted fracture with associated rib fractures and a moderate-sized pneumothorax (*arrows*)

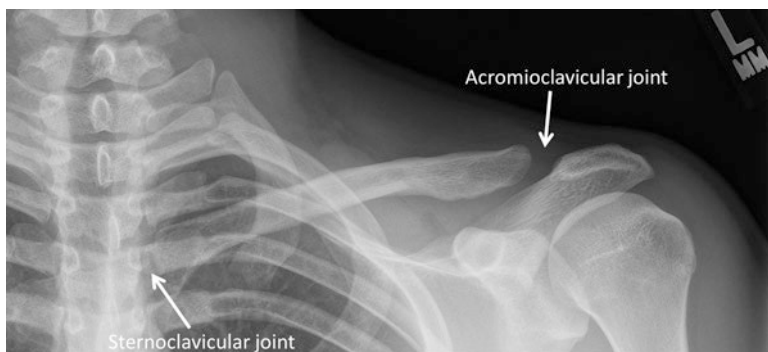

Fig. 4.2 AP radiograph of a normal left clavicle. Both the AC and SC joints are visible (*arrows*) and the entire clavicle is seen

of body. In this position, the central ray (CR) should be perpendicular to the mid-shaft of the clavicle. The collimation border should be visible with the entire clavicle visualized, including both AC and SC joints (Fig. 4.2).

The standard axial view of the clavicle is taken with the patient in a similar position; however, the CR should be angled 15–30° cephalic to the patient. Note is made that in thinner patients, a greater angle may be needed. Correct angulation of CR will project most of the clavicle above the scapula and ribs. It should be noted that only the medial portion of the clavicle will be superimposed by the first and second ribs. Both posteroanterior (PA) and PA axial views of the clavicle can also be obtained if the patient is unable to tolerate the AP position. In this position, the patient's chest should be pressed against the IR or tabletop.

Computed Tomography (CT) of the Clavicle

CT scanning is of little diagnostic value in an acute clavicle injury and is often reserved for cases of suspected neurovascular and/or visceral injury; CT angiogram is indicated in the setting of a distal vascular deficit following a clavicle fracture. The other utility of CT lies in the evaluation of delayed union or non-union of a clavicle fracture.

The patient is placed in the scanner in the supine and neutral position, with the arms at their sides. If the study aims to primarily evaluate the fracture, intravenous contrast material would not typically be used. Depending on the area to be scanned, the spiral length will generally vary from 30 to 40 s. Depending on the scanner used, a pitch up to 2 will be satisfactory [6]. Additionally, slice thickness is usually between 2 and 3 mm. Data reconstruction should be in 1 mm increments and using high (or ultra-high) reconstruction mode, which makes the images sharper [7]. Generation of both coronal and sagittal reformatted images is standard practice in the diagnostic CT imaging. Because of the obliquity of the clavicle, three-dimensional (3D) recon-

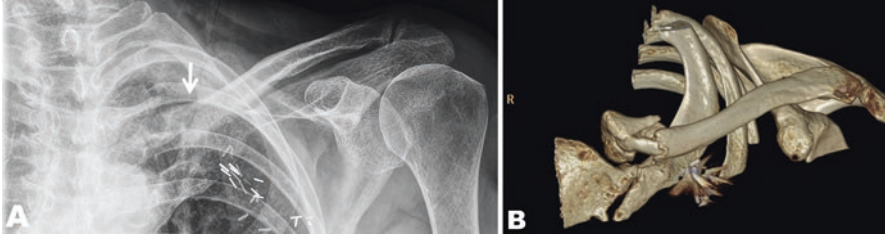


Fig. 4.3 (a) AP radiograph demonstrates a comminuted fracture of the medial third of the clavicle. (b) CT 3D reformatted image of the clavicle demonstrates distraction, angulation, and fragmentation

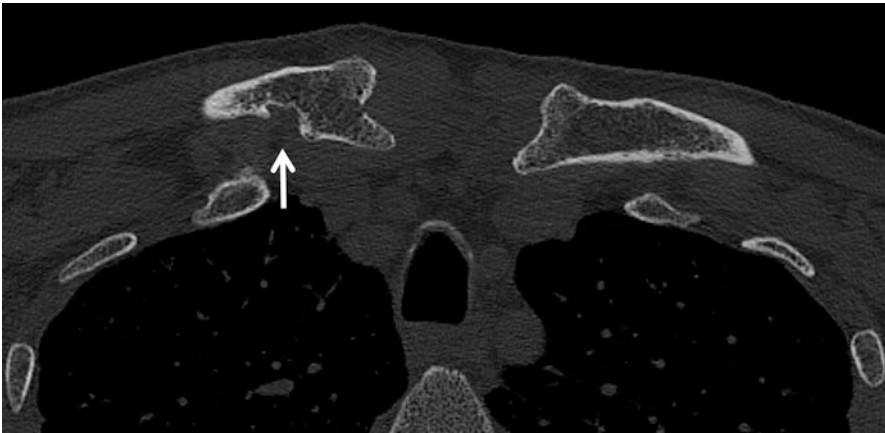


Fig. 4.4 Axial CT of the chest demonstrates a prominent but normal rhomboid fossa (*arrow*) of the right clavicle. Note its irregular appearance

structions are an excellent illustration of the fracture (Fig. 4.3). Recently, the development of 3D printing for fracture modeling has been used to help the surgeon manipulate accurate anatomical replicas of the fractured bone to assist in fracture reduction prior to surgery [8].

An important pitfall during the interpretation of clavicular fractures with CT relates to correctly identifying the rhomboid fossa, which is a variable and frequently irregular concavity on the undersurface of the medial clavicle above the costal cartilage of the first rib, being more common in males. The normal variant should not be mistaken for a lytic or erosive process (Fig. 4.4). It is also important to comment on several muscles that have their origins or insertions on the clavicle. Of the many surrounding muscles, the trapezius plays the most important role in clavicular support [9]. The sternohyoid and sternothyroid muscles should also be assessed medially as well as the subclavius and deltoid attachments.

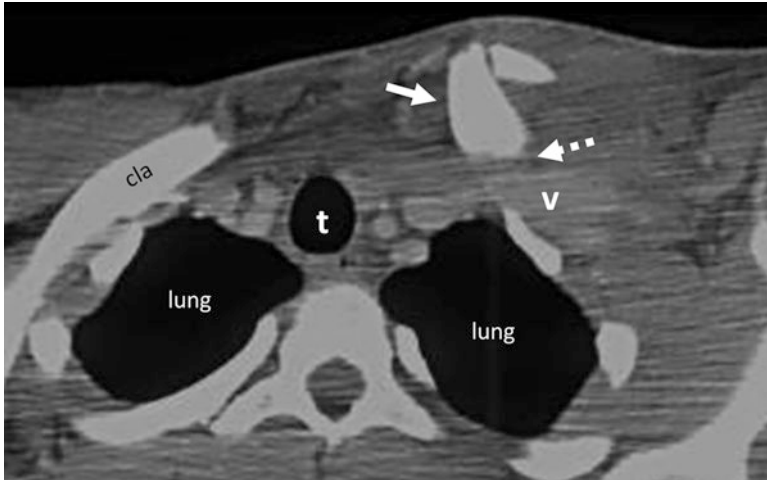


Fig. 4.5 Displaced fracture of the medial third of the clavicle (*arrow*) demonstrates close approximation to the brachiocephalic vein (*v*). However, a clear fat plane between the fragment and vein demonstrates absence of vascular injury (*dotted arrow*). *cla* clavicle, *t* trachea

Medial clavicular fractures are uncommon and comprise 2–3% of all clavicle fractures [10]. Most medial clavicle fractures are non-displaced, do not involve the SC joint, and are usually managed non-operatively. Conversely, a posterior-directed fracture has the potential to injure superior mediastinal structures. These types of fractures should be evaluated preferably with CT angiography to exclude vascular injury and closed or open reduction should be performed in an emergent fashion to reduce the displaced fragment (Fig. 4.5) [11].

While the incidence of clavicular non-unions is low (0.1–15%), they can cause significant discomfort and deformity in these patients [4]. Clavicular non-unions are best evaluated with CT that typically demonstrates sclerotic margins as well as 3D anatomy (Fig. 4.6). Additionally, the presence of infection can be readily evaluated with CT demonstrating periostitis, bone resorption, as well as surrounding soft tissue edema and fluid. If indicated, aspiration for culture and sensitivity can subsequently be performed under ultrasound or CT guidance by the clinician (Fig. 4.7).

CT is also useful in evaluating hardware failure and related complications. Steel alloys are commonly used in fixation hardware and constitute most of the hardware used by orthopaedic trauma surgeons. One of the benefits of multi-detector row CT (MDCT) is its capability to reduce the severity of metal or streak artifacts. These streak artifacts are essentially photopenic holes or black holes, in the X-ray beam projection [12]. With MDCT, adjacent channels pick up excess tissue irradiation in the penumbra of the beam, which partially fills these “black holes” [13]. Other techniques that contribute to the lessening of metal artifacts include augmentation of peak kilovoltage (kV) and tube current settings, as well as the use of decreased

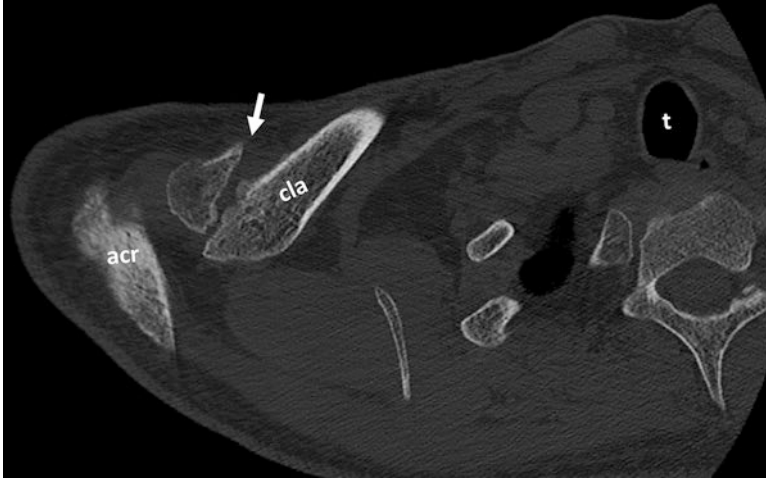

Fig. 4.6 Axial non-contrast CT scan of the right clavicle demonstrates a fracture of the distal third of the clavicle with sclerosis of the fracture edges representative of non-union (*arrow*). *acr* acromion, *cla* clavicle, *t* trachea

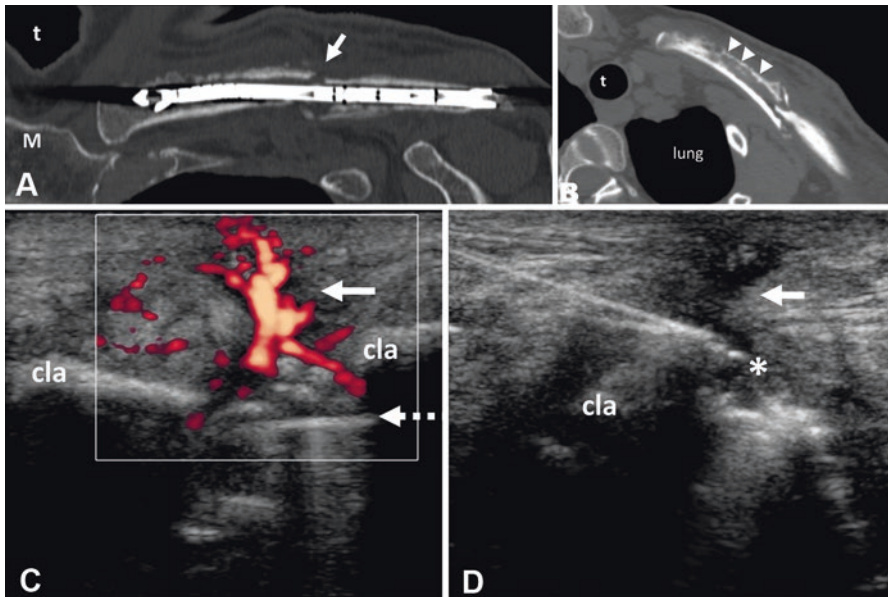


Fig. 4.7 (a) Coronal and (b) axial CT of the left clavicle demonstrates bone resorption (*arrow-heads*) around the intramedullary rod with periostitis (*arrow*). (c) Subsequent ultrasound evaluation of the area demonstrated increased power Doppler flow, representing hyperemia (*arrow*) and suggestive of infection. The intramedullary rod is seen as an echogenic line (*dotted arrow*). (d) Subsequent ultrasound-guided needle aspiration (*asterisk*) was performed, which grew *Staphylococcus aureus* from the collection (*arrow*). *cla* clavicle, *M* manubrium, *t* trachea

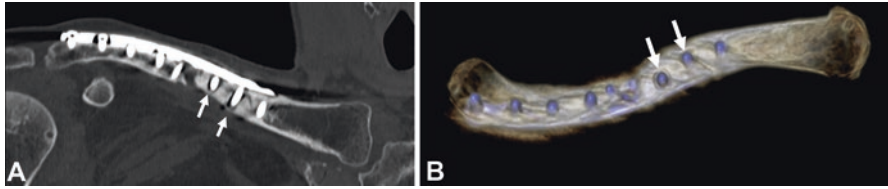


Fig. 4.8 (a) Coronal reformatted CT of the right clavicle demonstrates lucency surrounding two medial screws (*arrows*) in a loose implant which went onto non-union. (b) 3D reformatted image of the right clavicle demonstrating osteolysis surrounding the screws (*arrows*)

collimation as well as pitch values [14]. Additionally, the use of post-processing techniques such as multi-planar and 3D reformation with volume rendering also contributes to producing CT images with less severe metal artifacts (Fig. 4.8) [15].

Most recently, dual-energy CT has been used as a means to reduce beam-hardening metal artifacts by generating monoenergetic images. This is encouraging as recent studies have demonstrated that dual-energy CT with iterative reconstruction algorithms allows a reduction of radiation dose with similar signal-to-noise ratio relative to conventional MDCT [16, 17]. However, there is still little information available regarding the effect of acquisition parameters and hardware composition on the severity of artifacts and more research needs to be done.

Magnetic Resonance Imaging of the Clavicle

MRI of the clavicle, while not routinely performed, can be helpful in the evaluation of the osseous structures in the case of clavicular non-union. However, the prominent advantages of MRI relate to visualization of the associated soft tissues while assessing for infection, injury to the adjacent brachial plexus, vascular compression in post-traumatic-induced thoracic outlet syndrome (TOS) and during evaluation of the AC and SC joints. Most recently, there has been investigation in determining patient's bone age by using MRI to determine the presence of a fully ossified clavicular epiphyseal plate as evidence of completion of the 20th year of life [18].

At our institution, MRI is performed on the patient in the supine position, as this allows the most comfort for the patient and subsequently less motion with higher quality images acquired. Routine images are obtained of the patient's chest in coronal, axial, and sagittal planes. Traditionally, we perform high-resolution proton density images in three planes with the addition of a fluid-sensitive sequence called a short-inversion-time inversion-recovery (STIR) image. This provides uniform fat suppression; however, this technique is sensitive to B_1 field inhomogeneities, requires additional time for inversion pulses, and suffers from a low signal-to-noise ratio (SNR) [19]. Iterative decomposition of water and fat with echo asymmetry and least-squares estimation (IDEAL) is a newer method that provides uniform and reliable fat suppression creating high-quality fat-suppressed MR images [20].

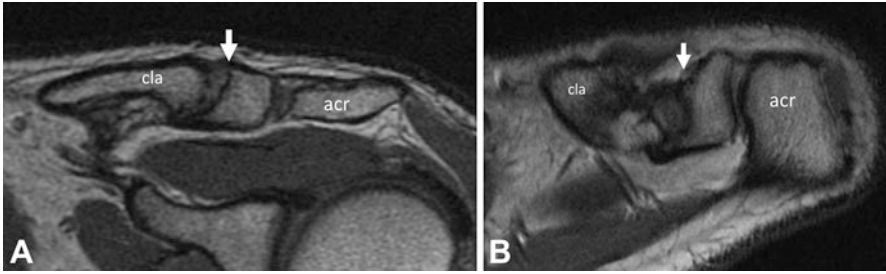


Fig. 4.9 (a) Coronal proton density image demonstrates fracture non-union of the distal third of the clavicle (*arrow*). (b) Axial proton density image of the clavicle non-union, note the low-signal intensity margins indicating sclerosis (*arrow*). *acr* acromion, *cla* clavicle

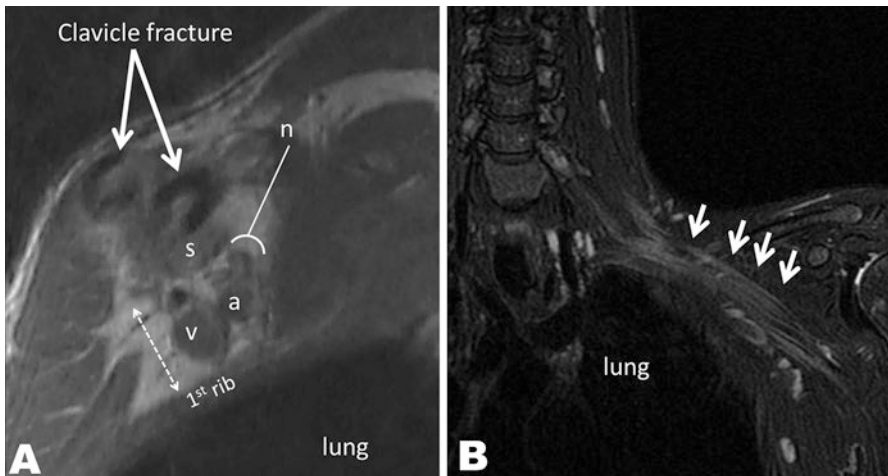


Fig. 4.10 (a) Sagittal proton density MRI demonstrates posterior inferior displacement of the ununited mid-shaft fracture fragments (*solid arrows*) narrowing the costoclavicular space (*dashed double arrow*). The subclavius muscle (*s*) with associated scarring is prominent through this region, narrowing the costoclavicular space (*dashed double arrow*). Note the scar tissue abuts the trunks of the brachial plexus (*n*). (b) Coronal T2 IDEAL MRI demonstrates hyperintensity of the divisions and cords of the brachial plexus (*arrows*), consistent with traumatic plexitis

The coronal and axial planes of imaging are useful for the evaluation of articular surfaces and optimal for the evaluation of a clavicular non-union (Fig. 4.9). Thoracic outlet syndrome (TOS) is a rare complication of a clavicular non-union and the sagittal plane of imaging can be used to measure and determine narrowing of the costoclavicular space and the IDEAL sequence is useful to determine hyperintensity, in the nerves, indicative of a plexitis (Fig. 4.10). Both the axial and coronal plane of imaging can be used to detect subtle cord entrapment of the plexus by callus formation (Fig. 4.11).

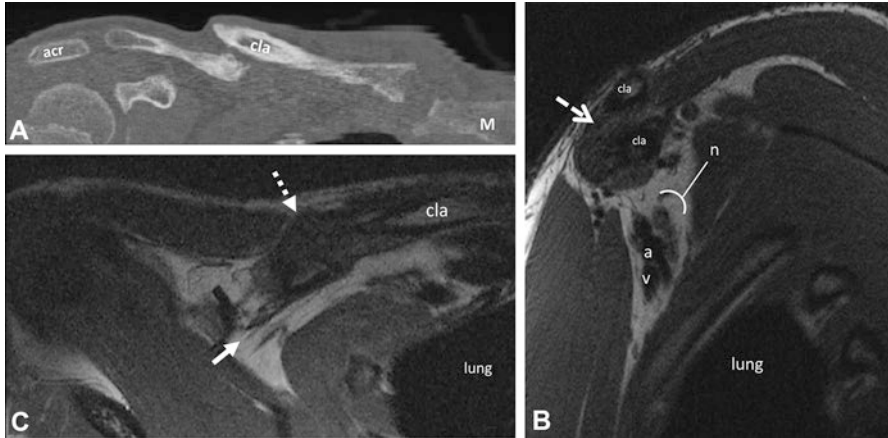


Fig. 4.11 (a) Coronal reformatted CT of the right clavicle demonstrates a displaced mid-shaft non-union fracture. However, the extent of soft tissue involvement is seen to best advantage in the sagittal MRI proton density sequence (b) as well axial MRI proton density sequence (c), where there is profound hypertrophic callus (*dotted arrows*) with scar encasement of the upper trunk of the brachial plexus (*solid arrow*). *a* subclavian artery, *v* subclavian vein, *acr* acromion, *cla* clavicle, *M* manubrium, *n* brachial plexus

Anatomy of the Acromioclavicular Joint

Despite its small size, the acromioclavicular (AC) joint plays a crucial role in upper-extremity function. It is essential in all motion of the arm/scapula, except in pronation and supination [21]. The AC joint unites the distal end of the clavicle with the acromion, at the lateral extension of the scapular spine. The AC joint itself is a simple diarthrodial joint made up of a fibrocartilaginous articular disc, intra-articular synovium, with articular cartilage, and a weak capsule. Of note, the size of the articular disc is highly variable and it can be completely absent [22]. The hyaline articular cartilage becomes fibrocartilage on the acromial side of the joint by the age of 17 and on the clavicular side by the age of 24 [23, 24].

Because the AC joint capsule is relatively thin, it has substantial ligamentous support. There are four AC ligaments: superior, inferior, anterior, and posterior, and the superior AC ligament has been found to be larger and thicker than the inferior ligament [25, 26]. Fukuda et al. found that the AC ligaments acted as the major restraint to posterior displacement of the clavicle [26]. Follow-up biomechanical studies have confirmed this observation by noting a 100% posterior displacement after complete transection of the AC joint ligaments [27].

The coracoclavicular (CC) ligament complex consists of the conoid and trapezoid ligaments, which insert on the posteromedial and anterolateral regions of the undersurface of the distal clavicle, respectively. Whereas the AC ligament works as the primary restraint to horizontal stability, the CC ligaments act as the primary

restraint to vertical stability. Costic et al. have evaluated the geometric and structural properties of the conoid and trapezoid portions of the ligament and have found no significant differences between them [28]. Load-to-failure test results by Mazzocca et al. have established that the conoid ligament fails initially when a load is applied to the CC complex in a superior direction [29]. Furthermore, they found the most common site of rupture was the mid-substance portion of the ligament, followed by rupture at the origin.

The deltoid, pectoralis major, and trapezius muscles have attachments on the clavicle; the deltoid inserts onto the anterior surface of the lateral third of the clavicle, and the trapezius inserts at its posterior aspect. The pectoralis major inserts onto the medial two-thirds of the clavicle, anteriorly [30]. Anteriorly, the acromion has a coarsened surface where the coracoacromial ligament inserts and it has fibers that merge medially with the inferior AC ligament [31].

Radiography of the Acromioclavicular Joint

Both the AP standing and AP weighted stress views (using 5–15 lb weight suspended from each wrist) of the AC joint are performed at 15° of cephalad inclination, along the scapular spine. This technique aids in opening the joint and avoids superimposition of the acromion at the distal clavicle (Fig. 4.12). Lateral and Alexander views can also be performed; the latter is obtained while the patient is standing, shoulders projected forward, with the ipsilateral hand in the contralateral axilla [32]. Additionally, the lateral view of the acromion is particularly helpful in posterior dislocations, which are often missed on stress views [33]. Often, contralateral views of the AC joint are helpful for comparison, as are outlet views of the supraspinatus, particularly for subtle injuries.

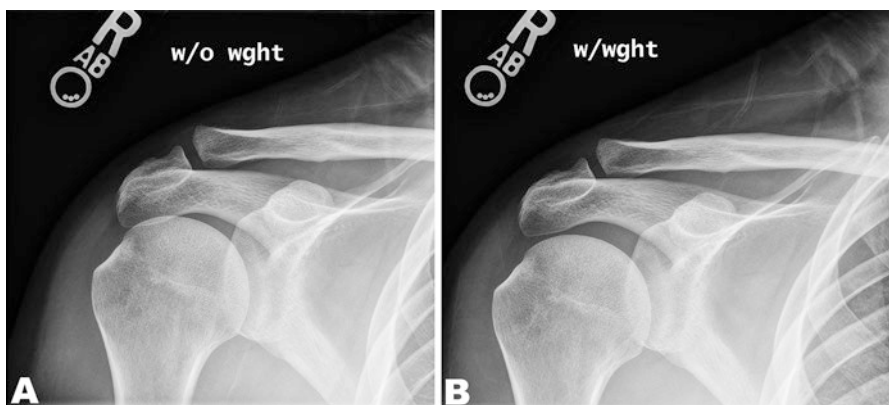


Fig. 4.12 (a) Normal AP view of the acromioclavicular joint. (b) Normal AP weighted stress view (using 5 lb weight) in the same patient, demonstrating normal slight widening with stress but no abnormal distraction

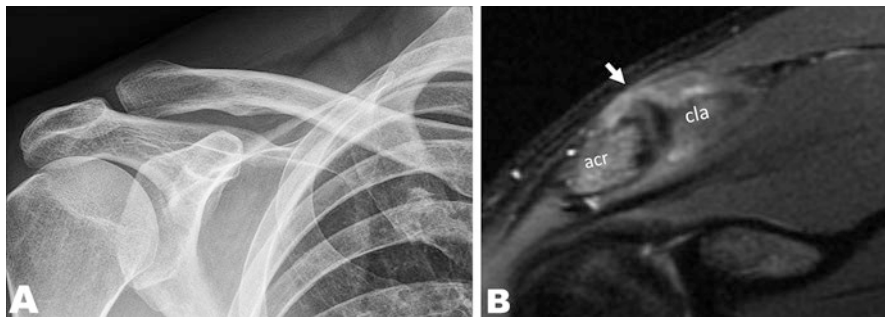


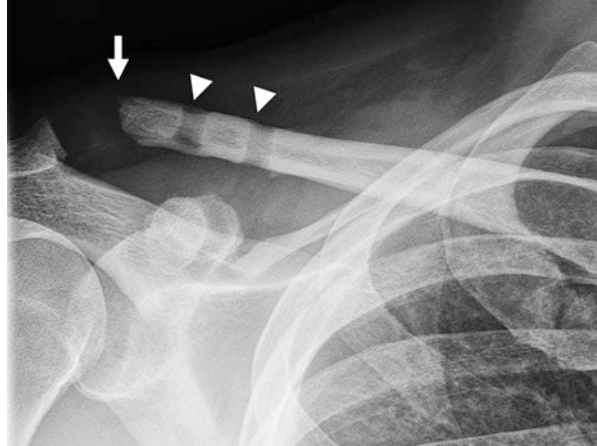
Fig. 4.13 Type I AC joint injury in a 22-year-old man who felt a “pop” in his shoulder while pushing a stretcher. (a) AP radiograph of the right AC joint demonstrates a normal appearing joint. (b) Inversion-recovery coronal MRI of the right shoulder performed on the same day demonstrates capsular edema (*arrow*) without widening of the AC joint, consistent with a type I injury. *acr* acromion, *cla* clavicle

The radiographic classification of AC joint injuries, as described by Rockwood et al., embodies a gamut of progressive soft tissue injury. In a type I injury, the AC ligaments are sprained, but the joint is intact and radiographically there is no abnormality (Fig. 4.13). The AC ligaments are torn, in type II injuries, but the CC ligaments are intact. Radiographically, the joint can be widened or the clavicle is displaced superiorly. However, it is important to remember that radiographic abnormalities are evident in 70–75% of type I or II AC injuries but in virtually 100% of type III injuries [32]. In type III injuries, both the AC and the CC ligaments are torn and the clavicle is always superiorly displaced relative to the acromion. Type IV injuries are characterized by complete dislocation with posterior displacement of the distal clavicle. The posterior displacement of the clavicle will extend into or through the fascia of the trapezius, the latter of which can only be seen with MRI. Type V injuries are characterized by a larger degree of soft tissue damage to the trapezius, whereas Type VI injuries are inferior AC joint dislocations into a subacromial or subcoracoid location.

Petersson et al. found the AC joint space to be 3.1 mm \pm 0.8 mm on average when studying healthy volunteers. According to their data, the normal AC joint space is significantly wider in men as compared with women. Moreover, their data demonstrates that a joint space wider than 7 mm in men and 6 mm in women is abnormal [34]. Increased joint space widening can be seen most commonly status-post trauma or after stress-induced osteolysis (Fig. 4.14) [35]. The differential diagnosis also includes rheumatoid arthritis, septic arthritis, gout, scleroderma, hyperparathyroidism, and lytic neoplasms.

Joint space narrowing, osteophytes, and cystic changes of osteoarthritis can be easily seen on radiographs of the AC joint, shoulder, or chest. Although specific in the evaluation of these osseous alterations, routine radiography is not sensitive [36]. Other important AC joint radiographic findings are fracture lines and joint capsule or ligamentous calcifications.

Fig. 4.14 AP view of the AC joint demonstrates a patient has undergone right-sided coracoclavicular ligament reconstruction (arrowheads). There is widening of the AC joint and at the end of the clavicle (arrow), there is irregularity and resorption representing post-traumatic osteolysis around the fixation



Computed Tomography of the Acromioclavicular Joint

CT with its superior contrast resolution is the best modality for fine osseous detail. It is also ideal for the careful characterization of clavicular fractures involving the AC joint including its capacity for multi-planar 3D reformations (Fig. 4.15). CT demonstrates the extent of the fracture lines and the number, relationship, and alignment of fracture fragments. CT is also useful in the evaluation of intra-articular bodies in the AC joint. Improvements in the speed of image acquisition make CT imaging generally well tolerated, even in the setting of more severe trauma. However, CT is limited in the evaluation of the surrounding soft tissues including capsular, ligamentous, and synovial abnormalities.

Magnetic Resonance Imaging of the Acromioclavicular Joint

On MRI, the oblique coronal plane, parallel to the distal clavicle, best demonstrates the AC joint, and this orientation purposefully displays the CC ligaments in the same plane in which they tear (Fig. 4.16a, b). The oblique sagittal plane roughly corresponds to the radiographic supraspinatus outlet view and also demonstrates the CC ligaments well (Fig. 4.16c) [37]. In addition to soft tissue injury, MRI offers the added advantage of the assessment of cartilage, which, in the author's opinion, is best evaluated in the axial plane of imaging. The distal clavicle can also be evaluated for osteolysis or an os acromiale (Fig. 4.17).

At our institution, patients undergo oblique coronal MR imaging performed parallel to the anterior fibers of the supraspinatus, with the humerus in the neutral position. This optimizes evaluation of the AC joint and the CC ligaments. Proton density-weighted fast spin echo as well as inversion-recovery fluid-sensitive

Fig. 4.15 Three-dimensional CT reformation from a patient with a comminuted distal fracture with intra-articular extension into the AC joint (*arrow*)

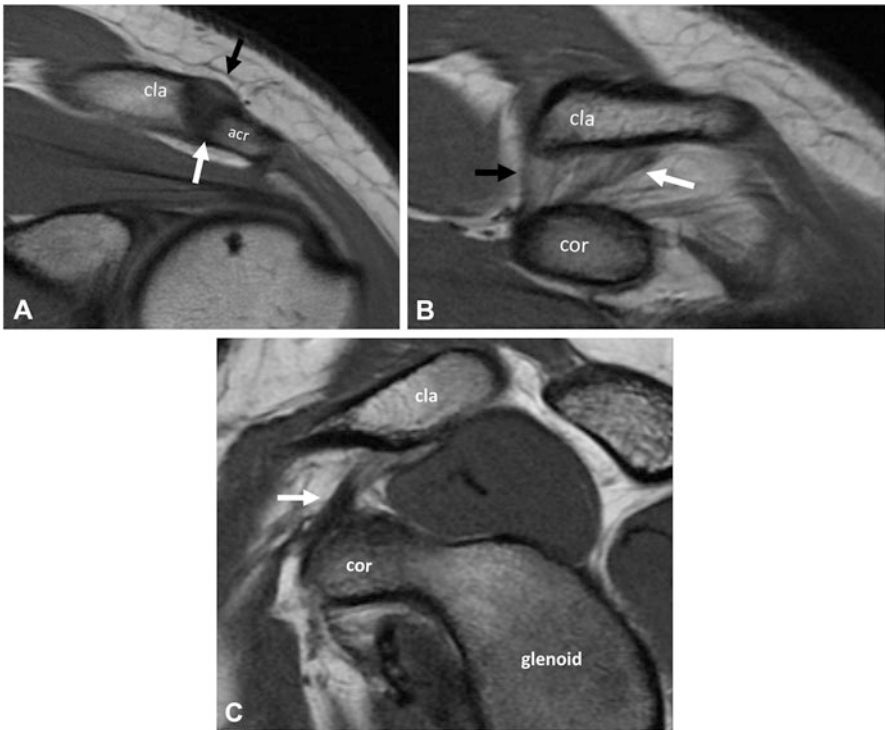
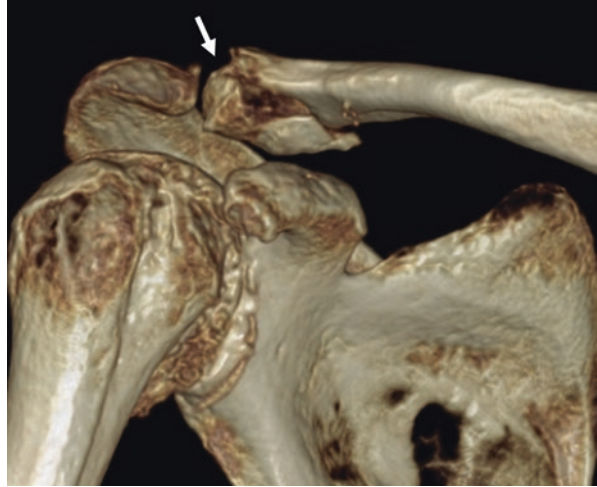
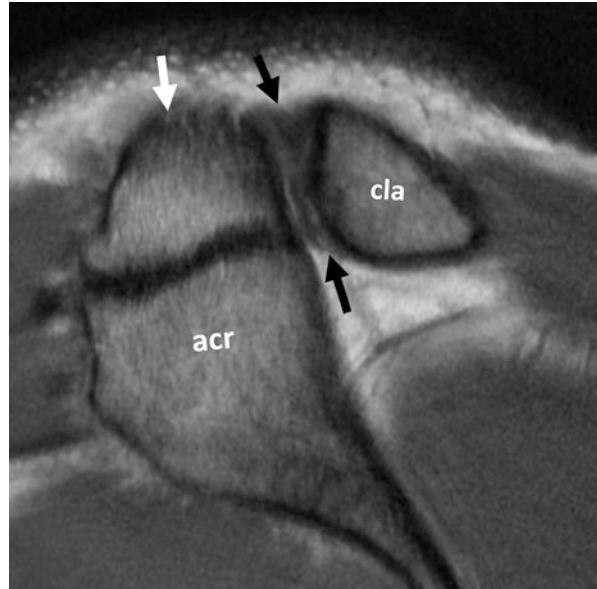


Fig. 4.16 Normal anatomy of the AC joint at MR imaging. (a) Coronal proton density-weighted image shows the superior (*black arrowhead*) and inferior (*small white arrow*) acromioclavicular ligaments. (b) Coronal proton density-weighted image, of the same shoulder, shows the conoid (*white arrow*) and trapezoid (*black arrow*) portions of the coracoclavicular ligament. (c) Sagittal proton density-weighted image shows the conoid component of the coracoclavicular ligament (*arrow*). *acr* acromion, *cla* clavicle, *cor* coracoid

Fig. 4.17 Axial proton density-weighted image shows the typical appearance of an os acromiale (*white arrow*), which is seen well on the axial images adjacent to the AC joint. Note is made of the presence of an intra-articular disk (*black arrows*). *acr* acromion, *cla* clavicle



sequences are performed in the described plane. These sequences are then accompanied with sagittal and axial proton density-weighted imaging, and injuries are graded according to the Rockwood classification.

Type I AC joint disruption results from injury to the acromioclavicular ligament and there is no complete disruption. In this setting, radiographs may demonstrate swelling but are usually normal. Although Schaefer et al. described no specific MR imaging findings for this injury [38], it is the author's experience that patients, in the acute setting, have capsular edema and/or a partial tear of the superior or inferior ligaments or both. In the chronic setting, the diagnosis of type I AC joint injury becomes much more difficult. In contrast, type II injuries result in disruption of the AC joint capsule and ligaments, and radiographs typically display a widened joint space (secondary to medial scapular rotation) [39]. MRI is key in demonstrating type I versus II injury as it can show that the acromioclavicular ligaments are torn and the CC ligaments are injured or partially torn (Fig. 4.18). The conoid component is most frequently involved in this injury [26].

Type III injuries lead to complete disruptions of both the AC and CC ligaments. The tear may extend to involve the deltoid and trapezius muscles and blood as well as fluid within the interspace of the CC ligaments may be seen (Fig. 4.19). Type IV injury occurs when the patient receives a blow to the acromion, with sufficient force to push the scapula posteriorly. Consequently, there is disruption of the acromioclavicular and CC ligaments with posterior and superior displacement of the clavicle, and the trapezius and deltoid are separated from their distal clavicular insertions (Fig. 4.20). The term "buttonholing" refers to the clavicle extending superiorly through the trapezius muscle. A type V injury is virtually an extremely severe type III injury, where the lateral trapezius and deltoid insertions as well as

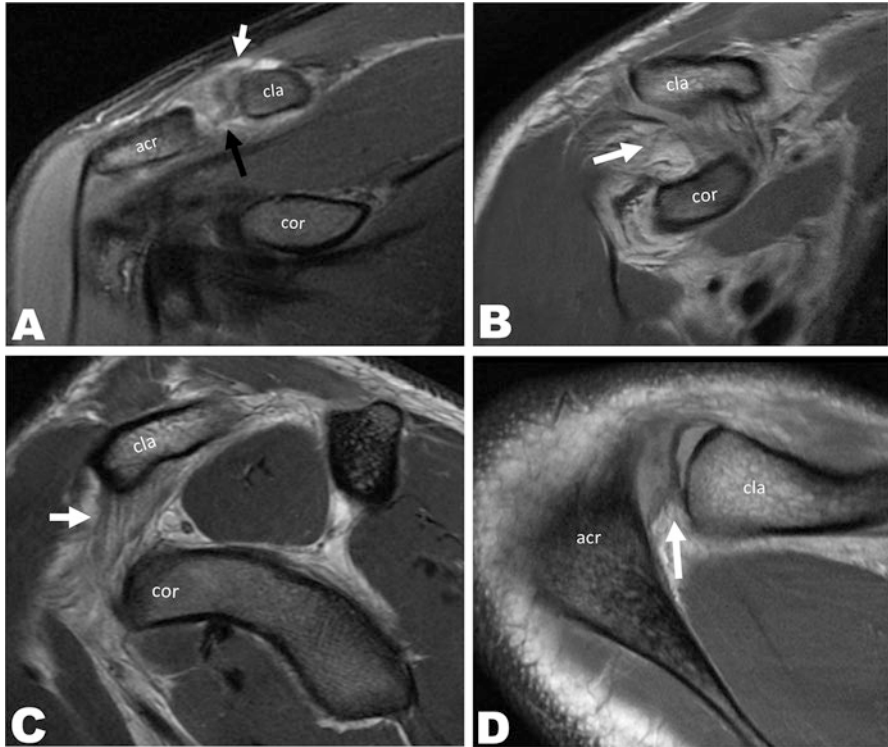


Fig. 4.18 Type II AC joint injury. (a) Coronal-inversion recovery of a 15-year old boy, after a lacrosse injury, shows disruption of the superior (*white*) and inferior (*black*) acromioclavicular ligaments off the clavicle. (b) Coronal proton density image shows the fibers of the trapezoid ligament are attenuated at the coracoid insertion (*arrow*), indicating a partial tear. (c) Sagittal proton density image demonstrates a partial tear of the conoid ligament (*arrow*). (d) Axial proton density image demonstrates fluid in the AC joint and a torn meniscus (*arrow*). *acr* acromion, *cla* clavicle, *cor* coracoid

the acromioclavicular and CC ligaments are torn. Additionally, unrestricted contraction of the sternocleidomastoid muscle can result in a large separation of the CC distance (Fig. 4.21). Finally, type VI injuries occur from superior trauma to the clavicle causing a reduction of the CC distance and a tear of the acromioclavicular ligament solely [40]. This type of injury pattern is extremely rare.

Anatomic-type reconstructions of the acromioclavicular joint are becoming popularized and typically involve the placement of one or more tendon allografts or autografts to reconstruct the CC ligaments, as discussed elsewhere (Fig. 4.22). It currently remains unclear if these more complex procedures will result in superior patient outcomes by approximating the native biomechanics of the joint more closely than the traditional Weaver Dunn procedure. However, it is important to consider that transplanted tendon grafts need to undergo a process of “ligamentization” and achieve good bony integration to be successful in the longer term (Fig. 4.23).

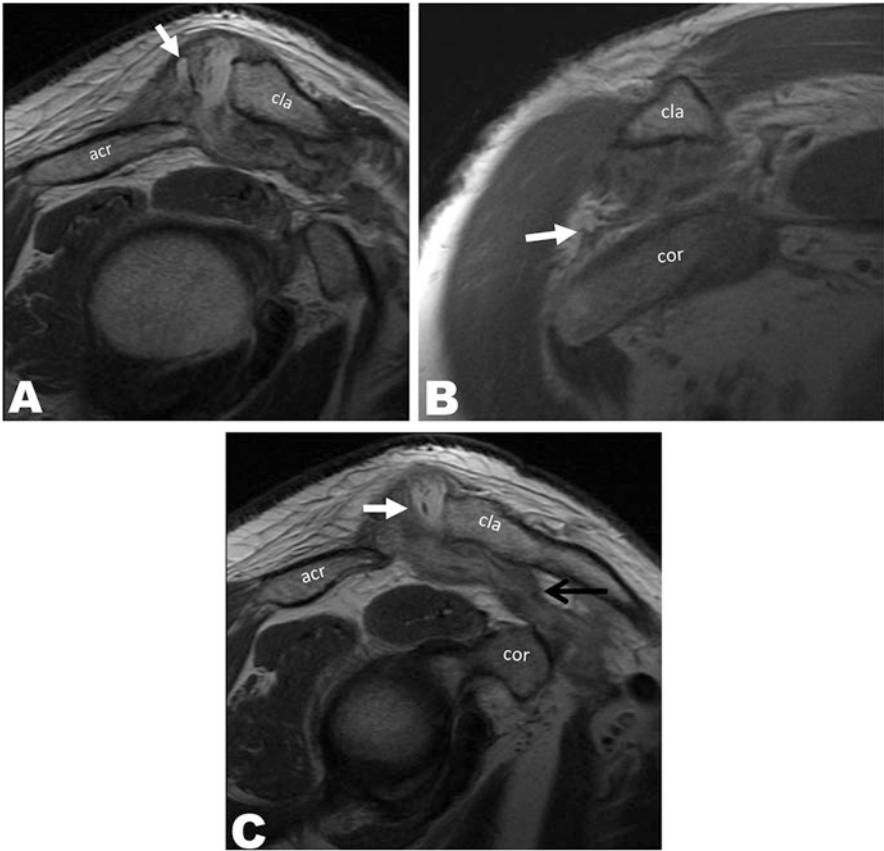


Fig. 4.19 Type III AC joint injury. (a) Sagittal proton density image, of a 65-year-old male who fell in the bathroom 1 month ago, demonstrates superior displacement of the clavicle relative to the acromion and chondral injury on the clavicular side with bone fragmentation (*white arrow*). (b) Coronal proton density image demonstrates complete disruption of the coracoclavicular ligaments (*arrow*). (c) Sagittal proton density image, of the same patient, demonstrates chondral fragments (*white arrow*) and fluid in the AC joint as well as complete disruption of the conoid ligament (*black arrow*). *acr* acromion, *cla* clavicle, *cor* coracoid

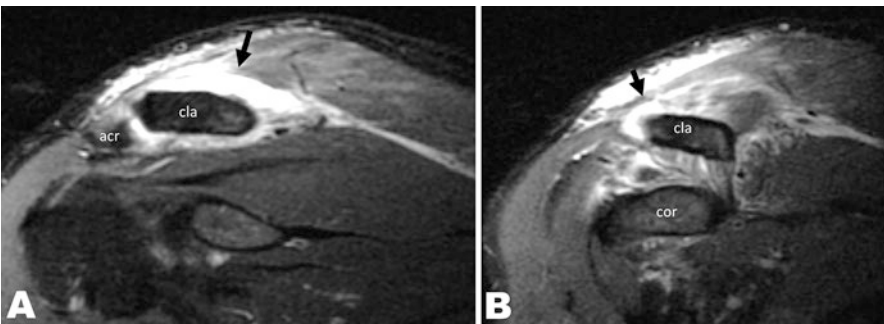


Fig. 4.20 Type IV AC joint injury. (a) Coronal inversion recovery images of a 48-year-old male, status post fall 1 day ago, with acute complete disruption of the AC joint capsule and supporting ligaments, associated with acute tear and detachment of the adjacent distal lateral trapezius muscle insertion upon the distal lateral clavicle, resulting in a fluid-filled gap (*arrow*). (b) Demonstration of a tear at the attachment of the deltoid muscle (*arrow*). *acr* acromion, *cla* clavicle, *cor* coracoid

Fig. 4.21 Type V AC joint injury. T2-weighted fat-saturated image, of a 47-year-old male who fell down the stairs 3 days ago, demonstrates marked widening of the coracoclavicular distance and high-grade partial tear of the trapezius (*arrow*). *cla* clavicle, *cor* coracoid

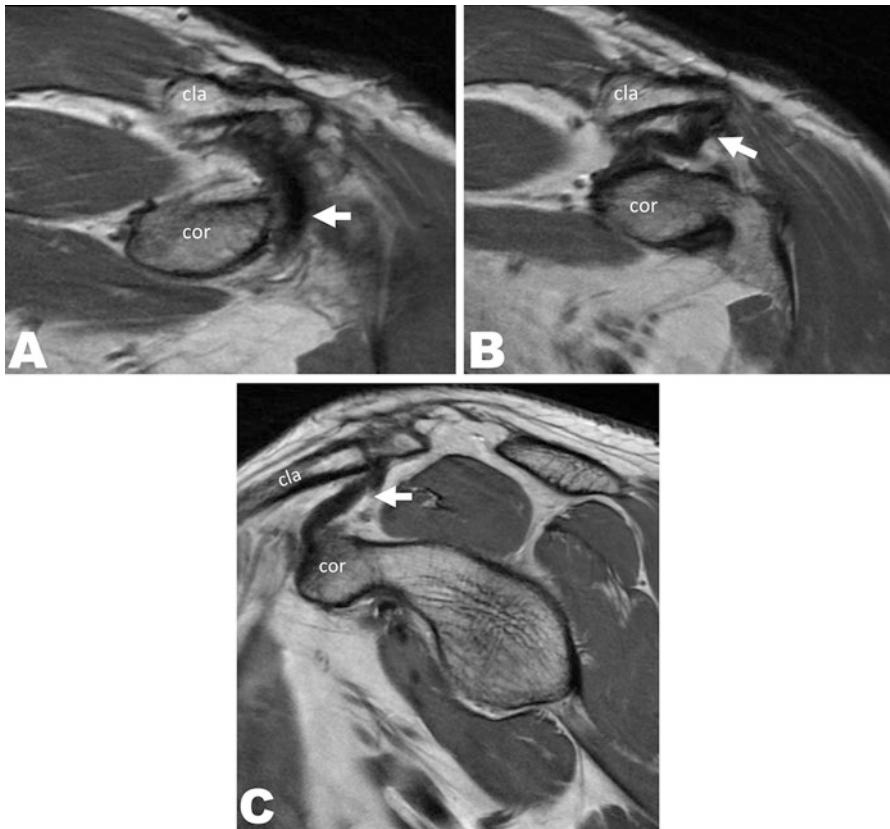
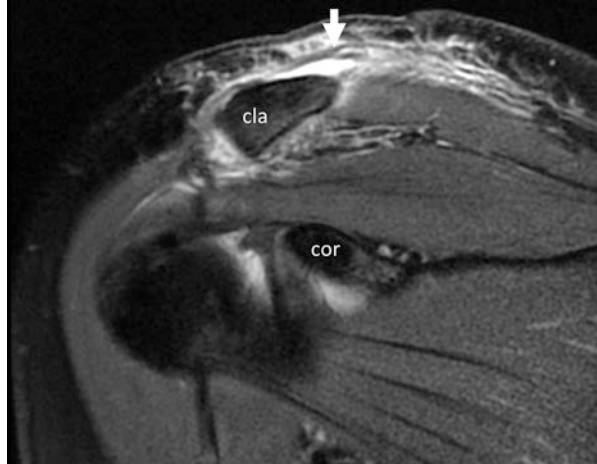


Fig. 4.22 Normal AC joint reconstruction. (a) Coronal proton density image demonstrates intact AC joint with graft (*arrow*) in continuity as it wraps around the coracoid anteriorly and posteriorly (b). (c) Sagittal proton density image demonstrates the intact graft as well. *acr* acromion, *cla* clavicle, *cor* coracoid

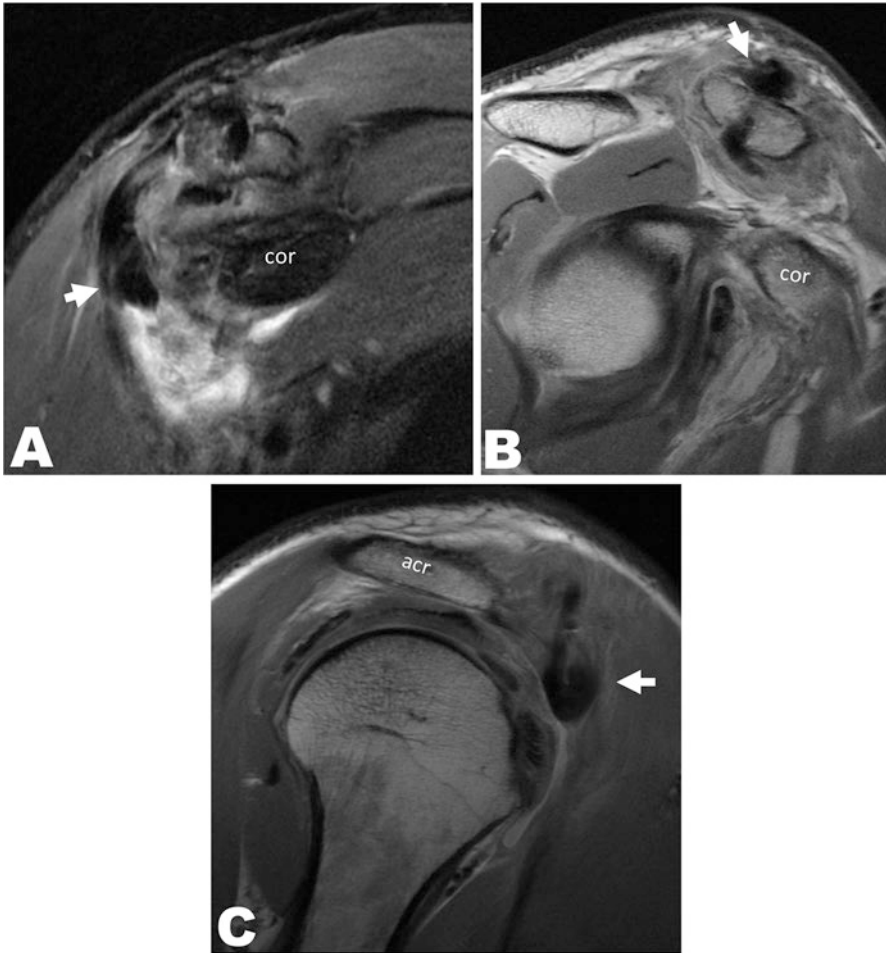


Fig. 4.23 Failed AC joint reconstruction. (a) Coronal T2 fat-saturated image of a 43-year-old man with allograft reconstruction of the AC joint demonstrates the inferior margin of the allograft has detached from the coracoid (*arrow*). (b) Sagittal proton density image demonstrates the proximal graft and the clavicular tunnel (*arrow*). Note the superior displacement of the clavicle relative to the acromion. (c) Sagittal image also demonstrates the disrupted graft, anterolateral to the coracoid (not seen) and flipped upon itself (*arrow*). *acr* acromion, *cor* coracoid

In addition, graft fixation using bone tunnels and additional hardware may disrupt the integrity of local bone stock; combined with altered loading following reconstruction, these factors may contribute to fracture risk in this patient population (Fig. 4.24). Going forward, the use of MR imaging (including quantitative parametric sequences) to objectively assess soft tissue healing and graft integration may be used to compliment clinical outcome data and refine reconstruction techniques, and thereby decrease associated risks of failure and fracture, thus improving patient care.

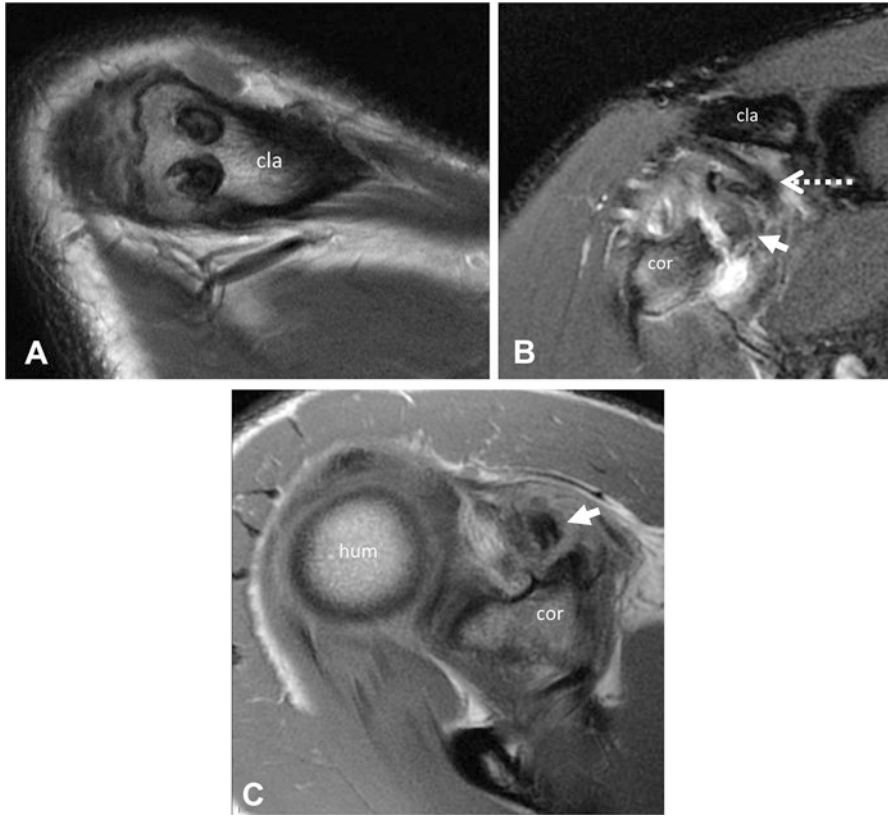


Fig. 4.24 Coracoid fracture causing failed AC joint reconstruction. (a) Axial image of the clavicle demonstrates drill holes in the clavicle for AC joint reconstruction. (b) Coronal T2 fat-saturated image demonstrates a fracture of the coracoid with superior displacement of the fragment (*solid arrow*) and retraction on the graft (*dotted arrow*). (c) Axial image demonstrates the fracture through the coracoid (*arrow*). *cla* clavicle, *cor* coracoid, *hum* humerus

In comparison to the rate of trauma to the AC joint, the incidence of osteoarthritis is much more common. Yet compared to the occurrence of osteoarthritis in the knee and hip, primary osteoarthritis in the shoulder is comparatively rare [41]. However, involvement of the AC joint is much more common than primary involvement of the glenohumeral joint and is the most common cause of pain in the AC joint [42]. The evaluation of osteoarthritis with MRI is best performed with cartilage-sensitive sequences such as fast spin echo techniques [43]. The authors prefer both the coronal and axial planes for the evaluation of AC joint osteoarthritis.

An increasingly recognized but somewhat infrequent entity that causes AC joint pain is distal clavicle osteolysis. Osteolysis related to repetitive microtrauma is seen commonly in weight lifters as well as in overhead occupations, such as builders and plasterers [44, 45]. The most common MRI finding in clavicular osteolysis is bone marrow edema as well as cortical irregularity and subchondral cystic changes (Fig. 4.25) [46].

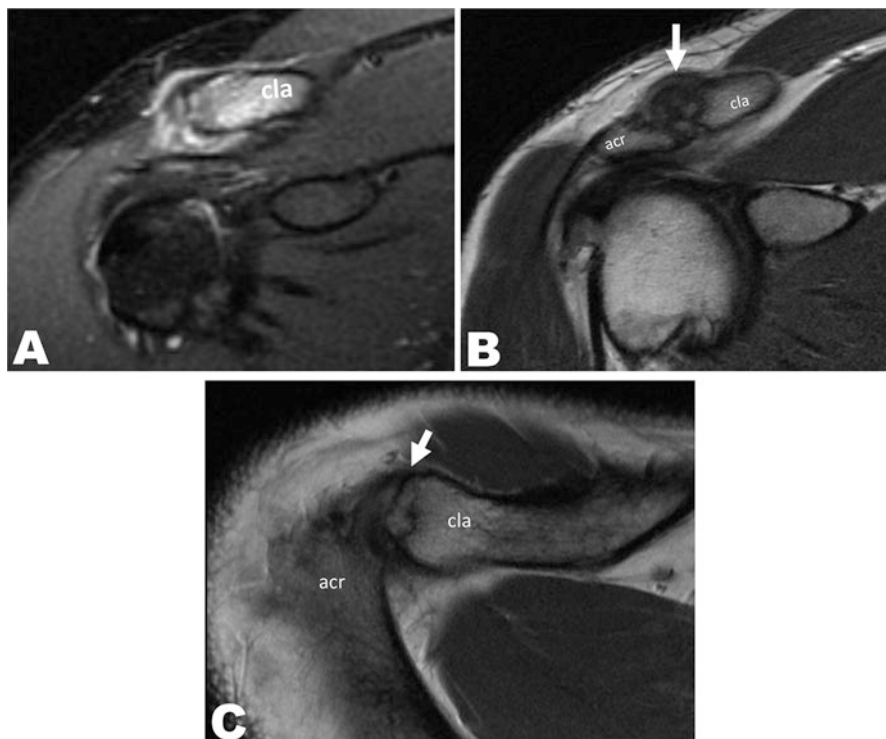


Fig. 4.25 Distal clavicular osteolysis. (a) Coronal-inversion recovery image in 37-year-old weight lifter demonstrates a profound bone marrow edema pattern within the distal clavicle. (b) Coronal proton density image shows marked capsular hypertrophy of the AC joint (*arrow*). (c) Axial proton density image shows subchondral cystic resorption of the distal clavicle (*arrow*). *acr* acromion, *cla* clavicle, *cor* coracoid

Ultrasound-Guided Injection of the Acromioclavicular Joint

The AC joint is a relatively frequent source of clinical pain, most often due to primary osteoarthritis, posttraumatic arthritis, or rarely trauma. Diagnostic uncertainty can be resolved through direct injection of local anesthetic and/or steroid into the AC joint. The difficulty with blind injections is inaccuracy in entering the joint, which has been estimated to succeed in only 40% of attempts [47]. Ultrasound guidance is a clinically proven substitute for blind or manual palpation injections and has proved to markedly increase intra-articular ingress of fluid in cadaver studies [48, 49].

At our institution, the authors perform AC joint injections with the patient in the supine position with the arm at the patient's side. The lateral aspect of the clavicle is palpated and a 12–3-MHz linear array transducer is placed on the anterior aspect of the clavicle, parallel to its long axis, and moved laterally to the level of the joint (Fig. 4.26a). The anterior superior portion of the AC joint is then sonographically

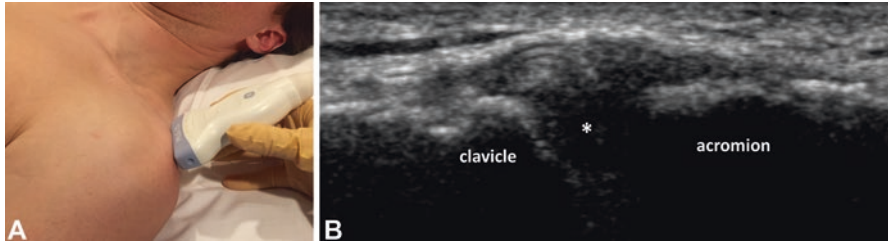


Fig. 4.26 (a) Linear array transducer is placed on the anterior aspect of the clavicle, parallel to its long axis, and moved laterally to the level of the joint. (b) Corresponding short-axis view of the AC joint (*asterisk*)

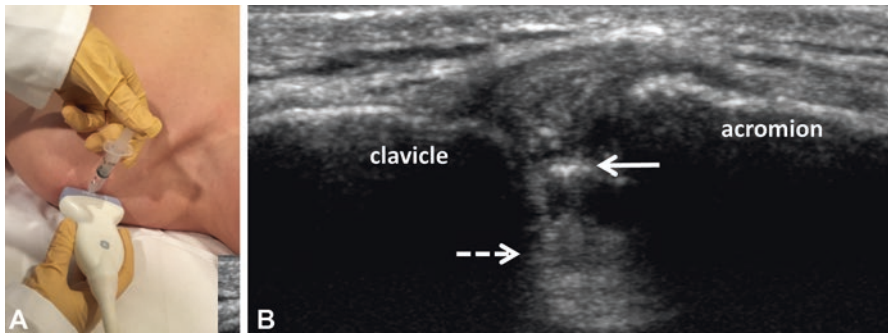


Fig. 4.27 (a) Needle with syringe filled with lidocaine is advanced, perpendicular to the long axis of the transducer. (b) Axial ultrasound shows the bony acoustic margins of the clavicle and acromion. The hyperechoic needle tip appears as an echogenic dot (*arrow*) within the AC joint. Note the echogenic cloud of steroid injectate filling the joint (*dashed arrow*)

visualized in the coronal plane (Fig. 4.26b). Subsequently, a 25-gauge needle is advanced in a lateral-to-medial direction, perpendicular to the long axis of the transducer (Fig. 4.27a). A test injection is performed with lidocaine, and once intra-articular positioning is achieved, the syringe is switched and a mixture containing steroid and anesthetic is injected (Fig. 4.27b).

The Sternoclavicular Joint

Injuries to the SC joint are uncommon, which is largely attributed to the immense amount of energy required to tear its ligamentous stabilizers [50]. In a series of 1603 traumatic injuries to the shoulder, the SC joint accounted for only 3% of the total injuries [51]. Furthermore, it is one of the least commonly disrupted joints in the body [52]. It is not surprising that motor vehicle accidents and athletic injuries account for greater than 80% of injuries to this joint because of the high-energy

trauma that is needed to disrupt this articulation, and in these settings, the incidence of associated injuries is high [53]. Orthopaedic surgeons should carefully scrutinize these injuries, as the joint lies in close proximity to the great vessels and other important structures of the superior mediastinum.

Anterior dislocations are approximately 20 times more frequent than the more clinically serious posterior dislocations [54]. Although posterior dislocations are rare, failure to correctly diagnose them can have devastating consequences, where there is a reportedly 25% incidence of injury to the vital structures of the superior mediastinum following a posterior dislocation [55]. Direct anteromedial force to the joint typically results in a posterior dislocation, and examples of this are often seen in athletics such as a kick to the front of the medial clavicle, in mixed-martial arts, or being jumped on while lying flat in football. In contrast, with indirect force, such as in motor vehicle accidents, the mechanism of injury can result in either anterior or posterior forces [56]. Rarely spontaneous dislocation can occur in patients with ligamentous laxity, severe scoliosis, and congenital abnormalities [57]. In addition, many presumed SC joint dislocations in patients younger than 25 years old are truly fractures through the physis. Note is made that the medial clavicular epiphysis may not close until the age of 24–25 and these physeal injuries represent Salter–Harris type I or II fractures (Figs. 4.28 and 4.29) [58].

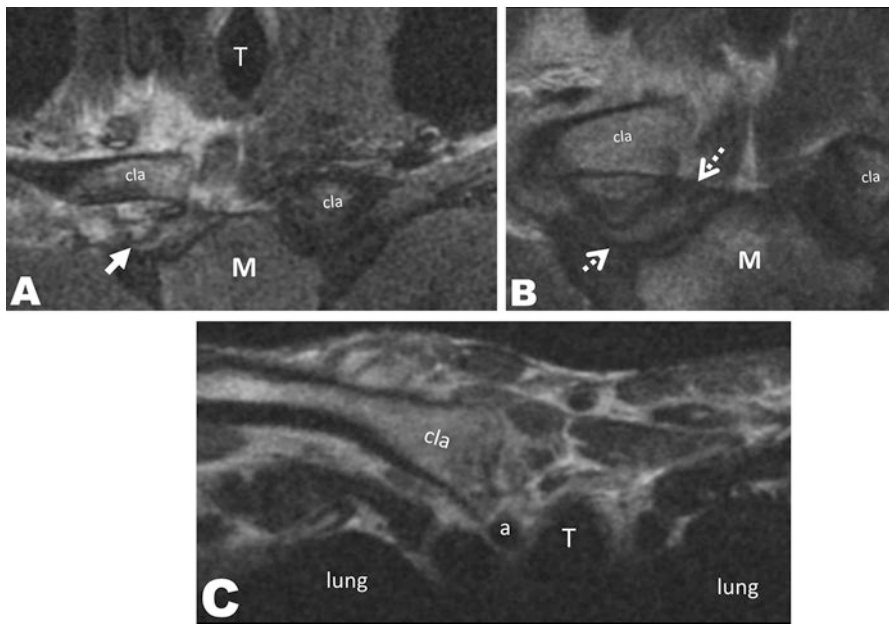


Fig. 4.28 Physeal shear fracture with displacement. (a) Coronal inversion recovery image, of a 16-year-old girl after an all-terrain vehicle (ATV) accident, demonstrates a shear fracture through the physis (*arrow*) of the right medial clavicle with extensive bone marrow and soft tissue edema within the strap muscles. (b) Coronal proton density image shows that the epiphysis (*dashed arrows*) is still articulating with sternum and the SC joint is maintained. (c) Axial proton density image shows posterior displacement of the fracture near the right carotid artery (a). *cla* clavicle, *M* manubrium, *T* trachea

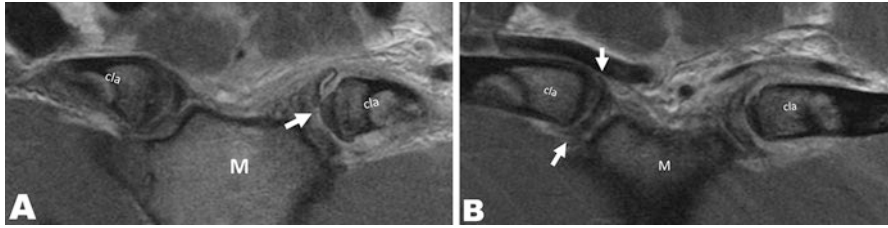


Fig. 4.29 Physeal shear fracture with meniscal transection. (a) Coronal proton density image of a 17-year-old male who fell while playing football 4 days ago. In addition to a vertical shear fracture through the apophysis of the left SC joint the intervening meniscus has been completely transected (arrow). (b) Note the normal-appearing meniscus of the right side (arrows). *cla* clavicle, *M* manubrium

Anatomy of the Sternoclavicular Joint

The SC joint is a diarthrodial synovial joint and is the only true articulation between the upper extremity and the axial skeleton. The joint is formed by the medial clavicle, the clavicular notch of the manubrium, and cartilage of the rib. The SC joint moves during virtually every arm movement. Interestingly, of all the joints in the body, the SC joint is one of the most inherently unstable joints due to the broad medial clavicle, which is twice the size of the sternal notch, with which it articulates [59].

The SC joint is composed of a fibrocartilaginous articular disc, a fibrous capsule, anterior and posterior SC ligaments, the costoclavicular ligament, and the interclavicular ligament. The articular disc of the SC joint is a shock absorber, functioning very similar to the meniscus of the knee [60]. The disc divides the joint into two synovial lined cavities and is attached to the clavicle superiorly, the first rib inferiorly, and to the capsule anteriorly and posteriorly [54]. Previous studies have suggested the capsule to be most vital in stabilizing the joint [9]. However, recent work by Tubbs et al. has demonstrated the costoclavicular ligament as the predominant stabilizer of the joint [61, 62]. Supporting these findings, Lee et al. demonstrated that the costoclavicular ligament had the largest footprint of all the SC joint-associated ligaments [63]. Additionally, both the anterior and posterior SC joint ligaments are important in joint stability. In a cadaveric study, Lee et al. found that articular cartilage covered approximately 70% of the medial end of the clavicle, with coverage only on the anteroinferior aspect of the clavicle [63].

The costoclavicular ligament extends from the medial metaphysis of the clavicle to the first rib. The interclavicular ligament connects the superomedial clavicle and the costoclavicular ligaments. The most common site of injury of the SC joint is the articular disc [64]. The SC ligaments are injured next most frequently and interclavicular and costoclavicular ligament injuries are rare.

Radiography of the Sternoclavicular Joint

Standard radiographic projections for the evaluation of the SC joint include postero-anterior, oblique, and lateral views. However, these are often inadequate due to the overlap of the medial clavicle with the sternum and the first rib. However, special projections can aid in the diagnosis of SC joint injury and include the serendipity, Hobbs, Heinig, and Kattan views. The serendipity view is performed with radiography tube angled at 40° cephalad, centering at the manubrium (Fig. 4.30). The Hobbs view approximates a 90° lateral view of the SC joint and is performed with the patient leaning over the table. The Heinig and Kattan views are rarely performed today and have been replaced by multi-detector CT.

Computed Tomography of the Sternoclavicular Joint

CT of the SC joint is performed with the patient in the supine position, using a slice thickness of approximately 1.5 mm with coronal and sagittal reformatted images. It is necessary to image both joints for comparison and detection of subtle abnormalities. The patient is usually placed in the neutral position or rarely, a “stress” scan can be obtained by asking the patient to internally rotate the humerus of the affected side and bring the arm medially across the chest and pull against the contralateral elbow [65]. Scans should be viewed at both bone (window level 250 HU, window width 1000 HU) and soft tissue settings (window level 30 HU, window width 500 HU) [66].

CT, with its excellent visualization of joint alignment and articular surfaces, has all but completely replaced radiographs in the evaluation of the SC joint. Additionally, the wide availability of CT scanners and markedly shortened scan time makes it the diagnostic modality of choice in trauma patients. Moreover, the ability to reformat CT data to reconstruct additional imaging planes has been very beneficial, particularly in pre-operative evaluation [67]. 3D reconstructions are an excellent method of illustrating clavicle fractures as well as SC joint dislocations (Fig. 4.31). If the patient sustains a posterior SC joint dislocation, the CT scan should be performed with intravenous contrast to exclude vascular injury (Fig. 4.32).

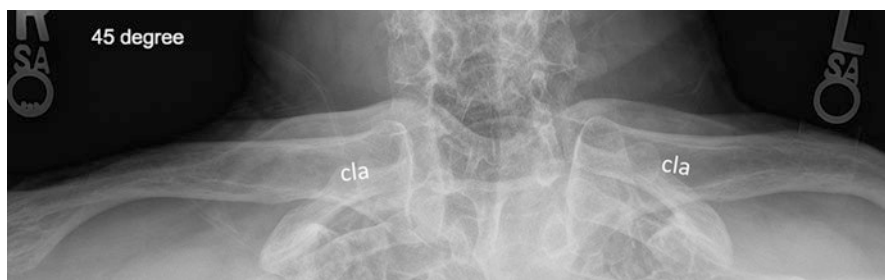

Fig. 4.30 Serendipity view of normal bilateral SC joints with the tube angled at 45°

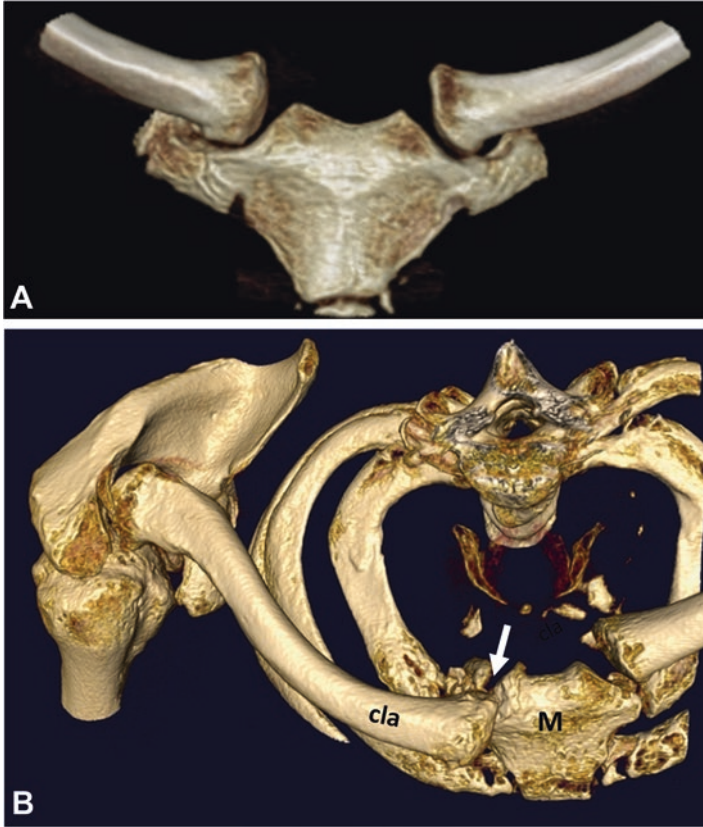


Fig. 4.31 (a) 3D reformatted CT image of normal and symmetric SC joints. (b) 3D reformatted CT image of 84-year-old man with non-traumatic anterior subluxation of the right SC joint (arrow). *cla* clavicle, *M* manubrium

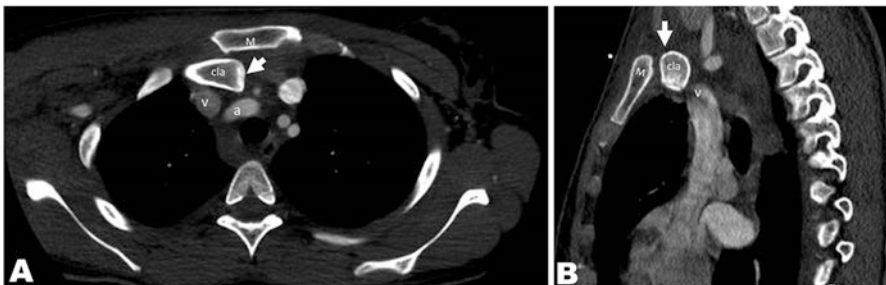


Fig. 4.32 (a) Axial and (b) Sagittal-reformatted contrast-enhanced CT of the chest demonstrates a posterior SC dislocation (arrow) with the clavicle coming in near approximation to the brachiocephalic vein (v) and artery (a). *cla* clavicle, *M* manubrium. *Case courtesy of Roger J. Bartolotta, M.D., Assistant Professor of Radiology, Weill Cornell Medicine*

In effect, the wide availability, rapid scan time, and ability to reformat in various planes as well as three-dimensionally makes CT very valuable for screening as well as pre-operative guidance in trauma patients [67]. However, note is made that imaging protocols must take into account measures for optimizing radiation dose and the exam must be performed *as low as reasonably achievable* (ALARA) [68]. This guiding principle for dose management in CT is that the correct dose for a CT examination takes into account the specific patient attenuation (or size) and the specific diagnostic question.

Magnetic Resonance Imaging of the Sternoclavicular Joint

While delineation of osseous anatomy is superior with CT, MRI allows for examination of both osseous and soft-tissue structures, including the supporting ligamentous structures of the SC joint. Additionally, in the case of a posterior dislocation, MR angiography can be performed at the same sitting [69].

Some authors advocate prone positioning for the evaluation of the SC joints, as it stabilizes the joint as well as decreases respiratory motion artifact [54]. It is the author's preference to perform MR imaging in the supine position. In our experience, the prone position can be very uncomfortable for patients, ultimately resulting in motion artifact, which degrades image quality. At our institution, imaging of the SC joints is performed in both the coronal and axial planes of imaging. The coronal plane is ideal for evaluating the articular surfaces of the SC joints as well for evaluating symmetry. Additionally, the coronal plane with thin (2 mm) slices allows accurate evaluation of the articular disc, and the costoclavicular and interclavicular ligaments (Fig. 4.33). The axial plane is useful for depiction of the SC ligaments, particularly the anterior ligament. The posterior SC ligament can also be seen on the coronal images by scrolling posteriorly. Additional planes such as the sagittal can be helpful in seeing the costoclavicular ligament and the oblique transaxial plane can be used to define the relationship of the medial clavicle and the manubrium [70].

Because of the strong ligamentous stabilizers of the SC joint, a large energy vector is required to disrupt this articulation. Allman classified SC joint injuries based on the degree of ligamentous disruption, almost 50 years ago [1]. Type 1 encompasses a simple sprain of the SC ligaments and capsule without subluxation or dislocation (Fig. 4.34). A Type 2 injury involves disruption of the SC ligaments and capsule and can result in subluxation without frank dislocation. Type 3 injuries involve a rupture of virtually all supporting ligaments with a complete anterior or posterior dislocation. In a study by Benitez et al., they found articular disk and anterior SC ligament injuries were more frequent in patients who had a component of superior subluxation compared to those who had a component of posterior subluxation and conversely, posterior SC ligament injuries were more frequent in patients who had posterior subluxation [64].

Similar to the AC joint, the articular cartilage of the SC joint is fibrocartilage when the patient reaches skeletal maturity. Thus, the articular disk and the cartilage demonstrate similar signal intensities on all pulse sequences. Also of note, the articular cartilage covering the clavicle is thicker than that of over the manubrium [54].

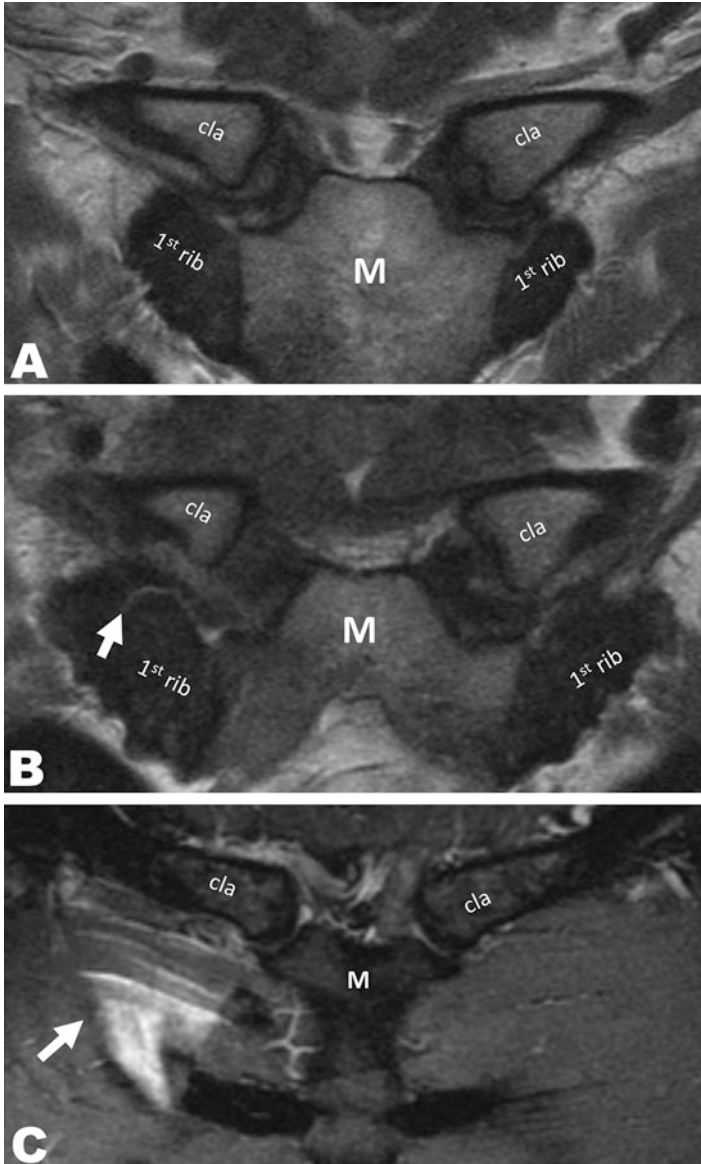


Fig. 4.33 Normal SC joints with rib fracture and muscular contusion. (a) Coronal proton density image of a 36-year-old male, status post blunt trauma to the chest demonstrates symmetric SC joint without dislocation. (b) Further inspection demonstrated a non-displaced fracture of the cartilaginous portion of the right first rib (*arrow*). (c) Coronal inversion recovery image demonstrates direct contusion to the sternal head of the right pectoralis muscle (*arrow*). *cla* clavicle, *M* manubrium

However, it has been well documented that long-term sequelae after trauma to the SC joint may result in painful degenerative changes if cartilage is damaged [71]. Thus, the added usefulness of MRI in evaluating not only the osseous and soft tissue injury but also cartilage injury with fast spin echo pulse sequences (Fig. 4.35).

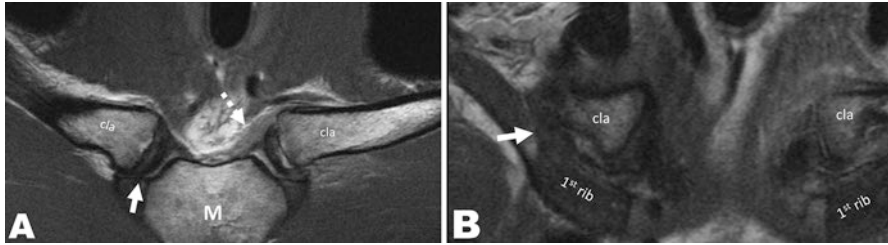


Fig. 4.34 Type I SC joint injury. (a) Coronal proton density image in a 26-year-old NFL football player after a tackling injury demonstrates a partial tear of the left interclavicular ligament (*white dashed arrow*). Note the normal appearing right interclavicular ligament and articular disc (*white arrow*). (b) Coronal proton density image, in the same patient, demonstrates a normal appearing right costoclavicular ligament (*white arrow*). *cla* clavicle, *M* manubrium

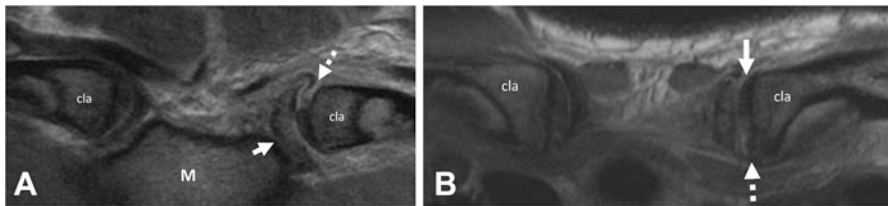


Fig. 4.35 SC joint cartilage shear. (a) Coronal proton density image in a 17-year-old male after a football injury demonstrates complete transection of the articular disk (*dashed arrow*), with concomitant articular cartilage shear (*solid arrow*). (b) Axial proton density image demonstrates cartilage shear posteriorly (*dashed arrow*). Note the preserved cartilage anteriorly (*white arrow*). *cla* clavicle, *M* manubrium

Ultrasound-Guided Injection of the Sternoclavicular Joint

The evaluation and management of patients presenting with SC joint region pain can be clinically challenging. Diagnostic SC joint injections may be used to confirm the joint as a pain generator, and therapeutic corticosteroid injections can reduce symptoms in cases of pain [72, 73]. Guaranteeing precise needle placement into the joint is of utmost importance to ensure both diagnostic specificity and therapeutic benefit [74]. Accordingly, radiologists and orthopaedic surgeons have traditionally used CT and fluoroscopic guidance to inject the SC joint with good clinical outcomes [75]. However, with the advent of musculoskeletal ultrasound, physicians are now able to see the joint in real time with excellent soft tissue imaging. Additionally, ultrasound provides additional advantages over computed tomography and fluoroscopy, such as transportability and most importantly the absence of ionizing radiation [76]. Pourcho et al., in a cadaver study, has reported 100% accuracy of intra-articular SC joint injections when used with sonographic guidance [76].

At our institution, the patient is placed in a supine position, the clavicle is palpated, and a 12–3-MHz linear array transducer is placed on the anterior aspect of the clavicle, parallel to its long axis, and moved medially to the level of the joint (Fig. 4.36a). The appearance of the SC joint demonstrates bony acoustic margins of the clavicle laterally and the manubrium medially. Additionally, in a normal patient, the clavicle lies superficial to the manubrium, creating a step-off that is conspicuous sonographically (Fig. 4.36b) [76]. Next, the transducer location is marked with a pen on the patient's skin and the patient and probe are dressed and draped in the usual sterile fashion. Subsequently, a 25-gauge needle, filled with lidocaine is placed into the joint with sonographic guidance (Fig. 4.37a). The joint is then distended with 1–2 mL of lidocaine, to confirm intra-articular positioning of the needle (Fig. 4.37b). The syringe is next switched to a long-acting anesthetic mixed with steroid, with the needle still in the joint. After the echogenic injectate is seen swirling around in the joint, the needle is removed and the injection site is cleaned.

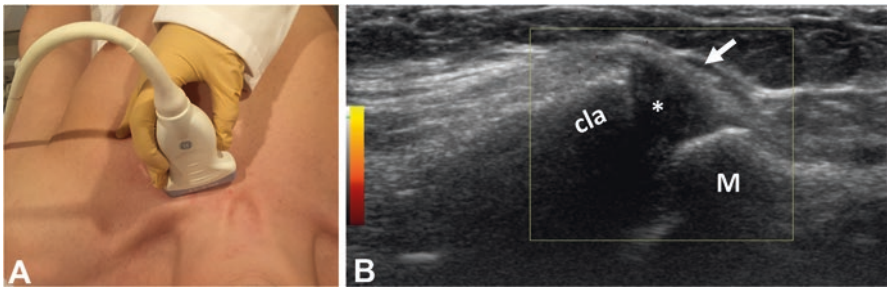


Fig. 4.36 (a) Linear transducer is placed in long axis, parallel to the clavicle over the SC joint, near the midline of the neck. (b) Axial ultrasound of the SC joint (*asterisk*) with power Doppler does not demonstrate hyperemia in a 24 year-old female with pain referable to the joint. The echogenic anterior SC ligament is seen (*white arrow*)

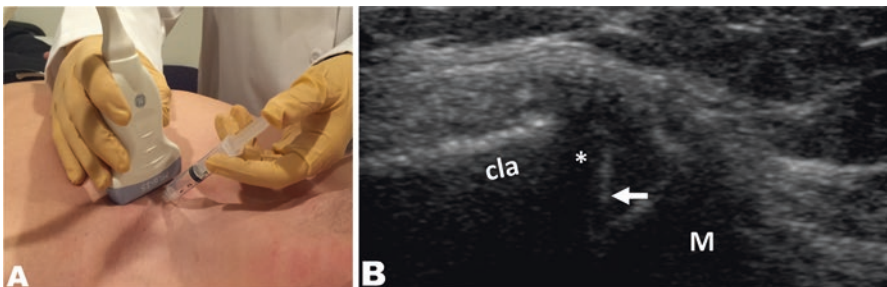


Fig. 4.37 (a) The needle is advanced using a sonographically guided out-of-plane approach. Note position of transducer is similar to Fig. 4.36a. (b) Axial ultrasound shows the bony acoustic margins of the clavicle (*cla*) and manubrium (*M*). The hyperechoic needle tip appears as an echogenic dot (*arrow*) within the SC joint (*asterisk*)

Conclusion

It remains that the sustained improvements in the treatment of clavicular pathology will rely on regular, updated communication between orthopaedic surgeons and radiologists. As outlined earlier, the scope and logistics of advanced imaging of the clavicle (and associated structures) have evolved in recent years. While radiography of the clavicle is far from redundant, MRI allows clinicians to further characterize more high-energy, complex injury patterns in the acute setting without compromising patient safety. In the post-operative setting, clinical suspicions regarding hardware failure, fracture non-union, and the status of soft tissue repairs may now be evaluated in finer detail with both CT and MRI. Finally, there is little doubt that incorporating these advances in the delivery of clinical care will optimize treatment strategies and guide patient expectation.

References

1. Allman Jr FL. Fractures and ligamentous injuries of the clavicle and its articulation. *J Bone Joint Surg Am.* 1967;49(4):774–84.
2. Neer II. CS. Fracture of the distal clavicle with detachment of the coracoclavicular ligaments in adults. *J Trauma.* 1963;3:99–110.
3. Crevelled EV. Fractures of the clavicle. In: Rockwood CA, Matsen FA, editors. *The shoulder.* Philadelphia: WB Saunders; 1990. p. 367–412.
4. Robinson CM. Fractures of the clavicle in the adult. Epidemiology and classification. *J Bone Joint Surg Br.* 1998;80(3):476–84.
5. Pavlov H, Burke M, Giesa M, et al. *Orthopaedist's guide to plain film imaging.* New York: Thieme; 1999.
6. Fishman EK. Spiral CT evaluation of the musculoskeletal system. In: Fishman EK, Jeffrey RB, editors. *Spiral CT: principles, techniques and clinical applications.* New York: Lippincott-Raven; 1998. pp. 273–98.
7. Pretorius ES, Fishman EK. Helical (spiral) CT of the musculoskeletal system. *Radiol Clin N Am.* 1995;33(5):949–79.
8. Kim HN, Liu XN, Noh KC. Use of a real-size 3D-printed model as a preoperative and intraoperative tool for minimally invasive plating of comminuted midshaft clavicle fractures. *J Orthop Surg Res.* 2015;10:91.
9. Bearn JG. Direct observations on the function of the capsule of the sternoclavicular joint in clavicular support. *J Anat.* 1967;101(Pt 1):159–70.
10. van der Meijden OA, Gaskill TR, Millett PJ. Treatment of clavicle fractures: current concepts review. *J Shoulder Elb Surg/Am Shoulder Elb Surg [et al].* 2012;21(3):423–9.
11. Hanby CK, Pasque CB, Sullivan JA. Medial clavicle physis fracture with posterior displacement and vascular compromise: the value of three-dimensional computed tomography and duplex ultrasound. *Orthopedics.* 2003;26(1):81–4.
12. Rydberg J, Buckwalter KA, Caldemeyer KS, Phillips MD, Conces Jr DJ, Aisen AM, et al. Multisection CT: scanning techniques and clinical applications. *Radiographics.* 2000;20(6):1787–806.
13. Wang G, Frei T, Vannier MW. Fast iterative algorithm for metal artifact reduction in X-ray CT. *Acad Radiol.* 2000;7(8):607–14.

14. Robertson DD, Weiss PJ, Fishman EK, Magid D, Walker PS. Evaluation of CT techniques for reducing artifacts in the presence of metallic orthopedic implants. *J Comput Assist Tomogr.* 1988;12(2):236–41.
15. Link TM, Berning W, Scherf S, Joosten U, Joist A, Engelke K, et al. CT of metal implants: reduction of artifacts using an extended CT scale technique. *J Comput Assist Tomogr.* 2000;24(1):165–72.
16. Bauer RW, Kramer S, Renker M, Schell B, Larson MC, Beeres M, et al. Dose and image quality at CT pulmonary angiography—comparison of first and second generation dual-energy CT and 64-slice CT. *Eur Radiol.* 2011;21(10):2139–47.
17. Schenzle JC, Sommer WH, Neumaier K, Michalski G, Lechel U, Nikolaou K, et al. Dual energy CT of the chest: how about the dose? *Investig Radiol.* 2010;45(6):347–53.
18. Vieth V, Schulz R, Brinkmeier P, Dvorak J, Schmeling A. Age estimation in U-20 football players using 3.0 tesla MRI of the clavicle. *Forensic Sci Int.* 2014;241:118–22.
19. Bydder GM, Pennock JM, Steiner RE, Khenia S, Payne JA, Young IR. The short TI inversion recovery sequence—an approach to MR imaging of the abdomen. *Magn Reson Imaging.* 1985;3(3):251–4.
20. Reeder SB, Pineda AR, Wen Z, Shimakawa A, Yu H, Brittain JH, et al. Iterative decomposition of water and fat with echo asymmetry and least-squares estimation (IDEAL): application with fast spin-echo imaging. *Magn Reson Med.* 2005;54(3):636–44.
21. Alexander OM. Radiography of the acromioclavicular articulation. *Med Radiogr Photogr.* 1954;30(2):34–9.
22. Lehtinen JT, Kaarela K, Belt EA, Kautiainen HJ, Kauppi MJ, Lehto MU. Incidence of acromioclavicular joint involvement in rheumatoid arthritis: a 15 year endpoint study. *J Rheumatol.* 1999;26(6):1239–41.
23. Rockwood CAJ, Williams GR, Young D. Disorders of the acromioclavicular joint. In: Rockwood CAJ, Matsen F, editors. *The shoulder.* Philadelphia: Saunders; 1998. p. 483–553.
24. Bontempo NA, Mazzocca AD. Biomechanics and treatment of acromioclavicular and sternoclavicular joint injuries. *Br J Sports Med.* 2010;44(5):361–9.
25. Salter Jr EG, Nasca RJ, Shelley BS. Anatomical observations on the acromioclavicular joint and supporting ligaments. *Am J Sports Med.* 1987;15(3):199–206.
26. Fukuda K, Craig EV, An KN, Cofield RH, Chao EY. Biomechanical study of the ligamentous system of the acromioclavicular joint. *J Bone Joint Surg Am.* 1986;68(3):434–40.
27. Debski RE, Parsons IM, Woo SL, Fu FH. Effect of capsular injury on acromioclavicular joint mechanics. *J Bone Joint Surg Am.* 2001;83-A(9):1344–51.
28. Costic RS, Vangura Jr A, Fenwick JA, Rodosky MW, Debski RE. Viscoelastic behavior and structural properties of the coracoclavicular ligaments. *Scand J Med Sci Sports.* 2003;13(5):305–10.
29. Mazzocca AD, Spang JT, Rodriguez RR, Rios CG, Shea KP, Romeo AA, et al. Biomechanical and radiographic analysis of partial coracoclavicular ligament injuries. *Am J Sports Med.* 2008;36(7):1397–402.
30. Klassen JMB, Ann KN. Surgical anatomy and the function of the acromioclavicular and coracoclavicular ligaments. *Oper Tech Sports Med.* 1997;(5):50–64.
31. Renfree KJ, Wright TW. Anatomy and biomechanics of the acromioclavicular and sternoclavicular joints. *Clin Sports Med.* 2003;22(2):219–37.
32. Cox JS. The fate of the acromioclavicular joint in athletic injuries. *Am J Sports Med.* 1981;9(1):50–3.
33. Waldrop JI, Norwood LA, Alvarez RG. Lateral roentgenographic projections of the acromioclavicular joint. *Am J Sports Med.* 1981;9(5):337–41.
34. Petersson CJ. Degeneration of the acromioclavicular joint. A morphological study. *Acta Orthop Scand.* 1983;54(3):434–8.
35. de la Puente R, Boutin RD, Theodorou DJ, Hooper A, Schweitzer M, Resnick D. Post-traumatic and stress-induced osteolysis of the distal clavicle: MR imaging findings in 17 patients. *Skelet Radiol.* 1999;28(4):202–8.

36. Alasaarela E, Tervonen O, Takalo R, Lahde S, Suramo I. Ultrasound evaluation of the acromioclavicular joint. *J Rheumatol.* 1997;24(10):1959–63.
37. Peh WC, Farmer TH, Totty WG. Acromial arch shape: assessment with MR imaging. *Radiology.* 1995;195(2):501–5.
38. Schaefer FK, Schaefer PJ, Brossmann J, Hilgert RE, Heller M, Jahnke T. Experimental and clinical evaluation of acromioclavicular joint structures with new scan orientations in MRI. *Eur Radiol.* 2006;16(7):1488–93.
39. Bossart PJ, Joyce SM, Manaster BJ, Packer SM. Lack of efficacy of ‘weighted’ radiographs in diagnosing acute acromioclavicular separation. *Ann Emerg Med.* 1988;17(1):20–4.
40. Alyas F, Curtis M, Speed C, Saifuddin A, Connell D. MR imaging appearances of acromioclavicular joint dislocation. *Radiographics.* 2008;28(2):463–79; quiz 619.
41. Peyron JG. Osteoarthritis. The epidemiologic viewpoint. *Clin Orthop Relat Res.* 1986;213:13–9.
42. Henry MH, Liu SH, Loffredo AJ. Arthroscopic management of the acromioclavicular joint disorder. A review. *Clin Orthop Relat Res.* 1995;316:276–83.
43. Brown WE, Potter HG, Marx RG, Wickiewicz TL, Warren RF. Magnetic resonance imaging appearance of cartilage repair in the knee. *Clin Orthop Relat Res.* 2004;422:214–23.
44. Cahill BR. Osteolysis of the distal part of the clavicle in male athletes. *J Bone Joint Surg Am.* 1982;64(7):1053–8.
45. Slawski DP, Cahill BR. Atraumatic osteolysis of the distal clavicle. Results of open surgical excision. *Am J Sports Med.* 1994;22(2):267–71.
46. Patten RM. Atraumatic osteolysis of the distal clavicle: MR findings. *J Comput Assist Tomogr.* 1995;19(1):92–5.
47. Wasserman BR, Pettrone S, Jazrawi LM, Zuckerman JD, Rokito AS. Accuracy of acromioclavicular joint injections. *Am J Sports Med.* 2013;41(1):149–52.
48. Borbas P, Kraus T, Clement H, Grechenig S, Weinberg AM, Heidari N. The influence of ultrasound guidance in the rate of success of acromioclavicular joint injection: an experimental study on human cadavers. *J Shoulder Elb Surg/Am Shoulder Elb Surg [et al].* 2012;21(12):1694–7.
49. Peck E, Lai JK, Pawlina W, Smith J. Accuracy of ultrasound-guided versus palpation-guided acromioclavicular joint injections: a cadaveric study. *PM R.* 2010;2(9):817–21.
50. Iannotti JP, Williams GR. Disorders of the shoulder: diagnosis and management. Philadelphia: Lippincott Williams & Wilkins; 1999. p. 765–813.
51. Cave EF, Harvard Medical School. Fractures and other injuries. Chicago: Yearbook Medical Publishers; 1958. p. 258.
52. Groh GI, Wirth MA. Management of traumatic sternoclavicular joint injuries. *J Am Acad Orthop Surg.* 2011;19(1):1–7.
53. Nettles JL, Linscheid RL. Sternoclavicular dislocations. *J Trauma.* 1968;8(2):158–64.
54. Klein MA, Spreitzer AM, Miro PA, Carrera GF. MR imaging of the abnormal sternoclavicular joint—a pictorial essay. *Clin Imaging.* 1997;21(2):138–43.
55. Martin SD, Altchek D, Erlanger S. Atraumatic posterior dislocation of the sternoclavicular joint. A case report and literature review. *Clin Orthop Relat Res.* 1993;292:159–64.
56. Mehta JC, Sachdev A, Collins JJ. Retrosternal dislocation of the clavicle. *Injury.* 1973;5(1):79–83.
57. Higginbotham TO, Kuhn JE. Atraumatic disorders of the sternoclavicular joint. *J Am Acad Orthop Surg.* 2005;13(2):138–45.
58. Macdonald PB, Lapointe P. Acromioclavicular and sternoclavicular joint injuries. *Orthop Clin North Am.* 2008;39(4):535–45. viii.
59. Cope R. Dislocations of the sternoclavicular joint. *Skelet Radiol.* 1993;22(4):233–8.
60. Cope R, Riddervold HO, Shore JL, Siström CL. Dislocations of the sternoclavicular joint: anatomic basis, etiologies, and radiologic diagnosis. *J Orthop Trauma.* 1991;5(3):379–84.
61. Cave AJ. The nature and morphology of the costoclavicular ligament. *J Anat.* 1961;95:170–9.

62. Tubbs RS, Shah NA, Sullivan BP, Marchase ND, Comert A, Acar HI, et al. The costoclavicular ligament revisited: a functional and anatomical study. *Romanian J Morphol Embryol.* 2009;50(3):475–9.
63. Lee JT, Campbell KJ, Michalski MP, Wilson KJ, Spiegl UJ, Wijdicks CA, et al. Surgical anatomy of the sternoclavicular joint: a qualitative and quantitative anatomical study. *J Bone Joint Surg Am.* 2014;96(19):e166.
64. Benitez CL, Mintz DN, Potter HG. MR imaging of the sternoclavicular joint following trauma. *Clin Imaging.* 2004;28(1):59–63.
65. Burnstein MI, Pozniak MA. Computed tomography with stress maneuver to demonstrate sternoclavicular joint dislocation. *J Comput Assist Tomogr.* 1990;14(1):159–60.
66. Hatfield MK, Gross BH, Glazer GM, Martel W. Computed tomography of the sternum and its articulations. *Skelet Radiol.* 1984;11(3):197–203.
67. Dalinka MK, Boorstein JM, Zlatkin MB. Computed tomography of musculoskeletal trauma. *Radiol Clin North Am.* 1989;27(5):933–44.
68. Sodhi KS, Krishna S, Saxena AK, Sinha A, Khandelwal N, Lee EY. Clinical application of ‘Justification’ and ‘Optimization’ principle of ALARA in pediatric CT imaging: “how many children can be protected from unnecessary radiation?”. *Eur J Radiol.* 2015;84(9):1752–7.
69. Ernberg LA, Potter HG. Radiographic evaluation of the acromioclavicular and sternoclavicular joints. *Clin Sports Med.* 2003;22(2):255–75.
70. Brossmann J, Stabler A, Preidler KW, Trudell D, Resnick D. Sternoclavicular joint: MR imaging— anatomic correlation. *Radiology.* 1996;198(1):193–8.
71. de Jong KP, Sukul DM. Anterior sternoclavicular dislocation: a long-term follow-up study. *J Orthop Trauma.* 1990;4(4):420–3.
72. Jung J, Molinger M, Kohn D, Schreiber M, Pfreundschuh M, Assmann G. Intra-articular glucocorticosteroid injection into sternocostoclavicular joints in patients with SAPHO syndrome. *Semin Arthritis Rheum.* 2012;42(3):266–70.
73. Wisniewski SJ, Smith J. Synovitis of the sternoclavicular joint: the role of ultrasound. *Am J Phys Med Rehabil.* 2007;86(4):322–3.
74. Hall MM. The accuracy and efficacy of palpation versus image-guided peripheral injections in sports medicine. *Curr Sports Med Rep.* 2013;12(5):296–303.
75. Peterson CK, Saupé N, Buck F, Pfirrmann CW, Zanetti M, Hodler J. CT-guided sternoclavicular joint injections: description of the procedure, reliability of imaging diagnosis, and short-term patient responses. *AJR Am J Roentgenol.* 2010;195(6):W435–9.
76. Pourcho AM, Sellon JL, Smith J. Sonographically guided sternoclavicular joint injection: description of technique and validation. *J Ultrasound Med.* 2015;34(2):325–31.

Chapter 5

Anesthesia for Clavicle Fractures

Joshua Dooley and Gavin Martin

Clavicle fractures are common, occurring in up to 5% of all fractures and 35% of shoulder girdle fractures [1]. Many of these will require surgical correction and thus also require anesthesia. There are well documented complications associated with clavicle fractures and surgical correction of clavicle fractures [2–4]. Pain from the fracture and from surgical correction can be difficult to manage.

Anesthesia considerations should include complications from the initial injury. Possible complications would include vascular compression or laceration, inwardly displaced fracture fragments with corresponding pneumothorax/hemothorax, pulmonary contusion, rib fractures and brachial plexus injury. Direct injury to the clavicle can occur during road traffic accidents from either the seatbelt or the steering wheel. With such a blunt force trauma associated injuries include sternal fracture and cardiac contusions. Cardiac contusions are not a contraindication to general anesthesia, but invasive hemodynamic monitoring during the anesthetic would be prudent [5]. In addition to proper monitoring, patients with a myocardial contusion have a 1.5-fold increase in mortality [6]. Advances in ultrasound imaging have led to widespread use in evaluation of the trauma patient. Specifically, chest ultrasonography has been shown to have a higher diagnostic value in detection of pneumothorax and pulmonary contusion compared to radiography [7]. In addition to improving detection, point of care ultrasound is less costly, is easier to access and offers less exposure of the patient to radiation. It is vitally important to recognize a pneumothorax prior to induction of general anesthesia and positive pressure ventilation because of the risk of the pneumothorax becoming a life-threatening tension pneumothorax.

J. Dooley, M.D. (✉)
Department of Anesthesiology, Duke University Hospital,
2301 Erwin Road, Durham, NC 27710, USA
e-mail: Joshua.dooley@duke.edu

G. Martin, M.B., Ch.B., D.A., F.R.C.A.
Department of Anesthesiology, Duke University, Box 3094, Durham, NC 27710, USA
e-mail: marti091@mc.duke.edu

Not only should there be hyper-vigilance in evaluating clavicle fractures from high-energy sources but also that of low-energy fractures. Prompt recognition of hemopneumothorax in a low-energy clavicle fracture with placement of a chest tube and involvement of a multidisciplinary team including cardiothoracic, trauma and orthopedic surgery has been employed with good outcome [8]. The use of nitrous oxide is often part of the maintenance phase of a general anesthesia; this has been shown to rapidly increase any existing pneumothorax [9]. With any suspected lung injury, nitrous should be avoided. Unrecognized arterial damage on the affected side may be continuously monitored through the use of ipsilateral pulse oxymetry such that any decrease in waveform or saturation may indicate evolving arterial disruption and/or occlusion. Depending on the particular kind of fracture and the surgical plan for correction, cardiac bypass may need to be on standby during the case due possible risk of injury to large vessels. Imaging studies and a full clinical evaluation of the patient by the anesthesiologist should be performed prior to any procedure with particular attention to a directed neurological exam to determine any pre-existing brachial plexus injury.

The use of regional anesthesia in this setting has allowed for improved pain control. The particular nerve block appropriate for clavicle fractures and surgery is currently in debate. Interventional strategies proposed include superficial cervical plexus blocks (SCPBs), inter-scalene brachial plexus blocks (ISBs) or a combination. The reason for controversy is due to the multiple nerves that may innervate the clavicle. While most anatomy textbooks describe innervation of the skin above the clavicle via the supraclavicular nerve, very few texts describe the actual bone innervation of the clavicle and these descriptions differ. The supraclavicular, subclavian, long thoracic and suprascapular nerves may all, partially or singularly be responsible for pain transmission. As reviewed by Tran in 2013 as many as eight renowned anatomists have characterized the sclerotomal innervation of the clavicle and noted varied input from C4 to C6 [10].

Superficial Cervical Plexus Block

The superficial cervical plexus (SCP) originates from ventral rami of C1–C4 spinal nerves. Importantly the plexus supplies the supraclavicular nerve (C3–C4), which innervates the clavicle and the sternoclavicular and acromioclavicular joints [11]. The SCP block is classically taught as a blind field block. Complications from this blind technique can occur from inadvertent deep injection of local anesthetic. Specifically, this can lead to interruption of the phrenic nerve, cervical plexus, brachial plexus and recurrent laryngeal nerve. With the recent increased utilization of ultrasound for nerve blocks and real-time visualization of local anesthetic deposition, a decrease in these complications can be achieved. However, even with a well-placed block, migration of local anesthetic can lead to Horner's syndrome after the block [12]. The physician should be aware of this and discuss with the patient prior to block placement as a benign side effect.

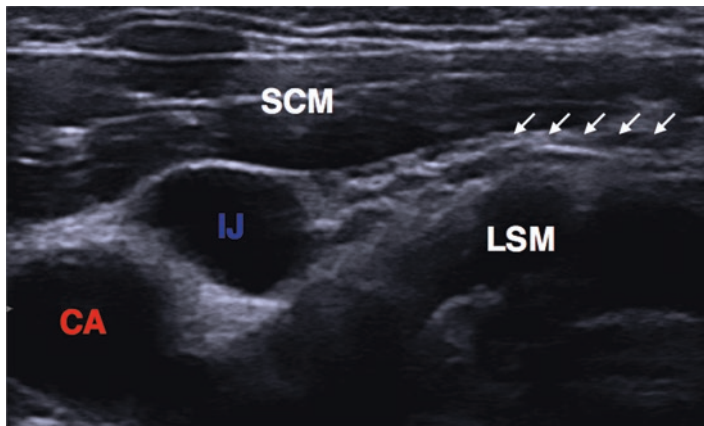


Fig. 5.1 Ultrasound image for placement of superficial cervical plexus (SCP) block. The SCP block is performed after identifying the carotid artery (CA), internal jugular vein (IJ), levator scapulae muscle (LSM) and sternocleidomastoid muscle (SCM) noting its posterolateral border and injection site (*arrows*) just deep the SCM fascia

Placement of this nerve block is performed using a high-frequency linear ultrasound probe. Structures that need to be identified prior to block placement are the sternocleidomastoid muscle (SCM), levator scapulae muscle, hypoechoic greater auricular nerve and Doppler identified carotid artery and other vessels, which should be avoided during block placement (Fig. 5.1). Real-time continuous needle visualization should be maintained throughout the procedure with needle insertion at the posterior border of the SCM at the level of the cricoid cartilage. Final needle tip position should be such that local anesthetic deposition occurs just deep to the SCM along the posterolateral border. The injection of local anesthetic should be above the pre-vertebral fascia in order to avoid a deep cervical plexus block. This block can be performed for surgical analgesia or for analgesia for clavicle fractures in the emergency department [13].

Interscalene Block

While the SCP can reliably block pain fibers originating in the C4 root, it will not cover C5 or C6, which is necessary for complete coverage of all pain fibers from the clavicle. Post-operative pain relief has been achieved with SCP, but it is unclear if this would allow for complete surgical anesthesia/analgesia [14].

In order to achieve complete coverage of the pain originating from the clavicle, an interscalene block can offer increased coverage. Either nerve stimulation or ultrasound can be used to perform an interscalene nerve block, but the use of ultrasound compared to nerve stimulation decreases risk of local anesthetic systemic toxicity and the incidence and intensity of phrenic nerve disruption [15].

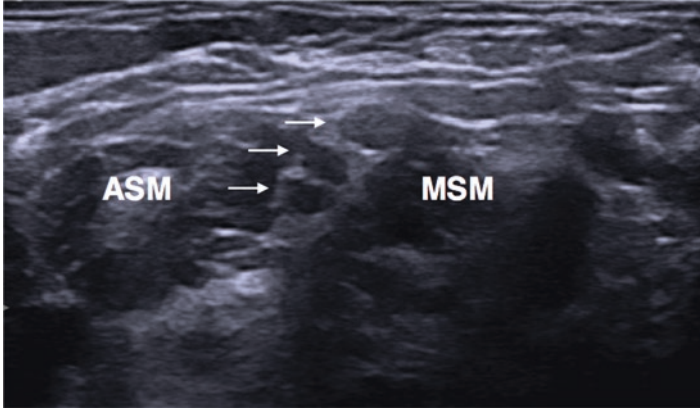


Fig. 5.2 Ultrasound image for placement of interscalene block (ISB). The ISB is placed after identifying the anterior scalene muscle (ASM) and the middle scalene muscle (MSM) with the hypoechoic brachial plexus sandwiched between the muscles

Using a high-frequency ultrasound probe, the structures that need to be identified are the carotid artery, the internal jugular vein, the SCM, the anterior and middle scalene muscles and the brachial plexus in the interscalene groove. The plexus at this level is hyperechoic and the block is performed by placing local anesthetic within the fascia and avoiding an intra-fascicular injection into the nerve roots of the plexus (Fig. 5.2). An interscalene block will reliably block nerve fibers originating from C5 to C7. Because of the distribution of this block, there is often sparing of the ulnar nerve, which is why this block is not used for procedures below the elbow. With this block, there is a real risk of hemidiaphragmatic paresis, which can be nearly 100% when traditionally performed [16]. The degree of hemiparesis can be decreased by using lower volumes of local anesthetic, and using ultrasound the volume of local anesthetic should be based on visual spread, not a particular pre-set volume [17]. Patients may have some respiratory compensation by having increased contralateral diaphragm movement. Despite the ability of some patients to compensate, it is paramount to try to decrease phrenic nerve disruption as we are encountering an increased number of elderly patients with baseline respiratory dysfunction. Ultrasound-guided interscalene block with extrafascial injection can reduce the incidence of respiratory disruption with similar analgesia to conventional injection techniques [15]. While injecting in an extrafascial plane did reduce phrenic nerve disruption it did increase the time to onset of block and decreased duration.

In addition to providing immediate pain relief for a period of hours during the duration of the local anesthetic, prolonged anesthesia/analgesia can be supplied by a nerve catheter. Through this nerve catheter, either SCP or interscalene, local anesthetic can be delivered in a continuous infusion from a pump for a period of days for pain relief. Ambulatory interscalene nerve catheter infusions have been proven to be effective, convenient and safe [18]. Not all locations are able to provide the necessary infrastructure or trained personnel to manage ambulatory catheters.

In addition to having a clinical framework in place, it is vital that there is appropriate patient selection to ensure a safe, effective implementation of an outpatient nerve catheter service [19].

Historically, opioids have been the sole method for pain control. Opioid-based analgesic therapy has many side effects, and limiting these side effects is one of the main objectives of multimodal analgesia (MMA). Clinical pathways that include MMA have been shown to effectively improve length of stay, post-operative complications, discharge to home and hospital cost [20]. In addition to nerve blocks to aid in pain control, a multimodal analgesia approach is thus recommended. The key to any MMA program is through the use of drugs from different drug classes. Classes most commonly used are opioid (morphine, hydromorphone, and oxycodone), non-steroidals (ibuprofen and COX2-inhibitors), acetaminophen, ketamine, alpha-2 agonists (dexmedetomidine and clonidine) and anti-epileptics (pregabalin, gabapentin).

Sensory innervation of the clavicle remains controversial and thus creates a dilemma when attempting to provide regional anesthesia. Also complicating current understanding of the innervation of the clavicle is the lack of comparative studies evaluating the different types of fractures that can occur and the corresponding distribution of pain. The innervation of the medial portion of the clavicle is ostensibly different than that of the lateral portion. In short, more research is definitely needed, but until a definitive answer has been reached, we are left with choices with little evidentiary support. There are two situations that can be addressed in the near term from strong practical and anatomic standpoint. The first situation to be addressed is analgesia that needs to be provided in the emergency department for pain from a clavicle fracture. The nerve block most appropriate for this setting is the SCP block; it is fairly easy to learn, avoids phrenic nerve paralysis and can be performed quite quickly with good pain relief [12]. Nerve blocks have also been shown to decrease length of stay compared with procedural sedation for upper extremity fractures in the emergency department [21]. The second situation is in the perioperative arena. This location has numerous advantages including time to perform multiple procedures, regional anesthesiologists and a block team to perform more complex nerve blocks. To completely block all of the anatomically understood pain fibers for clavicular surgery, an ISB combined with an SCP block can be performed. Combining these two blocks may be complex and time-consuming but has been demonstrated to provide complete surgical anesthesia for clavicular fracture [22].

Case Report

A 74-year-old female was evaluated in the emergency department for hip pain after a motor vehicle accident. A physician anesthesiologist arrived to evaluate the patient for placement of a femoral nerve catheter per institutional hip fracture protocol. After placement of the femoral nerve catheter and deposition of local anesthetic for immediate pain control the patient noted pain relief in her hip. Upon resolution of her hip pain the patient immediately complained of 8/10 pain in her ipsilateral

shoulder. It was noted that she had bruising consistent with a seatbelt, but a chest X-ray and physical exam did not appreciate any sign of pneumothorax. After discussion with the orthopedic trauma team, an X-ray was also taken of the shoulder, which showed a mid-clavicle fracture.

The patient had several comorbidities. A recent trans-thoracic echocardiogram noted an ejection fraction of 20% from ischemic cardiomyopathy. She had a body mass index of 47 kg/m², her daily activity was limited and she became short of breath walking in her home. The patient also had hypertension, obstructive sleep apnea and uncontrolled type II diabetes mellitus. During a previous surgery with a general anesthetic, she required re-intubation in the post-anesthesia care unit for respiratory distress, continued airway obstruction with elevated blood carbon dioxide levels. She recovered fully after 48 h in the surgical intensive care unit.

The orthopedic surgical team concluded that surgical correction was the most appropriate method of treatment. In discussion with the anesthesiologist, it was decided that a general anesthesia should be avoided, given her comorbidities and previous anesthetic history. In order to accomplish surgical anesthesia for operative closure, an interscalene nerve catheter and a single injection superficial cervical plexus block was performed pre-operatively. After performance of the blocks the patient noted complete relief of pain. The patient was minimally sedated during the case and was able to converse throughout. The surgical repair was successful and the patient was maintained on a local anesthetic infusion of ropivacaine 0.2% at 8 milliliters per hour. The patient was discharged to home 3 days post-operatively with an ambulatory nerve catheter infusion at the same rate and did not require opiates during her hospitalization. The nerve catheter was removed by the patient 2 days after discharge.

References

1. Jeray KJ. Acute midshaft clavicular fracture. *J Am Acad Orthop Surg.* 2007;15(4):239–48.
2. Asadollahi S, et al. Complications associated with operative fixation of acute midshaft clavicle fractures. *Injury.* 2016;47(6):1248–52.
3. Gao Y, et al. Plating versus intramedullary fixation for mid-shaft clavicle fractures: a systemic review and meta-analysis. *PeerJ.* 2016;4:e1540.
4. Bishop JY, Flatow EL. Pediatric shoulder trauma. *Clin Orthop Relat Res.* 2005;432:41–8.
5. Sybrandy KC, Cramer MJ, Burgersdijk C. Diagnosing cardiac contusion: old wisdom and new insights. *Heart.* 2003;89(5):485–9.
6. Vukmir RB. The outcome of cardiac dysfunction in critically ill trauma patients: myocardial contusion complicated by refractory hypotension. *Eur J Trauma Emerg Surg.* 2008;34(3):261–6.
7. Vafaei A, et al. Diagnostic accuracy of ultrasonography and radiography in initial evaluation of chest trauma patients. *Emerg (Tehran).* 2016;4(1):29–33.
8. Tjoumakaris FP, Matzon JL, Williams GR. Clavicle fracture with thoracic penetration and hemopneumothorax but without neurovascular compromise. *Orthopedics.* 2011;34(10):e692–5.
9. Kaur S, Cortiella J, Vacanti CA. Diffusion of nitrous oxide into the pleural cavity. *Br J Anaesth.* 2001;87(6):894–6.

10. Tran DQ, Tiyaprasertkul W, Gonzalez AP. Analgesia for clavicular fracture and surgery: a call for evidence. *Reg Anesth Pain Med.* 2013;38(6):539–43.
11. Marhofer P, P. Marhofer. *Ultrasound guidance in regional anaesthesia: principles and practical implementation.* 2nd ed. Oxford: Oxford University Press; 2010. xxii, 236 p.
12. Flores S, et al. Horner's syndrome after superficial cervical plexus block. *West J Emerg Med.* 2015;16(3):428–31.
13. Herring AA, et al. The ultrasound-guided superficial cervical plexus block for anesthesia and analgesia in emergency care settings. *Am J Emerg Med.* 2012;30(7):1263–7.
14. Choi DS, Atchabahian A, Brown AR. Cervical plexus block provides postoperative analgesia after clavicle surgery. *Anesth Analg.* 2005;100(5):1542–3.
15. Neal JM, et al. The second American Society of Regional Anesthesia and pain medicine evidence-based medicine assessment of ultrasound-guided regional anesthesia: executive summary. *Reg Anesth Pain Med.* 2016;41(2):181–94.
16. Zaragoza-Lemus G, Limon-Munoz M, Garcia-Reyes W. Ultrasonographic assessment of hemidiaphragm paralysis secondary to interscalene block. *Cir Cir.* 2012;80(4):352–6.
17. Hartrick CT, et al. The effect of initial local anesthetic dose with continuous interscalene analgesia on postoperative pain and diaphragmatic function in patients undergoing arthroscopic shoulder surgery: a double-blind, randomized controlled trial. *BMC Anesthesiol.* 2012;12:6.
18. Fredrickson MJ, et al. An analysis of 1505 consecutive patients receiving continuous interscalene analgesia at home: a multicentre prospective safety study. *Anaesthesia.* 2016;71(4):373–9.
19. Marhofer P, et al. A retrospective analysis of 509 consecutive interscalene catheter insertions for ambulatory surgery. *Anaesthesia.* 2015;70(1):41–6.
20. Barbieri A, et al. Effects of clinical pathways in the joint replacement: a meta-analysis. *BMC Med.* 2009;7:32.
21. Stone MB, Wang R, Price DD. Ultrasound-guided supraclavicular brachial plexus nerve block vs procedural sedation for the treatment of upper extremity emergencies. *Am J Emerg Med.* 2008;26(6):706–10.
22. Vandepitte C, et al. Combined interscalene-superficial cervical plexus blocks for surgical repair of a clavicular fracture in a 15-week pregnant woman. *Int J Obstet Anesth.* 2014;23(2):194–5.

Chapter 6

Nonoperative Clavicle Fractures

Michael R. Koerner and Kyle J. Jeray

Abbreviations

AP	Anteroposterior
ASES	American shoulder and elbow surgeon
DASH	Disability of arm shoulder and hand

Introduction

Historically, all clavicle fractures were treated nonoperatively, with acceptance of the associated clinical deformity and less emphasis on patient satisfaction and functional outcomes. However, the cosmetic deformity associated with clavicle fractures treated nonoperatively has long been a concern of patients. Even Hippocrates noted, “A fractured clavicle, like all other spongy bones, gets speedily united; for all such bones form callus in a short time. When, then, a fracture has recently been taken place the patients attach much importance to it, as supposing the mischief greater than it really is, and the physicians bestow great pains in order that it may be properly bandaged; but in a little time the patients having no pain, nor finding any impediment to their walking or eating, become negligent; and the physicians finding they cannot make the parts look well, take themselves off, and are not sorry at the neglect of the patients, and in the meantime the callus is quickly formed” [1]. Dupuytren described the deformity associated with the clavicle fracture as “inevitable”. However, he advocated for simplicity and comfort of treatment by placing the arm on a pillow until clinically healed [2].

M.R. Koerner, M.D. • K.J. Jeray, M.D. (✉)
Greenville Health System, 701 Grove Road, 2nd Floor Support Tower,
Greenville, SC 29605, USA
e-mail: mkoernerMD@ghs.org; kjeray@ghs.org

Clavicle fractures account for 2.6–5% of all fractures treated by orthopedic practitioners [3, 4]. They are the fourth most common fracture of the upper extremity with an incidence of 5.8 per 10,000 people [5]. Men are more than twice as likely to sustain a clavicle fracture with an incidence of 71 out of 100,000 males and 30 out of 100,000 females. Sixty-nine percent to eighty-two percent of these fractures involve the midshaft clavicle, with incidence of midshaft clavicle fractures decreasing as patient age increases [3, 4, 6, 7]. However, the incidence of high-energy midshaft fractures with associated comminution and significant shortening is on the rise [3].

Anatomy

The clavicle is the first bone to ossify around 5 weeks of fetal life, yet the medial physis is the last in the body to fuse around age 24. The clavicle is the only osseous link between the appendicular skeleton and the upper extremity through the sternoclavicular and acromioclavicular joints. With motion of the upper extremity, the clavicle can elevate 15°, retract up to 29°, and rotate through its long axis up to 33° [8, 9]. There are several fascial layers and muscles attached to the clavicle, which lead to the predictable and consistent pattern seen with midshaft clavicle fractures. The sternocleidomastoid pulls the medial fragment superiorly and the distal segment sags and rotates anteriorly secondary to the weight of the shoulder girdle, and the force of the pectoralis muscle on the humerus. The cross-sectional anatomy of the clavicle being triangular shaped medially, cylindrical in the middle third, and flat in the lateral third contributes to the fracture patterns often seen. The junction between the middle and lateral thirds has both the thinnest bone and a bare spot without any ligamentous or muscular attachment making it the most frequent site of fracture [10].

Patient Evaluation

When examining a patient with a clavicle fracture it is essential to evaluate for concomitant injuries. Visual inspection may show shoulder sag/droop or shortening with medialization of the scapula and glenoid. Additionally, the skin over the fracture site must be evaluated to ensure no skin tenting or threatened skin suggesting impending conversion to open fracture [11]. Evaluation for associated rib fractures, proximal humeral, scapula and/or glenoid fractures, and hemothorax or pneumothorax is vital [12]. Patients with any symptoms of these should have a chest X-ray. Some argue that pneumothorax must be evaluated radiographically with a chest radiograph in all patients with clavicle fractures, especially for open clavicle fractures or in patients with altered mentation [11, 13–17]. There are several case reports of pneumothoraces with isolated clavicle fractures, highlighting the need to evaluate a patient for a pneumothorax, especially if there is any suspicion based on the patient's clinical symptoms. [13, 14].

Although rare, clavicle fractures have been shown to lead to thoracic outlet syndrome, brachial plexopathy, and chest wall paresthesias and numbness [18–22]. A thorough neurologic exam of the upper extremity should be included in the initial evaluation of patients with clavicle fractures, to rule out these rare associated injuries. There are also cases of subclavian artery injury including one fatal transection from a midshaft clavicle fracture [23, 24]. Examination should include a bilateral distal upper extremity pulse exam, and if there is any difference between sides, further investigation should be completed. Options for further workup include bilateral blood pressures, distal pulse occlusion pressures, CT angiogram, or vascular surgery consult.

Imaging

Appropriate radiographic evaluation of clavicle fractures is paramount in developing a plan of care. A standard anteroposterior (AP) (Fig. 6.1a) as well as a 45° cephalad tilt view (Fig. 6.1b) should be included. Others recommend a standard AP, a 30° cephalad tilt, and a 60° caudal tilt radiograph to better evaluate the fracture and therefore make better-informed treatment decisions based on true orthogonal radiographs [25]. These radiographs should be obtained in the upright position as the displacement can increase by 89% when compared to the supine view [26]. The radiographs are evaluated for degree of comminution, displacement, angulation,

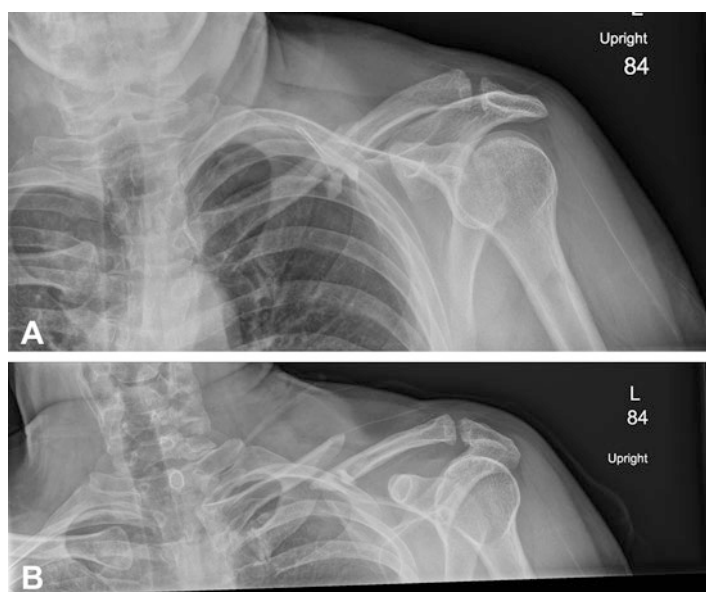


Fig. 6.1 Case 1, Upright anteroposterior (a) and 45° cephalic tilt (b) views showing a midshaft clavicle fracture

and change in length of the fracture. In addition to the fracture, it is important to evaluate for signs of concomitant pneumothorax, glenohumeral, or scapular injury on the radiographic images.

Patients should have upright radiographs obtained within the first 2 weeks. Even nondisplaced clavicle fractures can show significant instability and displacement on subsequent X-rays over 25% of the time, occasionally changing treatment decisions [27]. Higher energy mechanisms of injury are associated with increased likelihood of early displacement of initially minimally displaced fractures [28]. After the first 2 weeks, AP and cephalad tilt X-rays are obtained at 4 to 6 week intervals until radiographic union is obtained.

Indications

Today, widely accepted indications for nonoperative management in adults are nondisplaced or minimally displaced midshaft clavicle fractures and patients who are poor surgical candidates based on medical comorbidities. While open fractures or threatened skin compromise are indications for operative treatment, there are differing opinions regarding the optimal care of clavicle fractures that do not fall into one of the two aforementioned indications. Relative indications for nonsurgical management of clavicle fractures include displacement <1.5 cm, no comminution, bony contact, and shortening of less than 1.5–2 cm. Patients who do not meet these parameters have a higher probability of satisfactory functional and pain outcomes with surgical management [29–31]. Patient activity level, age, gender, soft tissue envelope, handedness, smoking habits, fracture pattern, and mechanism of injury are additional factors that impact management.

Robinson et al. have shown that female gender, increasing age, displacement, and comminution are all predictors of nonunion in midshaft clavicle fractures treated without surgery [29]. Patients should be counseled regarding the importance of smoking cessation and should be encouraged, at least during the period of healing to stop or decrease their smoking [32, 33]. Patients who smoke are four times more likely to progress to nonunion when midshaft clavicle fractures are treated nonsurgically [32, 33].

Murray et al. evaluated risk factors for developing nonunions in displaced midshaft clavicle fractures. They created a “Ready Reckoner” to allow practitioners to estimate the risk of nonunion with nonoperative treatment. They evaluated 941 adult patients with closed displaced midshaft clavicle fractures. Their predictor table is able to provide an expected risk of nonunion for displaced midshaft clavicle fractures treated nonoperatively. These factors included the overall radiographic displacement, smoking history, and fracture comminution. The overall expected risk of nonunion increases with smoking, comminution, and increasing displacement. Operative management of all displaced clavicle fractures requires 7.5 procedures to prevent a single nonunion according to the study. However, using the statistical information from the study, this result may be significantly improved.

If only those patients with an estimated 40% or greater risk of nonunion were treated surgically, the number of procedures required to prevent a single nonunion dropped to 1.7 operations [33].

Goals of Treatment

The goal of treatment is not only radiographic union but, most importantly, returning the patient's shoulder back to as close to preinjury functional level as possible. Neer asserted in Rockwood and Green's *Fractures*, in adults "a certain amount of deformity is to be expected, [but] generally [is] compatible with satisfactory return of function in the shoulder" and even completely displaced fractures "generally do well with nonoperative management" [34]. Much of the early literature focused on radiographic healing as the primary outcome, but over the last two to three decades, there has been increased focus on the importance of more patient reported outcomes in the literature.

Treatment Options

Immobilization of clavicle fractures is generally via figure of eight brace or simple shoulder sling, with the latter being more commonly utilized. A prospective, randomized study showed similar fracture healing between these two treatment methods, but showed that patients had 26% dissatisfaction with the figure of eight brace treatment protocol at 3 months compared to 7% dissatisfaction in the cohort treated with a sling [35]. In a more recent prospective, randomized study, the figure of eight brace also caused significantly more skin complications, most often in the axilla, than the sling. The figure of eight brace has also been suggested to be more painful during the first treatment day than the sling and more difficult for patients and their families to apply than a sling [36]. These have led to the decreased use of the figure of eight brace. The final fracture union with either method of immobilization showed minimal change from the initial amount of displacement, substantiating Neer's statement that there is no good way to hold an attempted reduction of clavicle fractures [35].

Treatment Course

Nonoperative management generally entails a period of 2–6 weeks of immobilization of the shoulder girdle for patient comfort with restricted overhead activities. The arm is generally held in internal rotation with the elbow flexed to approximately 90° in a sling [36]. Patients should be encouraged to remove the sling at several points during the day to work on elbow range of motion to prevent elbow stiffness

[36]. Immobilization can be discontinued and light activities below shoulder level can be resumed as patient comfort allows. Overhead activities are generally restricted for the first 6 weeks. By limiting the abduction and forward flexion to 90° the rotation of the clavicle is limited, minimizing rotational and torsional forces on the acutely healing clavicle. At approximately 6 weeks, most patients are ready to progress to activities as tolerated.

Nonoperative Treatment Adjuncts

In an effort to expedite healing or for treatment of delayed or nonunions, low-intensity pulsed ultrasound (LIPUS) has been attempted. When looking at all fractures the effect of LIPUS is inconsistent, with some randomized studies showing benefit and others showing no benefit [37–40]. A large Cochrane systematic review of 11 heterogeneous randomized or quasi-randomized controlled trials evaluating LIPUS in treating various acute fractures found equivocal results regarding, function, time to union, or pain. They suggest that there is insufficient evidence for the routine use of LIPUS in acute fractures [41]. In contrast, a recent meta-analysis evaluating healing in all bones, not just clavicle fractures, suggested improved outcomes at 6 months in acute fractures treated with LIPUS [42]. Once nonunion has developed, LIPUS showed improved healing in numerous long bone fractures, but again the clavicle was not specifically studied and only made up a small proportion of the included cases (1 out of 29) [43]. There is only one randomized controlled trial evaluating LIPUS in acute midshaft clavicle fractures. A level I study in which 101 adult patients with isolated midshaft clavicle fractures were randomized to either LIPUS or placebo ultrasound probe. They found no difference between placebo and LIPUS in regards to pain, pain medication requirement, return to activities, or subjective healing in the treatment of acute midshaft clavicle fractures. Future level 1 randomized trials are necessary to further evaluate the suggested benefits of LIPUS specific to midshaft clavicle fractures.

Outcomes

Despite the recent trend to surgically fix more midshaft clavicle fractures, authors caution against routine ORIF for all midshaft clavicle fractures [44–47]. Nordqvist et al. retrospectively reviewed outcomes of 225 patients with midshaft clavicle fractures treated nonoperatively with 197 of these placed into a figure of eight brace for approximately 3 weeks. Of the included fractures, 32% of the fractures included were either minimally or nondisplaced. Of all patients, 185 had “good” outcomes and reported an asymptomatic shoulder where 39 had moderate pain and were rated “fair” and only 1 rated “poor”. There were 53 malunions, of which 40 were

asymptomatic. There were seven nonunions, of which three were asymptomatic. They suggest that surgery should not be considered on an acute closed midshaft clavicle fracture without neurovascular or skin compromise [48]. A prospective study of 60 patients treated nonoperatively showed that regardless of the method of nonoperative treatment (sling vs. figure of eight), there was 100% radiographic union at 14 weeks with lesser than 1 cm shortening. Patients ultimately attained full function with Constant and American Shoulder and Elbow Surgeon (ASES) scores in the mid-90s on a 100-point scale with 100 being optimal. One caveat of this study is that 40% of these patients were minimally or nondisplaced [36]. Faldini et al. studied 100 displaced Edinburgh 2B midshaft clavicle fractures treated in a figure of eight brace and 81% had excellent results, 12% had good results, 5% had fair results, and only 2% had poor results based on the Disability of Arm Shoulder and Hand (DASH) scores with a 3% nonunion rate. They concluded that “nonoperative treatment is still appropriate in most cases, as it yields good results without incurring the potential complications of surgery” [49].

Complications

Patients should be aware of all risks and benefits of nonoperative treatment of clavicle fractures during initial patient evaluation. Patients should be counseled to expect approximately 4–12 weeks of pain and decreased function after injury.

Complications of both nonsurgical and surgical treatment of clavicle fractures include cosmetic deformity, nonunion, malunion, pain, local irritation, functional limitations of the shoulder, and need for future surgery. Cosmetic deformity from the “bump” alone has been reported to be the main source of patient dissatisfaction in approximately 40% of those patients who are ultimately unhappy with the outcome of nonoperative treatment [50].

When all complications are included, McKee et al. has shown a 42% complication rate for nonoperative treatment compared with 29% for surgical management of displaced clavicle fractures. However, the most common complications, excluding cosmetic deformity, for nonoperative treatment were nonunion, symptomatic malunion, and neurologic difficulty, whereas the most common operative complications were hardware irritation, pin protrusion, and wound infection [46]. However, it is cautioned that their results do not suggest surgery is necessary for all fractures as this would unnecessarily expose many patients, which would have healed well without surgery, to the risks associated with surgical treatment [47]. Nonoperative management of clavicle fractures avoids the complications specific to surgical treatment especially infection, symptomatic hardware, and anterior chest wall numbness.

Nonunions and malunions are widely accepted as the most frequent complications associated with midshaft clavicle fractures. Patients can have pain, neurologic changes, shoulder dysfunction, and clavicle deformity associated with improper union.

The definition of a clavicle nonunion has not been consistently defined, but is often absence of radiographical healing after 4–6 months [12, 29]. Research from the 1960s and 1970s demonstrated nonunion rates of only 0.1–0.8% for nonsurgical management. More recent literature shows a 0.5–5.9% nonunion rate for nonsurgical management of all midshaft clavicle fractures. However, the nonunion rate is significantly higher at up to 15.1% in completely displaced fractures treated nonoperatively [48, 51]. In the event of nonunion, delayed surgical treatment of nonunion with various techniques has shown 92–100% rates of successful union [52–55].

The majority of clavicle fractures treated without surgery will heal with some degree of deformity, with the most common being shortening with inferior displacement of the lateral fragment [12]. Malunion may be associated with symptoms including loss of shoulder function, loss of endurance, neurologic symptoms, cosmetic deformity, weakness, and pain in the shoulder [56]. Malunion with shortening >1.5 cm may be associated with increased pain [30].

McKee et al. evaluated range of motion, strength, and endurance in midshaft clavicle fractures treated nonoperatively. They found no loss of motion in forward flexion, abduction, or external rotation when compared to the noninjured side. There was a 19% loss of strength in flexion, 18% loss of strength in abduction, 19% loss of strength in external rotation, and 15% loss of strength in internal rotation. There was a 25% loss of endurance in flexion, 33% loss of abduction endurance, 18% loss of external rotation endurance, and 22% loss of internal rotation endurance. DASH and Constant scores showed a significant level of dysfunction at mean follow up of 55 months when compared to the general population [50]. Additionally, a study of midshaft clavicle fractures with final shortening of 15 mm or greater showed reduced peak abduction velocity [57]. However, nonoperative treatment of midshaft clavicle fractures is a viable option given that nonunion and malunion are both manageable complications of this treatment course.

Cost

The cost of treating midshaft clavicle fractures has increased relevance due to the recent emphasis on bundled payments and health care spending. Walton et al. compared the cost of surgical and nonsurgical treatment using 2013 Medicare values. The mean cost for surgical treatment was \$14,763 and nonsurgical cost was \$3113 with nonsurgical treatment saving \$11,650 per patient. They used a set endpoint of either delayed surgery for nonoperative patients or reoperation in operative patients. Nonoperative management was more financially sound compared to initial operative treatment until the point that delayed surgery was required in 95% of nonoperative patients, and reoperation rates for patients treated with surgery initially were below 15%. In fact, this study suggests that treating all closed displaced midshaft clavicle fractures nonoperatively initially and then managing the complications of such when they develop is more fiscally responsible [45]. However, this study fails to assess the patient's lost wages and decreased ability to contribute to society.

In contrast, a study of 204 patients accounting for lost wages, all hospital costs, and postoperative treatment found an ORIF treatment course cost \$12,977 and a nonoperative treatment course cost \$18,068 per patient. Operative patients had a mean lost earnings of \$321 compared to \$10,506 lost wages in the nonsurgically treated group. Additionally, operative patients required 3 days of assistance at home compared to 7 days of assistance for those treated nonoperatively, thus potentially causing lost wages in additional family members. Mean emergency room bills were similar, but the operative group did accrue an additional \$8500 hospital bill. Operative patients utilized half the physical therapy of the nonoperative group (\$900 vs. \$1800) [58]. Other research shows that ORIF of clavicle fractures compared to nonoperative management is cost-effective only when the improved functional outcome associated with ORIF persists for 9 years [59].

It is unclear which treatment option is more fiscally responsible, likely due to the variability of surgical indications and the heterogeneity of these two study groups. The financial implications of the treatment of clavicle fractures will be an integral part of treatment, and likely topic of much discussion in the coming years.

Summary

The recent focus on functional outcomes and cost has called into question the historic nonoperative treatment of midshaft clavicle fractures. The modern widely accepted indications for nonoperative management of clavicle fractures include nondisplaced or minimally displaced fractures and those patients who may not be surgical candidates based on medical comorbidities. The two most commonly utilized nonoperative treatment options are a simple sling, or figure of eight brace, although the sling has become more popular in recent years. All patient factors including baseline activity level, handedness, fracture pattern, patient expectation, mechanism of injury, and risk factors for nonunion should be evaluated and discussed with the patient. Patients should be counseled that nonoperative management in most cases will provide a successful outcome, however some may require delayed surgery. A thorough discussion should occur with the patient including the risks and benefits of surgical and nonsurgical management of clavicle fractures to develop a treatment plan that is mutually acceptable to the patient and the physician.

Cases

Case 1

Case 1 is a 52-year-old right hand dominant male involved in a low-speed (10 mph) motorcycle collision. In the emergency room, the patient was found to have a small left pneumothorax, which did not require a chest tube. A left midshaft clavicle fracture was identified on his trauma chest radiograph. Upright clavicle radiographs

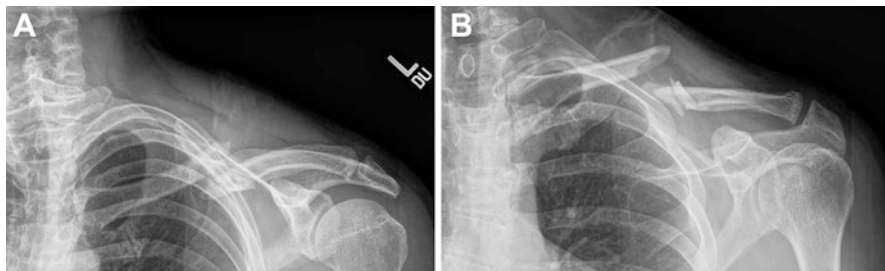


Fig. 6.2 Case 1, anteroposterior (a) and 45° cephalic tilt (b) radiographs taken at 8 days post-injury showing increased displacement

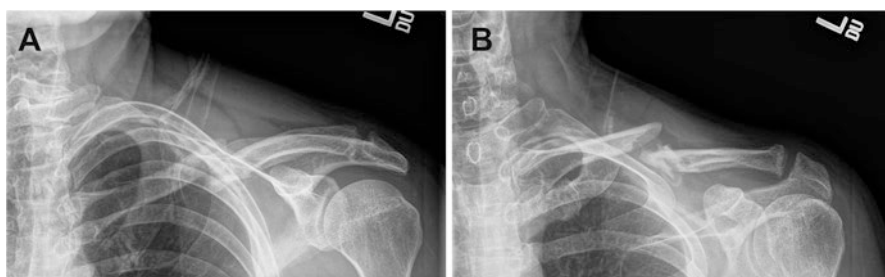

Fig. 6.3 Case 1, anteroposterior (a) and 45° cephalic tilt (b) radiographs at 6-week follow-up with visible callus

were then obtained (Fig. 6.1a, b). He was admitted overnight to monitor the pneumothorax. He had a history of hypertension and never smoked. His left arm was placed in a sling at admission, and he was discharged from the hospital the next day after being cleared by general surgery. He was seen 8 days after his injury and his pain was well controlled on occasional ibuprofen. Radiographs showed minimal change from the emergency room upright films (Fig. 6.2a, b). He was counseled on treatment options including benefits and risks of both and opted for nonoperative treatment. At his 2-week visit, he reported that he was comfortable doing activities of daily living without his sling. We discussed treatment options again and he elected to continue nonoperative management. At his 6-week follow up, he was only having occasional mild fracture site pain. There was a palpable and visible bump over the midshaft clavicle at this visit (Fig. 6.3a, b). By his 12 week follow-up, he had returned to his job stocking shelves and occasionally lifting up to 50 lbs with only minimal pain. There was still a prominence over the midshaft clavicle. He started working on his golf swing around 4 months out from the injury and reported no discomfort. At the 8-month follow up visit, he reported no pain. Upright clavicle radiographs showed a z-deformity of the clavicle with incomplete union (Fig. 6.4a, b). Despite his incomplete radiographic healing, he was clinically completely asymptomatic, denied any functional deficits, and had full symmetric range of motion (Fig. 6.5a, b).

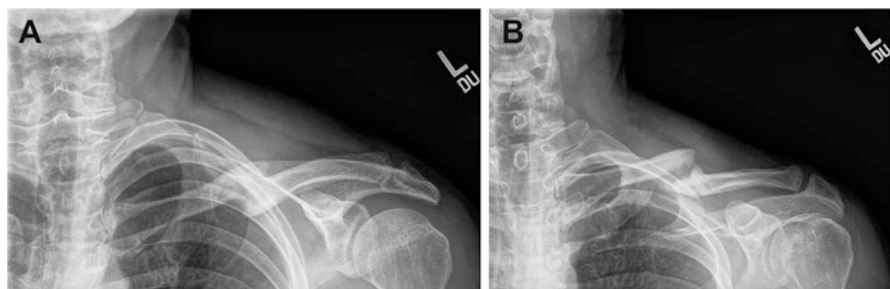

Fig. 6.4 Case 1, anteroposterior (a) and 45° cephalic tilt (b) radiographs at 8-month follow-up showing z-deformity and questionable union

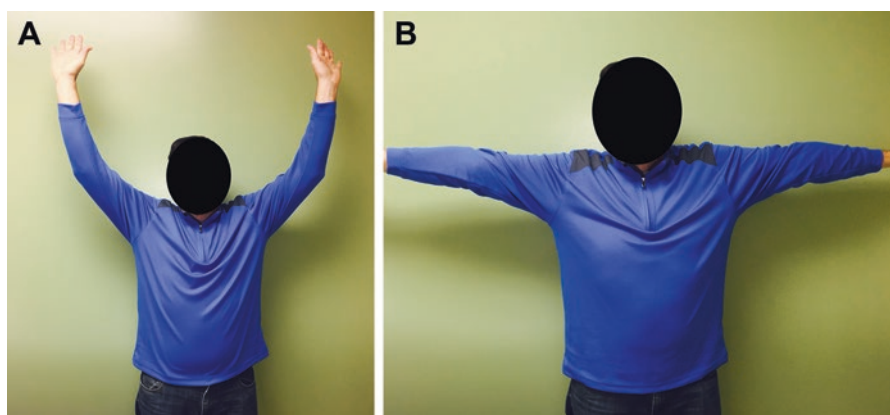


Fig. 6.5 Case 1, 8-month follow-up showing active flexion (a) and abduction (b) with symmetric range of motion

Case 2

Case 2 is a 57-year-old left hand dominant male involved in a bicycle accident when he slid on wet leaves and fell directly onto his left side. He had a loss of consciousness and multiple left-sided rib fractures and was admitted by the trauma service. He was found to have a left midshaft clavicle fracture, left scapula body fracture, and an LC1 pelvis injury. His medical history was noncontributory and he denied any tobacco use. Supine X-rays were obtained and are shown in Fig. 6.6a, b. While admitted, we had a lengthy discussion with him regarding the risks and benefits of surgical and nonsurgical management of his clavicle fracture and he elected for a trial of nonoperative management. He was placed into a sling on the day of injury with the instructions to remove it as tolerated to work on range of motion. At his 2-week follow up appointment, he was having minimal shoulder girdle pain wearing the sling. He was routinely taking the sling off at home to work on range of motion and was able to do some of his activities of daily living without the sling. Upright radiographs showed increased displacement (Fig. 6.7a, b). Treatment options were discussed again and he elected for continued nonoperative treatment of his clavicle fracture. When seen for his 6-week follow-up, his pain was controlled on occasional

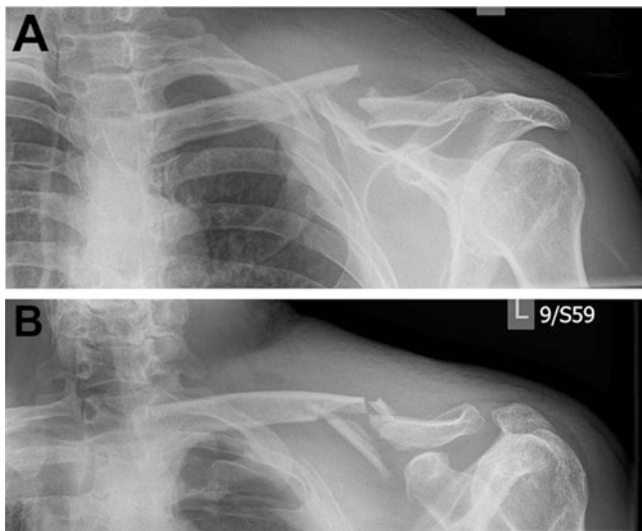


Fig. 6.6 Case 2, supine anteroposterior (a) and 45° cephalic tilt (b) radiographs of acute left clavicle fracture

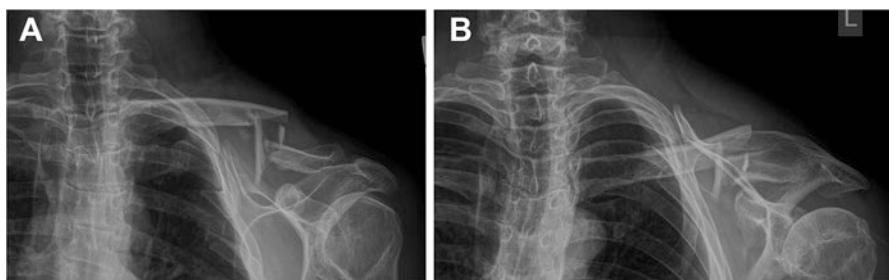


Fig. 6.7 Case 2, anteroposterior (a) and 45° cephalic tilt (b) radiographs at 2-week follow-up showing increased displacement

over the counter pain medications and he had completely weaned out of the sling by 4 weeks. He had 110° of painless forward flexion and 130° of painless shoulder abduction. At his 3-month follow-up, he had near full range of motion of the shoulder without pain and was not requiring any pain medication. There was a visible and palpable deformity of the clavicle with slight shoulder sag. Upright radiographs were obtained (Fig. 6.8a, b). At 6 months, he was cycling routinely and noticing continued improvements in left shoulder strength. The deformity of his clavicle was no longer visible but was still palpable and he had a slight shoulder droop. He was back to work as a laborer and renovating his house without much difficulty. Despite a 5°–10° loss of forward flexion and abduction, he had painless ROM without functional deficit at 8 months (Fig. 6.9a, b). He still had a slight shoulder droop with palpable clavicle deformity. Despite having obvious radiographic z-deformity and at least 1 cm of displacement (Fig. 6.10a, b), the patient was pleased with his nonsurgical outcome and had returned to baseline activity and strength with minimal loss of motion.

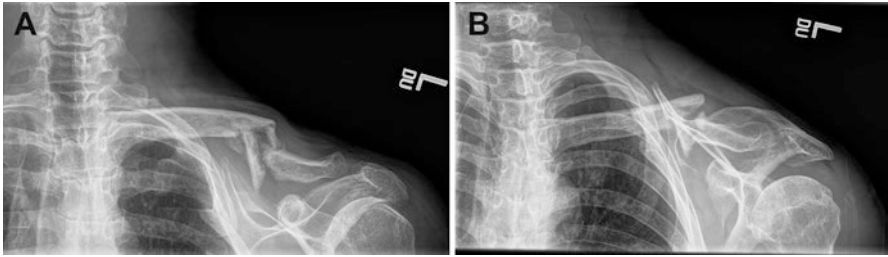


Fig. 6.8 Case 2, anteroposterior (a) and 45° Cephalic tilt (b) radiographs at 3-month follow-up showing similar displacement and callus formation

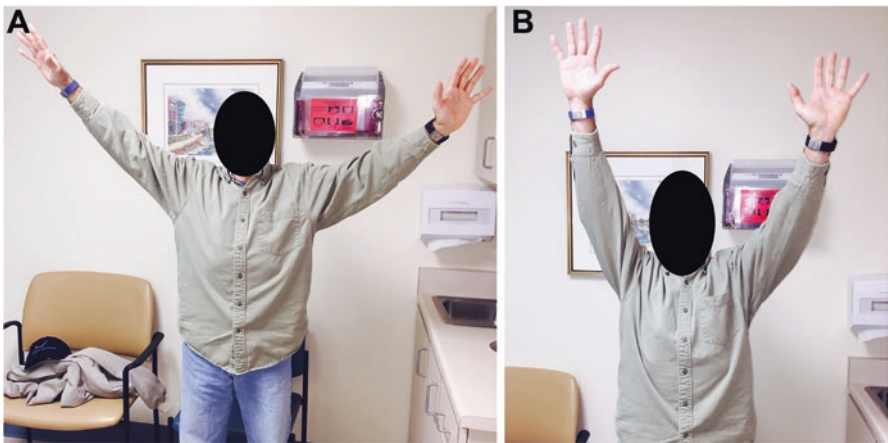

Fig. 6.9 Case 2, clinical images at 6 months showing a 10° loss of motion to forward flexion and abduction

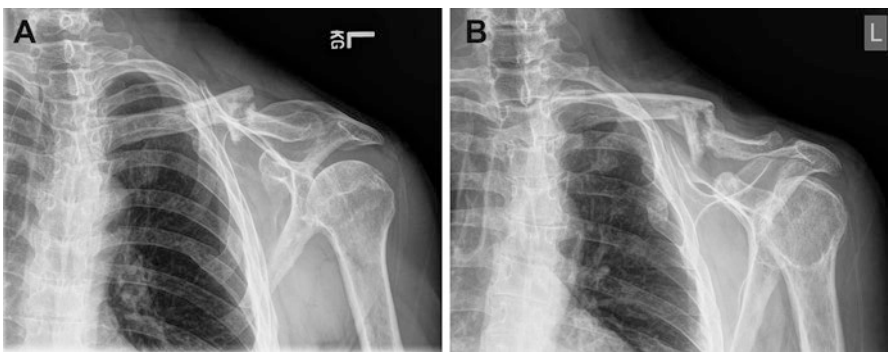


Fig. 6.10 Case 2, anteroposterior (a) and 45° cephalic tilt (b) radiographs at 6-month follow-up images showing z-deformity

References

1. Adams F. The genuine works of Hippocrates, translated from the Greek. Baltimore: Williams & Wilkins; 1939. p. 216–7.
2. Dupuytren G. On injuries and disease of bone. Selections from the collected edition of the clinical lectures of Baron Dupuytren [Internet]. 1847. p. 97–8. https://books.google.com/books?id=2XYFAAAAQAAJ&pg=PA97&source=gbs_toc_r&cad=3#v=onepage&q&f=false
3. Nordqvist A, Petersson C. The incidence of fractures of the clavicle. *Clin Orthop Relat Res*. 1994;(300):127–32.
4. Postacchini F, Gumina S, De Santis P, Albo F. Epidemiology of clavicle fractures. *J Shoulder Elb Surg*. 2002;11(5):452–6.
5. Karl JW, Olson PR, Rosenwasser MP. The epidemiology of upper extremity fractures in the United States, 2009. *J Orthop Trauma*. 2015;29(8):e242–4.
6. Robinson CM. Fractures of the clavicle in the adult. Epidemiology and classification. *J Bone Joint Surg Br*. 1998;80(3):476–84.
7. Nowak J, Mallmin H, Larsson S. The aetiology and epidemiology of clavicular fractures. A prospective study during a two-year period in Uppsala, Sweden. *Injury*. 2000;31(5):353–8.
8. Ludewig PM, Behrens SA, Meyer SM, Spoden SM, Wilson LA. Three-dimensional clavicular motion during arm elevation: reliability and descriptive data. *J Orthop Sports Phys Ther*. 2004;34(3):140–9.
9. Sahara W, Sugamoto K, Murai M, Yoshikawa H. Three-dimensional clavicular and acromioclavicular rotations during arm abduction using vertically open MRI. *J Orthop Res*. 2007;25(9):1243–9.
10. Ljunggren AE. Clavicular function. *Acta Orthop Scand*. 1979;50(3):261–8.
11. Taitzman LA, Nork SE, Coles CP, Barei DP, Agel J. Open clavicle fractures and associated injuries. *J Orthop Trauma*. 2006;20(6):396–9.
12. Jeray KJ. Acute midshaft clavicular fracture. *J Am Acad Orthop Surg*. 2007;15(4):239–48.
13. Malcolm BW, Ameli FM, Simmons EH. Pneumothorax complicating a fracture of the clavicle. *Can J Surg*. 1979;22(1):84.
14. Williams RJ. Significant pneumothorax complicating a fractured clavicle. *J Accid Emerg Med*. 1995;12(3):218–9.
15. Dugdale TW, Fulkerson JP. Pneumothorax complicating a closed fracture of the clavicle. A case report. *Clin Orthop Relat Res*. 1987;221:212–4.
16. Dath R, Nashi M, Sharma Y, Muddu BN. Pneumothorax complicating isolated clavicle fracture. *Emerg Med J*. 2004;21(3):395–6.
17. Hani R, Ennaciri B, Jeddi I, El Bardouni A, Mahfoud M, Berrada MS. Pneumothorax complicating isolated clavicle fracture. *Pan Afr Med J*. 2015;21:202.
18. Barbier O, Malgheem J, Delaere O, Vande Berg B, Rombouts JJ. Injury to the brachial plexus by a fragment of bone after fracture of the clavicle. *J Bone Joint Surg Br*. 1997;79(4):534–6.
19. Yates DW. Complications of fractures of the clavicle. *Injury*. 1976;7(3):189–93.
20. Leffert RD, Seddon H. Infraclavicular brachial plexus injuries. *J Bone Joint Surg Br*. 1965;47:9–22.
21. Howard FM, Shafer SJ. Injuries to the clavicle with neurovascular complications. A study of fourteen cases. *J Bone Joint Surg Am*. 1965;47(7):1335–46.
22. Chen DJ, Chuang DC, Wei FC. Unusual thoracic outlet syndrome secondary to fractured clavicle. *J Trauma*. 2002;52(2):393–8; discussion 398–9.
23. Kendall K, Burton J, Cushing B. Fatal subclavian artery transection from isolated clavicle fracture. *J Trauma*. 2000;48(2):316–8.
24. Natali J, Maraval M, Kieffer E, Petrovic P. Fractures of the clavicle and injuries of the subclavian artery. Report of 10 cases. *J Cardiovasc Surg (Torino)*. 1975;16(5):541–7.
25. Harris JD, Latshaw JC. Improved clinical utility in clavicle fracture decision-making with true orthogonal radiographs. *Int J Shoulder Surg*. 2012;6(4):130–4.

26. Backus JD, Merriman DJ, McAndrew CM, Gardner MJ, Ricci WM. Upright vs. supine radiographs of clavicle fractures: does positioning matter? *J Orthop Trauma*. 2014;28(22):636–41.
27. Plocher EK, Anavian J, Vang S, Cole PA. Progressive displacement of clavicular fractures in the early postinjury period. *J Trauma*. 2011;70(5):1263–7.
28. Riehl JT, Athans BJ, Munro MW, Langford JR, Kupiszewski SJ, Haidukewych GJ, et al. Minimally displaced clavicle fracture after high-energy injury: are they likely to displace? *Can J Surg*. 2014;57(3):169–74.
29. Robinson CM, Court-Brown CM, McQueen MM, Wakefield AE. Estimating the risk of nonunion following nonoperative treatment of a clavicular fracture. *J Bone Joint Surg Am*. 2004;86-A(7):1359–65.
30. Eskola A, Vainionpää S, Myllynen P, Päätiälä H, Rokkanen P. Outcome of clavicular fracture in 89 patients. *Arch Orthop Trauma Surg*. 1986;105(6):337–8.
31. Wick M, Müller EJ, Kollig E, Muhr G, Müller MWEJ, Muhr EKG. Midshaft fractures of the clavicle with a shortening of more than 2 cm predispose to nonunion. *Arch Orthop Trauma Surg*. 2001;121(4):207–11.
32. Liu W, Xiao J, Ji F, Xie Y, Hao Y. Intrinsic and extrinsic risk factors for nonunion after nonoperative treatment of midshaft clavicle fractures. *Orthop Traumatol Surg Res*. 2015;101(2):197–200.
33. Murray IR, Foster CJ, Eros A, Robinson CM. Risk factors for nonunion after nonoperative treatment of displaced midshaft fractures of the clavicle. *J Bone Joint Surg Am*. 2013;95(13):1153–8.
34. Neer CS, Rockwood CA. Fractures in adults. In: Rockwood C, Green D, editors. *Fractures in adults*. 2nd ed. Philadelphia: Lipincott; 1984. p. 711.
35. Andersen K, Jensen PO, Lauritzen J. Treatment of clavicular fractures. Figure-of-eight bandage versus a simple sling. *Acta Orthop Scand*. 1987;58(1):71–4.
36. Ersen A, Atalar AC, Birisif F, Saglam Y, Demirhan M. Comparison of simple arm sling and figure of eight clavicular bandage for midshaft clavicular fractures: a randomised controlled study. *Bone Joint J*. 2015;97(11):1562–5.
37. Zura R, Mehta S, Della Rocca GJ, Jones J, Steen RG. A cohort study of 4,190 patients treated with low-intensity pulsed ultrasound (LIPUS): findings in the elderly versus all patients. *BMC Musculoskelet Disord*. 2015;16:45.
38. Heckman JD, Ryaby JP, McCabe J, Frey JJ, Kilcoyne RF. Acceleration of tibial fracture-healing by non-invasive, low-intensity pulsed ultrasound. *J Bone Joint Surg Am*. 1994;76(1):26–34.
39. Emami A, Petrén-Mallmin M, Larsson S. No effect of low-intensity ultrasound on healing time of intramedullary fixed tibial fractures. *J Orthop Trauma*. 1999;13(4):252–7.
40. Lubbert PH, van der Rijt RH, Hoorntje LE, van der Werken C. Low-intensity pulsed ultrasound (LIPUS) in fresh clavicle fractures: a multi-centre double blind randomised controlled trial. *Injury*. 2008;39(12):1444–52.
41. Griffin XL, Smith N, Parsons N, Costa ML. Ultrasound and shockwave therapy for acute fractures in adults. *Cochrane Database Syst Rev*. 2012;2:CD008579.
42. Ebrahim S, Mollon B, Bance S, Busse JW, Bhandari M. Low-intensity pulsed ultrasonography versus electrical stimulation for fracture healing: a systematic review and network meta-analysis. *Can J Surg*. 2014;57(3):E105–18.
43. Nolte PA, van der Krans A, Patka P, Janssen IM, Ryaby JP, Albers GH. Low-intensity pulsed ultrasound in the treatment of nonunions. *J Trauma*. 2001;51(4):693–702; discussion 702–3.
44. Robinson CM, Goudie EB, Murray IR, Jenkins PJ, Ahktar MA, Read EO, et al. Open reduction and plate fixation versus nonoperative treatment for displaced midshaft clavicular fractures: a multicenter, randomized, controlled trial. *J Bone Joint Surg Am*. 2013;95(17):1576–84.
45. Walton B, Meijer K, Melancon K, Hartman M. A cost analysis of internal fixation versus nonoperative treatment in adult midshaft clavicle fractures using multiple randomized controlled trials. *J Orthop Trauma*. 2015;29(4):173–80.

46. McKee RC, Whelan DB, Schemitsch EH, McKee MD. Operative versus nonoperative care of displaced midshaft clavicular fractures: a meta-analysis of randomized clinical trials. *J Bone Joint Surg Am.* 2012;94(8):675–84.
47. Kong L, Zhang Y, Shen Y. Operative versus nonoperative treatment for displaced midshaft clavicular fractures: a meta-analysis of randomized clinical trials. *Arch Orthop Trauma Surg.* 2014;134(11):1493–500.
48. Nordqvist A, Petersson CJ, Redlund-Johnell I. Mid-clavicle fractures in adults: end result study after conservative treatment. *J Orthop Trauma.* 1998;12(8):572–6.
49. Faldini C, Nanni M, Leonetti D, Acri F, Galante C, Luciani D, et al. Nonoperative treatment of closed displaced midshaft clavicle fractures. *J Orthop Traumatol.* 2010;11(4):229–36.
50. McKee MD, Pedersen EM, Jones C, Stephen DJG, Kreder HJ, Schemitsch EH, et al. Deficits following nonoperative treatment of displaced midshaft clavicular fractures. *J Bone Joint Surg Am.* 2006;88(1):35–40.
51. Zlowodzki M, Zelle BA, Cole PA, Jeray K, McKee MD. Evidence-Based Orthopaedic Trauma Working Group. Treatment of acute midshaft clavicle fractures: systematic review of 2144 fractures: on behalf of the Evidence-Based Orthopaedic Trauma Working Group. *J Orthop Trauma.* 2005;19(7):504–7.
52. Manske DJ, Szabo RM. The operative treatment of mid-shaft clavicular non-unions. *J Bone Joint Surg Am.* 1985;67(9):1367–71.
53. Jupiter JB, Leffert RD. Non-union of the clavicle. Associated complications and surgical management. *J Bone Joint Surg Am.* 1987;69(5):753–60.
54. Karaharju E, Joukainen J, Peltonen J. Treatment of pseudarthrosis of the clavicle. *Injury.* 1982;13(5):400–3.
55. Boehme D, Curtis RJ, DeHaan JT, Kay SP, Young DC, Rockwood CA. Non-union of fractures of the mid-shaft of the clavicle. Treatment with a modified Hagie intramedullary pin and autogenous bone-grafting. *J Bone Joint Surg Am.* 1991;73(8):1219–26.
56. McKee MD, Wild LM, Schemitsch EH. Midshaft malunions of the clavicle. *J Bone Joint Surg Am.* 2003;85(5):790–7.
57. Ledger M, Leeks N, Ackland T, Wang A. Short malunions of the clavicle: an anatomic and functional study. *J Shoulder Elb Surg.* 2005;14(4):349–54.
58. Althausen PL, Shannon S, Lu M, O'Mara TJ, Bray TJ. Clinical and financial comparison of operative and nonoperative treatment of displaced clavicle fractures. *J Shoulder Elb Surg.* 2013;22(5):608–11.
59. Pearson AM, Tosteson ANA, Koval KJ, McKee MD, Cantu RV, Bell JE, et al. Is surgery for displaced, midshaft clavicle fractures in adults cost-effective? Results based on a multicenter randomized, controlled trial. *J Orthop Trauma.* 2010;24(7):426–33.

Chapter 7

Midshaft Clavicle Injuries: Operative Management

Mark A. Mighell, Jonathan Clark, and Rafael Serrano-Riera

Introduction

Clavicle fractures account for 5–10% of all fractures and almost half of all shoulder girdle injuries [1, 2]. About 80% of these fractures affect the middle third of the clavicle.

The management of clavicle fractures still remains controversial. Historically, the orthopedic literature reported high union rates with conservative measures [1–3]; however, patient satisfaction and outcome measures were not gauged. In the past decade, surgical treatment has gained increasing popularity due to McKee's work [4] and advances in surgical implants. Recent publications show no long-term differences between operative and non-operative treatment. It is still unclear whether greater patient satisfaction and function justify the increased cost and complications associated with surgery [5–7].

Operative and non-operative treatments are both supported by the current body of orthopedic literature. To this end, criteria have been proposed to help surgeons decide which patient may benefit most from surgery [8, 9]. In addition to fracture characteristics (comminution, shortening, and displacement), patient-specific factors such as demographics, baseline activity level, or employment status must be

M.A. Mighell, M.D. (✉)

Florida Orthopaedic Institute, 13020 Telecom Parkway North, Tampa, FL 33637, USA

e-mail: mmighell@floridaortho.com

J. Clark, M.D.

Shoulder and Elbow Service, Florida Orthopaedic Institute,

13020 Telecom Parkway North, Tampa, FL 33637, USA

e-mail: jonathan.clark.md@gmail.com

R. Serrano-Riera, M.D.

Orthopaedic Trauma Service, Florida Orthopaedic Institute,

13020 Telecom Parkway North, Tampa, FL 33637, USA

e-mail: rafa.serrano.riera@hotmail.com

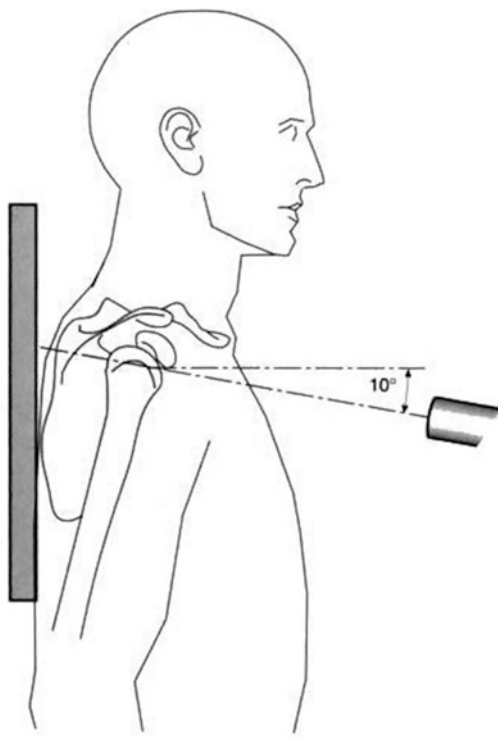
considered when discussing treatment options. For example, the outcomes and expectations from a displaced mid-shaft clavicle fracture in a 25-year-old competitive cyclist are vastly different from a similar fracture in a low demand 65-year-old.

Radiographic Assessment and Classification

Antero-posterior and 30° cephalic tilt are the standard radiographs used to evaluate injuries on the scapular girdle. Additional information can be obtained with the Zanca view (Fig. 7.1), which provides a better visualization of the Acromioclavicular (AC) joint, or Quesana view (Fig. 7.2) giving an accurate idea of the extent of displacement and shortening [10]. Upright films may be better than supine x-rays to demonstrate displacement and shortening [10]. Patients who cannot tolerate upright x-rays will have radiographs that in general, will underestimate the degree of displacement. A CT scan has limited value in the assessment of the majority of clavicle fractures with the exception of sternoclavicular injuries and fractures of the medial physis of the clavicle.

Two commonly accepted classifications for clavicle injuries are the AO/OTA, which divides clavicle fractures in three subtypes according to the location of the fracture line and the Robinson Classification which adds variables of proven diagnostic value such as comminution, displacement, or intraarticular extension (Fig. 7.3).

Fig. 7.1 Zanca view: beam directed with 10° of cephalic tilt providing excellent visualization of AC joint



Management

Mid-shaft Clavicle Fractures (AO/OTA 15-B)

This is by far the most common fracture type and where the bulk of literature focuses to find out whether the operative or non-operative treatment is most adequate.

Operative Versus Non-operative Management of Mid-shaft Clavicular Fractures

Traditionally, middle third clavicle fractures have been treated non-operatively with sling or Figure-of-Eight brace immobilization. Neer and Rowe reported acceptable results of conservatively treated mid-shaft clavicle fractures [1, 3]. Hill et al. were the first to report unsatisfactory functional results in patients who underwent non-operative treatment for displaced mid-shaft clavicle fractures [11]. The authors argued that open reduction and internal fixation (ORIF) would be the preferred treatment in these cases. In 2006, the first randomized control trial (RCT) performed on this topic by McKee [4] yielded better DASH scores and a lower nonunion rate in patients who underwent ORIF of their displaced mid-shaft clavicle fractures. The reoperation rate for the surgical group was 12%, with irritation of the implant the most common cause for reoperation. In 2007, a meta-analysis [12] by the Canadian Orthopedic Society showed that the majority of clavicle fractures managed non-operatively had normal motion and strength. In a meta-analysis of RCTs, Mckee [6] later found that operative treatment significantly reduces the incidence of nonunion and symptomatic malunion. Nevertheless, the study failed to demonstrate superior long-term outcomes of operative treatment versus non-operative care. Robinson [7] asserted that ORIF reduces the rate of nonunion. However, they reported that the improvement in functional outcomes associated with surgery appears to result from plate fixation as the mechanism of nonunion prevention (Figs. 7.4a, b and 7.5a–d).

The problem remains that 25% of patients develop a nonunion or a symptomatic malunion [12]. The goal of the surgeon is to identify these patients in the acute setting and treat them with ORIF.

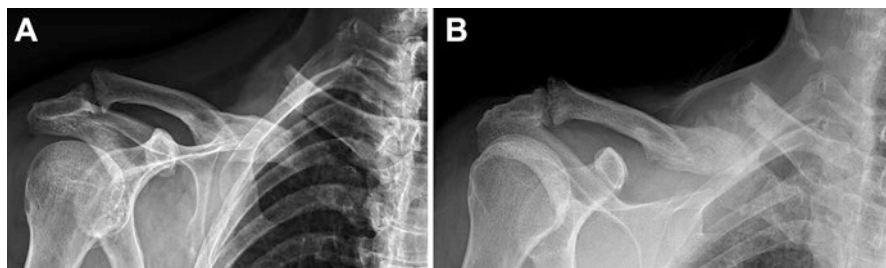

Fig. 7.4 (a) Injury film of acute displaced mid-shaft clavicle fracture. (b) Two months follow-up showing callus formation and satisfactory healing

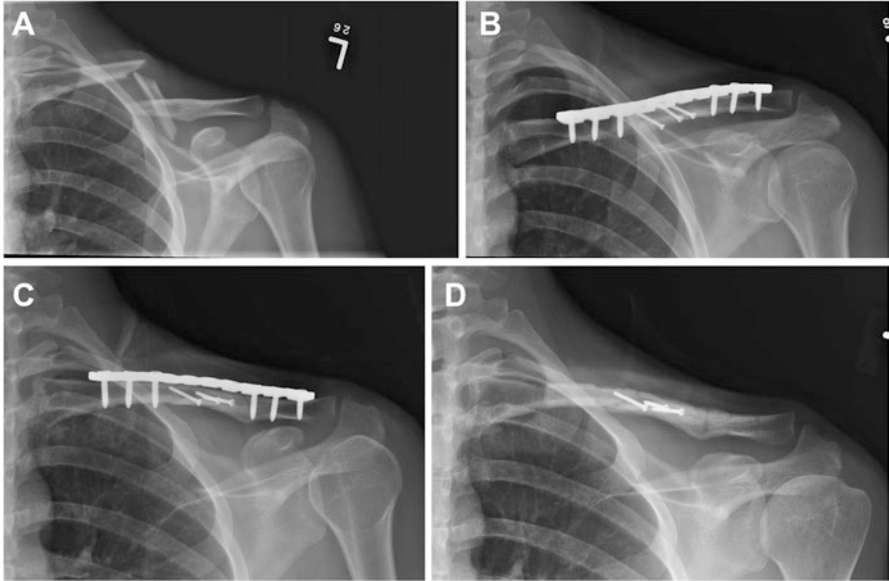


Fig. 7.5 (a) Injury film of displaced mid-shaft clavicle fracture. (b) Fixation with lag screws and neutralization plate. (c) Follow-up showing fracture healed. (d) Removal of painful hardware once fracture healed

The economics of treating these fractures is another variable that should influence our surgical decision making. In 2010, Pearson [5] published in a multicenter RCT that surgery for displaced mid-shaft clavicle fractures was not cost-effective. One major advantage of operative treatment in actively employed patients is a significantly earlier return to work, thus minimizing loss of income, and a decreased usage of pain medication [13, 14]. Conversely, Walton et al. [15] reported that in unemployed individuals, initial non-operative treatment followed by delayed operative treatment only as needed is less costly than initial operative fixation.

Fixation of clavicle fractures is an elective procedure that is technically easier to perform within 2 weeks of injury. Das et al. [16] showed that there is no difference in long-term clinical outcomes whether the fracture is fixed within 3 weeks of injury or between 3 and 12 weeks post-injury. While outcomes are no different, the procedure becomes technically more challenging due to scarring and early callus formation.

Indications for Operative Treatment

Absolute indications for surgical fixation include open or impending open fractures, and neurologic or vascular compromise. Relative indications for surgical treatment include displaced fractures, shortening of two or more centimeters, comminution, polytrauma, high level athletes, and symptomatic nonunion or malunion [8] (Table 7.1).

Table 7.1 Surgical indications for displaced mid-shaft clavicle fractures

Absolute	Relative
Open injury/impending open	>2 cm displacement
Neurologic or vascular compromise	Comminution
Floating shoulder	Cosmesis/patient discontentment
	Polytrauma
	Athletes
	Seizure disorder
	Painful nonunion or malunion

Factors Linked to Failure of Conservative Treatment

Robinson [9] and Zlowodzki et al. [17] showed that there are certain patient- and fracture-specific characteristics that when present predispose to poor outcomes in conservatively treated middle third clavicle fractures. Fracture-specific characteristics that have been shown to lead to poor outcomes include displacement, shortening greater than or equal to two centimeters, and comminution. Patient-specific characteristics associated with poor outcomes include female sex, advanced age, and use of tobacco products.

Surgical Techniques

Plating

Open reduction and internal fixation can be achieved with superior or anterior-inferior plate positioning. Newer plate technology allows for pre-contoured plates that are lower profile and allow locking fixation in selected cases.

The surgical approach for clavicle fractures is done with the patient in the supine position with the head of the bed elevated approximately 30°. Prior to the surgical incision, an image intensifier is positioned to allow for both AP and cephalic tilt views of the clavicle. A linear incision is made parallel to the clavicular shaft. Full-thickness skin and subcutaneous flaps should be raised to the level of the platysma. The platysma is divided in order to expose the fractured clavicle. When anterior-inferior plating is the preferred method, the insertions of the pectoralis major and deltoid are released subperiosteally to allow for application of the plate. The senior author prefers anterior-inferior plating when possible due to decreased incidence of soft tissue irritation and necessity of hardware removal [18].

Fracture reduction requires restoration of length, rotation, and angulation of the clavicle. The fracture ends are identified and when possible, serrated clamps are used to provisionally hold the fracture reduced. In cases in which the fracture line is transverse, a pointed tenaculum can facilitate reduction of the fracture. Fracture reduction is often maintained through the use of mini-fragment screws. This technique is ideal in oblique fractures and in those with large butterfly fragments (Fig. 7.5a–d). Commercially available pre-contoured plates fit a large portion of the population and

are lower profile, which lessens plate prominence and may reduce the chance of plate removal [19].

When open reduction with plate fixation is elected, the next decision the surgeon must make is where to place the implant. Over the past decade, anterior-inferior clavicle plating for the treatment of displaced mid-shaft fractures has become increasingly popular. Good results have been reported with both superior and anterior-inferior plating locations; however, the literature provides mixed data regarding which position makes the construction more stable [18, 20, 21]. Iannotti et al. [22] found that 3.5 mm Recon plates applied superiorly provided stiffer and more rigid constructs, but did not find any differences in load to failure between positions. A recent study from Partal and George [23] in a saw bones model reported no difference in axial or torsional stiffness, but a more stable bending stiffness for the AI plating. Favre [24] found that AI plating is less likely to fail during normal physiological loading. Additionally, AI plating is thought to decrease the risk of neurovascular damage since drilling in the anterior-inferior to posterior direction presumably keeps the screws away from the underlying neurovascular bundle. However, the current literature evaluating this theory in detail is inconclusive regarding which location is safer with regards to screw proximity to the adjacent neurovascular structures [25, 26]. Patients undergoing superior plating are more likely to complain of implant prominence and it was recently reported that the anterior-inferior plating significantly decreases the rate of secondary intervention, thus reducing the costs and risk of an additional surgery [27–29].

Intramedullary Fixation

Given the rate of implant prominence and need for subsequent hardware removal seen with plate fixation of clavicle fractures, there has been renewed interest in intramedullary fixation. Recently, two RCTs [30, 31] compared intramedullary versus plate fixation and found similar DASH scores at 1 year follow-up, comparable time to union, and similar complication rates. However, intramedullary devices (cannulated screws, flexible nails, and clavicle specific pins) have been shown to be biomechanically inferior to plates, especially with increasing comminution [32]. When compared to non-operative treatment, intramedullary fixation yields higher union rates and DASH scores. Nonetheless, the rate of medial protrusion of the nail has been reported to be as high as 18% [33, 34]. The use of small diameter smooth pins is contraindicated due to the potential for pin migration.

Distal Third (AO/OTA 15-C)

Fractures of the lateral third account for 10–15% of clavicle fractures. Neer classified them in three types. Type I, occurs lateral to the coracoclavicular (CC) ligaments. The mainstay of treatment in this group is conservative. Type II fractures are divided in two subsets. Type IIA with the fracture line medial to intact CC ligaments

and, Type IIB with the fracture occurring either between a ruptured conoid and intact trapezoid, or lateral to both ligaments torn. Type II fractures have an inherent high rate of nonunion (22–42%) when treated with closed methods [35–39] due to distraction of the proximal fragment by the muscle attachments. Therefore, a more aggressive approach is recommended. The use of a superior locked plate with reconstruction of the CC ligaments in the acute setting results in a high fracture union with a low rate of complications [40]. Hook plate fixation [41] is a valid alternative, but often requires reoperation for implant removal due to irritation of the subacromial bursa and superior rotator cuff. Surgical intervention may be deferred in low demand patients as many of these patients will go on to develop asymptomatic nonunion [36–39]. Type III corresponds to intra-articular fractures of the AC joint with stable CC ligaments. As the ligamentous structures remain intact, nonoperative treatment is preferred.

Type IV and V were subsequently added to the classification. Type IV are physeal fractures that occur in immature patients where the periosteal sleeve is disrupted. Nonoperative treatment in these cases is recommended. Type V are comminuted fractures where the CC ligaments remain attached to the comminuted fragments and the medial clavicle is unstable. Operative treatment in this situation is indicated due to an increased risk of symptomatic non-union.

Medial Third (AO/OTA 15-A)

Medial clavicular fractures are the least common subset, and because of this there is a scarcity of literature on this subject. Most of these injuries are managed non-operatively unless there is posterior displacement with actual or potential compromise of the airway and great vessels. The medial clavicular physis is among the last to close during maturation and medial physeal fractures can occur in patients into their early to mid-20s. These fractures can be treated in a similar manner to sternoclavicular dislocations as posteriorly displaced fractures often require urgent reduction with thoracic surgeons immediately available due to the potential for injury to vital intrathoracic structures.

Malunion and Symptomatic Nonunion

Factors associated with nonunion that can predict its development include: female gender, advanced age, smoking, no cortical contact between fragments, shortening greater than 2 cm, comminution, and refracture [8, 11, 42–44].

Malunion and/or symptomatic nonunion of a clavicle fracture have adverse effects on functional result [44]. The goal is to restore clavicular length and anatomy. This may require an osteotomy as well as possible tricortical interposition graft. Lag screws should be used if possible to allow for compression across the fracture nonunion site (Fig. 7.6a–c).

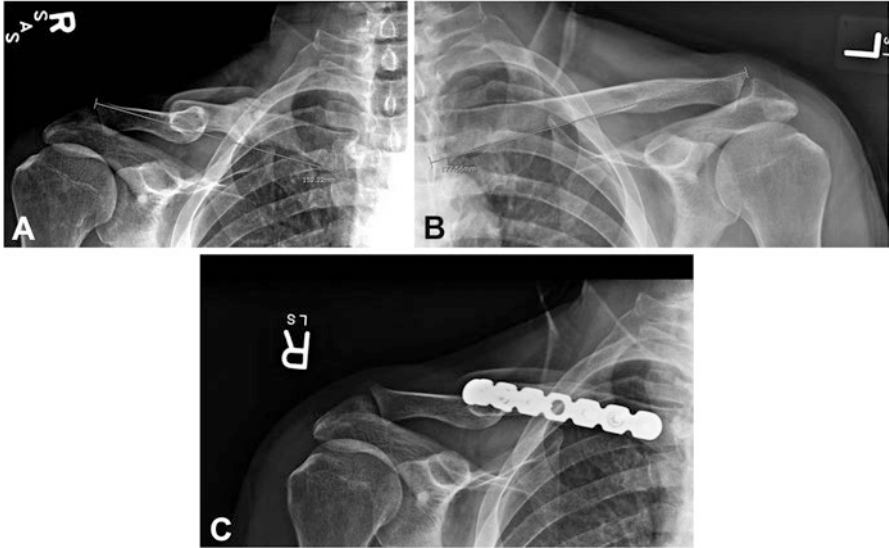


Fig. 7.6 (a) Symptomatic clavicle malunion. (b) Measurements on the contralateral side to restore length. (c) Osteotomy with interpositional graft and plating fixation

The clavicular length is evaluated preferably on a computed tomography of both clavicles or at a minimum on anteroposterior and oblique radiographs of both clavicles. If there is greater than 2 cm of shortening, then an osteotomy with interposition bone grafting should be considered to restore the appropriate length.

Plate fixation of clavicle nonunions and malunions provides high union rates and improvement in shoulder function. Both plates and nails have been used successfully [45–47]. Plates are the superior method due to higher torsional rigidity. The improvement is almost comparable to acute fixation of displaced fractures [48].

Summary

Fracture non-union is higher than historically reported. Despite that, non-operative treatment yields good results in 75% of patients. Surgery basically eradicates the occurrence of both nonunions and malunions. Operative treatment should be offered to active patients who desire an earlier return to work, patients with an absolute indication for surgery, or those with high risk for nonunion. In the case of surgery, anterior-inferior plating results in fewer secondary interventions. In the low demand patient, conservative treatment is ideal since there is no difference in the long-term outcomes when compared to operative treatment. Nonunion and malunion repair is successful at achieving healing.

References

1. Neer CS. Fractures of the clavicle. In: Rockwood and green's fractures in adults. 1st ed. Philadelphia: Lippincott-Raven; 1984. p. 686–91.
2. Nordqvist A, Petersson C. The incidence of fractures of the clavicle. *Clin Orthop Relat Res.* 1994;(300):127–32.
3. Rowe CR. An atlas of anatomy and treatment of midclavicular fractures. *Clin Orthop Relat Res.* 1968;58:29–42.
4. McKee MD, et al. Deficits following nonoperative treatment of displaced midshaft clavicular fractures. *J Bone Joint Surg Am.* 2006;88-A:35–40.
5. Pearson AM. Is surgery for displaced, midshaft clavicle fractures in adults cost-effective? Results based on a multicenter randomized, controlled trial. *J Orthop Trauma.* 2010;24(7):426–33.
6. McKee RC. Operative versus nonoperative care of displaced midshaft clavicular fractures: a meta-analysis of randomized clinical trials. *J Bone Joint Surg Am.* 2012;94(8):675–84.
7. Robinson CM. Open reduction and plate fixation versus nonoperative treatment for displaced midshaft clavicular fractures: a multicenter, randomized, controlled trial. *J Bone Joint Surg Am.* 2013;95(17):1576–84.
8. Wick M, Muller EJ, Kollig E, Muhr G. Midshaft fractures of the clavicle with a shortening of more than 2 cm predispose to nonunion. *Arch Orthop Trauma Surg.* 2001;121(4):207–11.
9. Robinson CM. Estimating the risk of nonunion following nonoperative treatment of a clavicular fracture. *J Bone Joint Surg Am.* 2004;86-A(7):1359–65.
10. Backus JD. Upright versus supine radiographs of clavicle fractures: does positioning matter? *J Orthop Trauma.* 2014;28:636–41.
11. Hill JM, McGuire MH, Crosby LA. Closed treatment of displaced middle-third fractures of the clavicle gives poor results. *J Bone Joint Surg Br.* 1997;79(4):537–9.
12. Canadian Orthopaedic Trauma Society. Nonoperative treatment compared with plate fixation of displaced midshaft clavicular fractures. A multicenter, randomized clinical trial. *J Bone Joint Surg Am.* 2007;89A:1–10.
13. Althausen PL. Clinical and financial comparison of operative and nonoperative treatment of displaced clavicle fractures. *J Shoulder Elb Surg.* 2013;22(5):608–11.
14. Melean PA, Zuniga A, Marsalli M, Fritis NA, Cook ER, Zilleruelo M, Alvarez C. Surgical treatment of displaced middle-third clavicular fractures: a prospective, randomized trial in a working compensation population. *J Shoulder Elb Surg.* 2015;24(4):587–92.
15. Walton B, et al. A cost analysis of internal fixation versus nonoperative treatment in adult midshaft clavicle fractures using multiple randomized controlled trials. *J Orthop Trauma.* 2015;29(4):173–80.
16. Das A, et al. Early versus delayed operative intervention in displaced clavicle fractures. *J Orthop Trauma.* 2014;28(3):119–23.
17. Zlowodzki M, Zelle BA, Cole PA, Jeray K, McKee MD. Treatment of acute midshaft clavicle fractures: systematic review of 2144 fractures: on behalf of the Evidence-Based Orthopaedic Trauma Working Group. *J Orthop Trauma.* 2005;19(7):504–7.
18. Collinge C, Devinney S, Herscovici D, DiPasquale T, Sanders R. Anterior-inferior plate fixation of middle-third fractures and nonunions of the clavicle. *J Orthop Trauma.* 2006;20(10):680–6.
19. VanBeek C. Precontoured plating of clavicle fractures: decreased hardware-related complications? *Clin Orthop Relat Res.* 2011;469(12):3337–43.
20. Kloen P. Anteroinferior plating of midshaft clavicular nonunions. *J Orthop Trauma.* 2002;16(6):425–30.
21. Jones CB. Results of anterior-inferior 2.7-mm dynamic compression plate fixation of midshaft clavicular fractures. *J Orthop Trauma.* 2013;27(3):126–9.
22. Iannotti MR, et al. Effects of plate location and selection on the stability of midshaft clavicle osteotomies: a biomechanical study. *J Shoulder Elb Surg.* 2002;11:457–62.

23. Partal G. Superior versus anteroinferior plating of the clavicle revisited: a mechanical study. *J Orthop Trauma*. 2010;24(7):420–5.
24. Favre P. Superior versus anteroinferior plating of the clavicle: a finite element study. *J Orthop Trauma*. 2011;25(11):661–5.
25. Werner SD. Anatomic relationships after instrumentation of the midshaft clavicle with 3.5-mm reconstruction plating: an anatomic study. *J Orthop Trauma*. 2011;25:657–60.
26. Sinha A. A radiological study to define safe zones for drilling during plating of clavicle fractures. *J Bone Joint Surg Br*. 2011;93:1247–52.
27. Formaini N. Superior versus anteroinferior plating of clavicle fractures. *Orthopedics*. 2013;36(7):e898–904.
28. Stufkens SA. Treatment of midshaft clavicular delayed and non-unions with anteroinferior locking compression plating. *Arch Orthop Trauma Surg*. 2010;130(2):159–64.
29. Serrano-Riera R. Anterior-inferior plating results in fewer secondary interventions compared to superior plating for acute displaced mid-shaft clavicle fractures. In: *Orthopedic Trauma Association Annual Meeting San Diego*; 2015.
30. Van der Meijden OA, et al. Operative treatment of dislocated midshaft clavicular fractures: plate or intramedullary nail fixation? A randomized controlled trial. *J Bone Joint Surg Am*. 2015;97(8):613–9. doi:10.2106/JBJS.N.00449.
31. Andrade-Silva FB, et al. Single, superiorly placed reconstruction plate compared with flexible intramedullary nailing for midshaft clavicular fractures: a prospective, randomized controlled trial. *J Bone Joint Surg Am*. 2015;97(8):620–6.
32. Golish SR, Oliviero JA, Francke EI, Miller MD. A biomechanical study of plate versus intramedullary devices for midshaft clavicle fixation. *J Orthop Surg Res*. 2008;3:28.
33. Smekal V. Elastic stable intramedullary nailing versus nonoperative treatment of displaced midshaft clavicular fractures—a randomized, controlled, clinical trial. *J Orthop Trauma*. 2009;23(2):106–12.
34. Mueller M, et al. Minimally Invasive Intramedullary Nailing of Midshaft Clavicular Fractures Using Titanium Elastic Nails. *J Trauma*. 2008;64:1528–34.
35. Neer II CS. Fracture of the distal clavicle with detachment of the coracoclavicular ligaments in adults. *J Trauma*. 1963;3:99–110.
36. Rokito AS, Zuckerman JD. A comparison of nonoperative and operative treatment of type II distal clavicle fractures. *Bull Hosp Jt Dis*. 2002–2003;61(1–2):32–9.
37. Robinson CM, Cairns DA. Primary nonoperative treatment of displaced lateral fractures of the clavicle. *J Bone Joint Surg Am*. 2004;86-A(4):778–82.
38. Nordqvist A, Petersson C, Redlund-Johnell II. The natural course of lateral clavicle fracture. 15 (11–21) year follow-up of 110 cases. *Acta Orthop Scand*. 1993;64(1):87–91.
39. Deafenbaugh MK, Dugdale TW, Staeheli JW, Nielsen R. Nonoperative treatment of Neer type II distal clavicle fractures: a prospective study. *Contemp Orthop*. 1990;20(4):405–13.
40. Klein SM, Mighell MA. Results of surgical treatment for unstable distal clavicular fractures. *J Shoulder Elb Surg*. 2010;19(7):1049–55. doi:10.1016/j.jse.2009.11.056. Epub 24 Mar 2010.
41. Meda PV, Machani B, Sinopidis C, et al. Clavicular hook plate for lateral end fractures: a prospective study. *Injury*. 2006;37(3):277–83.
42. McKee MD, Wild LM, Schemitsch EH. Midshaft malunions of the clavicle. *J Bone Joint Surg Am*. 2003;85-A(5):790–7.
43. Nowak J, Hølgerrsson M, Larsson S. Can we predict long-term sequelae after fractures of the clavicle based on initial findings? A prospective study with nine to ten years of follow-up. *J Shoulder Elb Surg/Am Shoulder Elb Surg ... [et al]*. 2004;13(5):479–86.
44. Ristevski B, Hall JA, Pearce D, Potter J, Farrugia M, McKee MD. The radiographic quantification of scapular malalignment after malunion of displaced clavicular shaft fractures. *J Shoulder Elb Surg/Am Shoulder Elb Surg ... [et al]*. 2013;22(2):240–6.
45. Smekal V, Deml C, Kamelger F, Dallapozza C, Krappinger D. Corrective osteotomy in symptomatic midshaft clavicular malunion using elastic stable intramedullary nails. *Arch Orthop Trauma Surg*. 2010;130(5):681–5.

46. Hillen RJ, Eygendaal D. Corrective osteotomy after malunion of mid shaft fractures of the clavicle. *Strategies Trauma Limb Reconstr.* 2007;2(2-3):59-61.
47. McKee MD, Wild LM, Schemitsch EH. Midshaft malunions of the clavicle. Surgical technique. *J Bone Joint Surg Am.* 2004;86-A(Suppl 1):37-43.
48. Potter JM, Jones C, Wild LM, Schemitsch EH, McKee MD. Does delay matter? The restoration of objectively measured shoulder strength and patient-oriented outcome after immediate fixation versus delayed reconstruction of displaced midshaft fractures of the clavicle. *J Shoulder Elb Surg.* 2007;16(5):514-8.

Chapter 8

Acromioclavicular Joint Injuries

Kyle P. Lavery, Stephen D. Daniels, and Laurence D. Higgins

Introduction

Acromioclavicular (AC) joint injuries are common in the athletic population, particularly in those who participate in contact sports. A thorough history, physical examination, and imaging evaluation are critical to establish the correct diagnosis, guide treatment, and ensure optimal outcomes. The paradigm for managing complete AC separations has dramatically shifted over time and continues to evolve with new evidence and improved surgical techniques. In this chapter, we review of the pathoanatomy, workup, and treatment of AC joint injuries.

Epidemiology

Acromioclavicular joint injuries are thought to be the most common traumatic athletic injuries to the shoulder girdle. However, due to variations in activity levels among populations and the likely under-reporting of low-grade sprains, their true incidence cannot be accurately calculated. Acromioclavicular injuries frequently present in contact athletes, particularly in those who play collision sports such as football, rugby, hockey, and wrestling [1]. In a study of elite rugby players, 45% reported a personal history of AC injury [2].

K.P. Lavery, M.D.

Division of Sports Medicine, Department of Orthopaedic Surgery,
Massachusetts General Hospital, 175 Cambridge Street, Suite 400, Boston, MA 02114, USA
e-mail: kplavery16@gmail.com

S.D. Daniels, B.S. • L.D. Higgins, M.D., M.B.A. (✉)

Division of Sports Medicine, Department of Orthopedic Surgery,
Brigham and Women's Hospital, 75 Francis Street, Boston, MA 02115, USA
e-mail: sddaniels@partners.org; ldhiggins@partners.org

Utilizing the NFL Injury Surveillance System (NFLISS), Lynch et al. presented the most complete and comprehensive series of AC injuries in professional football players [3]. Data collected over 12 consecutive seasons documented that AC injuries accounted for 29.2% of shoulder injuries. While defensive backs (16.1%) and wide receivers (15.7%) sustained the greatest total number, quarterbacks and special team players had a higher incidence of injuries and exposure risk based on number of players and time spent on the field. Dragoo et al. reported similar data utilizing the NCAA Injury Surveillance System (NCAAISS) [4]. Acromioclavicular injuries constituted 4.5% of all musculoskeletal and 32% of shoulder injuries over five seasons. Over 96% of these injuries represented sprains (vs. complete dislocations).

Pallis et al. published a comprehensive study of AC injuries in physically active cadets at the U.S. Military Academy over a 4 year period [1]. Eighty-nine percent were low-grade sprains, with the highest incidence rates in rugby in both sexes. Overall, males had over twice the risk of sustaining an AC injury compared to females with an equal amount of exposures. This increased to over a threefold risk with higher-level intercollegiate athletic competition.

Mechanism of Injury

Acromioclavicular joint injuries are commonly caused by either a direct, or far less frequently, an indirect mechanism. Direct mechanisms generally result from a blow to the lateral shoulder and acromion with the arm in an adducted position. In athletic competition, contact can occur with another player or the playing surface. In a large cohort of NCAA football players sustaining AC injuries, 72% of these were sustained during contact with another player [4]. Indirect forces to the shoulder girdle generally result when a force is applied through the arm during a fall, causing the proximal humerus to be driven superiorly into the acromion (Fig. 8.1).

Fig. 8.1 Indirect mechanism of an AC separation. A force is applied through the arm during a fall, causing the proximal humerus to be driven superiorly into the acromion

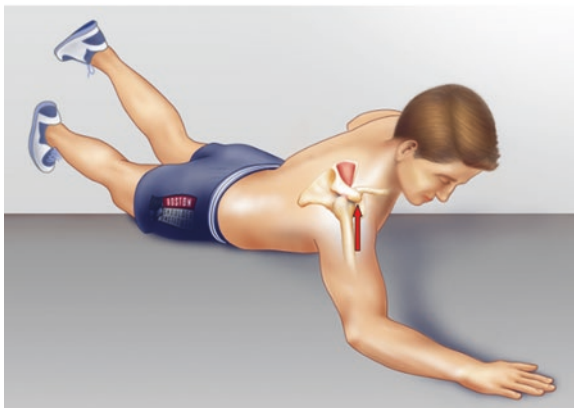
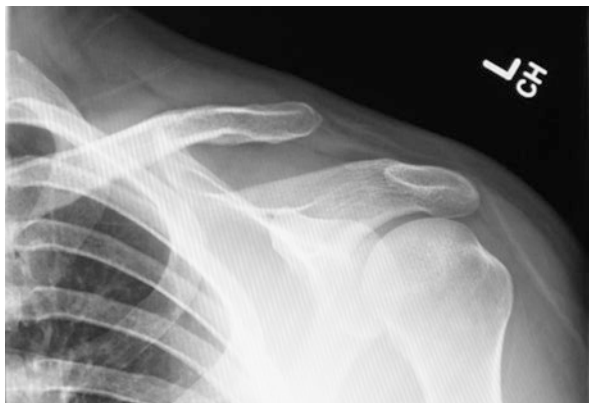

Fig. 8.2 AP radiograph of iatrogenic AC instability caused by an over-aggressive distal clavicle resection



Iatrogenic causes are an increasingly recognized etiology of AC joint instability [5]. This is generally a sequelae of an overly aggressive resection during a distal clavicle excision (Fig. 8.2). Over-resection can destabilize the AC capsule and ligaments, leading to horizontal instability [6]. If severe, the coracoclavicular (CC) ligaments can be violated, resulting in vertical instability. As a result, surgeons are trending toward resecting less distal clavicle for degenerative conditions than the originally recommended 10 mm. A cadaveric biomechanical study has supported this practice, confirming as little as 5 mm of resection prevented articular contact [7].

Pathoanatomy

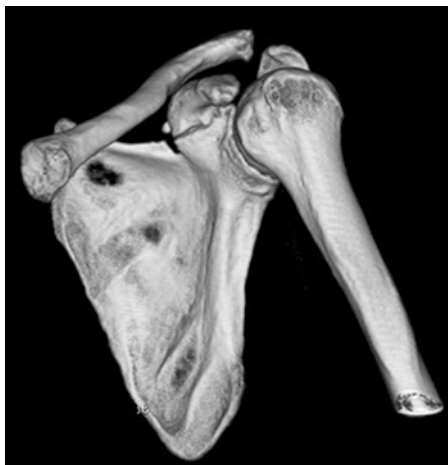Although the distal clavicle is generally described as displaced in an AC separation, it is truly downward displacement of the scapula and upper extremity, as the clavicle remains stabilized by its rigid attachments to the axial skeleton at the sternoclavicular joint. As an increasing force is applied, there is systematic failure of the joint's stabilizing structures, beginning with the AC capsule and ligaments. This is followed by failure of the CC ligaments (trapezoid and conoid) and, finally, deltotrapezial fascia. A coracoid fracture is a relatively rare, but well reported injury variant [8–17] (Fig. 8.3).

The force vector applied to the acromion determines direction of displacement. Most commonly, an inferior force is applied to the acromion, resulting in a relative superior displacement of the distal clavicle. Although less common, posterior [18, 19], inferior [20–24], and anterior [25, 26] variants have also been described.

Associated Injuries

Long overlooked, associated intraarticular glenohumeral injuries are increasingly recognized with AC injuries, largely due to the development of arthroscopic-assisted reconstruction techniques. Tischer et al. reported a series of 77 patients

Fig. 8.3 3-D reconstructions demonstrating a coracoid fracture associated with an AC separation



with complete AC separations of various types treated surgically [27]. At the time of diagnostic arthroscopy, 18.2% were found to have concomitant intraarticular pathology. Superior labral tears were found in 14.3% of these shoulders, while 3.9% had rotator cuff tears, with the majority of lesions occurring with more severe separations. Subsequent authors have reported even higher rates. In a series of 98 reconstructions, Arrigoni et al. found 42.8% to have associated pathology; 29.5% of these patients required additional surgical intervention [28]. Superior labrum and rotator cuff tears were the most prevalent concomitant injuries and seen more frequently in older patients. Similarly, Pauly et al. reported a rate of 30.4% in a series of 125 patients with Rockwood type III and V injuries [29]. Although it is impossible to definitively determine acuity, identification and treatment of associated intraarticular pathology may improve results in AC injuries. It is also difficult to estimate incidence of pathology in low-grade (Rockwood I & II) AC separations, as these are generally treated conservatively and do not undergo diagnostic arthroscopy.

While the identification of simultaneous intra-articular injuries may be a new phenomenon, injuries to the remainder of the shoulder girdle and suspensory mechanism have long been recognized. Despite their rarity, associated clavicle fractures are reported in several studies [30–37]. Sternoclavicular injuries, resulting in a “floating clavicle” or “bipolar” clavicle injury, are more infrequent [38, 39]. Finally, the orthopedic trauma surgeon must always be attentive to the possibility of an AC separation as the presentation of a high energy and limb threatening scapulothoracic dissociation [40].

While true open injuries to the AC joint are rare, superficial abrasions are common. Likewise, associated neurovascular injuries to the brachial plexus are not expected, but have been reported [41, 42].

Classification

Tossy is credited with developing the first classification system for AC injuries in 1966, describing three grades of increasing severity [43]. Rockwood later expanded this classification to include six injury types based purely on radiographs; his system remains the most widely accepted and utilized today (Fig. 8.4).

According to the Rockwood system, a type I injury represents a simple AC ligament sprain. A type II injury signifies an AC ligament tear. The CC ligaments are sprained, but intact, and up to a 50% vertical relative displacement of the distal clavicle may be seen. In a type III injury, there is complete separation and CC ligament disruption with 100% superior displacement of the clavicle. A type IV injury is defined by posterior displacement into the trapezius muscle. A type V injury is essentially an extreme variation of a type III injury, with 100–300% displacement and extensive soft tissue disruption and detachment of the deltotrachezial fascial attachments. Finally, in the rare type VI variant, the clavicle is dislocated inferiorly into a subacromial or subcoracoid position.

Although nearly universally utilized, the accuracy and reproducibility of the Rockwood classification system has recently come under question. The International Society of Arthroscopy, Knee Surgery, and Orthopaedic Sports Medicine (ISAKOS) has suggested an expansion of the current Rockwood classification to account for stable (IIIa) and unstable (IIIb) complete injuries [44]. The consistent classification of AC joint injuries by surgeons has been shown to be variable in the literature.

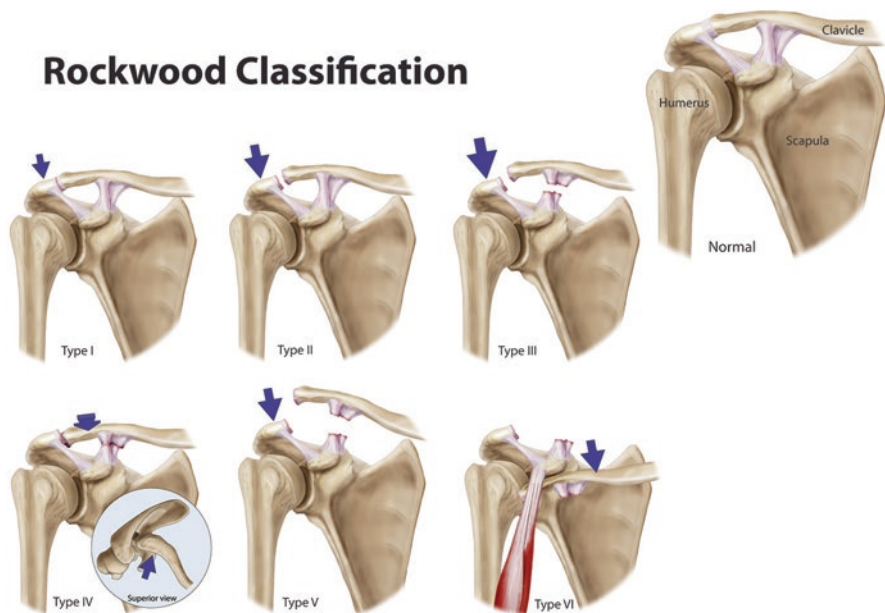


Fig. 8.4 Rockwood classification of acromioclavicular separations

While Schneider et al. reported excellent reliability, Cho et al. demonstrated a lack of interobserver and intraobserver agreement in the classification of these injuries using plain radiographs amongst experienced shoulder surgeons [45, 46]. In several studies, magnetic resonance imaging did not consistently demonstrate ligament injuries corresponding to the predicted soft tissue injury patterns described in the scheme [47, 48].

Physical Examination

Physical findings are related to the severity and acuity of the injury pattern. The patient should be examined upright, to avoid accentuation of the deformity by gravity. In acute injuries, the physical examination is generally limited due to patient discomfort. Pain, swelling, ecchymosis, and localized tenderness are reliably present at the AC joint. In complete separations, a clinical deformity and prominent distal clavicle are apparent. The remainder of the shoulder girdle should be examined, focusing on the ipsilateral clavicle and sternoclavicular joint. Although uncommonly compromised, a thorough neurovascular examination of the distal extremity should be conducted for completeness.

In chronic injuries, a comprehensive examination of the shoulder should be performed, including range of motion and rotator cuff strength testing. Range of motion should be observed from behind to assess for abnormal scapulothoracic motion, or “scapular dyskinesis”, as an abnormal clavicular strut complex may alter scapular mechanics [49, 50]. Although tenderness at the AC joint is generally present in symptomatic cases, the diagnosis can be ambiguous. A cross-chest adduction maneuver may produce pain, while an injection of local anesthetic can confirm symptoms localized to the AC joint. Clinical instability and mobility of the distal clavicle in the horizontal and vertical plane should be assessed.

Imaging

Orthogonal plain radiographs remain the initial imaging modality of choice due to availability, cost, and information provided. Bilateral dedicated anteroposterior (AP) views of the AC joint should be obtained to evaluate the symmetry of the articulation and CC interspace. The Zanca view, an AP variant with 10°–15° cephalic tilt and 50% penetration, can enhance visualization [51]. Weighted stress views, once used commonly to distinguish partial from complete injuries, have become less popular [52].

Although an axillary lateral view is considered critical for horizontal instability, recent studies have questioned their reliability in diagnosing type IV separations [53, 54]. Standard axillary views may falsely suggest posterior displacement of the distal clavicle in normal shoulders or miss type VI separations due to a lack of standardization of imaging techniques. Dynamic lateral radiographs have been proposed to increase the effectiveness of evaluating horizontal instability [55].

Advanced imaging has been suggested to better characterize and guide treatment of AC injuries. Techniques for computed tomography (CT), magnetic resonance imaging (MRI), and dynamic ultrasound (US) have all been described [56–59]. While it may be helpful in isolated cases, advanced imaging has not proven beneficial or cost-effective in improving the reliability of diagnosis, classification, or treatment [45].

Nonsurgical Treatment

Indications

Nonsurgical treatment is almost always recommended for management of incomplete (Rockwood type I and II) injuries. Although there has been much controversy regarding the treatment of type III separations, we recommend initial nonsurgical management in the majority of acute cases due to a lack of definitive high-level evidence supporting acute reconstruction [60–63].

Techniques

Historically, multiple external methods for attempted clavicle reduction and immobilization were described [64–68]. These straps, harnesses, compressive dressings, splints, and casts have been abandoned due to patient discomfort and lack of efficacy.

Today, a generally accepted protocol begins with a period of immobilization in a sling for pain control with adjunctive oral analgesics and ice. This typically lasts for 5–7 days for type I and II injuries, but can be necessary for several weeks with complete separations. As discomfort subsides, early self directed range of motion is initiated with participation in activities of daily living. Formal physical therapy, particularly aquatherapy, can be helpful in achieving full motion and can guide strengthening and training for sports-specific activities. Return to play is variable depending on the severity of injury, ranging from 1 to 2 weeks for low grade sprains to 3–4 months for complete separations. Pregame anesthetic injection can be considered for earlier return to play in elite collegiate and professional contact athletes.

Results

Results after the nonoperative treatment of incomplete (type I and II) injuries are generally described as excellent. Both recreational and high-level athletes commonly return to their desired activities in a timely fashion. In a large cohort of NFL players, a mean of only 9.8 days of participation were lost due to AC injuries. Surgical intervention occurred in only 1.7% over a 12 year period [3]. Similarly, a mean of 11.6 days were lost in NCAA football players [4].

While outcomes of low-grade AC sprains are anecdotally excellent, a number of series do acknowledge residual symptoms from these seemingly benign injuries. Shaw et al. reported significant pain in 40% of patients 6 months post-injury, although this decreased to 14% at final follow-up [69]. In another series of 37 consecutive patients treated nonoperatively for type I and II injuries, 27% required surgical intervention at a mean of 26 months after injury for residual symptoms of pain and instability [70]. At 10-year follow-up of AC sprains, Mikek reported a 52% incidence of at least occasional persistent symptoms [71].

Likewise, excellent results are generally reported with nonoperative treatment of type III complete injuries with good maintenance of shoulder strength and function [72, 73]. While there have been several movements over the last half century advocating for acute surgical management of type III separations, definitive data to support improved clinical results with operative treatment are lacking. Direct comparison studies consistently fail to show a benefit to surgical intervention [74–84]. In 2011, the Cochrane Collaboration published a detailed review examining the surgical vs. nonsurgical controversy surrounding complete separations [60]. Only three randomized trials met their inclusion criteria [74, 83, 77, 85]. Collectively, surgical treatment failed to result in significant gains in comparative shoulder function, and had higher complication rates and longer return to work times. While authors reported insufficient high-level evidence to advocate surgical treatment, they acknowledged small sample sizes and lack of validated outcomes measures in the studies included in their analysis. More recently, Beitzel et al. conducted a systematic review of studies comparing operative with nonoperative management. When data from 14 studies were pooled, a favorable clinical outcome was reported in 88% and 85.5% of surgically and nonsurgically managed patients, respectively [61] (Table 8.1).

Table 8.1 Summary of outcomes of nonoperatively vs. operatively treated type III AC separations

Study	Favorable outcome/Mean outcome score	
	Operative	Nonoperative
Rosenorn and Pedersen [79]	45%	54%
Galpin et al. [177]	75%	71%
Jacobs et al. [80]	86%	88%
Calvo et al. [81]	97%	82%
MacDonald et al. [82]	2.5/4.0	2.2/4.0
Larsen et al. [74]	97%	98%
Taft et al. [75]	94%	91%
Gstettner et al. [101]	88%	59%
Walsh et al. [178]	2.8/4.0	3.1/4.0
Bakalim and Wilppula [179]	74%	59%
Bannister et al. [83]	85%	100%
Larsen and Hede [180]	100%	96%
Press et al. [84]	17/20	15.4/20
Cardone et al. [85]	66%	50%

Adapted from Beitzel, K., et al., *Current concepts in the treatment of acromioclavicular joint dislocations*. *Arthroscopy*, 2013. **29**(2): p. 387–97 [61]

Recently, it has been proposed that unreduced, complete AC separations may impair the normally coupled scapuloacromioclavicular mechanics due to the loss of a stable shoulder fulcrum, resulting in scapular dyskinesis and pain. Gumina et al. analyzed scapular motion in 34 patients with chronic type III separations and found abnormal scapulothoracic motion in over 70%, with associated decreases in Constant scores [50]. Associated scapular dyskinesis has subsequently been shown to be responsive to a focused physiotherapy program [86].

Surgical Treatment

Indications

Consensus for acute surgical management of Rockwood type IV, V, and VI separations exists despite limited high-level evidence supporting these recommendations [83]. It is generally felt that a large degree of displacement and extensive soft tissue disruption will lead to long-term pain and disruption if left unreduced. Treatment of type III separations have long been considered controversial despite a lack of clear evidence supporting acute surgical management [60–63]. Many surgeons consider operative intervention for cases that are symptomatic after 4–6 weeks of physiotherapy, although there are no clearly defined protocols. Many techniques to obtain and maintain anatomic reduction have been described, with a recent review citing 151 techniques for operative reduction of the AC joint [61]. This number demonstrates the lack of agreement for the superiority of a single method.

Primary Acromioclavicular Fixation

Primary AC fixation is generally reserved for acute cases (<3 weeks) in which the injured ligamentous structures are believed to have healing potential. Screws and pins have largely been replaced with plating techniques.

Historically, primary fixation was achieved with Kirschner wires, Steinman pins, or screws. Percutaneous and open techniques have been described [87–92]. This practice has essentially been abandoned in modern practice due to hardware problems, including breakage and migration to organs and vessels in the chest cavity [93, 94].

The hook plate is an alternative method for AC fixation commonly used in Europe [95–97]. A lateral projection off the plate is inserted deep to the acromion with bicortical screw fixation in the clavicle, producing stiff construct to allow for ligament healing [98]. Staged plate removal is often required due to concerns for subacromial impingement and restricted motion [99]. Excellent results have been reported in case series with regard to maintenance of reduction and clinical results [100–103]. However, selected reports of high complication rates are concerning [104, 105].

Primary Coracoclavicular Fixation

Similar to AC fixation, primary CC fixation is generally recommended for acute cases (<3 weeks) to promote healing of the torn AC and CC ligaments in an anatomic position. Samuel Cooper is credited with performing the first AC stabilization surgery in 1861 using a wire loop between the coracoid and clavicle, a practice that continued until the late twentieth century [106]. In 1917, Delbet described the first procedure in which a suture looped around the coracoid and was fixed through clavicular bone tunnels.

Many variations have subsequently been described using absorbable and non-absorbable materials. These sutures may be looped around bone, pulled through tunnels, or fixed with anchors. Over the years, methods involving polydioxanone sulfate (PDS), nylon, mersilene, and modern high strength synthetic braided suture have been described [107–113]. Failure of the suture or cutout through bone are well documented complications [114]. Over the last 5 years, novel methods involving the use of suture pulley systems combined with cortical button fixation have been commercially available and gained popularity [115–117]. While these devices theoretically allow for smaller tunnels to be drilled through the coracoid and clavicle with a lesser risk of iatrogenic fracture, intraoperative and postoperative implant failures have been reported [115].

A movement for CC fixation with synthetic ligament grafts occurred but never gained widespread use. Literature focused on the use of polyethylene grafts surfaced in the early 1990s and has reemerged of late [118–124]. Lack of efficacy over other surgical options and the potential for aseptic foreign body reaction have led some surgeons to question their use [125–127].

Primary screw fixation between the clavicle and coracoid was popularized by Bosworth [128]. Coracoclavicular lag screws can be used in isolation or combined with ligament reconstruction and have been made technically easier with the routine use of intraoperative fluoroscopy [129, 130]. While biomechanical studies have shown this to be the most rigid construct when compared to native CC ligament complex, surgeons have expressed concern over hardware complications, iatrogenic fractures, and staged hardware removal [131, 132] (Fig. 8.5).

Biologic Coracoclavicular Ligament Reconstruction

Biologic CC ligament reconstructions are generally recommended in chronic (>3 weeks) cases in which the native AC and CC ligaments are unlikely to heal effectively, but are utilized by some surgeons for all reconstructions. Free tendon grafts have largely replaced the once common native coracoacromial ligament transfers in order to anatomically reconstruct the conoid and trapezoid.

Weaver and Dunn are credited with describing the use of coracoacromial (CA) ligament to reconstruct the CC ligaments, a technique later modified to include a

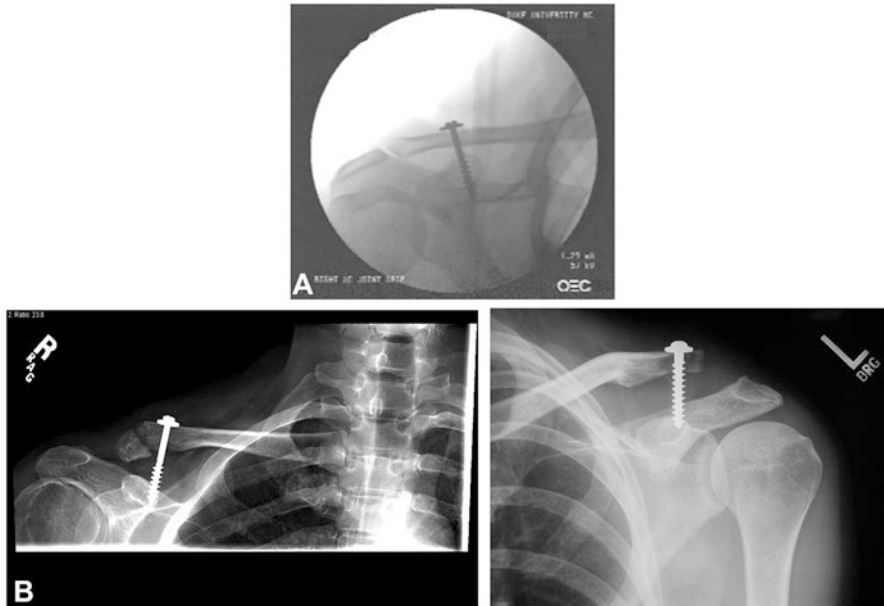


Fig. 8.5 (a) CC fixation complicated by a distal clavicle fracture. (b) Postoperative loss of CC fixation

distal clavicle resection to prevent late symptomatic degenerative changes [133]. The ligament is detached from its acromial insertion through a tenotomy or small osteotomy and transferred to the clavicle [134–136]. The Weaver–Dunn procedure is considered a non-anatomic reconstruction with poor biomechanical properties compared to the native CC ligament complex, particularly with regard to horizontal stability [137, 138]. As a result, supplementary CC fixation is often advocated [139–141]. Nonetheless, excellent clinical and radiographic results have been achieved by multiple authors [142, 136].

A more sophisticated understanding of the complex anatomy and biomechanics of the AC joint have led to a push for more anatomic techniques. As a result, free tendon graft reconstructions have gain popularity over the last decade. Jones et al. originally described using a looped semitendinosus graft around the coracoid and clavicle [143]. Various autografts (gracilis, palmaris) and allografts (tibialis anterior, peroneus brevis) have also been utilized [144, 145].

Several modifications to the technique have been described, and techniques continue to evolve. Bone tunnels or sockets in the clavicle and coracoid have been employed to more anatomicly reconstruct the trapezoid and conoid individually [146, 147]. Grafts are generally fixed on the clavicular side with interference screws and a suture button device may be added for supplementary fixation while the graft incorporates [148, 117]. Recently, a novel technique in which the excess lateral trapezoid graft limb has been used to reconstruct the AC ligaments and capsule, as this may provide additional horizontal stability [149, 150] (Fig. 8.6).

Fig. 8.6 Intraoperative graft passage for a CC reconstruction. The lateral graft limb may be utilized for supplementary AC fixation

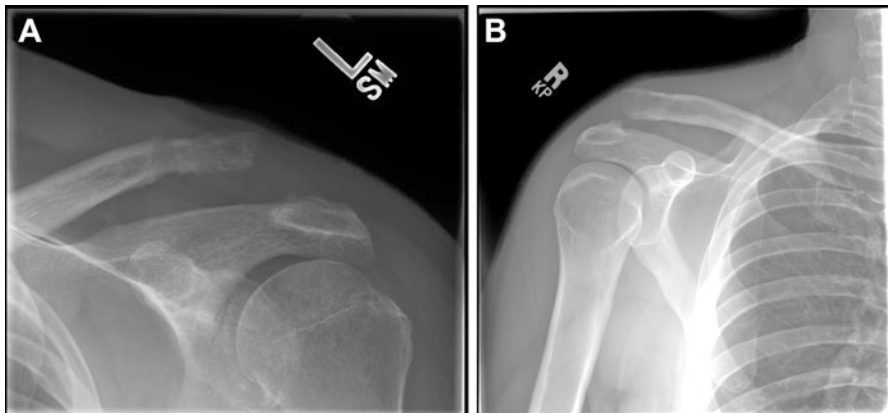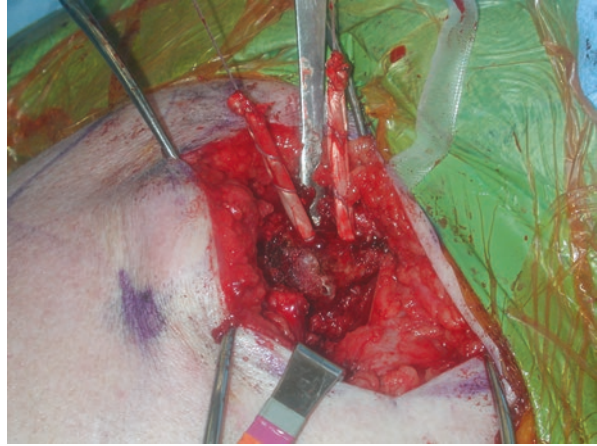


Fig. 8.7 Postoperative loss of reduction after CC reconstruction with superior migration of the distal clavicle relative to the acromion (**A** and **B**)

Free tendon graft CC reconstruction has been biomechanically shown to best reproduce the horizontal and vertical stability provided by the native CC ligaments [146, 151]. In a prospective direct clinical comparison, Tauber showed more favorable American Shoulder and Elbow Surgeons (ASES) and Constant scores with a semitendinosus reconstruction over a CA ligament transfer [152]. Concern exists for long-term osteolysis and tunnel widening with subsequent coracoid and clavicle fractures [153, 154].

Graft placement at the anatomic footprint of the CC ligaments appears to be critical to maximize fixation, maintain reduction, and achieve optimal biomechanical and clinical results [155, 156]. Cook et al. performed a retrospective review of 28 consecutive reconstruction in an active military population [155]. A mean radiographic failure rate of 28.6% was reported at a mean 7.4 weeks postoperatively, with a medialized graft position predictive of early failure. Authors recommended preoperative templating to ensure optimal clavicular tunnel positions (Fig. 8.7).

Arthroscopy-Assisted Techniques

Arthroscopic-assisted techniques for AC stabilization have developed with the widespread use and evolution of shoulder arthroscopy. In addition to the potential benefits of a less invasive approach, arthroscopic techniques also allow the surgeon to assess and treat associated glenohumeral pathology. Originally described by Wolf and Pennington, many subsequent variations using both tendon grafts and suture systems have been described [157–167]. While many authors report excellent results with these techniques, no high-level studies comparing arthroscopic and open techniques exist [168]. In isolated series, unacceptably high complication rates have been reported ranging from 22 to 44%, presumably due to the difficulty associated with these techniques [169, 170].

Role of Distal Clavicle Resection

Distal clavicle resection has long been routinely combined with CA ligament transfer and CC reconstruction in an attempt to prevent late symptomatic arthritis. Recently, there has been concern that concomitant resection of the distal clavicle may further exacerbate horizontal instability. A cadaveric biomechanical study by Beaver et al. has questioned the validity of this concern in association with AC stabilization techniques [171]. Similarly, a recent large, multicenter level II study by Barth et al. showed no difference in clinical results with or without distal clavicle resection combined with CC ligament reconstruction for chronic separations [172].

Surgical Timing

Surgeons have debated the potential benefits of acute surgical intervention in complete separations. Beitzel et al. conducted a systematic review examining the surgical timing of reconstruction [61]. While the definition of delayed reconstruction was not uniform, it was generally considered to be greater than 3–4 weeks after injury. In the four retrospective studies included, favorable outcomes were achieved in 91% of the early treatment group compared with 72% in the delayed cohort, suggesting a possible benefit to expedited intervention when appropriate. However, no prospective study has similarly directly demonstrated this advantage [173–176].

Rehab

The rehabilitation after AC joint reconstruction remains highly variable among surgeons. Cote et al. provided an excellent review detailing all aspects of the rehabilitation of surgically and nonsurgically treated injuries. The extremity is placed in a

platform brace for 6–8 weeks to allow for graft incorporation, although many surgeons advocate a simple sling with early passive motion. After discontinuation of the brace, formal therapy focusing on active assisted range of motion and stretching is initiated. Strengthening begins at approximately 12 weeks.

Summary

Acromioclavicular injuries are likely the most common injury to the shoulder girdle in contact athletes. A seemingly inconsequential joint, the AC articulation has complex biomechanics that we are continuing to investigate and understand. Disruption of its normal anatomy and stability can lead to abnormal shoulder function and chronic pain. Making definitive statements to guide treatment is difficult given the paucity of high quality research. Since no single method is clearly superior in replicating the anatomy and biomechanics of the native AC joint, surgical techniques continue to evolve.

References

1. Pallis M, et al. Epidemiology of acromioclavicular joint injury in young athletes. *Am J Sports Med.* 2012;40(9):2072–7.
2. Webb J, Bannister G. Acromioclavicular disruption in first class rugby players. *Br J Sports Med.* 1992;26(4):247–8.
3. Lynch TS, et al. Acromioclavicular joint injuries in the National Football League: epidemiology and management. *Am J Sports Med.* 2013;41(12):2904–8.
4. Dragoo JL, et al. Acromioclavicular joint injuries in National Collegiate Athletic Association football: data from the 2004–2005 through 2008–2009 National Collegiate Athletic Association Injury Surveillance System. *Am J Sports Med.* 2012;40(9):2066–71.
5. Labson JD, Anderson KA, Marder RA. Acromioclavicular dislocation after arthroscopic distal clavicle resection: a case report. *J Shoulder Elb Surg.* 2011;20(2):e10–2.
6. Beitzel K, et al. Sequential resection of the distal clavicle and its effects on horizontal acromioclavicular joint translation. *Am J Sports Med.* 2012;40(3):681–5.
7. Edwards SL, et al. Arthroscopic distal clavicle resection: a biomechanical analysis of resection length and joint compliance in a cadaveric model. *Arthroscopy.* 2007;23(12):1278–84.
8. Smith DM. Coracoid fracture associated with acromioclavicular dislocation. A case report. *Clin Orthop Relat Res.* 1975;108:165–7.
9. Lasda NA, Murray DG. Fracture separation of the coracoid process associated with acromioclavicular dislocation: conservative treatment—a case report and review of the literature. *Clin Orthop Relat Res.* 1978;134:222–4.
10. Bernard Jr TN, Brunet ME, Haddad Jr RJ. Fractured coracoid process in acromioclavicular dislocations. Report of four cases and review of the literature. *Clin Orthop Relat Res.* 1983;175:227–32.
11. Carr AJ, Broughton NS. Acromioclavicular dislocation associated with fracture of the coracoid process. *J Trauma.* 1989;29(1):125–6.
12. Wilson KM, Colwill JC. Combined acromioclavicular dislocation with coracoclavicular ligament disruption and coracoid process fracture. *Am J Sports Med.* 1989;17(5):697–8.
13. Hak DJ, Johnson EE. Avulsion fracture of the coracoid associated with acromioclavicular dislocation. *J Orthop Trauma.* 1993;7(4):381–3.

14. Wang KC, Hsu KY, Shih CH. Coracoid process fracture combined with acromioclavicular dislocation and coracoclavicular ligament rupture. A case report and review of the literature. *Clin Orthop Relat Res.* 1994;300:120–2.
15. DiPaola M, Marchetto P. Coracoid process fracture with acromioclavicular joint separation in an American football player: a case report and literature review. *Am J Orthop (Belle Mead NJ).* 2009;38(1):37–9; discussion 40.
16. Kim KC, et al. Displaced fracture of the coracoid process associated with acromioclavicular dislocation: a two-bird-one-stone solution. *J Trauma.* 2009;67(2):403–5.
17. Kose O, et al. Acromioclavicular dislocation associated with coracoid process fracture: report of two cases and review of the literature. *Case Rep Orthop.* 2015;2015:858969.
18. Sondergard-Petersen P, Mikkelsen P. Posterior acromioclavicular dislocation. *J Bone Joint Surg Br.* 1982;64(1):52–3.
19. Barber FA. Complete posterior acromioclavicular dislocation. A case report. *Orthopedics.* 1987;10(3):493–6.
20. Sage J. Recurrent inferior dislocation of the clavicle at the acromioclavicular joint. A case report. *Am J Sports Med.* 1982;10(3):145–6.
21. Schwarz N, Kuderna H. Inferior acromioclavicular separation. Report of an unusual case. *Clin Orthop Relat Res.* 1988;234:28–30.
22. Cresswell TR. Spontaneous reduction of an inferior acromioclavicular joint dislocation. *Injury.* 1998;29(7):567–8.
23. Leppilahti J, Jalovaara P. Recurrent inferior dislocation of the acromioclavicular joint: a report of two cases. *J Shoulder Elb Surg.* 2001;10(4):387–8.
24. Namkoong S, Zuckerman JD, Rose DJ. Traumatic subacromial dislocation of the acromioclavicular joint: a case report. *J Shoulder Elb Surg.* 2007;16(1):e8–10.
25. Hastings DE, Horne JG. Anterior dislocation of the acromioclavicular joint. *Injury.* 1979;10(4):285–8.
26. Baek SH, et al. Anterior clavicle dislocation associated with acromioclavicular dislocation in a soccer player: a case report. *Am J Sports Med.* 2007;35(10):1752–5.
27. Tischer T, et al. Incidence of associated injuries with acute acromioclavicular joint dislocations types III through V. *Am J Sports Med.* 2009;37(1):136–9.
28. Arrigoni P, et al. Associated lesions requiring additional surgical treatment in grade 3 acromioclavicular joint dislocations. *Arthroscopy.* 2014;30(1):6–10.
29. Pauly S, et al. Prevalence and pattern of glenohumeral injuries among acute high-grade acromioclavicular joint instabilities. *J Shoulder Elb Surg.* 2013;22(6):760–6.
30. Lancourt JE. Acromioclavicular dislocation with adjacent clavicular fracture in a horseback rider. A case report. *Am J Sports Med.* 1990;18(3):321–2.
31. Heinz WM, Misamore GW. Mid-shaft fracture of the clavicle with grade III acromioclavicular separation. *J Shoulder Elb Surg.* 1995;4(2):141–2.
32. Juhn MS, Simonian PT. Type VI acromioclavicular separation with middle-third clavicle fracture in an ice hockey player. *Clin J Sport Med.* 2002;12(5):315–7.
33. Yeh PC, et al. Midshaft clavicle fracture and acromioclavicular dislocation: a case report of a rare injury. *J Shoulder Elb Surg.* 2009;18(5):e1–4.
34. Psarakis SA, et al. A rare injury of ipsilateral mid-third clavicle fracture with acromioclavicular joint dislocation. *Hand (N Y).* 2011;6(2):228–32.
35. Woolf SK, et al. Middle-third clavicle fracture with associated type IV acromioclavicular separation: case report and literature review. *J Surg Orthop Adv.* 2013;22(2):183–6.
36. Solooki S, Azad A. Simultaneous middle third clavicle fracture and type 3 acromioclavicular joint dislocation; a case report. *Arch Bone Jt Surg.* 2014;2(1):69–71.
37. Madi S, et al. A dual injury of the shoulder: acromioclavicular joint dislocation (type IV) coupled with ipsilateral mid-shaft clavicle fracture. *BMJ Case Rep.* 2015;2015.
38. Wade AM, et al. Medial clavicular epiphyseal fracture with ipsilateral acromioclavicular dislocation: a case report of panclavicular fracture dislocation. *J Orthop Trauma.* 2007;21(6):418–21.
39. Schemitsch LA, Schemitsch EH, McKee MD. Bipolar clavicle injury: posterior dislocation of the acromioclavicular joint with anterior dislocation of the sternoclavicular joint: a report of two cases. *J Shoulder Elb Surg.* 2011;20(1):e18–22.

40. Merk BR, Minihane KP, Shah NA. Scapulothoracic dissociation with acromioclavicular separation: a case report of a novel fixation method. *J Orthop Trauma*. 2008;22(8):572–5.
41. Meislin RJ, Zuckerman JD, Nainzadeh N. Type III acromioclavicular joint separation associated with late brachial-plexus neuroparaxia. *J Orthop Trauma*. 1992;6(3):370–2.
42. Gallagher CA, Blakeney W, Zellweger R. Acromioclavicular joint dislocation with associated brachial plexus injury. *BMJ Case Rep*. 2014;2014.
43. Tossy JD, Mead NC, Sigmund HM. Acromioclavicular separations: useful and practical classification for treatment. *Clin Orthop Relat Res*. 1963;28:111–9.
44. Beitzel K, et al. ISAKOS upper extremity committee consensus statement on the need for diversification of the Rockwood classification for acromioclavicular joint injuries. *Arthroscopy*. 2014;30(2):271–8.
45. Cho CH, et al. Reliability of the classification and treatment of dislocations of the acromioclavicular joint. *J Shoulder Elb Surg*. 2014;23(5):665–70.
46. Schneider MM, et al. Inter- and intraobserver reliability of the Rockwood classification in acute acromioclavicular joint dislocations. *Knee Surg Sports Traumatol Arthrosc*. 2016;24(7):2192–6.
47. Barnes CJ, et al. Magnetic resonance imaging of the coracoclavicular ligaments: its role in defining pathoanatomy at the acromioclavicular joint. *J Surg Orthop Adv*. 2004;13(2):69–75.
48. Nemeč U, et al. MRI versus radiography of acromioclavicular joint dislocation. *AJR Am J Roentgenol*. 2011;197(4):968–73.
49. Kibler WB, Sciascia A. Current concepts: scapular dyskinesis. *Br J Sports Med*. 2010;44(5):300–5.
50. Gumina S, Carbone S, Postacchini F. Scapular dyskinesis and SICK scapula syndrome in patients with chronic type III acromioclavicular dislocation. *Arthroscopy*. 2009;25(1):40–5.
51. Zanca P. Shoulder pain: involvement of the acromioclavicular joint. (Analysis of 1,000 cases). *Am J Roentgenol Radium Ther Nucl Med*. 1971;112(3):493–506.
52. Bossart PJ, et al. Lack of efficacy of ‘weighted’ radiographs in diagnosing acute acromioclavicular separation. *Ann Emerg Med*. 1988;17(1):20–4.
53. Rahm S, et al. Standard axillary radiographs of the shoulder may mimic posterior subluxation of the lateral end of the clavicle. *J Orthop Trauma*. 2013;27(11):622–6.
54. Gastaud O, et al. Reliability of radiographic measurements for acromioclavicular joint separations. *Orthop Traumatol Surg Res*. 2015;101(Suppl 8):S291–5.
55. Tauber M, et al. Dynamic radiologic evaluation of horizontal instability in acute acromioclavicular joint dislocations. *Am J Sports Med*. 2010;38(6):1188–95.
56. Dyer DR, Troupis JM, Kamali Moaveni A. Wide field of view CT and acromioclavicular joint instability: a technical innovation. *J Med Imaging Radiat Oncol*. 2015;59(3):326–30.
57. Alyas F, et al. MR imaging appearances of acromioclavicular joint dislocation. *Radiographics*. 2008;28(2):463–79; quiz 619.
58. Izadpanah K, et al. A stress MRI of the shoulder for evaluation of ligamentous stabilizers in acute and chronic acromioclavicular joint instabilities. *J Magn Reson Imaging*. 2013;37(6):1486–92.
59. Peetrons P, Bedard JP. Acromioclavicular joint injury: enhanced technique of examination with dynamic maneuver. *J Clin Ultrasound*. 2007;35(5):262–7.
60. Tamaoki MJ, et al. Surgical versus conservative interventions for treating acromioclavicular dislocation of the shoulder in adults. *Cochrane Database Syst Rev*. 2010;8:CD007429.
61. Beitzel K, et al. Current concepts in the treatment of acromioclavicular joint dislocations. *Arthroscopy*. 2013;29(2):387–97.
62. Ceccarelli E, et al. Treatment of acute grade III acromioclavicular dislocation: a lack of evidence. *J Orthop Traumatol*. 2008;9(2):105–8.
63. Korsten K, Gunning AC, Leenen LP. Operative or conservative treatment in patients with Rockwood type III acromioclavicular dislocation: a systematic review and update of current literature. *Int Orthop*. 2014;38(4):831–8.
64. Gibbens ME. An appliance for the conservative treatment of acromioclavicular dislocation. *J Bone Joint Surg Am*. 1946;28:164.

65. Batchelor JS. Splint for fractured clavicle and acromioclavicular dislocation. *Lancet*. 1947;2(6480):690.
66. Morrison GM. Cast treatment of acromioclavicular dislocations. *J Bone Joint Surg Am*. 1948;30A(1):238.
67. Varney JH, Coker JK, Cawley JJ. Treatment of acromioclavicular dislocation by means of a harness. *J Bone Joint Surg Am*. 1952;34-A(1):232–3.
68. Anzel SH, Streitz WL. Acute acromioclavicular injuries. A report of nineteen cases treated non-operatively employing dynamic splint immobilization. *Clin Orthop Relat Res*. 1974;103:143–9.
69. Shaw MB, et al. Acromioclavicular joint sprains: the post-injury recovery interval. *Injury*. 2003;34(6):438–42.
70. Mouhsine E, et al. Grade I and II acromioclavicular dislocations: results of conservative treatment. *J Shoulder Elb Surg*. 2003;12(6):599–602.
71. Mikek M. Long-term shoulder function after type I and II acromioclavicular joint disruption. *Am J Sports Med*. 2008;36(11):2147–50.
72. Wojtyś EM, Nelson G. Conservative treatment of Grade III acromioclavicular dislocations. *Clin Orthop Relat Res*. 1991;268:112–9.
73. Rasmont Q, et al. Is conservative treatment still defensible in grade III acromioclavicular dislocation? Are there predictive factors of poor outcome? *Acta Orthop Belg*. 2015;81(1):107–14.
74. Larsen E, Bjerg-Nielsen A, Christensen P. Conservative or surgical treatment of acromioclavicular dislocation. A prospective, controlled, randomized study. *J Bone Joint Surg Am*. 1986;68(4):552–5.
75. Taft TN, Wilson FC, Oglesby JW. Dislocation of the acromioclavicular joint. An end-result study. *J Bone Joint Surg Am*. 1987;69(7):1045–51.
76. Phillips AM, Smart C, Groom AF. Acromioclavicular dislocation. Conservative or surgical therapy. *Clin Orthop Relat Res*. 1998;353:10–7.
77. Imatani RJ, Hanlon JJ, Cady GW. Acute, complete acromioclavicular separation. *J Bone Joint Surg Am*. 1975;57(3):328–32.
78. Joukainen A, et al. Results of operative and nonoperative treatment of rockwood types III and V acromioclavicular joint dislocation: a prospective, randomized trial with an 18- to 20-year follow-up. *Orthop J Sports Med*. 2014;2(12):2325967114560130.
79. Rosenorn M, Pedersen EB. A comparison between conservative and operative treatment of acute acromioclavicular dislocation. *Acta Orthop Scand*. 1974;45(1):50–9.
80. Jacobs B, Wade PA. Acromioclavicular-joint injury. An end-result study. *J Bone Joint Surg Am*. 1966;48(3):475–86.
81. Calvo E, Lopez-Franco M, Arribas IM. Clinical and radiologic outcomes of surgical and conservative treatment of type III acromioclavicular joint injury. *J Shoulder Elb Surg*. 2006;15(3):300–5.
82. MacDonald PB, et al. Comprehensive functional analysis of shoulders following complete acromioclavicular separation. *Am J Sports Med*. 1988;16(5):475–80.
83. Bannister GC, et al. The management of acute acromioclavicular dislocation. A randomised prospective controlled trial. *J Bone Joint Surg Br*. 1989;71(5):848–50.
84. Press J, et al. Treatment of grade III acromioclavicular separations. Operative versus nonoperative management. *Bull Hosp Jt Dis*. 1997;56(2):77–83.
85. Cardone D, et al. Grade III acromioclavicular joint injury in Australian Rules Football. *J Sci Med Sport*. 2002;5(2):143–8.
86. Carbone S, Postacchini R, Gumina S. Scapular dyskinesis and SICK syndrome in patients with a chronic type III acromioclavicular dislocation. Results of rehabilitation. *Knee Surg Sports Traumatol Arthrosc*. 2015;23(5):1473–80.
87. Meier AW, Grannis WR, Tanner JB. Acromioclavicular dislocations; open reduction with screw fixation. *Calif Med*. 1957;87(4):261–2.
88. O'Carroll PF, Sheehan JM. Open reduction and percutaneous Kirschner wire fixation in complete disruption of the acromioclavicular joint. *Injury*. 1982;13(4):299–301.

89. Paavolainen P, et al. Surgical treatment of acromioclavicular dislocation: a review of 39 patients. *Injury*. 1983;14(5):415–20.
90. Leidel BA, et al. Consistency of long-term outcome of acute Rockwood grade III acromioclavicular joint separations after K-wire transfixation. *J Trauma*. 2009;66(6):1666–71.
91. Wang SJ, Wong CS. Transacromial extra-articular Knowles pin fixation treatment of acute type V acromioclavicular joint injuries. *J Trauma*. 2008;65(2):424–9.
92. Eskola A, et al. Four-year outcome of operative treatment of acute acromioclavicular dislocation. *J Orthop Trauma*. 1991;5(1):9–13.
93. Norrell Jr H, Llewellyn RC. Migration of a threaded steinmann pin from an acromioclavicular joint into the spinal canal. A case report. *J Bone Joint Surg Am*. 1965;47:1024–6.
94. Lindsey RW, Gutowski WT. The migration of a broken pin following fixation of the acromioclavicular joint. A case report and review of the literature. *Orthopedics*. 1986;9(3):413–6.
95. Mlasowsky B, et al. Repair of complete acromioclavicular dislocation (Tossy stage III) using Balser's hook plate combined with ligament sutures. *Injury*. 1988;19(4):227–32.
96. Faraj AA, Ketzler B. The use of a hook-plate in the management of acromioclavicular injuries. Report of ten cases. *Acta Orthop Belg*. 2001;67(5):448–51.
97. De Baets T, et al. The treatment of acromioclavicular joint dislocation Tossy grade III with a clavicle hook plate. *Acta Orthop Belg*. 2004;70(6):515–9.
98. Nuchtern JV, et al. Biomechanical evaluation of 3 stabilization methods on acromioclavicular joint dislocations. *Am J Sports Med*. 2013;41(6):1387–94.
99. Kim YS, et al. In vivo analysis of acromioclavicular joint motion after hook plate fixation using three-dimensional computed tomography. *J Shoulder Elb Surg*. 2015;24(7):1106–11.
100. Ejam S, Lind T, Falkenberg B. Surgical treatment of acute and chronic acromioclavicular dislocation Tossy type III and V using the Hook plate. *Acta Orthop Belg*. 2008;74(4):441–5.
101. Gstetner C, et al. Rockwood type III acromioclavicular dislocation: surgical versus conservative treatment. *J Shoulder Elb Surg*. 2008;17(2):220–5.
102. Liu HH, et al. Surgical treatment of acute acromioclavicular joint injuries using a modified Weaver-Dunn procedure and clavicular hook plate. *Orthopedics*. 2010;33(8).
103. Yoon JP, et al. Comparison of results between hook plate fixation and ligament reconstruction for acute unstable acromioclavicular joint dislocation. *Clin Orthop Surg*. 2015;7(1):97–103.
104. Sim E, et al. Repair of complete acromioclavicular separations using the acromioclavicular-hook plate. *Clin Orthop Relat Res*. 1995;314:134–42.
105. Eschler A, et al. Hook plate fixation for acromioclavicular joint separations restores coracoclavicular distance more accurately than PDS augmentation, however presents with a high rate of acromial osteolysis. *Arch Orthop Trauma Surg*. 2012;132(1):33–9.
106. Heitemeyer U, et al. The operative treatment of fresh ruptures of the acromioclavicular joint (Tossy III). *Arch Orthop Trauma Surg*. 1986;104(6):371–3.
107. Hessmann M, et al. Reconstruction of complete acromioclavicular separations (Tossy III) using PDS-banding as augmentation: experience in 64 cases. *Acta Chir Belg*. 1995;95(3):147–51.
108. Monig SP, et al. Treatment of complete acromioclavicular dislocation: present indications and surgical technique with biodegradable cords. *Int J Sports Med*. 1999;20(8):560–2.
109. Wellmann M, Zantop T, Petersen W. Minimally invasive coracoclavicular ligament augmentation with a flip button/polydioxanone repair for treatment of total acromioclavicular joint dislocation. *Arthroscopy*. 2007;23(10):1132.e1–5.
110. Greiner S, et al. Mid to long-term results of open acromioclavicular-joint reconstruction using polydioxansulfate cerclage augmentation. *Arch Orthop Trauma Surg*. 2009;129(6):735–40.
111. Dimakopoulos P, et al. Double-loop suture repair for acute acromioclavicular joint disruption. *Am J Sports Med*. 2006;34(7):1112–9.
112. Sobhy MH. Midterm results of combined acromioclavicular and coracoclavicular reconstruction using nylon tape. *Arthroscopy*. 2012;28(8):1050–7.
113. Kumar V, et al. Modified Weaver-Dunn procedure versus the use of a synthetic ligament for acromioclavicular joint reconstruction. *J Orthop Surg (Hong Kong)*. 2014;22(2):199–203.

114. Motta P, et al. Suture rupture in acromioclavicular joint dislocations treated with flip buttons. *Arthroscopy*. 2011;27(2):294–8.
115. Nordin JS, Aagaard KE, Lunsjo K. Chronic acromioclavicular joint dislocations treated by the GraftRope device. *Acta Orthop*. 2015;86(2):225–8.
116. Walz L, et al. The anatomic reconstruction of acromioclavicular joint dislocations using 2 TightRope devices: a biomechanical study. *Am J Sports Med*. 2008;36(12):2398–406.
117. Zooker CC, et al. TightRope versus fiber mesh tape augmentation of acromioclavicular joint reconstruction: a biomechanical study. *Am J Sports Med*. 2010;38(6):1204–8.
118. Stam L, Dawson I. Complete acromioclavicular dislocations: treatment with a Dacron ligament. *Injury*. 1991;22(3):173–6.
119. Verhaven E, et al. Surgical treatment of acute type V acromioclavicular injuries. A prospective study. *Acta Orthop Belg*. 1992;58(2):176–82.
120. Frascini G, et al. Surgical treatment of chronic acromioclavicular dislocation: comparison between two surgical procedures for anatomic reconstruction. *Injury*. 2010;41(11):1103–6.
121. Giannotti S, et al. Surgical treatment of acromioclavicular dislocation with LARS artificial ligament. *Eur J Orthop Surg Traumatol*. 2013;23(8):873–6.
122. Lu N, et al. Evaluation of the coracoclavicular reconstruction using LARS artificial ligament in acute acromioclavicular joint dislocation. *Knee Surg Sports Traumatol Arthrosc*. 2014;22(9):2223–7.
123. Marcheggiani Muccioli GM, et al. Acromioclavicular joint reconstruction with the LARS ligament in professional versus non-professional athletes. *Knee Surg Sports Traumatol Arthrosc*. 2016;24(6):1961–7.
124. Wright J, et al. Stabilisation for the disrupted acromioclavicular joint using a braided polyester prosthetic ligament. *J Orthop Surg (Hong Kong)*. 2015;23(2):223–8.
125. Colosimo AJ, Hummer 3rd CD, Heidt Jr RS. Aseptic foreign body reaction to Dacron graft material used for coracoclavicular ligament reconstruction after type III acromioclavicular dislocation. *Am J Sports Med*. 1996;24(4):561–3.
126. Boldin C, et al. Foreign-body reaction after reconstruction of complete acromioclavicular dislocation using PDS augmentation. *J Shoulder Elb Surg*. 2004;13(1):99–100.
127. Stewart AM, Ahmad CS. Failure of acromioclavicular reconstruction using Gore-Tex graft due to aseptic foreign-body reaction and clavicle osteolysis: a case report. *J Shoulder Elb Surg*. 2004;13(5):558–61.
128. Bosworth BM. Acromioclavicular dislocation: end-results of screw suspension treatment. *Ann Surg*. 1948;127(1):98–111.
129. Kumar S, Sethi A, Jain AK. Surgical treatment of complete acromioclavicular dislocation using the coracoacromial ligament and coracoclavicular fixation: report of a technique in 14 patients. *J Orthop Trauma*. 1995;9(6):507–10.
130. Guy DK, et al. Reconstruction of chronic and complete dislocations of the acromioclavicular joint. *Clin Orthop Relat Res*. 1998;347:138–49.
131. Jari R, et al. Biomechanical function of surgical procedures for acromioclavicular joint dislocations. *Arthroscopy*. 2004;20(3):237–45.
132. Ammon JT, Voor MJ, Tillett ED. A biomechanical comparison of Bosworth and poly-L lactic acid bioabsorbable screws for treatment of acromioclavicular separations. *Arthroscopy*. 2005;21(12):1443–6.
133. Weaver JK, Dunn HK. Treatment of acromioclavicular injuries, especially complete acromioclavicular separation. *J Bone Joint Surg Am*. 1972;54(6):1187–94.
134. Shoji H, Roth C, Chuinard R. Bone block transfer of coracoacromial ligament in acromioclavicular injury. *Clin Orthop Relat Res*. 1986;208:272–7.
135. Kutschera HP, Kotz RI. Bone-ligament transfer of coracoacromial ligament for acromioclavicular dislocation. A new fixation method used in 6 cases. *Acta Orthop Scand*. 1997;68(3):246–8.
136. Millett PJ, et al. Acromioclavicular joint reconstruction with coracoacromial ligament transfer using the docking technique. *BMC Musculoskelet Disord*. 2009;10:6.

137. Lee SJ, et al. Reconstruction of the coracoclavicular ligaments with tendon grafts: a comparative biomechanical study. *Am J Sports Med.* 2003;31(5):648–55.
138. Deshmukh AV, et al. Stability of acromioclavicular joint reconstruction: biomechanical testing of various surgical techniques in a cadaveric model. *Am J Sports Med.* 2004;32(6):1492–8.
139. Wilson DR, et al. Mechanics of coracoacromial ligament transfer augmentation for acromioclavicular joint injuries. *J Biomech.* 2005;38(3):615–9.
140. Shin SJ, Yun YH, Yoo JD. Coracoclavicular ligament reconstruction for acromioclavicular dislocation using 2 suture anchors and coracoacromial ligament transfer. *Am J Sports Med.* 2009;37(2):346–51.
141. Al-Ahaideb A. Surgical treatment of chronic acromioclavicular joint dislocation using the Weaver-Dunn procedure augmented by the TightRope(R) system. *Eur J Orthop Surg Traumatol.* 2014;24(5):741–5.
142. Karlsson J, Arnarson H, Sigurjonsson K. Acromioclavicular dislocations treated by coracoacromial ligament transfer. *Arch Orthop Trauma Surg.* 1986;106(1):8–11.
143. Jones HP, Lemos MJ, Schepsis AA. Salvage of failed acromioclavicular joint reconstruction using autogenous semitendinosus tendon from the knee. Surgical technique and case report. *Am J Sports Med.* 2001;29(2):234–7.
144. Law KY, et al. Coracoclavicular ligament reconstruction using a gracilis tendon graft for acute type-III acromioclavicular dislocation. *J Orthop Surg (Hong Kong).* 2007;15(3):315–8.
145. Gonzalez R, et al. Acromioclavicular joint reconstruction using peroneus brevis tendon allograft. *Arthroscopy.* 2007;23(7):788.e1–4.
146. Mazzocca AD, et al. A biomechanical evaluation of an anatomical coracoclavicular ligament reconstruction. *Am J Sports Med.* 2006;34(2):236–46.
147. LaPrade RF, Hilger B. Coracoclavicular ligament reconstruction using a semitendinosus graft for failed acromioclavicular separation surgery. *Arthroscopy.* 2005;21(10):1277.
148. Erak S, et al. Acromioclavicular reconstructions with hamstring tendon grafts: a comparative biomechanical study. *J Shoulder Elb Surg.* 2008;17(5):772–8.
149. Saier T, et al. Value of additional acromioclavicular cerclage for horizontal stability in complete acromioclavicular separation: a biomechanical study. *Knee Surg Sports Traumatol Arthrosc.* 2015;23(5):1498–505.
150. Shin SJ, et al. Simultaneous anatomic reconstruction of the acromioclavicular and coracoclavicular ligaments using a single tendon graft. *Knee Surg Sports Traumatol Arthrosc.* 2014;22(9):2216–22.
151. Michlitsch MG, et al. Biomechanical comparison of a modified Weaver-Dunn and a free-tissue graft reconstruction of the acromioclavicular joint complex. *Am J Sports Med.* 2010;38(6):1196–203.
152. Tauber M, et al. Semitendinosus tendon graft versus a modified Weaver-Dunn procedure for acromioclavicular joint reconstruction in chronic cases: a prospective comparative study. *Am J Sports Med.* 2009;37(1):181–90.
153. Gerhardt DC, et al. Postoperative coracoid fracture after transcoracoid acromioclavicular joint reconstruction. *J Shoulder Elb Surg.* 2011;20(5):e6–10.
154. Yoo JC, et al. Distal clavicle tunnel widening after coracoclavicular ligament reconstruction with semitendinosus tendon: a case report. *J Shoulder Elb Surg.* 2006;15(2):256–9.
155. Cook JB, et al. Clavicular bone tunnel malposition leads to early failures in coracoclavicular ligament reconstructions. *Am J Sports Med.* 2013;41(1):142–8.
156. Geaney LE, et al. Graft fixation is highest with anatomic tunnel positioning in acromioclavicular reconstruction. *Arthroscopy.* 2013;29(3):434–9.
157. Wolf EM, Pennington WT. Arthroscopic reconstruction for acromioclavicular joint dislocation. *Arthroscopy.* 2001;17(5):558–63.
158. Cook JB, Tokish JM. Surgical management of acromioclavicular dislocations. *Clin Sports Med.* 2014;33(4):721–37.

159. Liu X, Huangfu X, Zhao J. Arthroscopic treatment of acute acromioclavicular joint dislocation by coracoclavicular ligament augmentation. *Knee Surg Sports Traumatol Arthrosc.* 2015; 23(5):1460–6.
160. Izadpanah K, et al. Arthroscopically assisted reconstruction of acute acromioclavicular joint dislocations: anatomic AC ligament reconstruction with protective internal bracing—the “AC-RecoBridge” technique. *Arthrosc Tech.* 2015;4(2):e153–61.
161. Venjakob AJ, et al. Arthroscopically assisted 2-bundle anatomic reduction of acute acromioclavicular joint separations: 58-month findings. *Am J Sports Med.* 2013;41(3):615–21.
162. Scheibel M, et al. Arthroscopically assisted stabilization of acute high-grade acromioclavicular joint separations. *Am J Sports Med.* 2011;39(7):1507–16.
163. Salzmann GM, et al. Arthroscopically assisted 2-bundle anatomical reduction of acute acromioclavicular joint separations. *Am J Sports Med.* 2010;38(6):1179–87.
164. DeBerardino TM, et al. Arthroscopic stabilization of acromioclavicular joint dislocation using the AC graftrope system. *J Shoulder Elb Surg.* 2010;19(Suppl 2):47–52.
165. Boileau P, et al. All-arthroscopic Weaver-Dunn-Chuinard procedure with double-button fixation for chronic acromioclavicular joint dislocation. *Arthroscopy.* 2010;26(2):149–60.
166. Murena L, et al. Arthroscopic treatment of acute acromioclavicular joint dislocation with double flip button. *Knee Surg Sports Traumatol Arthrosc.* 2009;17(12):1511–5.
167. Baumgarten KM, Altchek DW, Cordasco FA. Arthroscopically assisted acromioclavicular joint reconstruction. *Arthroscopy.* 2006;22(2):228.e1–6.
168. Modi CS, et al. Controversies relating to the management of acromioclavicular joint dislocations. *Bone Joint J.* 2013;95-B(12):1595–602.
169. Shin SJ, Kim NK. Complications after arthroscopic coracoclavicular reconstruction using a single adjustable-loop-length suspensory fixation device in acute acromioclavicular joint dislocation. *Arthroscopy.* 2015;31(5):816–24.
170. Clavert P, et al. Complication rates and types of failure after arthroscopic acute acromioclavicular dislocation fixation. Prospective multicenter study of 116 cases. *Orthop Traumatol Surg Res.* 2015;101(Suppl 8):S313–6.
171. Beaver AB, Parks BG, Hinton RY. Biomechanical analysis of distal clavicle excision with acromioclavicular joint reconstruction. *Am J Sports Med.* 2013;41(7):1684–8.
172. Barth J, et al. Prognostic factors to succeed in surgical treatment of chronic acromioclavicular dislocations. *Orthop Traumatol Surg Res.* 2015;101(Suppl 8):S305–11.
173. Rolf O, et al. Acromioclavicular dislocation Rockwood III–V: results of early versus delayed surgical treatment. *Arch Orthop Trauma Surg.* 2008;128(10):1153–7.
174. Weinstein DM, et al. Surgical treatment of complete acromioclavicular dislocations. *Am J Sports Med.* 1995;23(3):324–31.
175. Mignani G, et al. The surgical treatment of Rockwood grade III acromioclavicular dislocations. *Chir Organi Mov.* 2002;87(3):153–61.
176. Dumontier C, et al. Acromioclavicular dislocations: treatment by coracoacromial ligamentoplasty. *J Shoulder Elb Surg.* 1995;4(2):130–4.
177. Galpin RD, Hawkins RJ, Grainger RW. A comparative analysis of operative versus nonoperative treatment of grade III acromioclavicular separations. *Clin Orthop Relat Res.* 1985;193:150–5.
178. Walsh WM, et al. Shoulder strength following acromioclavicular injury. *Am J Sports Med.* 1985;13(3):153–8.
179. Bakalim G, Wilppula E. Surgical or conservative treatment of total dislocation of the acromioclavicular joint. *Acta Chir Scand.* 1975;141(1):43–7.
180. Larsen E, Hede A. Treatment of acute acromioclavicular dislocation. Three different methods of treatment prospectively studied. *Acta Orthop Belg.* 1987;53(4):480–4.

Chapter 9

Sternoclavicular Joint Injuries

Gordon I. Groh

Introduction

Sternoclavicular joint injuries are rare events. In a series by Cave [1], they comprised only 3% of all shoulder girdle injuries. Some orthopedic surgeons will have never seen or treated a sternoclavicular dislocation during their entire career.

The rarity of sternoclavicular injuries should not be confused with these injuries being innocuous. The close proximity of the hilar structures including the great vessels (innominate artery/vein, internal jugular vein, aortic arch, superior vena cava, and pulmonary artery), trachea, esophagus, and lung lead to the possible injury of any of these structures associated with traumatic injury. A systematic evaluation and treatment algorithm is essential to successful management of sternoclavicular joint injuries.

Anatomy

Although the clavicle is the first long bone to ossify by the fifth intrauterine week, the epiphysis of the medial end of the clavicle is the last of the long bones to appear. This is also the last epiphysis to close. The medial clavicular epiphysis does not ossify until between ages 18 and 20. Further, the epiphysis does not fuse with the shaft of the clavicle until ages 23 to 25 [2].

The sternoclavicular joint is freely mobile. It functions in almost all planes including rotation. The joint itself is small and diarthrodial, consisting of the only true articulation between the upper extremity and the axial skeleton. The combination of forces directed at this joint in all planes would seem to make the

G.I. Groh, M.D. (✉)

Mission Orthopedics, Mission Health, One Hospital Drive, 28801 Asheville, NC, USA

e-mail: gordonigroh@gmail.com

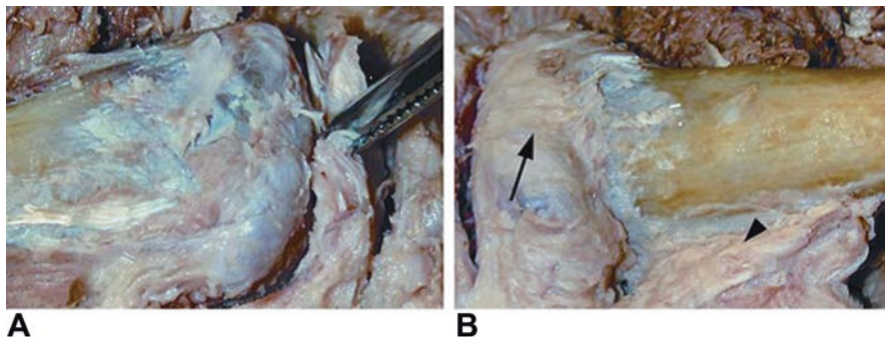


Fig. 9.1 The intra-articular disk ligament (*Held by forceps*), costoclavicular ligament (*Figure B arrowhead*), capsular ligament (*Figure B arrow*), and interclavicular ligament lend integrity to the sternoclavicular joint

sternoclavicular joint an inherently unstable mechanism. However, the ligamentous supporting structure yields a strength which accounts for its extremely low rate of dislocation.

The surrounding ligaments (intra-articular disk ligament, costoclavicular ligament, capsular ligament, and interclavicular ligament) lend integrity to this small incongruous joint (Fig. 9.1). The strongest ligament is the costoclavicular ligament also called the rhomboid ligament. This short and strong ligament is made up of two separate bands, which give the ligament a twisted appearance. Due to its separate fibers, the ligament is critical in resisting both anterior and posterior rotation forces of the medial clavicle [3]. The anterior and posterior capsular ligaments are important in providing anterior–posterior stability and rotational stability.

Mechanism of Injury

Due to the strong ligamentous supporting structure of the sternoclavicular joint, it requires tremendous force to dislocate the joint. These forces may be applied via direct or indirect application to the shoulder. Direct forces to the sternoclavicular joint typically result in posterior forces to the joint. Indirect forces (Fig. 9.2) are the most common mechanism of injury and may result in either anterior or posterior direction of forces across the sternoclavicular joint [4, 5]. Motor vehicular accidents and athletics account for over 80% of the cases of injury to this joint [6–8].

Classification of Injury

Sternoclavicular joint subluxation/dislocation injuries are uncommon. They can be organized by degree (subluxation, dislocation), timing (acute, chronic, recurrent), direction (anterior, posterior), and cause (traumatic, atraumatic).

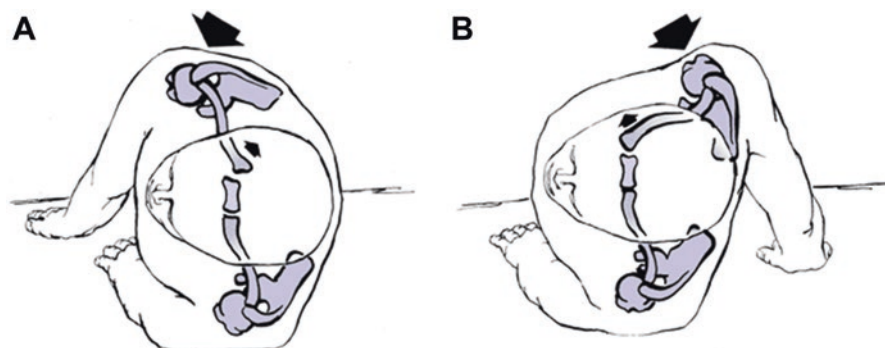


Fig. 9.2 (a) Forces resulting in an anterior dislocation of the sternoclavicular joint. (b) Forces resulting in a posterior dislocation of the sternoclavicular joint

Atraumatic Subluxation and Dislocation

Atraumatic SCJ dislocation/subluxation is an uncommon injury which occurs most often in adolescent female overhead athletes with multijoint laxity. On the basis of its bony anatomy, the SCJ is inherently unstable. However, the strong costoclavicular and intraclavicular ligaments, as well as capsular support, render the SCJ extremely stable. Atraumatic SCJ subluxation/dislocation must be distinguished from traumatic injury, as the treatment strategies and outcomes are significantly different [9].

Physical examination typically reveals that the patient to be neurovascularly intact, with symmetric shoulder girdle appearance without any visible abnormalities, and full shoulder range of motion bilaterally. Active and passive abduction with forward flexion may provoke SCJ subluxation which was accompanied by an audible click. The shoulder examination also typically reveals glenohumeral joint multidirectional instability, with hyperlaxity also present at wrist, elbow, finger, knee, and ankle joints.

Radiographic evaluation of these cases includes standard three view radiographic examinations of the shoulder (ap, axillary lateral and scapular y views). In an office setting, the addition of a serendipity view as described by Rockwood [10] (Fig. 9.3) may be beneficial. Further radiographic studies should typically include a computerized tomogram (Fig. 9.4a, b). If there is a question of physeal injury, an MRI examination can separate the difference between physeal injury and subluxation/dislocation.

The differential diagnosis includes atraumatic subluxing SCJ, secondary to congenital multijoint hypermobility. Other diagnostic considerations to exclude would be ligamentous and bony abnormalities, including the growth plate, and degenerative or neoplastic lesions.

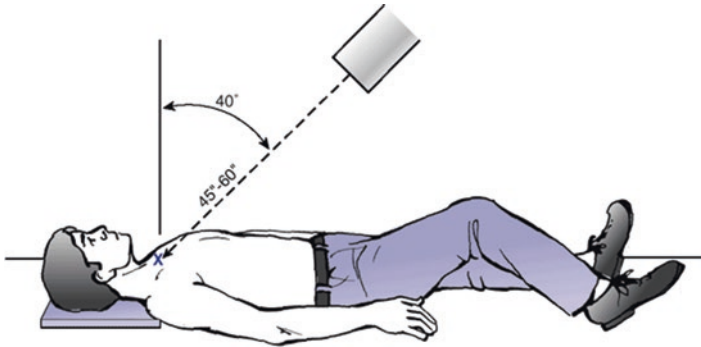


Fig. 9.3 Serendipity view may be beneficial

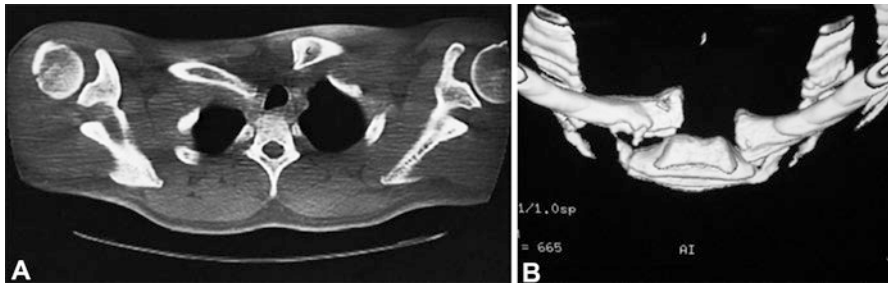


Fig. 9.4 (a) Computerized tomogram demonstrating a posterior dislocation. (b) 3 Dimensional image of a posterior sternoclavicular dislocation

Treatment

Most patients seek medical treatment because of initial pain and concern regarding the potential harm of the condition. In a review of 37 patients with spontaneous anterior subluxation of the sternoclavicular joint [11], subluxations were reproducible and painless in 29 patients. Eighty percent of the patients demonstrated evidence of generalized ligamentous laxity. Twenty-nine patients were treated nonsurgically with strengthening exercises and advancement to unrestricted activity as tolerated. Although many patients subsequently reported intermittent episodes, few reported discomfort, and most were able to participate successfully in athletics.

The most common reason for surgery was the failure of a previous attempt at reconstruction. Surgery is rarely indicated. Nonsurgical management, including patient education of the benign nature of the condition, is recommended [11]. For patients with continued symptoms in spite of physical therapy, sternoclavicular joint reconstruction with a figure-of-eight graft may be indicated. Short- and intermediate-term clinical results of this reconstruction [12] have shown promise. However, longer term studies are currently lacking regarding the durability of results. The surgical technique is described in the following section outlining anterior SC dislocation.

Strains and Subluxations

In a mild sprain, the ligaments of the sternoclavicular joint remain intact. The patient reports pain and tenderness with palpation over the joint. Swelling may be present, but no instability is noted. Swelling and pain become more pronounced as the ligaments are stretched, which results in subluxation of the joint. Pain is marked with motion of the ipsilateral extremity. Laxity of the joint may be apparent compared with the contralateral joint.

Dislocation

Severe pain and deformity accompany dislocations of the sternoclavicular joint. Surprisingly, clinical examination to determine the direction of the dislocation may be inconclusive because of swelling. In addition to swelling, compression of the vital structures posterior to the joint may occur with dislocation injuries. The orthopedic surgeon should keep this potential life-threatening complication in mind while performing the clinical evaluation.

Anterior sternoclavicular injuries may exhibit prominence of the medial clavicle. This prominence is more easily appreciated while the patient is in the supine position. Posterior dislocation is less common than anterior dislocation. Patients with posterior dislocation demonstrate a higher level of pain, and the corner of the sternum may be discerned as the medial clavicle is displaced posteriorly [7]. However, swelling may preclude an accurate clinical assessment of injury.

Patients with posterior displacement may report shortness of breath or difficulty breathing because of compression of the trachea or pneumothorax. Similarly, compression of the esophagus may result in dysphagia. Compression of the posterior vascular structures can result in decreased circulation to the ipsilateral extremity or venous congestion in the extremity or neck. Tingling or numbness may be the predominant complaint with compression of the brachial plexus. Posterior sternoclavicular dislocation or associated injuries may render the patient medically unstable.

Radiographic Evaluation

Routine radiographic studies of the sternoclavicular joint are difficult to interpret. Rockwood [10] developed an oblique view of the sternoclavicular joint dubbed the serendipity view. This radiograph is obtained by pointing the radiographic beam at a 40° angle tilted cephalic with the beam centered on the sternoclavicular joint. The resulting radiograph allows for comparison of the relationship of the injured clavicle to the normal clavicle. The technique is best suited for isolated sternoclavicular injuries.

Plain radiographic examination and oblique views have largely been supplanted with the availability of computerized tomograms. CT scanning is far superior technique over conventional radiographs to study any problems of the sternoclavicular

joint (Fig. 9.3). These scans easily distinguish sprains, dislocations, and medial clavicle fractures. In order to assist the radiologist, information pertaining to the history and mechanism of injury is provided. An accurate diagnosis is further facilitated by ensuring that the scan includes both medial clavicles so that the injured sternoclavicular joint can be compared to the opposite side. The examination should also include a CT of the chest to identify any associated injuries.

In children and young adults, MRI is especially helpful in distinguishing a dislocation of the sternoclavicular joint from a physeal injury. The ability of MRI to image soft tissue also allows assessment of the integrity of the costoclavicular ligament and attachments of the intra-articular disk. Imaging and location of the trachea, esophagus and great vessels are also available with MRI. CT examination is the imaging medium of choice in the acute situation due to its speed, availability, and ability to image bone injury.

Treatment

Anterior Strain/Subluxation

The utilization of ice and analgesics in the initial treatment of these injuries is advocated. Subluxations may be reduced by directing the shoulders posterior and medial. Support of the injury by utilization of a clavicle strap or sling and swath is typically useful. The patient is protected from injury using immobilization for 6 weeks after injury.

Anterior Dislocation

Closed reduction of anterior dislocation is the current treatment of choice although there is still some controversy regarding management [13, 14]. Closed reduction may be accomplished with sedation, local or general anesthesia. The patient is placed supine on a table with a 3 in. pad between the shoulders. Pressure is placed posteriorly on the medial clavicle. If the joint remains reduced, the patient is immobilized (figure-eight or velpeau type sling) for 6 weeks is utilized to allow healing.

Unfortunately, most anterior sternoclavicular dislocations are unstable after closed reduction, but if successful results in improved cosmesis. Anterior dislocations frequently will remain chronically unstable but generally do not deteriorate to debilitating symptoms [11, 15]. Good results have been shown with nonoperative treatment of asymptomatic anterior instability by physical therapy and activity modification. In rare instances, patients may develop painful crepitus with arm motion and pain that radiates into the neck, altering their ability to work and to participate in athletics [16, 17].

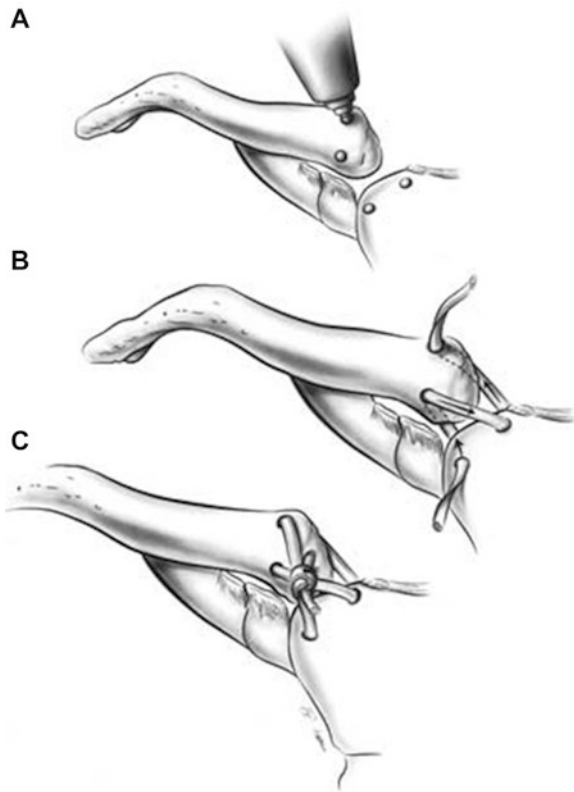
Although numerous methods of open reduction have been described [18–20], most injuries are asymptomatic. Surgical treatment remains controversial as indications and techniques continue to evolve. In 2004, Spencer and Kuhn [21] reported a

biomechanical study investigating the strength of a reconstructed sternoclavicular joint utilizing a figure-of-eight semi-tendinosis graft which demonstrated superior biomechanical properties. Multiple clinical studies have demonstrated good results utilizing the technique [22] with minor technical changes incorporated since the initial report including utilization of suture anchors and allograft tissue. Sabatini et al. [12] reported the most recent results of this technique in ten patients with significant improvements in pain scores and ASES scores with a minimum of complications.

Surgical Technique

The exposure for this technique reported by Sabatini et al. [12] is similar to what has been previously described [23–25] (Fig. 9.5). Briefly, the patient was placed in a supine position and prepared and draped (left shoulder and anterior chest), with the assistance of a cardiothoracic surgeon; a slightly angled transverse incision was made from the medial aspect of the clavicle to the manubrium. This area was then dissected, and the platysma was incised and raised, followed by elevation of periosteum off of the clavicle. The SCJ was visualized and the capsule reflected superiorly and inferiorly, providing room for the reconstruction.

Fig. 9.5 (a) Drilling holes in clavicle and sternum for the reconstruction. (b) Passing tendon reconstruction through holes. (c) Reconstruction is secured in a figure eight technique



Typically, it is necessary to elevate the soft tissues surrounding the manubrium with removal of the intra-articular disk. Once the approach had been completed and adequate deep visualization of the manubrium and the clavicle was obtained, the allograft was prepared. Typically, a 4.5-mm 25-cm semitendinosus allograft was used with No. 2 polyethylene suture on each end. Four drill holes were placed by a 4.5-mm drill with a cannulated system, 2 in the manubrium and 2 in the distal clavicle.

After this, the graft was shuttled in the sequential fashion from the inferior manubrial drill hole to the inferior clavicle back to the superior manubrial drill hole back to the superior clavicle drill hole.²⁷ With the graft tensioned, two 4.75-mm-diameter 15-mm-length PEEK tenodesis screws (Arthrex, Naples FL, USA) were then placed within the first (inferior manubrium) and fourth (superior clavicle) drill holes to secure the graft. After the placement of the tenodesis screws, two figure-of-eight stitches were placed with No. 2 polyethylene suture to secure the two sides of the graft to one another for additional support without the prominence of a knot of tied tendon. The suture knots were subsequently buried. The sternocleidomastoid, which was initially taken down, was then reapproximated with No. 1 Vicryl. The subcuticular layer was closed with 2-0 Vicryl (Ethicon, Somerville, NJ, USA), and then the skin with staples.

Postoperatively the patient is immobilized in a sling and allowed elbow and hand range of motion immediately postoperatively. Pendulum exercises are instituted within the first 2 weeks after surgery and passive range of motion exercises for the shoulder are continued through the sixth week after surgery. At this point, a gentle strengthening program is instituted and the sling may be discontinued. Activity restriction is typically enforced until 16 weeks after surgery and a return to sport may occur at 6 months postoperatively.

Posterior Dislocation

A careful history and physical examination of these injuries and a low threshold for the utilization of CT imaging is recommended. If evaluation reveals dyspnea, choking, or hoarseness, this indicates pressure on the mediastinum. Mediastinal involvement requires prompt consultation with a thoracic or cardiothoracic surgeon in the management of these individuals.

Closed Reduction

Open techniques are typically not required to reduce acute posterior sternoclavicular injuries. Further, once the reduction is achieved via closed reduction it is typically stable [26]. The authors have a thoracic surgeon available during closed reductions.

Technique

Under sedation or general anesthesia, the patient is placed supine on the operating room table. Folded towels or sandbags, 3–4 in. thick, are placed between the scapulae to extend the shoulders. The involved extremity is positioned near the edge of the table, allowing the arm to be extended and abducted (Fig. 9.6). Initially, gentle traction is applied to the abducted extremity in line with the clavicle while counter traction is applied by an assistant who steadies the patient. The traction on the arm is slowly increased while the arm is brought into extension. If this reduction technique fails [27], traction may be applied to the arm in adduction while a posterior pressure is applied to the shoulder in order to lever the clavicle over the first rib.

If the traction techniques are not successful, an assistant grasps and pushes down on the medial clavicle in an effort to dislodge it from the sternum. In cases of swelling, it may be impossible to grasp the medial clavicle. The skin is then surgically prepped, and a sterile towel clip is used to grasp the clavicle percutaneously (Fig. 9.7a, b). The clip will not penetrate the dense cortical bone of the clavicle, but instead is used to grasp completely around the clavicle. Traction through the effected limb combined with lifting anteriorly on the clavicle will usually reduce the dislocation. The reduction may be accompanied by an audible snap and can be noted visually or by palpation. The reduction should be confirmed with intraoperative radiographs and the authors recommend a figure-of-eight clavicle strap or sling to be used for 4 weeks to allow soft tissue healing based on our clinical experience.

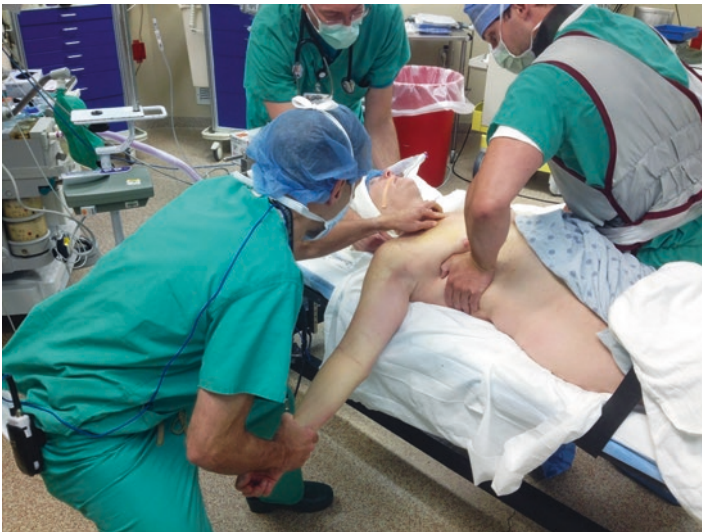

Fig. 9.6 Closed reduction maneuvers for treatment of a posterior sternoclavicular dislocation include positioning the extremity near the edge of the table, allowing the arm to be extended and abducted

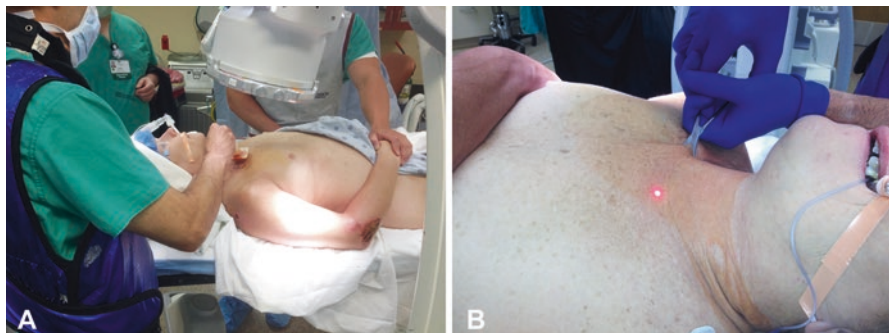


Fig. 9.7 A sterile towel clip is used to grasp the clavicle percutaneously spanning the width of the clavicle

Technique of Open Reduction

If closed reduction in adults over age 23 fails, open reduction is indicated. This treatment is necessitated since unreduced posterior dislocations are associated with numerous complications including thoracic outlet syndrome, vascular compromise, and erosion of the medial clavicle into vital posterior structures. These complications may arise acutely or from chronic posterior dislocations and are potentially life threatening.

Open reduction of the sternoclavicular joint should always be performed with a thoracic surgeon assisting or immediately available. The procedure is performed under general anesthesia with the patient supine and a bolster placed between the scapulae. The involved extremity is draped free to allow the intraoperative use of traction. A folded sheet should also be placed around the thorax which can be used to provide counter traction. An anterior incision which parallels the superior border of the medial clavicle over 5–7 cm and extends down the over the sternum is utilized. Preservation of as much anterior capsular structure as possible is the goal during exposure. After exposure has been obtained, a combination of traction/counter traction and lifting anteriorly on the medial clavicle with a clamp will result in reduction.

If enough anterior capsule has been preserved and undamaged from the initial injury, the reduction will be stable. Instability of the medial clavicle can be addressed by any number of surgical techniques [18–20]. Spencer and Kuhn [21] biomechanically described a figure-eight reconstruction utilizing a semitendinosus graft (Fig. 9.5). This reconstruction provided an initial stiffness close to that of the intact sternoclavicular joint.

Rockwood et al. addressed instability in this situation by resecting the medial clavicle and securing the residual clavicle anatomically to the periosteum of the first rib with 1 mm Dacron tape [28]. The medial clavicle is exposed subperiosteally (Fig. 9.8a–c). Any remnants of the intra-articular or capsular ligaments are identified and preserved. These structures are tagged with a 1 mm Dacron suture with the suture exiting the avulsed free end of the ligament. The medial clavicle is then

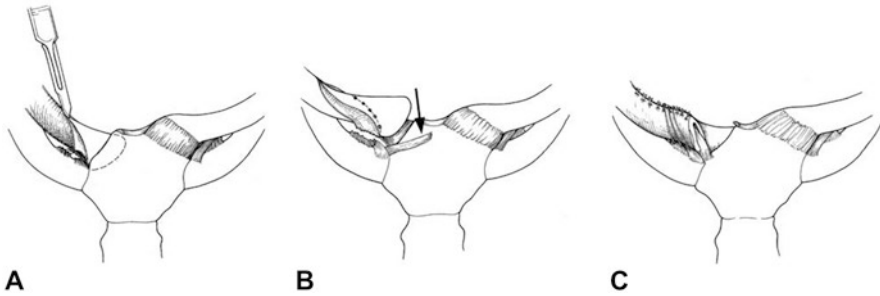


Fig. 9.8 (a–c) Subperiosteal exposure of the medial clavicle

resected protecting the posterior vascular structures with a curved Crego or ribbon retractor. The resection includes 1 centimeter of clavicle inferiorly and curves laterally to include two centimeters. Care should also be taken not to damage any remaining costoclavicular (rhomboid) ligament.

The medullary canal of the clavicle is now drilled and curetted to receive the transferred disk and capsular ligaments. Two superior holes are drilled in the clavicle 1 cm lateral to the resection. The free sutures are then shuttled through the medullary canal and out the drill holes to accept the sutures from the ligament transfer. With the clavicle held in a reduced position, the sutures are tied securing the transferred ligament into the clavicle.

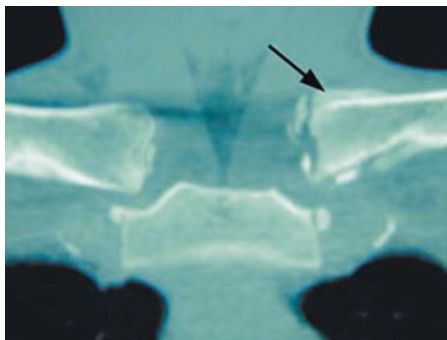
The procedure is completed by passing multiple 1 mm sutures around the reflected periosteal tube, clavicle and any residual costoclavicular ligament. These sutures restore the normal space between the clavicle and first rib. If the repair is tenuous, it may be augmented by the reconstruction method of Spencer and Kuhn [21]. Typically, the clavicular head of the sternocleidomastoid is detached as it is a superior deforming force on the medial clavicle.

Postoperatively, a figure-eight clavicle splint is utilized for 4 weeks in all open reductions or resections and followed by a sling for an additional 6–8 weeks. Patients should not elevate the arm over 60 degrees during this time frame and should use the extremity only for hygiene. After 12 weeks, patients are allowed to gradually increase the use of the arm for daily living activities. However, we do not recommend patients return to heavy labor activities if they have undergone medial clavicle resection. We have reported our results using this reconstruction technique. Excellent or good results were obtained in all patients [28].

Physeal Injuries of the Medial Clavicle

Closed reduction maneuvers described above are performed for anterior or posterior injury (Fig. 9.9). Open reduction of the physeal injury is seldom indicated, except for an irreducible posterior displacement with symptoms of compression of mediastinal structures. After reduction, a figure-eight splint is utilized for 4 weeks.

Fig. 9.9 CT examination demonstrating callous formation 6 weeks after trauma in this physeal injury of the sternoclavicular joint closed reduction maneuvers performed for anterior or posterior injury



Complications of Operative Procedures

Complications of surgical management [29–34] include postoperative infection, loss of reduction, and posttraumatic arthritis. The most serious complications have arisen from the utilization of pins that cross the sternoclavicular joint. The tremendous torque applied to these pins cause migration and fatigue failure of the hardware. The literature [30, 35–48] is replete with reports of migration (Fig. 9.10a–c) of intact or broken pins and wires into the heart, pulmonary artery, subclavian artery, innominate artery, spine, or aorta. No transfixing device, regardless of diameter, should be utilized across the sternoclavicular joint.

Illustrative Case

A 45-year-old right-hand-dominant woman was admitted to the general surgery service after a motorcycle accident. She complained of right arm pain and swelling. Her initial evaluation included radiographs of her right shoulder (Fig. 9.11) which were read by the radiologist as normal. She underwent an ultrasound of her right upper extremity which was also normal.

The orthopedic surgery service was asked to see her in consultation the next day. She continued to complain of right sided chest pain, swelling of her right arm and hoarseness. Her physical examination did not reveal any neurological defects. Her right arm was diffusely swollen (Fig. 9.12a, b), and she did have hoarseness with speech. The patient exhibited pain over the right sternoclavicular joint; however, due to swelling no further information could be gleaned by an examination. The patient was sent for an urgent CT of the chest.

The chest CT (Fig. 9.13) revealed a right posterior sternoclavicular dislocation. Due to the direction of the dislocation, compression of venous vessels and laryngeal nerve, she was scheduled urgently into the operating room. Under a general anesthetic with a thoracic surgeon available, a closed reduction was attempted (Fig. 9.6 and 9.7) which was unsuccessful. The patient's right chest was then sterilely prepped and a towel clamp was placed around the clavicle percutaneously which was also unsuccessful.

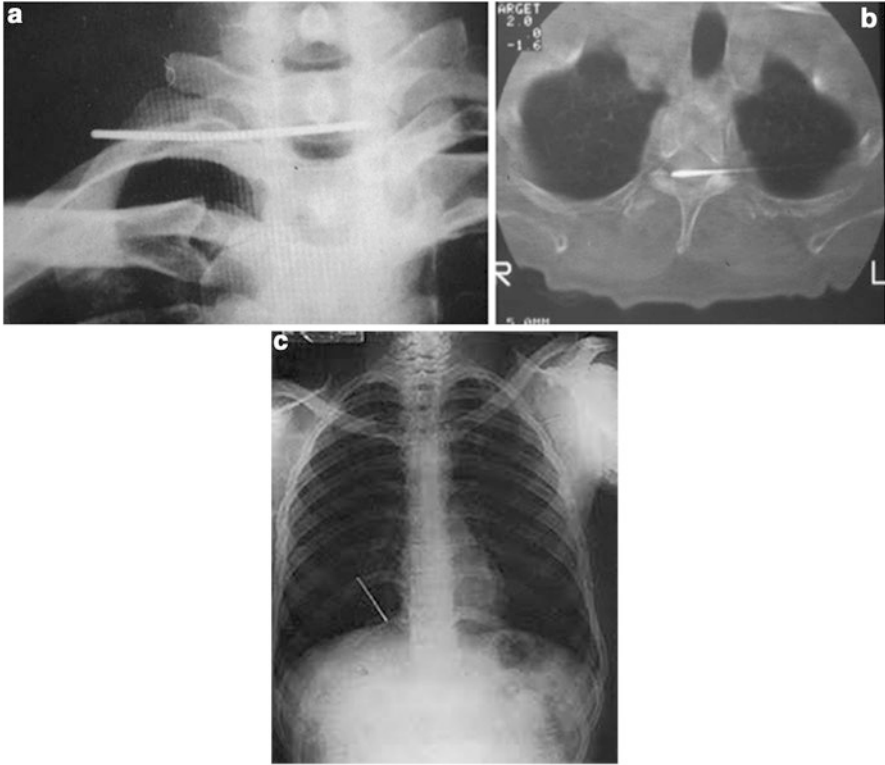
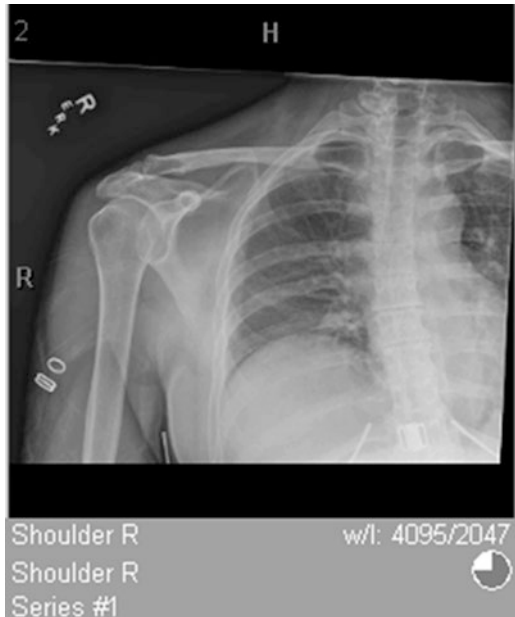

Fig. 9.10 Migration of intact or broken pins and wires into the heart, pulmonary artery, subclavian artery, innominate artery, or aorta have been reported

Fig. 9.11 Right shoulder radiographs of a 45-year-old right-hand-dominant woman admitted to the general surgery service after a motorcycle accident



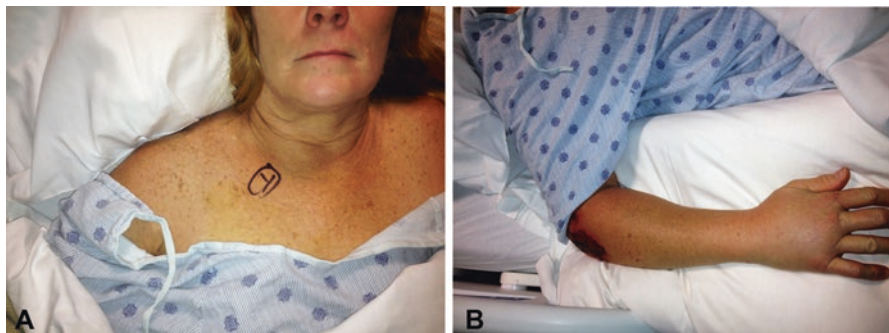
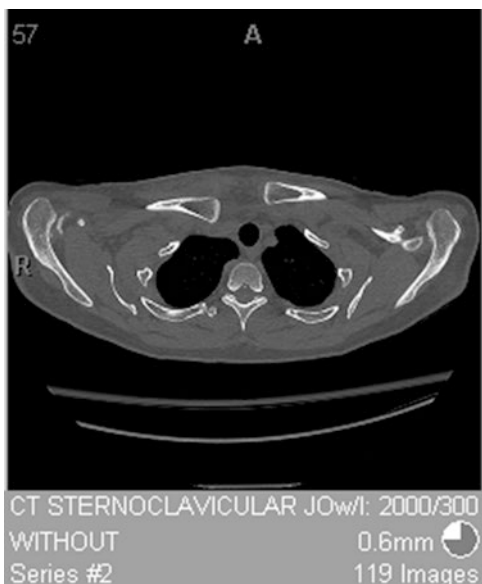
Fig. 9.12 Diffusely swollen right arm. Patient exhibited pain over the right sternoclavicular joint

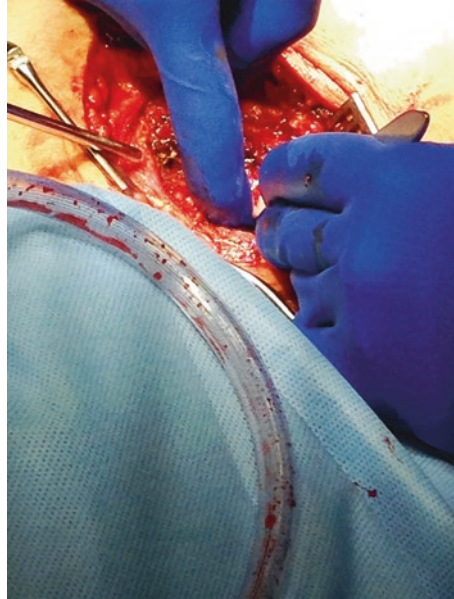Fig. 9.13 Chest CT revealing a right posterior sternoclavicular dislocation



The patient's entire chest was now prepped and draped. An open reduction of the right sternoclavicular joint was performed with assistance from the thoracic surgeon (Fig. 9.14). The reduction was stable and supplemented by the thoracic surgeon with wire suture. Intraoperative fluoroscopy demonstrated reduction, and the wound was closed in layers. The patient was placed in a sling and taken to the recovery room. Postoperative imaging confirmed anatomic reduction (Fig. 9.15a, b).

Examination of the patient on postoperative day 1 revealed resolution of her hoarseness and marked improvement of her right arm swelling (Fig. 9.16). She was discharged in her sling and kept her postop visit in 2 weeks at which time her sutures

Fig. 9.14 Open reduction of the right sternoclavicular joint with assistance from the thoracic surgeon. Reduction was stable and supplemented by the thoracic surgeon with wire suture



were removed, and she began a passive range of motion program for her shoulder. At 6 weeks postoperatively she began a strengthening program. At her 12-week visit, she demonstrated full motion without pain and had returned to her previous employment (Fig. 9.17).

Summary

Sternoclavicular injuries are rare events, but can be associated with grave short- and long-term complications. Anterior injuries are typically unstable even after reduction, but well tolerated. Most patients after anterior dislocation are asymptomatic, and the majority improve with physical therapy. Operative indications and techniques continue to evolve, but typically involve a figure-of-eight tendon reconstruction of the sternoclavicular joint. Few patients after anterior dislocation may develop late degenerative changes and can be treated with medial clavicle excision and ligament reconstruction.

Posterior sternoclavicular dislocations can be immediately associated with pneumothorax, laceration, or occlusion of the great vessels, rupture of the esophagus, brachial plexus compression, and recurrent laryngeal nerve injury. Late complications of retrosternal dislocation can include tracheoesophageal fistula, stridor, and dysphagia. Proper physical examination to detect these complications is of importance in evaluating every patient with a sternoclavicular joint injury.

Plain radiographs have been largely supplanted by CT examination for viewing bony detail. The medial clavicular physis does not close until age 23 and MRI examination may be extremely helpful in differentiating a physeal injury from a sternoclavicular dislocation, in the nonacute setting. Physeal injuries can typically

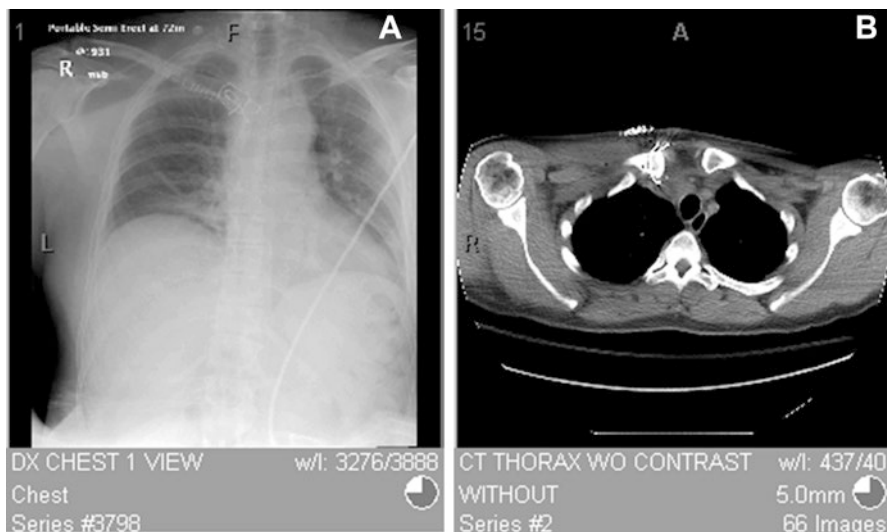


Fig. 9.15 Postoperative imaging confirmed anatomic reduction

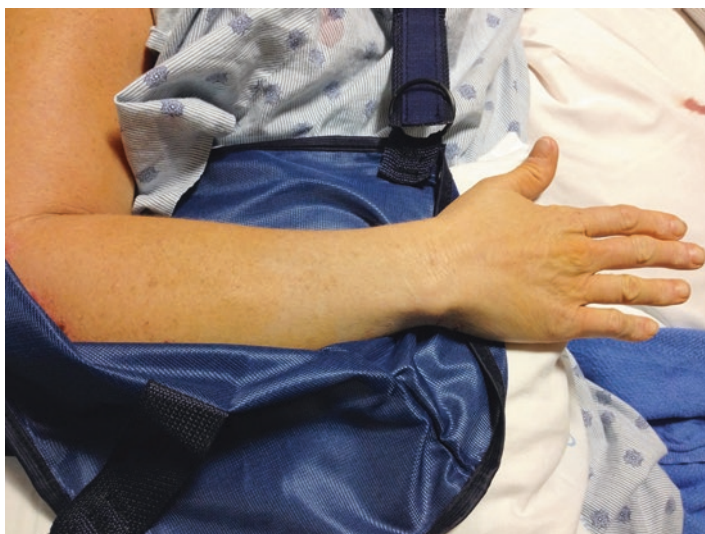

Fig. 9.16 Examination on postoperative day 1 revealed resolution of hoarseness and marked improvement of right arm swelling

be managed with closed reduction alone and rarely require open reduction except for irreducible posterior dislocations in the face of mediastinal compression.

In contrast to anterior dislocations, acute posterior dislocations are typically amenable to closed reduction and are stable after reduction. Because of the

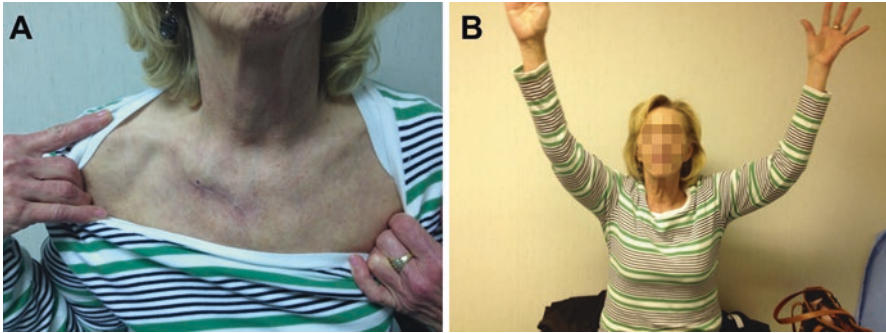


Fig. 9.17 Twelve weeks after procedure, patient demonstrated full motion without pain

possibility of late life-threatening complications, all unreduced posterior dislocations should be operatively reduced with a thoracic surgeon present. Resection of the medial clavicle and reconstruction of the costoclavicular ligaments have yielded good results. No transfixing pins should ever be utilized at the sternoclavicular joint.

References

1. Cave EF. Fractures and other injuries. Chicago: Year Book; 1958.
2. Webb PAO, Suchey JMM. Epiphyseal union of the anterior iliac crest and medial clavicle in a modern multiracial sample of American males and females. *Am J Phys Anthropol.* 1985;68:457–66.
3. Bearn JG. Direct observations on the function of the capsule of the sternoclavicular joint in clavicular support. *J Anat.* 1967;101:159–70.
4. Mehta JC, Sachdev A, Collins JJ. Retrosternal dislocation of the clavicle. *Injury.* 1973;5:79–83.
5. Hening CF. Retrosternal dislocation of the clavicle: early recognition, xray diagnosis and management. *J Bone Joint Surg Am.* 1968;50:830.
6. Nettles JL, Linscheid R. Sternoclavicular dislocations. *J Trauma.* 1968;8:158–64.
7. Waskowitz WJ. Disruption of the sternoclavicular joint: an analysis and review. *Am J Orthop.* 1961;3:176–9.
8. Omer GE. Osteotomy of the clavicle in surgical reduction of anterior sternoclavicular dislocation. *J Trauma.* 1967;7:584–90.
9. Hiramuro-Shoji F, Wirth MA, and Rockwood CA. Jr. Atraumatic conditions of the sternoclavicular joint. *J Shoulder Elbow Surg.* 2003;12:79–88 doi:[10.1067/mse.2003.128566](https://doi.org/10.1067/mse.2003.128566).
10. Wirth MA, Rockwood CA. Disorders of the sternoclavicular joint. In: Rockwood CA, Matsen FA, Wirth MA, Lippitt SB, editors. *The shoulder.* Philadelphia: Saunders. p. 527–60.
11. Rockwood Jr CA, Odor JM. Spontaneous atraumatic anterior subluxation of the sternoclavicular joint. *J Bone Joint Surg Am.* 1989;71:1280–6.
12. Sabatini JB, et al. Outcomes of augmented allograft figure of eight sternoclavicular joint reconstruction. *J Shoulder Elbow Surg.* 2015;24:902–907.
13. Fery A, Sommelet J. Dislocation of the sternoclavicular joint: a review of 49 cases. *Int Orthop.* 1988;12:187–95.
14. de Jong KP, Sukul DM. Anterior sternoclavicular dislocation: a long-term follow-up study. *J Orthop Trauma.* 1988;4:420–3.

15. Thut D, Hergan D, Dukas A, Day M, Sherman OH. Sternoclavicular joint reconstruction—a systematic review. *Bull NYU Hosp Jt Dis.* 2011;69:128–35.
16. Bicos J, Nicholson GP. Treatment and results of sternoclavicular joint injuries. *Clin Sports Med.* 2003;22:359–70.
17. Kibler WB, Sciascia A. Current concepts: scapular dyskinesis. *Br J Sports Med.* 2010;44:300–5. doi:[10.1136/bjsm.2009.058834](https://doi.org/10.1136/bjsm.2009.058834).
18. Bankart ASB. An operation for recurrent dislocation (subluxation) of the sternoclavicular joint. *Br J Surg.* 1938;26:320–3.
19. Key JA, Conwell HE. The management of fracture, dislocations, and sprains. 5th ed. St. Louis: CV Mosby; 1951. p. 458–61.
20. Burrows HJ. Tenodesis of subclavis in the treatment of recurrent dislocation of the sternoclavicular joint. *J Bone Joint Surg Br.* 1951;33:240–3.
21. Spencer EE, Kuhn JE. Biomechanical analysis of reconstructions for sternoclavicular joint instability. *J Bone Surg Am.* 2004;86:98–105.
22. Kawaguchi K, Tanaka S, Yoshitomi H, Nagai I, Sato W, Karita T, et al. Double figure-of-eight reconstruction technique for chronic anterior sternoclavicular joint dislocation. *Knee Surg Sports Traumatol Arthrosc.* 2014; doi:[10.1007/s00167-014-2979-4](https://doi.org/10.1007/s00167-014-2979-4).
23. Bak K, Fogh K. Reconstruction of the chronic anterior unstable sternoclavicular joint using a tendon autograft: medium-term to long-term follow-up results. *J Shoulder Elbow Surg.* 2014;23:245–50. doi:[10.1016/j.jse.2013.05.010](https://doi.org/10.1016/j.jse.2013.05.010).
24. Gaines RJ, Liporace FA, Yoon RS, DeMaio M. A novel technique for ligamentous reconstruction of the sternoclavicular joint. *J Orthop Trauma.* 2014;28:e65–9. doi:[10.1097/BOT.0b013e31829aa9c5](https://doi.org/10.1097/BOT.0b013e31829aa9c5).
25. Uri O, Barmpagiannis K, Higgs D, Falworth M, Alexander S, Lambert SM. Clinical outcome after reconstruction for sternoclavicular joint instability using a sternocleidomastoid tendon graft. *J Bone Joint Surg Am.* 2014;96:417–22. doi:[10.2106/JBJS.M.00681](https://doi.org/10.2106/JBJS.M.00681).
26. Groh GI, Wirth MA, Rockwood CA. Treatment of traumatic posterior sternoclavicular joint injuries. *J Shoulder Elbow Surg.* 2011; doi:[10.1016/j.jse.2010.03.009](https://doi.org/10.1016/j.jse.2010.03.009).
27. Buckerfield CT, Castle ME. Acute traumatic retrosternal dislocation of the clavicle. *J Bone Joint Surg Am.* 1984;66:379–84.
28. Rockwood CA, Groh GI, Wirth MA, Grassi FA. Resection arthroplasty of the sternoclavicular joint. *J Bone Joint Surg Am.* 1997;79:387–93.
29. Wirth MA, Rockwood CA. Complications following repair of the sternoclavicular joint. In: Bigliani LU, editor. *Complications of the shoulder.* Baltimore: Williams & Wilkins; 1993. p. 139–53.
30. Brown JE. Anterior sternoclavicular dislocation—a method of repair. *Am J Orthop.* 1961;31:184–9.
31. Eskola A, Vainionpaa S, Vastamaki M, et al. Operation for older sternoclavicular dislocation. Results in 12 cases. *J Bone Joint Surg Br.* 1989;71:53–5.
32. Lunseth PA, Chapmen KW, Frankel VJ. Surgical treatment of chronic dislocation of the sternoclavicular joint. *J Bone Joint Surg Br.* 1975;57:193–6.
33. Ge O. Osteotomy of the clavicle in surgical reduction of anterior sternoclavicular dislocation. *J Trauma.* 1967;7:584–90.
34. Groh GI, Wirth MA. Management of traumatic sternoclavicular joint injuries. *J Am Acad Orthop Surg.* 2010;19(1):1–7.
35. Clark RI, Milgram JW, Yawn DH. Fatal aortic perforation and cardiac tamponade due to a Kirshner wire migrating from the right sternoclavicular joint. *South Med J.* 1974;67:316–8.
36. Gerlach D, Wemhoner SR, Ogbuihi S. On two cases of fatal heart tamponade due to migration of fracture nails from the sternoclavicular joint. *Z Rechtsmed.* 1984;93:53–60.
37. Leonard JW, Gifford RW. Migration of a Kirshner wire from the clavicle into pulmonary artery. *Am J Cardiol.* 1965;16:598–600.
38. Richman KM, Boutin RD, Vaughan LM, et al. Tophaceous pseudogout of the sternoclavicular joint. *AJR Am Roentgenol.* 1999;172:1587–9.

39. Smolle-Juettner FM, Hofer PH, Pinter H, et al. Intracardiac malpositioning of a sternoclavicular fixation wire. *J Orthop Trauma*. 1992;6:102–5.
40. Worman LW, Leagus C. Intrathoracic injury following retrossternal dislocation of the clavicle. *J Trauma*. 1967;7:416–23.
41. Pate JW, Wilhite J. Migration of a foreign body from the sternoclavicular joint to the heart: a case report. *Am Surg*. 1969;35:448–9.
42. Song HK, Sloane G, Kaiser LR, Shrager JB. Current presentation and optimal surgical management of sternoclavicular joint infections. *Ann Thorac Surg*. 2002;73:427–31.
43. Nordback I, Markkula H. Migration of Kirschner pin from clavicle into ascending aorta. *Acta Chir Scand*. 1985;151:177–9.
44. Jelesijevic V, Knoll D, Klinke F, et al. Penetrating injuries of the heart and intrapericardial blood vessels caused by migration of a Kirshner pin after osteosynthesis. *Acta Chir Jugosl*. 1982;29:274.
45. Liu HP, Chang CH, Lin PJ, et al. Migration of Kirshner wire for the right sternoclavicular joint into the main pulmonary Artery: a case report. *Chang Gung Med J*. 1992;15:49–53.
46. Rubenstein ZR, Moray B, Itzhak Y. Percutaneous removal on intravascular foreign bodies. *Cardiovasc Intervent Radiol*. 1982;5:64–8.
47. Schechter DC, Gilbert L. Injuries of the heart and great vessels due to pins and needles. *Thorax*. 1969;24:246–53.
48. Sethi GK, Scott SM. Subclavian artery laceration due to migration of a Hagie pin. *Surgery*. 1976;80:644–6.

Chapter 10

Distal Clavicle and Medial Clavicle Fractures

Michael D. McKee and Justin L. Hodgins

Abbreviations

AC	Acromioclavicular
AP	Anteroposterior
CC	Coracoclavicular
CT	Computed tomography
MRI	Magnetic resonance imaging
ROM	Range-of-motion
SC	Sternoclavicular

Medial Clavicle Fractures

Fractures of the medial or proximal third of the clavicle are rare and comprise 2–4% of all clavicle fractures [1–6]. Medial fractures are less likely to be displaced compared to those of the diaphysis, seldom involve the sternoclavicular (SC) joint, and most often are treated nonoperatively [1, 5, 7]. Operative treatment is reserved for select clinical scenarios given the proximity of critical anatomic structures and the potential for catastrophic intraoperative complications. This includes open fractures, fractures with neurovascular compromise threatening mediastinal contents and highly unstable bipolar clavicle fractures [8–10].

M.D. McKee, M.D. (✉)

Division of Orthopaedics, Department of Surgery, St. Michael's Hospital,
University of Toronto, 55 Queen Street East, Suite 800, Toronto, ON, Canada, M5C 1R6
e-mail: McKeeM@smh.ca

J.L. Hodgins, M.D.

Upper Extremity Reconstruction and Trauma, St. Michael's Hospital,
University of Toronto, 55 Queen Street East, Suite 800, Toronto, ON, Canada, M5C 1R6
e-mail: jhodgins117@gmail.com

Applied Anatomy

The clavicle is the first bone to ossify during the 10th week of gestation and it also contains the last ossification center to fuse in the human body; the medial ossification center adjacent to the SC joint [11]. The delayed fusion of the medial physis occurs well after 20 years of age and explains the pathophysiology behind adolescent physeal separation injuries [11, 12].

The medial third of the clavicle has a relatively flat superior border and articulates with the sternum through strong capsuloligamentous attachments at the SC joint and first rib. This extensive ligamentous support is partly responsible for the undisplaced nature of most medial clavicle fractures. Medial attachments include the sternocleidomastoid, the pectoralis major, and sternohyoid muscles. In displaced midshaft fractures, the sternocleidomastoid muscles produce the major superomedial deforming force on the medial fragment [13]. The medial clavicle is an important structural support protecting neurovascular and airways structures. The brachial plexus and the subclavian vessels transverse towards the axillae under the middle third of the clavicle and the carotid and jugular vessels are protected by the adjacent SC joint [14].

Clinical Evaluation

Most patients have a history of a direct fall onto the shoulder girdle [1, 3–6]. The strong ligamentous attachments combined with less exposure to direct trauma make injuries to the medial clavicle far less common than those of the middle or lateral third. However, a high clinical suspicion is required in the context of the high-energy or multisystem trauma patient. For instance, a large retrospective review reported 84% of patients with medial clavicle injuries were involved in motor vehicle collisions, and 90% had multisystem trauma [15]. Due to the close anatomic relationship between the medial clavicle and neurovascular structures, numerous cases of concomitant scapular, intrathoracic, subclavian vessel, and brachial plexus injuries have been reported in high-energy clavicle fractures [14, 16–19].

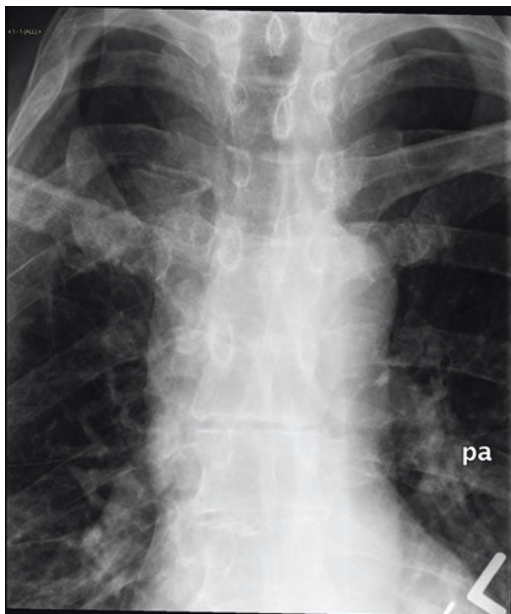
Physical examination findings include swelling, ecchymosis, and tenderness over the medial clavicle and SC joint. Asymmetric posturing of the ipsilateral shoulder or droop may be present. Anteriorly displaced fragments may be associated with deformity in the form of a palpable bony prominence. When posterior displacement is suspected, patients should be examined for evidence of dyspnea, dysphagia, tachypnea, and stridor. Injury to the subclavian vessels may manifest as an expanding hematoma at the fracture site [18]. Assessment should include inspection for a local bruit, diminished or absent distal pulses and asymmetric blood pressure. A thorough neurological examination of the shoulder and the upper extremity should be performed and documented.

Radiographic Evaluation

In addition to dedicated shoulder films, routine radiographs include full-length anteroposterior (AP) views of the clavicle containing both the SC and acromioclavicular (AC) joints. To best visualize fractures and/or dislocations involving the medial third of the clavicle, the serendipity view has a 40° cephalic tilt directed at the SC joints allowing comparison of both SC joints (Fig. 10.1). The distal fragment tends to sag with the weight of the arm and the proximal fragment attached to the SC joint appears superiorly.

The interpretation of medial clavicle fractures using plain radiographs is often challenging and computed tomography (CT) is the preferred modality (Fig. 10.2). Axial CT imaging of bilateral SC joints can better delineate fracture displacement and the proximity of close neurovascular structures for surgical planning. CT scans can also differentiate medial physeal separations from true SC joint dislocations which may have treatment and prognosis implications. These are often Salter-Harris II physeal injuries with posterior displacement of the lateral fragment. CT scans are essential in identifying the often small, poorly visualized metaphyseal bone fragment still aligned with the sternum [20, 21]. These injuries can be a diagnostic challenge often having a delayed presentation and diagnosis in as many as 57% of cases [22–25].

Fig. 10.1 Serendipity radiographic view of bilateral SC joints. A malunion of the right medial clavicle is present although difficult to appreciate



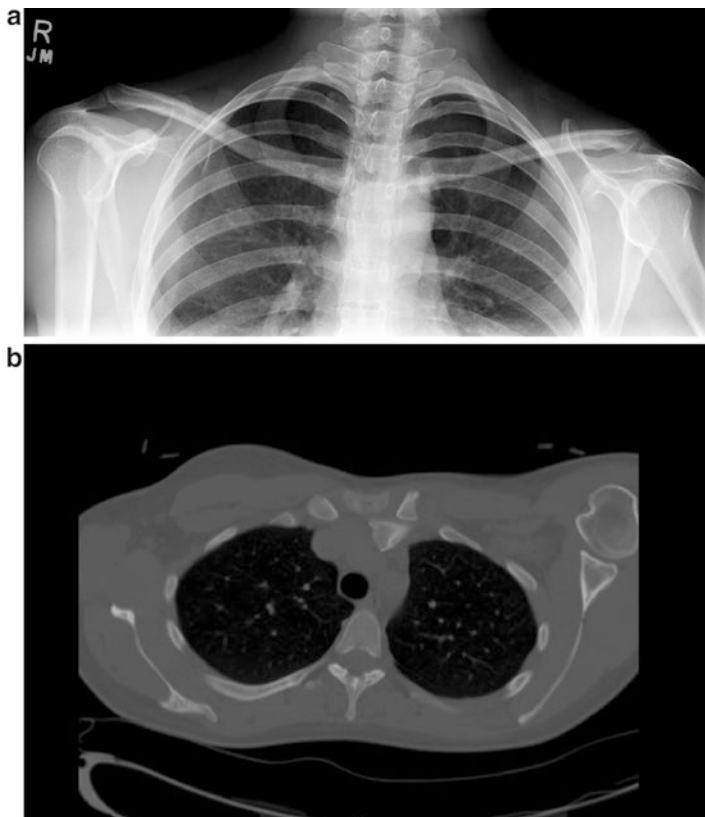


Fig. 10.2 (a) Radiograph of bilateral full-length clavicles demonstrating subtle fracture of the left proximal clavicle. (b) Axial CT scan of same patient demonstrating physeal fracture of medial clavicle with significant posterior displacement of lateral fragment in close proximity of mediastinal structures

As an alternative, MRI (magnetic resonance imaging) affords good visualization without the risk of radiation exposure associated with CT. Assessment of the sternoclavicular joint congruity and underlying mediastinal compression are best viewed in the axial plane [26]. A high clinical suspicion is required when evaluating for medial physeal injuries as they are commonly misdiagnosed as SC joint dislocations despite advanced imaging [27].

In the high-energy trauma patient, careful radiological assessment of the shoulder girdle is necessary to rule out concomitant injuries to the scapula and glenoid [28]. An AP chest film is critical as part of a trauma series and may identify associated rib fractures or potentially life-threatening intrathoracic injuries such as pneumo or hemothoraces. A CT angiogram is also a valuable adjunct when a distal vascular deficit is detected following a high-energy clavicle fracture.

Management

Traditionally, fractures of the medial clavicle have been treated nonoperatively, even when significantly displaced. The risk of damage to neurovascular and airway structures combined with the relative infrequency of the injuries has led many authors to advocate for conservative measures [12, 15, 29–33]. This typically includes a brief period of shoulder immobilization for 2–6 weeks followed by a structured rehabilitation program. The results of nonsurgical treatment for medial clavicle injuries are in general satisfactory although the low prevalence of these fractures and retrospective nature of most reports precludes a detailed analysis [4, 9]. In addition, confounding variables including severe neurovascular or visceral injuries in polytrauma patients complicate the analysis of clinical outcomes [18].

Nonunion rates between 4 and 8% have been reported; however, the nonunion rate for patients with displaced medial-end fractures may be as high as 14% [4, 5] (Fig. 10.3). Nonunion has been associated with significant pain, loss of function,

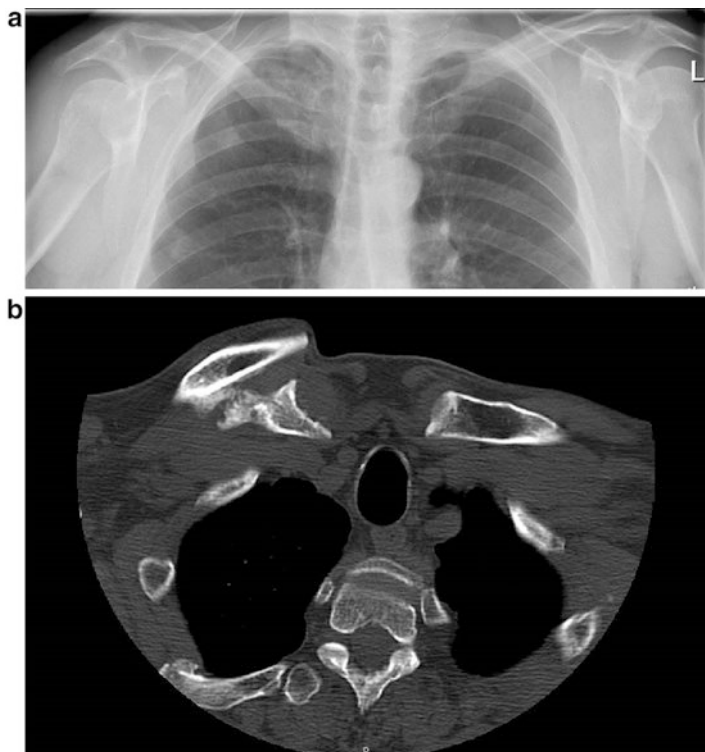


Fig. 10.3 (a) Radiograph of bilateral full-length clavicles demonstrating right medial clavicle nonunion. (b) Axial CT scan of same patient demonstrating nonunion of right medial clavicle

limb weakness, and pectoral muscle dysfunction [4, 9, 34]. Therefore, in select clinical settings, open reduction and internal fixation of displaced medial fractures has been described and recommended [8, 10, 24, 35–37]. This also includes retrosternal SC dislocations or adolescent medial epiphyseal separations compromising mediastinal structures [7, 24, 35, 38] and case reports of highly unstable bipolar clavicle injuries with segmental fractures involving both the medial and lateral thirds of the clavicle [8, 10].

Adult-type displaced medial fractures are typically treated with anatomic reduction with plate and screw fixation. Excellent functional outcomes and low complication rates have been reported in this population [25, 39, 40]. Cases of hardware failure are rare although patients often have mild symptoms of plate irritation [25]. Open reduction and transosseous suture techniques are used in the operative treatment of displaced physal injuries [25]. This avoids significant disruption to the physis and does not typically have the issues with hardware irritation, migration, and subsequent removal as previous techniques using Kirschner wires or metal sutures [41–43]. Excellent long-term functional results with low complications have been reported using transosseous suture techniques [24, 25, 36].

Preferred Surgical Technique

The senior author's treatment of choice for displaced fractures of the medial clavicle is anatomic reduction and plate fixation. Fracture pattern and the size of the medial fragment determine whether the fixation spares or spans the SC joint. A cardiac surgeon is present and available in the event of an intrathoracic vascular injury

After a general anesthetic, the patient is placed in the modified beach-chair position with the head secured on a headrest. The entire chest and upper portion of the abdomen are prepared and draped to allow for possible sternotomy in an emergency situation. The authors do not routinely free-drape the arm. The incision is made directly over the SC joint at the level of the fracture and extended laterally in line with the shaft of the clavicle. A single, thick subcutaneous tissue flap is elevated exposing the underlying myofascial layer. This layer is divided sharply down to the clavicle and SC joint and is elevated off the bone as a single layer that can be later closed over the plate. If a traumatic tear or "rent" exists in the fascia, this instead is utilized and extended.

The fracture site is then exposed and inspected. Hematoma and interposed soft tissue are carefully debrided. Depending on fracture type, a medial fracture fragment is usually attached to the SC joint with adjacent displacement of the shaft portion of the clavicle. Tissue is carefully released using blunt dissection from the inferior and superior borders of the displaced fragment. A sharp reduction forcep is used to gently reduce the lateral clavicle to the medial portion. The reduction is held provisionally with fracture reduction forceps.

If a large proximal fragment exists, adequate fixation may be achieved with multiple 3.5 mm cancellous screws secured through a 3.5 mm non-locking plate. When a small medial fragment is encountered or additional fixation is required, the construct should span the SC joint. Bicortical screws in the sternum and clavicle are desired and uncontrolled plunging with the drill or depth gauge must be avoided. Since the procedure is typically reserved for young, active patients, bone quality is rarely an issue, and the authors have not found locking plates to be required or useful in this setting. A one-third tubular plate is typically used.

If damaged, the anterior capsuloligamentous attachments of the SC joint should be repaired using a strong nonabsorbable suture. The surgical site is thoroughly irrigated and a two-layer closure of the soft tissues is performed to maximize local resistance to infection and minimize the potential for hardware irritation. The myofascial layer is sutured with #1 absorbable suture and the skin with 3-0 monofilament sutures. Absorbable subcutaneous sutures are avoided to minimize the risk of tissue reaction or stitch abscesses.

The patient wears a simple sling for comfort and can begin range-of-motion (ROM) exercises in the immediate postoperative period. The use of the sling is discontinued after 10–14 days and strengthening exercises are initiated at 6 weeks postoperatively.

Illustrative Cases

Case 1

An 18-year-old male was seen in consultation for a left shoulder girdle injury he sustained while snowboarding. He landed on his left shoulder from a height of 10 ft when attempting a jump. He complained of isolated left chest discomfort and denied any difficulty breathing or swallowing. Upon physical examination, there was an anterior prominence of the proximal left clavicle with a significant amount of swelling and ecchymosis. The area was tender and he is neurologically intact.

CT scan of bilateral SC joints identifies an anterior fracture-dislocation of the left SC joint with anterior displacement of the residual shaft fragment (Fig. 10.4).

Management options included nonoperative treatment with a period of sling immobilization followed by early ROM and then strengthening at 6 weeks. This would include accepting the current deformity and asymmetry of the chest wall and the potential for a symptomatic nonunion. Open reduction and internal fixation would aim to correct the deformity and minimize the risk of nonunion. In addition to routine surgical risks of an open procedure, there was the remote possibility life-threatening hemorrhage.

The patient was managed operatively with open reduction and internal fixation with plate and screw fixation. A “T-shaped” plate was utilized and screw purchase in the large medial fragment was sufficient and therefore the SC joint was spared (Fig. 10.5).

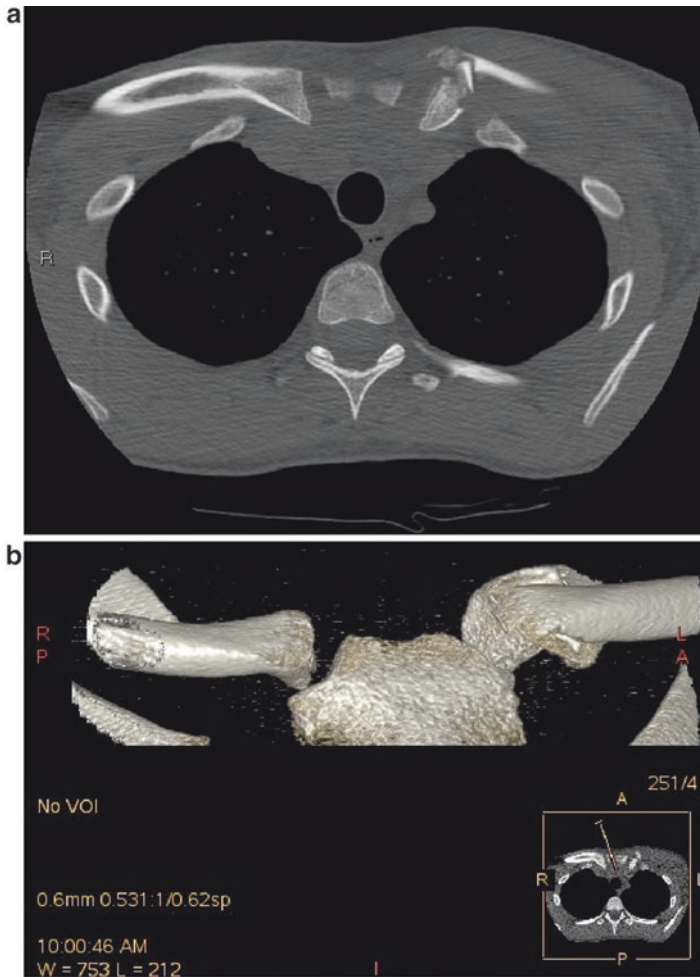


Fig. 10.4 (a) Axial CT scan of bilateral sternoclavicular joints demonstrating an anterior fracture-dislocation on the left side. (b) 3D CT scan reconstruction of same patient demonstrating left SC fracture-dislocation

Case 2

A 13-year-old male was seen in consultation for a right shoulder girdle injury he sustained while playing tackle football. He was hit from standing height and forcefully landed on his left shoulder with his arm adducted. He had pain along his right medial chest wall and was reluctant to move his right shoulder. He denied difficulty breathing or swallowing. Upon physical examination, there was an obvious asymmetry in the appearance of his right medial clavicle and his right shoulder appeared internally rotated. There was no significant swelling or ecchymosis and he was neurovascular intact distally.

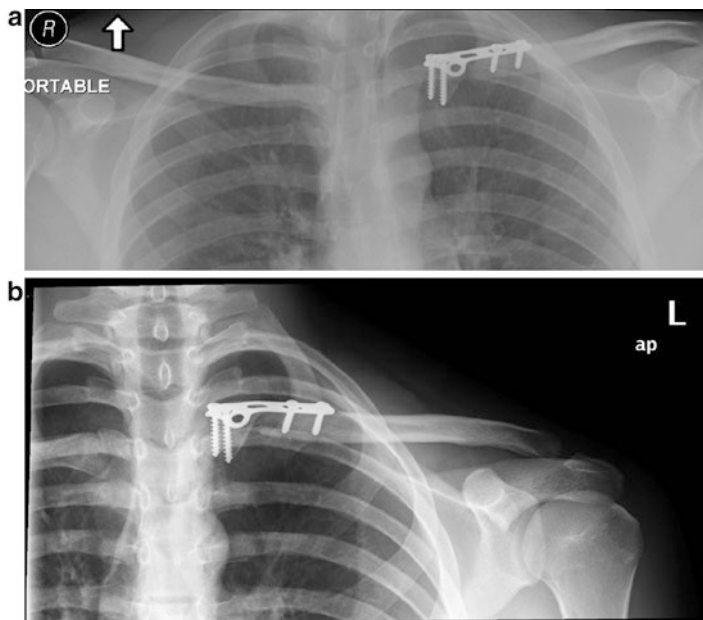


Fig. 10.5 (a) Postoperative radiograph of chest after open reduction and internal fixation with plate and screw fixation of the left medial clavicle. (b) AP radiograph of left clavicle after open reduction and internal fixation

Right clavicle radiographs and axial CT scan of the SC joint demonstrated a significantly displaced fracture of the medial clavicle with the residual epiphyseal fragment attached to the SC joint (Fig. 10.6).

Given the degree of displacement resulting in shortening and deformity of the shoulder girdle and the close proximity of mediastinal structures to the displaced fragment, operative treatment was chosen.

The patient underwent open reduction and internal fixation with plate and screw fixation. Due to the small size of the epiphyseal fragment, an SC spanning construct was utilized for adequate fixation (Fig. 10.7).

Distal Clavicle Fractures

Distal clavicle fractures account for 10–30% of all clavicle fractures [1, 2, 4, 5, 16]. The majority of these fractures are nondisplaced or minimally displaced, extra-articular, and are typically managed nonoperatively [1, 4]. A particular subset of distal clavicle injuries are inherently unstable, prone to displacement, and are at risk for delayed or nonunion [44]. Distinguishing the subtle variations in fracture pattern stability can be challenging and ultimately guides treatment decisions. However, nonunions are often asymptomatic, particularly in elderly and sedentary individuals, and the preferred operative fixation remains controversial [34, 45].

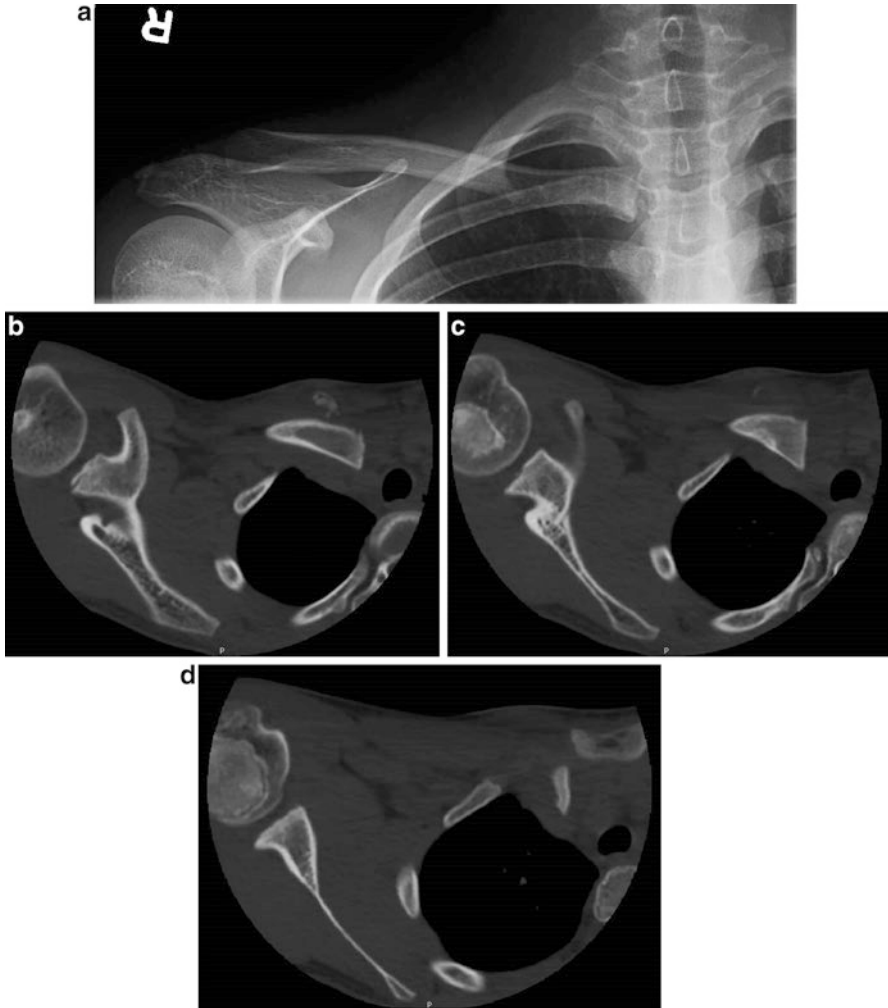


Fig. 10.6 (a) Right clavicle radiograph of subtle posterior physal separation of medial clavicle. (b–d) Unilateral CT scan demonstrating posteriorly displaced physal separation of right medial clavicle

Applied Anatomy

The clavicle widens along its acromial end and the lateral third contains the apex of the superior bow of the clavicle. The clavicle acts as a strut connecting the shoulder girdle to the axial skeleton and scapulothoracic motion is dependent on the stable relationship between the distal clavicle and scapula [44]. The distal clavicle is anchored solidly to the scapula by the AC capsuloligament and the coracoclavicular (CC) ligaments. The AC capsuloligament complex spans the AC joint and attaches to the distal aspect of the clavicle 6 mm medial to the AC joint [4]. The AC ligament

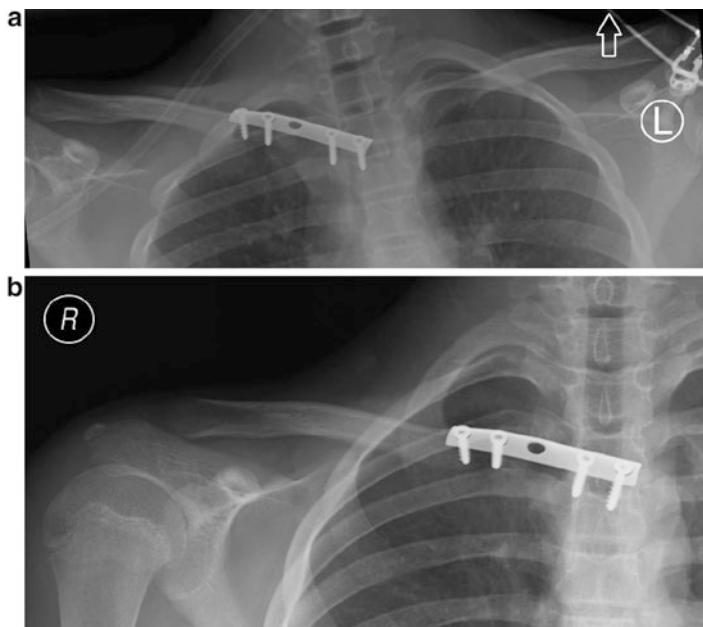


Fig. 10.7 (a) Postop chest radiograph after open reduction and internal fixation of the right medial clavicle. (b) AP of right clavicle after open reduction and internal fixation with plate and screws

and joint capsule are important stabilizers in the horizontal plane of motion [46]. The CC ligaments consist of the trapezoid and conoid ligaments which originate from the base of the coracoid process and attach on the inferior boarder of the distal clavicle and provide vertical stability. The trapezoid ligament originates more lateral attaching to the clavicle approximately 2 cm from the AC joint while the conoid ligament attaches to the medial clavicle approximately 4 cm from the AC joint [4].

Muscular attachments of the lateral third of the clavicle include the anterior fibers of the deltoid and trapezius as well as the clavicular head of the pectoralis major. The pectoralis major and weight of the arm provide the chief deforming force on the lateral fragment, causing inferomedial and anterior displacement in fractures of the middle third of the clavicle [47].

Classification

Neer and later Craig defined lateral-third fractures based on the relationship of the fracture line to the CC ligaments and the AC joint [30, 48] (Fig. 10.8). Type I fractures occur lateral to the CC ligaments and spare the AC joint. These fractures are often minimally displaced as the proximal fragment is stabilized by the CC ligaments and the distal fragment by the deltotrapezial fascia. Type III fractures are also minimally displaced as the ligaments remain intact, but have an intra-articular

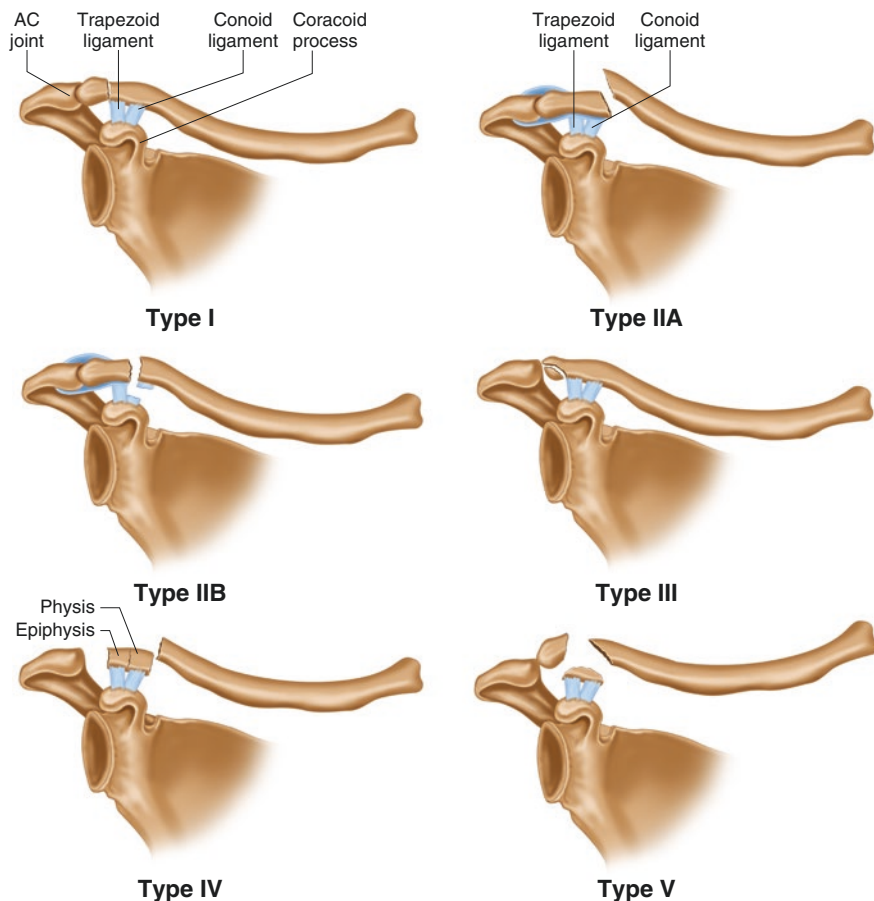


Fig. 10.8 Illustration of the Neer Classification of distal clavicle fractures

component. Type II fractures are inherently unstable as the proximal fragment is detached from the CC ligaments while the distal fragment remains attached to the scapula via the AC joint capsule. Type II fractures are differentiated into those where the fracture occurs medial to the conoid ligament (Type IIA) and those where the fracture lies between the conoid and trapezoid ligaments (Type IIB). Determination of the precise location of the fracture and the integrity of the CC ligaments can be difficult to determine on plain radiographs [44]. Type IV fractures are rare injuries involving epiphyseal separation in pediatric patients [49]. Type V injuries are comminuted and unstable as neither the proximal or distal fragments have ligamentous continuity with the coracoid [49]. An investigation using shoulder fellowship-trained observers demonstrated overall fair agreement for the Neer classification, but only slight agreement for the Type IIB pattern, which is thought as the most important determining factor for surgery [50].

A more recent classification was introduced by Robinson in which fractures are subdivided according to displacement, angulation, comminution, and intra-articular involvement [4] (Fig. 10.9). Distal clavicle fractures were classified as Type 3, with

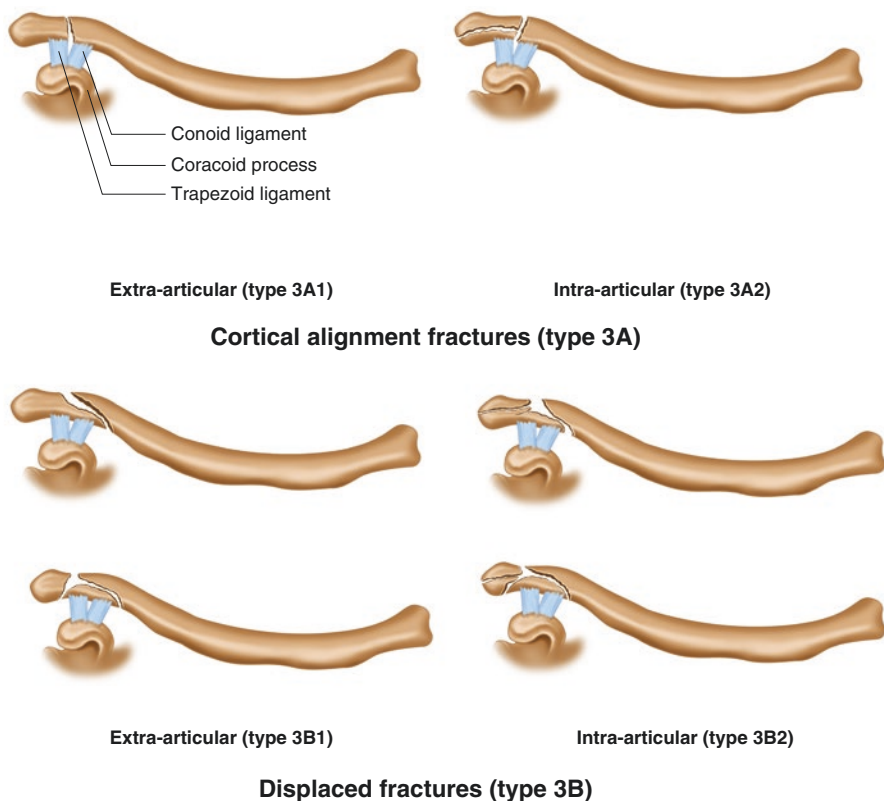


Fig. 10.9 Illustration of the Robinson classification for distal clavicle fractures (type 3)

subgroups into A and B based on displacement of the major fragments. The subgroups are further divided according to articular involvement. Although complicated, the classification system demonstrated excellent interobserver and intraobserver reliability among orthopedic trainees [4].

Clinical Evaluation

Most distal clavicle fractures occur as the result of either a direct blow or a fall on shoulder with the arm in the adducted position [5, 51]. The force from the impact at the acromion is transmitted through the AC joint to the CC ligaments and the distal clavicle [44].

Physical examination findings include ecchymosis, swelling, and tenderness at the level of the distal clavicle. A bony protuberance under the skin may be present caused by fracture displacement of the proximal fragment with an appearance similar to that of a high grade AC joint separation. As with medial clavicle injuries, a thorough neurological examination of the shoulder and the upper extremity should be performed and documented, particularly in high-energy clavicle fractures.

Radiographic Evaluation

Radiographic assessment should include routine views of the shoulder girdle to identify associated scapular or glenoid fractures. An axillary view is particularly useful in identifying subtle injuries of the distal clavicle including posterior displacement. The Zanca view is centered over the AC joint with a 10–15° cephalic tilt and can be helpful in evaluating intra-articular involvement [38] (Fig. 10.10). A single radiograph including bilateral clavicles and AC joints can also be useful in assessing overall fracture pattern and displacement.

Management

Most fractures of the lateral third of the clavicle are nondisplaced or minimally displaced and can be treated successfully nonoperatively [1, 4]. The rehabilitation regimen is similar to that of medial and midshaft clavicle fractures. After a period of sling immobilization for 2–6 weeks where supine passive and active-assisted ROM are initiated, active ROM is then allowed. Strengthening is initiated when signs of fracture consolidation are present radiographically.

The integrity of the CC ligaments plays an important role in the stability of the medial fragment and a smaller proportion of fractures involving the lateral third of the clavicle are at risk for delayed or nonunion. The nonunion rate ranges from 22 to 37% for displaced Neer type II fractures, and the absence of cortical contact is an independent risk for nonunion [4, 34, 52]. The risk of nonunion has also been reported to increase with advancing patient age and fracture displacement [53, 54]. Thus, the Neer classification has been traditionally used to determine fracture stability which is the driving factor for surgical decision-making and displaced type II, type IV, and type V fracture patterns in active healthy patients are typically managed surgically. However, only fair agreement between observers for the Neer classification has been demonstrated in the literature and only slight agreement for the type IIB Neer pattern [50].

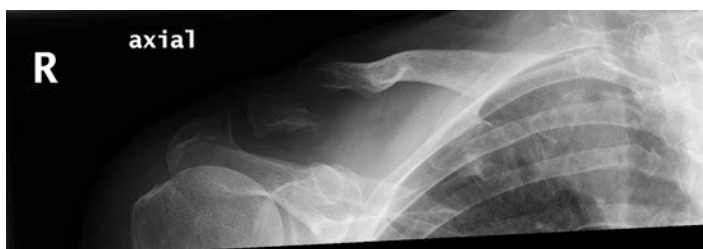

Fig. 10.10 Zanca radiographic view of the right shoulder demonstrating a nonunion of the distal clavicle

In addition, long-term data suggests many patients with non-united fractures of the distal clavicle are asymptomatic, particularly in elderly and sedentary individuals [34, 52]. Currently, there are no prospective prognostic studies identifying possible radiologic and/or clinical risk factors for symptomatic nonunion of the distal clavicle to help guide timely treatment decisions [18]. Similarly, there are no prospective comparative trials of nonoperative versus operative treatment.

A variety of surgical techniques have been described for the management of distal clavicle fractures including transacromial wire fixation, the modified Weaver-Dunn procedure, CC screw fixation, anatomic and hook plate fixation, and arthroscopic-assisted treatments [7, 48, 55–66]. Most of these studies are small case series without prospective design and lack a nonoperative control cohort. Although modifications have led to a reduction in unsatisfactory outcomes, the use of Kirschner wires as a primary fixation technique has largely been abandoned with reported complications such as pin migration as high as 50% [59, 67]. The modified Weaver-Dunn procedure, primarily used for AC joint dislocation, has been described for fractures where the distal fragment can be easily excised and the CA ligament transferred to the distal end of the proximal clavicle fragment [68]. In CC screw fixation, anatomic reduction of the distal clavicle is performed by temporarily fixing the distal clavicle to the coracoid process. Small case series have reported successful outcomes, but CC fixation is limited by fracture location and comminution and routinely requires a second procedure for screw removal [7, 56, 59, 69].

The introduction of pre-contoured, anatomic locking plates has resulted in high union rates with excellent return to function [53, 70, 71]. The plates contain multiple locking options for the cancellous bone of the lateral clavicle and do not require mandatory removal (Fig. 10.11). For those fractures where the distal fragment is too small for fixation, a hook plate achieves distal fixation by placing the “hooked” end of the implant under the acromion to maintain the reduction (Fig. 10.12). Good union rates have been reported, but a high instance of subacromial impingement and shoulder stiffness often necessitate plate removal. Asymptomatic osteolysis of the acromion and migration of the hook into the acromion have been described [60, 63, 64, 72]. Finally, suture and graft sling techniques can be used to supplement fixation or primarily reconstruct CC ligaments in a fashion similar to anatomic AC joint reconstruction [42, 73, 74]. Arthroscopic-assisted techniques have also yielded satisfactory results in select cases and can be augmented with suture and button devices [65, 75].

Preferred Surgical Technique

The senior author’s preferred treatment for displaced fractures of the distal clavicle is anatomic reduction and rigid fixation using either a pre-contoured distal clavicle locking plate or a hook plate.

After general anesthetic, the patient is placed in the modified beach-chair position with the head secured on a headrest. The shoulder is prepped and draped to include both the AC and SC joints; the authors do not routinely free-drape the arm.

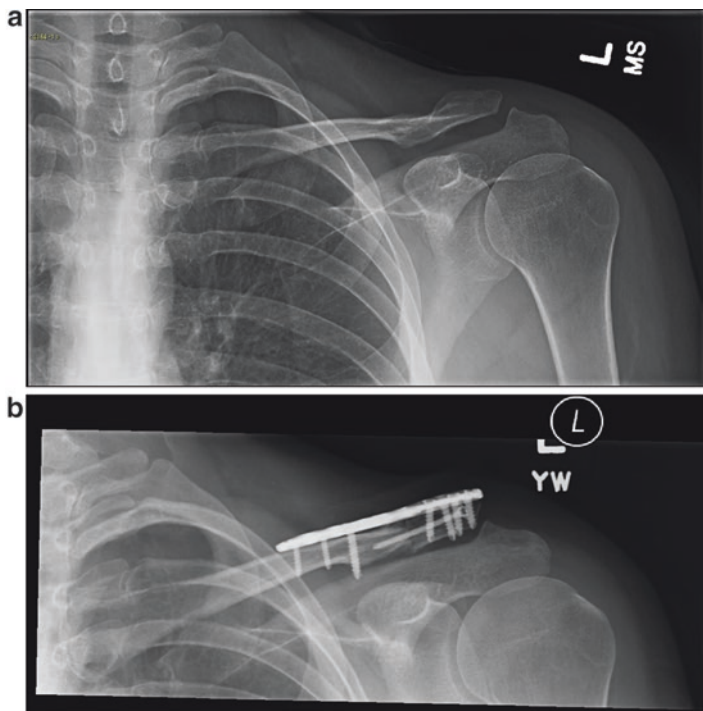


Fig. 10.11 (a) AP radiograph of the left AC joint demonstrating a distal clavicle malunion. (b) AP radiograph of the left clavicle following osteotomy and open reduction with distal clavicle locking plate

A longitudinal skin incision is made over the fracture on the superior boarder of the clavicle and extended across the AC joint. A single, thick subcutaneous tissue flap is elevated exposing the underlying myofascial layer. This layer is divided sharply down to the clavicle and AC joint and is elevated off the bone as a single layer that can be later closed over the plate. If a traumatic tear or “rent” exists in the fascia, this instead is utilized and extended.

The fracture site is then exposed and inspected. Hematoma and interposed soft tissues are carefully debrided. If the distal fragment is large enough to hold screws, a low-profile, pre-contoured, locking plate is the preferred method of fixation. Anatomic distal clavicle plates offer extra holes with locking options for the cancellous bone of the distal clavicle. Bone-holding forceps are used for anatomic reduction of the fracture. Alternatively, the plate can first be fixed provisionally to the medial clavicle fragment to aid in reduction. It is rarely necessary to cross the AC joint for fixation; if required, unicortical screws can be used to avoid impinging on the subacromial space.

For cases where the size or quality of the lateral fragment is not sufficient to obtain stability, a hook plate is preferred. Cautery is used to create an opening posterior to the AC joint to pass the hook underneath the acromion. The plate can then be applied to the medial clavicle as a reduction device. One must be careful not to over reduce the medial clavicle relative to the AC joint and the plate and hook can each be contoured as needed. Intraoperative AP radiographs can be confirmatory and may be

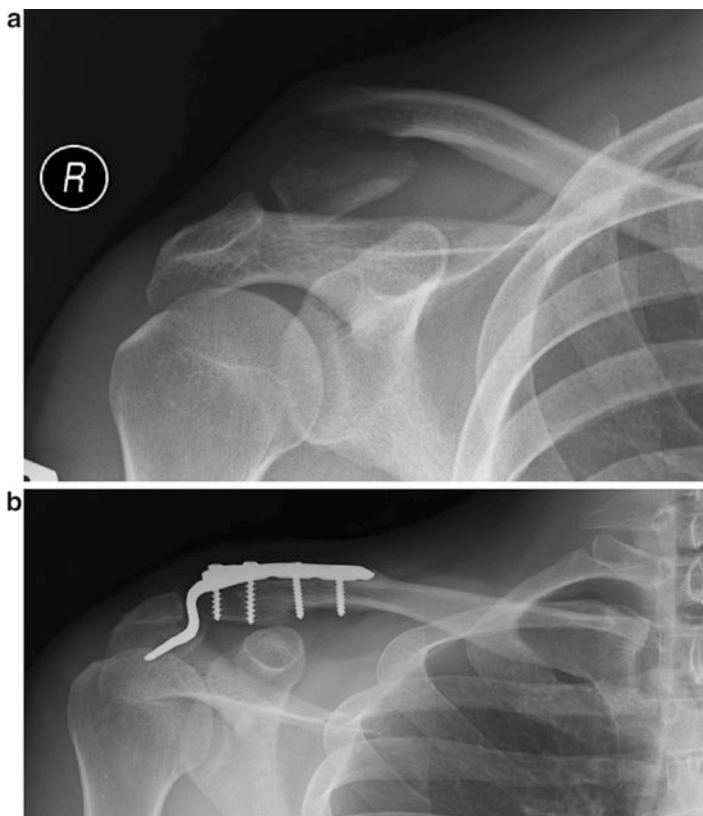


Fig. 10.12 AP radiographs of the right AC joint demonstrating a distal clavicle fracture pre (a) and post (b) open reduction with hook plate fixation

useful when trialing hook depths and angles. When possible, a partially threaded screw is inserted in a lag fashion to compress the distal fragment directly to the medial clavicle prior to hook plate application. In selected cases where a very small distal fragment is present, hook plate fixation can be augmented with a modified Weaver-Dunn procedure. This involves an anterior acromioplasty with a small “wafer” of bone and the insertion of the CA ligament from the acromion. The bony wafer is then secured into or onto the distal end of the clavicle with a nonabsorbable suture.

The surgical site is thoroughly irrigated and a two-layer closure of the soft tissues is performed as previously described for medial clavicle injuries. Subcutaneous sutures are avoided to minimize the risk of tissue reaction or stitch abscesses.

The patient wears a simple sling for a full-time basis for 2 weeks followed by active-assisted ROM exercises in the scapular plane of motion. Full active ROM exercises are initiated a 4 weeks postop followed by strengthening at 6–8 weeks. Return to sport is considered when full motion and strength have been achieved at approximately 3 months postop. Although not universally required, the hook plate can be removed after a minimum of 6 months postoperatively and may allow the patient to achieve further improvements in ROM including forward elevation and lateral abduction.

Illustrative Cases

Case 1

A 31-year-old male was seen regarding a left shoulder injury he sustained after falling from his bike. He landed directly on his left shoulder with his arm at his side. He was complaining of isolated lateral shoulder pain. Upon physical examination, there is an obvious protuberance at the level of the AC joint with swelling and ecchymosis. The area was tender and he was neurologically intact.

Radiographs of the left clavicle demonstrated a significantly displaced lateral-third fracture with a large butterfly fragment spanning the distal and medial clavicle (Fig. 10.13).

Given the degree of initial displacement in a young, active patient, surgical treatment was recommended.

The patient was managed operatively with open reduction and internal fixation with a low-profile, pre-contoured, distal locking plate (Fig. 10.14). The fracture was provisionally reduced and then a lag screw inserted to secure the butterfly fragment followed by the locking plate with multiple screws in the distal fragment.

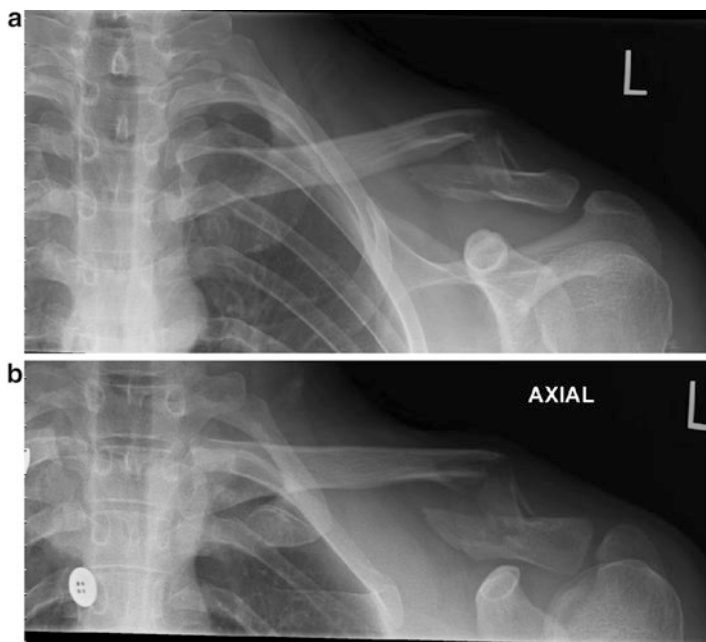


Fig. 10.13 AP (a) and axial (b) radiographs of the left clavicle demonstrating significantly displaced lateral-third fracture

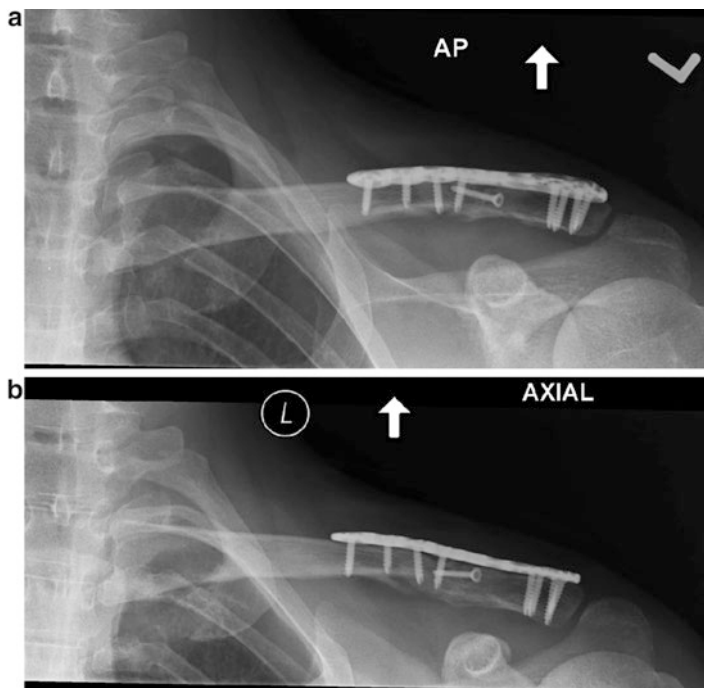


Fig. 10.14 Postoperative AP (a) and axial (b) radiographs of the left clavicle after open reduction and internal fixation with a distal third locking plate

Case 2

A 17-year-old male was seen in consultation 12 months after sustaining an injury to his right shoulder. He was previously assessed at an outside institution immediately following the injury where he had opted for nonoperative treatment. He complained of ongoing shoulder pain, crepitus, and deformity in the shoulder affecting his function and quality of life. Upon physical examination, there was an obvious asymmetry of his clavicles with a protuberance at the level of the AC joint. He has discomfort with palpation of the distal clavicle and with shoulder ROM. A mobile fragment at the distal clavicle was palpable.

Radiographs of the right clavicle reveal a nonunion with a small lateral fragment (Fig. 10.15).

The patient was managed operatively with open reduction and internal fixation using a hook plate construct (Fig. 10.16). The nonunion site was carefully debrided and the non-united lateral fragment secured to the medial clavicle in compression via a lag screw. The hook plate was then contoured and applied to maintain the reduction. Uneventful union resulted.

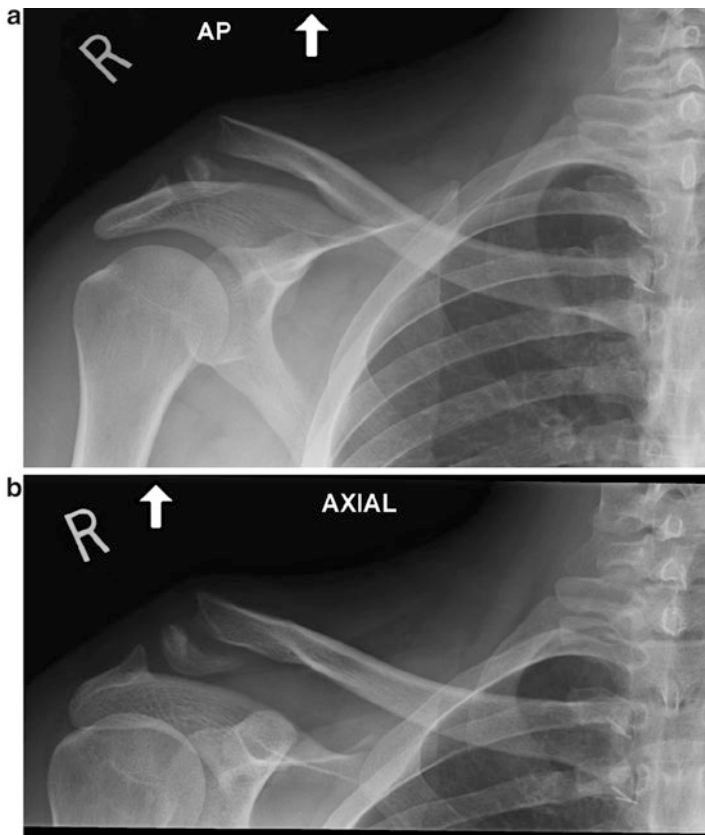
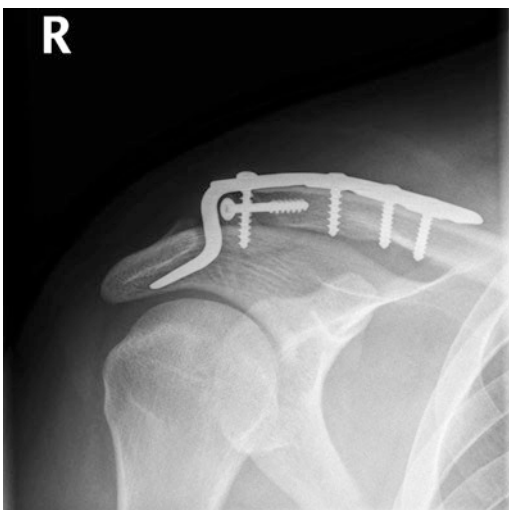


Fig. 10.15 AP (a) and axial (b) radiographs of the right clavicle demonstrating a distal clavicle nonunion

Fig. 10.16 Postoperative AP radiograph of the right clavicle after open reduction and internal fixation with hook plate construct



References

1. Nordqvist A, Petersson C. The incidence of fractures of the clavicle. *Clin Orthop*. 1994;300:127–32.
2. Nowak J, Mallmin H, Larsson S. The aetiology and epidemiology of clavicular fractures: a prospective study during a two-year period in Uppsala, Sweden. *Injury*. 2000;31:353–8.
3. Patel B, Gustafson PA, Jastifer J. The effect of clavicle malunion on shoulder biomechanics; a computational study. *Clin Biomech (Bristol, Avon)*. 2012;27:436–42.
4. Renfree KJ, Riley MK, Wheeler D, Hentz JG, Wright TW. Ligamentous anatomy of the distal clavicle. *J Shoulder Elbow Surg*. 2003;12(4):355–9.
5. Robinson CM, Cairns DA. Primary nonoperative treatment of displaced lateral fractures of the clavicle. *J Bone Joint Surg Am*. 2004;86(4):778–82.
6. Postacchini F, Gumina S, De Santis P, et al. Epidemiology of clavicle fractures. *J Shoulder Elbow Surg*. 2002;11:454–6.
7. Waters PM, Bae DS, Kadiyala RK. Short-term outcomes after surgical treatment of traumatic posterior sternoclavicular fracture-dislocations in children and adolescents. *J Pediatr Orthop*. 2003;23(4):464–9.
8. Pang KP, Yung SW, Lee TS, et al. Bipolar clavicular injury. *Med J Malaysia*. 2003;58(4):621–4.
9. Throckmorton T, Kuhn JE. Fractures of the medial end of the clavicle. *J Shoulder Elbow Surg*. 2007;16(1):49–54.
10. van der Meijden OA, Gaskill TR, Millett PJ. Treatment of clavicle fractures: current concepts review. *J Shoulder Elbow Surg*. 2012;21:423–9.
11. Gardner E. The embryology of the clavicle. *Clin Orthop*. 1968;58:9–16.
12. Lewonowski K, Bassett GS. Complete posterior sternoclavicular epiphyseal separation. A case report and review of the literature. *Clin Orthop*. 1992;281:84–8.
13. Lazarus MD. Fractures of the clavicle. In: Bucholz RW, Heckman JD, editors. *Rockwood and Green's fractures in adults*. 5th ed. Philadelphia: Lippincott Williams & Wilkins; 2002. p. 1041–78.
14. Rowe CR. An atlas of anatomy and treatment of mid-clavicular fractures. *Clin Orthop*. 1968;58:29–42.
15. Stanley D, Trowbridge EA, Norris SH. The mechanism of clavicular fracture: a clinical and biomechanical analysis. *J Bone Joint Surg Br*. 1998;70(3):461–4.
16. Barbier O, Malghem J, Delaere O, et al. Injury to the brachial plexus by a fragment of bone after fracture of the clavicle. *J Bone Joint Surg Br*. 1997;79:534–6.
17. Katras T, Baltazar U, Rush DS, et al. Subclavian arterial injury associated with blunt trauma. *Vasc Surg*. 2001;35(1):43–50.
18. Kim W, McKee MD. Management of acute clavicle fractures. *Orthop Clin North Am*. 2008;39(4):491–505, vii.
19. Lange RH, Noel SH. Traumatic lateral scapular displacement: an expanded spectrum of associated neurovascular injury. *J Orthop Trauma*. 1993;7:361–6.
20. Carmichael KD, Longo A, Lick S, Swishuk L. Posterior sternoclavicular epiphyseal fracture-dislocation with delayed diagnosis. *Skeletal Radiol*. 2006;35:608–12.
21. Cope R. Dislocations of the sternoclavicular joint. *Skeletal Radiol*. 1993;22:233–8.
22. Brooks AL. Injury to the proximal clavicular epiphysis. *J Bone Joint Surg Am*. 1972;54:1347–8.
23. Garretson RB, Williams Jr GR. Clinical evaluation of injuries to the acromioclavicular and sternoclavicular joints. *Clin Sports Med*. 2003;22:239–54.
24. Goldfarb CA, Bassett GS, Sullivan S, et al. Retrosternal displacement after physeal fracture of the medial clavicle in children treatment by open reduction and internal fixation. *J Bone Joint Surg Br*. 2001;83(8):1168–72.
25. Scadden JE, Richards R. Intramedullary fixation of Neer type 2 fractures of the distal clavicle with an AO/ASIF screw. *Injury*. 2005;36(10):1172–5.

26. Zaslav KR, Ray S, Neer CS. Conservative management of a displaced medial clavicular physal injury in an adolescent athlete. A case report and literature review. *Am J Sports Med.* 1989;17:833–6.
27. Chaudhry S. Pediatric posterior sternoclavicular joint injuries. *J Am Acad Orthop Surg.* 2015;23(8):468–75.
28. DeFranco MJ, Patterson BM. The floating shoulder. *J Am Acad Orthop Surg.* 2006;14(8):499–509.
29. Allman Jr FL. Fractures and ligamentous injuries of the clavicle and its articulation. *J Bone Joint Surg Am.* 1967;49:774–84.
30. Craig EV. Fractures of the clavicle. In: Rockwood CA, Matsen FA, editors. *The shoulder.* Philadelphia: WB Saunders; 1990. p. 367–412.
31. Jupiter JB, Ring D. Fractures of the clavicle. In: Iannotti JP, Williams GR, editors. *Disorders of the shoulder: diagnosis and management.* Philadelphia: Lippincott Williams & Wilkins; 1999. p. 709–36.
32. Rokito AS, Zuckerman JD, Shaari JM, Eisenberg DP, Cuomo F, Gallagher MA. A comparison of nonoperative and operative treatment of type II distal clavicle fractures. *Bull Hosp Jt Dis.* 2002–2003;61(1–2):32–9.
33. Zanca P. Shoulder pain: involvement of the acromioclavicular joint: analysis of 1,000 cases. *Am J Roentgenol Radium Ther Nucl Med.* 1971;112(3):493–506.
34. Robinson CM. Fractures of the clavicle in the adult: epidemiology and classification. *J Bone Joint Surg Br.* 1998;80:476–84.
35. Brinker MR, Bartz RL, Reardon PR, et al. A method for open reduction and internal fixation of the unstable posterior sternoclavicular joint dislocation. *J Orthop Trauma.* 1997;11(5):378–81.
36. Wade AM, Barrett MO, Crist BD, et al. Medial clavicular epiphyseal fracture with ipsilateral acromioclavicular dislocation: a case report of panclavicular fracture dislocation. *J Orthop Trauma.* 2007;21(6):418–21.
37. Yamaguchi H, Arakawa H, Kobayashi M. Results of the Bosworth method for unstable fractures of the distal clavicle. *Int Orthop.* 1998;22(6):366–8.
38. Yang J, al-Etani H, Letts M. Diagnosis and treatment of posterior sternoclavicular joint dislocations in children. *Am J Orthop.* 1996;25(8):565–9.
39. Low AK, Duckworth DG, Bokor DJ. Operative outcome of displaced medial-end clavicle fractures in adults. *J Shoulder Elbow Surg.* 2008;17:751–4.
40. Oe K, Gaul L, Hierholzer C, Woltmann A, Miwa M, Kurosaka M, et al. Operative management of periarticular medial clavicle fractures—report of 10 cases. *J Trauma.* 2011;72:E1–7.
41. Clark RL, Milgram JW, Yawn DH. Fatal aortic perforation and cardiac tamponade due to a Kirschner wire migrating from the right sternoclavicular joint. *South Med J.* 1974;67:316–8.
42. Leonard JW, Gifford Jr RW. Migration of a Kirschner wire from the clavicle into the pulmonary artery. *Am J Cardiol.* 1965;16:598–600.
43. Sidhu VS, Hermans D, Duckworth DG. The operative outcomes of displaced medial-end clavicle fractures. *J Shoulder Elbow Surg.* 2015;24(11):1728–34.
44. Banerjee R, Waterman B, Padalecki J, Robertson W. Management of distal clavicle fractures. *J Am Acad Orthop Surg.* 2011;19(7):392–401.
45. Robinson CM, Court-Brown CM, McQueen MM, et al. Estimating the risk of nonunion following nonoperative treatment of a clavicular fracture. *J Bone Joint Surg Am.* 2004;86(7):1359–65.
46. Fukuda K, Craig EV, An KN, Cofield RH, Chao EY. Biomechanical study of the ligamentous system of the acromioclavicular joint. *J Bone Joint Surg Am.* 1986;68(3):434–40.
47. Neer II CS. Fracture of the distal clavicle with detachment of the coracoclavicular ligaments in adults. *J Trauma.* 1963:399–110.
48. Neer II CS. Fractures of the distal third of the clavicle. *Clin Orthop Relat Res.* 1968;58:43–50.
49. Neer II CS. Fractures and dislocations of the shoulder. In: Rockwood Jr CA, Green DP, editors. *Fractures in adults.* Philadelphia, PA: J.B. Lippincott; 1984. p. 711–2.

50. Bishop JY, Jones GL, Lewis B, Pedroza A, MOON Shoulder Group. Intra- and interobserver agreement in the classification and treatment of distal third clavicle fractures. *Am J Sports Med.* 2015;43(4):979–84.
51. Smolle-Juettner FM, Hofer PH, Pinter H, Friehs G, Szyskowitz R. Intracardiac malpositioning of a sternoclavicular fixation wire. *J Orthop Trauma.* 1992;6:102–5.
52. Nordqvist A, Petersson C, Redlund-Johnell I. The natural course of lateral clavicle fracture. 15 (11-21) year follow-up of 110 cases. *Acta Orthop Scand.* 1993;64:87–91.
53. Klein SM, Badman BL, Keating CJ, Devinney DS, Frankle MA, Mighell MA. Results of surgical treatment for unstable distal clavicle fractures. *J Shoulder Elbow Surg.* 2010;19:1049–55.
54. Kona J, Bosse MJ, Steaheli JW, Rosseau RL. Type II distal clavicle fractures: a retrospective review of surgical treatment. *J Orthop Trauma.* 1990;4:115–20.
55. Badhe SP, Lawrence TM, Clark DI. Tension band suturing for the treatment of displaced type 2 lateral end clavicle fractures. *Arch Orthop Trauma Surg.* 2007;127(1):25–8.
56. Ballmer FT, Gerber C. Coracoclavicular screw fixation for unstable fractures of the distal clavicle. A report of five cases. *J Bone Joint Surg Br.* 1991;73:291–4.
57. Bezer M, Aydin N, Guven O. The treatment of distal clavicle fractures with coracoclavicular ligament disruption: a report of 10 cases. *J Orthop Trauma.* 2005;19(8):524–8.
58. Chen CH, Chen WJ, Shih CH. Surgical treatment for distal clavicle fracture with coracoclavicular ligament disruption. *J Trauma.* 2002;52(1):72–8.
59. Edwards DJ, Kavanagh TG, Flannery MC. Fractures of the distal clavicle: a case for fixation. *Injury.* 1992;23:44–6.
60. Flinkkilä T, Ristiniemi J, Hyvönen P, et al. Surgical treatment of unstable fractures of the distal clavicle: a comparative study of Kirschner wire and clavicular hook plate fixation. *Acta Orthop Scand.* 2002;73(1):50–3.
61. Goldberg JA, Bruce WJ, Sonnabend DH, et al. Type 2 fractures of the distal clavicle: a new surgical technique. *J Shoulder Elbow Surg.* 1997;6(4):380–2.
62. Jin CZ, Kim HK, Min BH. Surgical treatment for distal clavicle fracture associated with coracoclavicular ligament rupture using a cannulated screw fixation technique. *J Trauma.* 2006;60(6):1358–61.
63. Kashii M, Inui H, Yamamoto K. Surgical treatment of distal clavicle fractures using the clavicular hook plate. *Clin Orthop.* 2006;447:158–64.
64. Meda PV, Machani B, Sinopidis C, et al. Clavicular hook plate for lateral end fractures: a prospective study. *Injury.* 2006;37(3):277–83.
65. Nourissat G, Kakuda C, Dumontier C, et al. Arthroscopic stabilization of Neer type 2 fracture of the distal part of the clavicle. *Arthroscopy.* 2007;23(6):674.e1–4.
66. Rumball KM, Da Silva VF, Preston DN, et al. Brachial plexus injury after clavicular fracture: case report and literature review. *Can J Surg.* 1991;34:264–6.
67. Lyons FA, Rockwood Jr CA. Migration of pins used in operations on the shoulder. *J Bone Joint Surg Am.* 1990;72:1262–7.
68. Anderson K. Evaluation and treatment of distal clavicle fractures. *Clin Sports Med.* 2003;22(2):319–26. vii
69. Macheras G, Kateros KT, Savvidou OD, Sofianos J, Fawzy EA, Papagelopoulos PJ. Coracoclavicular screw fixation for unstable distal clavicle fractures. *Orthopedics.* 2005;28(7):693–6.
70. Fleming MA, Dachs R, Maqungo S, du Plessis JP, Vrettos BC, Roche SJ. Angular stable fixation of displaced distal-third clavicle fractures with superior precontoured locking plates. *J Shoulder Elbow Surg.* 2015;24(5):700–4.
71. Lee SK, Lee JW, Song DG, Choy WS. Precontoured locking plate fixation for displaced lateral clavicle fractures. *Orthopedics.* 2013;36(6):801–7.
72. Good DW, Lui DF, Leonard M, Morris S, McElwain JP. Clavicle hook plate fixation for displaced lateral-third clavicle fractures (Neer type II): a functional outcome study. *J Shoulder Elbow Surg.* 2012;21(8):1045–8.
73. Johnston PS, Sears BW, Lazarus MR, Frieman BG. Fixation of unstable type II clavicle fractures with distal clavicle plate and suture button. *J Orthop Trauma.* 2014;28(11):e269–72.

74. Li Y, Shi S, Ou-Yang YP, Liu TL. Minimally invasive treatment for Neer IIb distal clavicle fractures with titanium cable. *J Trauma*. 2011;71(2):E37–40.
75. Checchia SL, Doneux PS, Miyazaki AN, Fregoneze M, Silva LA. Treatment of distal clavicle fractures using an arthroscopic technique. *J Shoulder Elbow Surg*. 2008;17(3):395–8.

Chapter 11

Outcomes of Clavicle Injuries

Nathan T. Formaini and Jonathan C. Levy

Introduction

Clavicle fractures are among the most common of all orthopedic injuries and result from various mechanisms during sporting activities, motor vehicle collisions, or accidental falls [1–5]. Traditionally, these fractures were treated conservatively with sling or brace immobilization as early studies demonstrated high rates of union with little evidence of patient dissatisfaction or functional complaints [6, 7]. Early studies evaluating the operative treatment of clavicle fractures had even shown high rates of nonunion, further supporting nonoperative management as the standard of care [6, 7]. However, more recent literature has shown that conservative treatment for some clavicle fractures leads to higher rates of nonunion, shoulder dysfunction, and residual pain from malunion that previously described [8–16]. Various studies have now demonstrated improved outcomes with surgical intervention for displaced, comminuted, or shortened clavicle fractures in active individuals when compared to nonoperative management [8, 9, 11, 13, 17, 18]. Despite newer implants and techniques, surgical management of clavicle fractures is not without risk and potential complications [19–23]. Therefore, the ideal treatment for clavicle fractures should be based on the age, activity level, functional demands, and expectations of the patient as well as the specific fracture characteristics in each case to ensure the best possible outcomes.

N.T. Formaini, D.O (✉)
Armstrong Orthopedic Associates, 77 Glade Drive, Kittanning, PA 16201, USA
e-mail: nateformaini@gmail.com

J.C. Levy, M.D.
Holy Cross Orthopedic Institute, 5597 North Dixie Highway, Fort Lauderdale,
FL 33334, USA
e-mail: jonlevy123@yahoo.com

Fractures of the Middle-Third

Nonoperative Treatment

Nonoperative management for middle-third clavicle fractures remains the standard of care for nondisplaced and minimally displaced fractures in children and adults. Initial studies by Neer and Rowe reported very low rates of nonunion with conservative management [6, 7]. Other studies further supported conservative management as the optimal choice, reporting that patient satisfaction was acceptable without surgical intervention [14, 24, 25]. These early studies are still relevant as newer evidence further confirms that nonoperative care for nondisplaced and minimally displaced midshaft clavicle fractures should remain the treatment of choice.

A large meta-analysis by Zlowodzki et al. [18] reviewed 2144 midshaft clavicle fractures to compare results of nonoperative and operative treatment methods in the acute setting. A total of 1145 fractures were treated nonoperatively, with 986 of these fractures being nondisplaced. Of the 986 nondisplaced fractures, the nonunion rate was only 5.9%. They did observe, however, that within the remaining 159 displaced fractures treated nonoperatively, the nonunion rate grew to 15.1%. Newer evidence has shown that this higher nonunion rate can significantly impact patient outcomes [8–16] and careful consideration of patient factors such as age, activity level, and expectations is important when selecting the best treatment for each individual patient.

Figure-of-Eight Brace vs. Sling

Very few randomized, controlled trials have been performed to compare the nonoperative treatments for middle-third clavicle fractures. Conservative management treatments range from the extremes of spica casting to benign neglect. The two most commonly employed methods of immobilization are the simple arm sling and the figure-of-eight clavicle brace.

A study in 1987 by Anderson and colleagues [24] were the first to compare these two forms of immobilization in a randomized trial. The authors demonstrated that both the simple arm sling and the figure-of-eight brace adequately stabilized the clavicle to provide union, without significant change in initial displacement over the treatment course. The functional and cosmetic results of the two methods were reported to be similar as well. They reported the most significant difference to be poor tolerance of the figure-of-eight brace. Anderson et al. concluded that the simple sling be recommended due to improved comfort and potential for fewer complications.

A recent study by Ersen et al. in 2015 [26] compared the simple sling to the figure-of-eight brace and evaluated differences in patient-reported pain, Constant and American Shoulder and Elbow Surgeon (ASES) scores, and radiographic union. While there were no differences in subjective outcome scores, their findings demonstrated a significantly higher reported mean visual analog pain (VAS) pain

score in the first 24 h of treatment as well as a trend towards increased shortening in fracture alignment with the figure-of-eight brace. Similar to the study by Anderson et al. [24], their conclusions were to recommend the arm sling over figure-of-eight bracing due to improved comfort and ease of use.

Surgical Management

Outcomes of Nonoperative vs. Operative Treatment

While it is generally accepted and well documented that nondisplaced and minimally displaced midshaft clavicle fractures will heal and result in excellent outcomes with nonoperative treatment [14, 18], there is growing evidence that comminuted or significantly displaced fractures demonstrate higher incidences of nonunion, symptomatic malunion, and worse patient subjective outcome scores [8–16]. Robinson et al. [16] conducted a large observational cohort study to assess which factors may predispose a patient to developing a clavicle nonunion with nonoperative treatment. They found multiple variables that independently predicted an increased incidence of nonunion. These variables included lack of cortical apposition, presence of comminution, female gender, and advanced age. In an earlier study, Hill and associates [10] observed a statistically significant increase in the incidence of nonunion if the fractured clavicle was shortened by greater than two centimeters. Due to these observations and a wealth of literature now reporting outcome differences between nonoperative and operative treatment of displaced midshaft clavicle fractures, a paradigm shift has occurred with many surgeons favoring early operative intervention [27].

The Canadian Orthopaedic Trauma Society published a multicenter, prospective clinical trial of 132 patients randomized to either plate fixation or nonoperative treatment for a displaced midshaft fracture of the clavicle [8]. Radiographic union of the fracture occurred 12 weeks earlier on average in the patients treated with open reduction and plating. The rate of nonunion was 3% versus 14% in the operative and nonoperative group, respectively, and symptomatic malunions occurred in 9 of the 49 patients in the nonoperative group. Constant shoulder scores and DASH (Disabilities of the Arm, Shoulder, and Hand) scores were significantly higher as was overall patient satisfaction in the operative group [8].

In another study comparing outcomes between operative and nonoperative treatment, Kulshrestha et al. [11] demonstrated a 0% versus 29% incidence of nonunion and a 4% versus 36% incidence of malunion, favoring the operative group treated with plate fixation. Constant shoulder scores were significantly better at all follow-up periods out to 18 months from injury in the operative group.

The most recent multicenter, randomized, controlled trial comparing management by Robinson et al. [28] continued this trend with significantly fewer nonunions occurring in the operative group. DASH and Constant shoulder scores were significantly better at one-year follow-up and patients were more satisfied with the

overall cosmesis of their shoulder after having undergone open reduction and plate fixation. When eliminating patients with a nonunion from the statistical analysis, however, they showed that outcome scores were similar between groups. They concluded that operative treatment improved outcomes mainly by prevention of fracture nonunion furthering the evidence that certain displaced fractures may benefit more from surgical intervention.

Nearly, all of the trials comparing nonoperative and operative treatment for displaced midshaft clavicle fractures have shown similar results as they demonstrate improved outcomes after surgical fixation. This has resulted in a significant increase in the frequency of operative clavicle fracture management over the past decade [27], but another similarity which all of these studies share and perhaps less frequently highlighted, is the complications inherent with surgical management. Infection, wound issues, parasthesias, and vascular injury have all been reported [19–23, 29]. Most commonly, however, is the incidence of hardware-related irritation or prominence which may incur subsequent procedures for implant removal and additional risks to the patient [8, 11, 13, 17, 19, 21, 23, 28]. Surgical intervention should therefore be reserved for fracture types known to be at high risk for nonunion [10, 16] and only after careful consideration of the individual patient's demands and expectations.

Plate vs. Intramedullary Fixation

Many different surgical techniques have been described for the management of displaced midshaft clavicle fractures, with plating and intramedullary nail fixation being the two most commonly used. Plate fixation has been the gold standard for surgical treatment of midshaft clavicle fractures and has proven to be reproducible with a high rate of union [8, 11, 13, 17, 18, 21, 28]. In addition, plate fixation offers increased biomechanical stability and may allow for earlier, more aggressive rehabilitation protocols [30]. Advocates of intramedullary clavicle fixation cite the larger exposure and potential disruption of the periosteal blood supply associated with plate fixation as major disadvantages. Intramedullary clavicle pins offer the advantage of being minimally invasive with less concern for scar cosmesis and theoretically reduced infection risk while preserving the soft-tissue envelope, periosteum, and vascularity at the fracture site [31]. Regardless of the chosen implant, hardware prominence may occur, prompting patient requests for later removal.

A randomized clinical trial by Ferran et al. [32] sought to evaluate the differences in outcomes between plating and intramedullary fixation for displaced, midshaft clavicle fractures. Seventeen patients were randomized to lock intramedullary pinning, while 15 patients were randomized to plate fixation. There was a 100% union rate in both groups with no statistically significant differences in outcomes comparing both Constant and Oxford shoulder scores. All pins were routinely removed due to the pin design chosen for fixation. Plating led to a higher incidence of superficial wound complications and 53% of the plates were subsequently removed due to complaints of irritation, superficial infection, or patient request.

Additional studies comparing plating to intramedullary fixation have been performed with similar results. Union rates have been proven to be high with either technique, while no significant differences in functional outcomes have been shown [20, 31, 33, 34]. Significant variations in implant removal rates for either method of fixation have been reported and are likely multifactorial. While the chosen surgical technique and implant is largely due to surgeon preference or familiarity, a discussion on the particular advantages and disadvantages of the selected method is vital to maximize patient expectations and outcomes.

Clavicle Plate Position

Plate positioning on the clavicle may affect the incidence of implant prominence and low-profile pre-contoured plates have been developed to fit on either the superior or anteroinferior aspect of the clavicle (Figs. 11.1 and 11.2). While there have been multiple biomechanical studies performed to evaluate which plate position provides a stronger construct, there has been little agreement between studies as each has biomechanical advantages depending on the particular forces exerted on the clavicle [35–37]. Anteroinferior plating has been shown to have a lower reported rate of implant prominence or irritation and may reduce need for plate removal after fracture union [21, 38].

In a large retrospective review, Formaini et al. [21] compared the outcomes of 105 patients having undergone either superior or anteroinferior plating of a displaced, midshaft clavicle fracture. Of the 62 patients in the superior plating group,

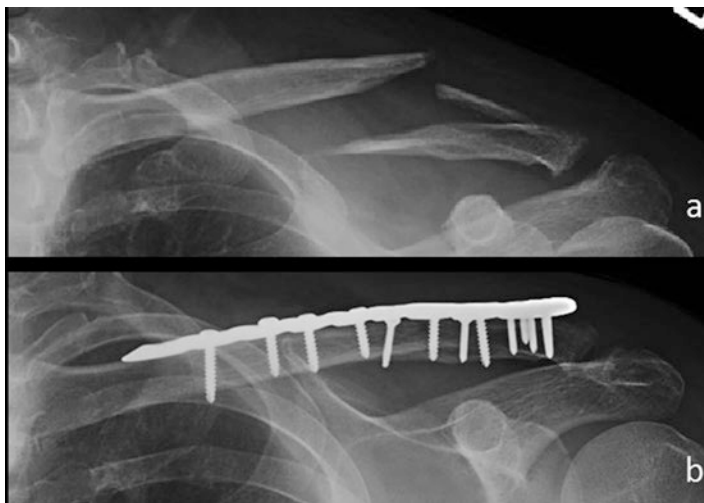

Fig. 11.1 (a) AP radiograph demonstrating a completely displaced and comminuted middle-third clavicle fracture. (b) Postoperative AP radiograph after open reduction internal fixation with a pre-contoured, superior clavicle locking plate

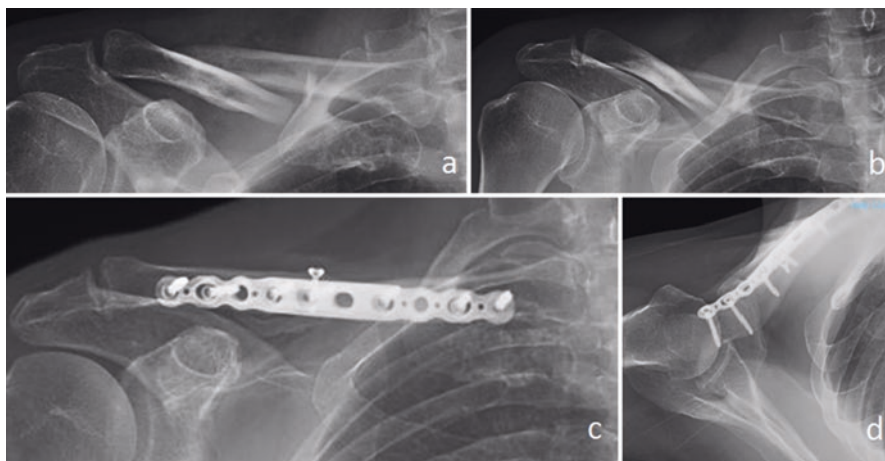


Fig. 11.2 (a and b) Plain radiographs of a severely shortened and displaced middle-third clavicle fracture. (c and d) Postoperative radiographs after open reduction internal fixation with a pre-contoured anteroinferior clavicle locking plate

54% of patients complained of implant prominence, and 19% of the plates were eventually removed. The anteroinferior plating group which consisted of the 43 remaining patients had only a 29% rate of reported implant prominence and only 9% of patients underwent additional surgery for plate removal. Union rates were identical at 95% in both groups and patients having undergone anteroinferior plating reported significantly higher Oxford shoulder scores. In a similar study by Hulsmans et al. [38] comparing these two plating methods, a statistically significant difference was noted between the number of patients with asymptomatic retained hardware, favoring the anteroinferior group. Forty-six percent of patients in the anteroinferior group reported asymptomatic hardware versus only 22% in the superior plating group. Interestingly, the rate of plate removal in symptomatic patients was nearly identical between anteroinferior and superior plating at 36% and 37%, respectively.

While both superior plating and anteroinferior plating have demonstrated high union rates and low complication rates, the anteroinferior plate position appears to reduce the risk of patient-reported implant prominence or irritation and may lead to fewer requests for consequent hardware removal [21, 38].

Children and Adolescents

Nonsurgical management for midshaft clavicle fractures in children and adolescents has long been the standard of care and typically leads to excellent functional outcomes. Remodeling capabilities and the amplified healing potential in this age group has made surgical intervention very infrequent compared to adults.

Multiple studies have demonstrated high union rates with low incidences of complications [16, 39]. However, as in the adult population, significant degrees of fracture shortening and displacement may predispose to malunion and functional deficits especially as individuals approach skeletal maturity. Return to sport or high demand activities as well as desire to avoid cosmetic deformity may influence the decision to proceed with surgical management in younger patients. Plate fixation has proven to be reliable at restoring anatomical alignment and shortening time to union while having low complication rates [40]. Differences in long-term outcomes between nonoperative and operative treatment in children and adolescents, however, have been less conclusive [41]. Careful selection of patients in the younger population for operative clavicle fracture management is critical and should be reserved for appropriate cases based on detailed discussion between the surgeon, patient, and family.

Fractures of the Distal-Third

Nonoperative Treatment

Fractures of the distal-third of the clavicle which are nondisplaced, minimally displaced, or extra-articular have shown high union rates and good functional outcomes with nonsurgical treatment [16]. These fractures are typically defined as type I distal clavicle fractures according to the classification system by Neer [42], occurring distal to the coracoclavicular (CC) ligaments and without extension into the acromioclavicular joint. This fracture pattern is inherently stable due to the integrity of the CC ligaments and quick functional recovery is commonly seen. Even if a nonunion develops after a type I injury, they are seldom symptomatic. In the infrequent cases when painful nonunion does develop, distal clavicle excision is typically curative. The immobilization method, rehabilitation, and conservative treatment modalities for these injuries are similar or identical to those for midshaft clavicle fractures.

Controversy does exist, however, in whether nonoperative or operative treatment is the optimal choice for management of displaced type II and type III distal clavicle injuries. Type II distal clavicle fractures occur medial to the coracoclavicular ligaments and similar to an earlier study done by Neer [42], displaced type II fractures treated nonsurgically have demonstrated a nonunion rate of 33.3% in a recent large systematic review [43]. Despite the high nonunion rate, multiple studies have shown that nonoperative treatment does not lead to a significant difference in functional scores compared to those treated surgically [44–47]. In addition, the complication rate associated with surgical management far exceeds that of nonoperative treatment for these fractures [43]. Nonoperative treatment of type III fractures which extend into the acromioclavicular articulation may result in later development of symptomatic joint degeneration and if symptomatic arthrosis occurs, delayed surgical management in the form of distal clavicle excision may be indicated.

In small prospective study by Deafenbaugh et al. [44], ten patients were treated nonoperatively for a displaced Neer type II distal clavicle fracture. At an average follow-up of 14.3 months, seven out of ten fractures healed while three went on to develop nonunion. Of the seven patients with healed fractures, six (86%) reported a satisfactory outcome. None of the patients with nonunion desired later surgery although they did report at least occasional discomfort. At final follow-up, eight out of ten (80%) patients had returned to full activity. In a larger, long-term study by Nordqvist et al. [46], a total of 110 patients with various types of distal clavicle fractures were treated nonoperatively and followed for an average of 15 years after their injury. Outcomes were rated as fair in 15 patients who reported moderate pain and dysfunction; however, no patients reported severe shoulder disability or pain. The nonunion rate in their study was 9% and included more type II fractures but 80% of patients with a nonunion were asymptomatic. Their conclusions were that nonoperative treatment provides satisfactory results and operative management in many cases is likely unnecessary. Finally in a study by Rokito et al. [47], the authors retrospectively compared patients having either undergone nonsurgical management or open reduction and CC stabilization for a type II distal clavicle fracture. Despite early healing in the operative group and 44% of patients developing a nonunion in the nonoperative group, they found no significant differences in UCLA, Constant, or ASES scores between the two cohorts. Nonunion had no effect on functional outcome or strength leading the authors to conclude that type II fractures could be successfully treated nonoperatively.

Nonsurgical management has been proven to be successful for all types of distal clavicle fractures and could be supported in nearly all cases with the obvious exceptions being open injuries or skin compromise from excessive displacement. Despite this, the ultimate decision on ideal management is still based on multiple factors, most important of which are the patient's specific demands and activity level as well as acceptance of potential cosmetic deformity. If surgery is to be performed, the timing and acceptance of this decision is critical as delayed surgery has been shown to have markedly increased complication rates compared to acute management (36% vs. 7%) [48].

Surgical Management

The indications for surgical management of distal clavicle fractures are based largely on the stability of fracture fragments, patient age, and patient activity level. Absolute indications include open fractures or soft-tissue compromise, floating shoulder, or multiple trauma. Excessive displacement of the lateral clavicle, as seen in type II injuries with CC ligament disruption, has been shown to lead to nonunion in approximately one-third of cases [5, 42]. Multiple fixation methods have been described including Kirschner wire fixation, coracoclavicular screws, pre-contoured plates or hook-plate fixation, and suture or sling techniques to reconstruct the CC ligaments. Surgical management has shown to significantly reduce the incidence of nonunion and multiple techniques have provided good long-term outcomes.

However, the benefits over nonsurgical treatment are inconclusive [44, 46, 47] and complications vary significantly depending on the chosen technique with some having fallen out of favor due to unacceptably high complication rates.

Techniques for Surgical Fixation

Kirschner wire fixation for distal clavicle fractures has been reported in the literature with varied results. Local skin complication, wound infections, failure of fixation, and K-wire migration have all been reported [49, 50]. A comparative study evaluating outcomes between Kirschner wire fixation and hook-plate fixation was performed on 39 patients, showing acceptable and similar functional outcomes between both methods but with wire migration occurring in more than half of the cases and frequent loss of reduction [49]. Due to similar reports and experience with this method of fixation, it has largely been abandoned.

Hook-plate fixation is another option for managing displaced type II distal clavicle fractures. While successful stable reduction of the distal clavicle can be achieved, the associated issues of impingement, plate migration, and adjacent fracture are major disadvantages [51–54]. Oh and associates [43], in a large systematic review, evaluated multiple studies reporting on hook-plate fixation. Of all the surgical methods reviewed, hook plating was associated with a 40.7% complication rate with impingement and plate migration representing the vast majority of issues. Routine plate removal after fracture union is necessary to prevent these as well as other late complications associated with the hook-plate device [51–54].

The most successful techniques for distal clavicle fixation, reporting good outcomes and low complication rates, appear to be coracoclavicular stabilization, intramedullary fixation, and interfragmentary fixation. In the large systematic review by Oh et al. [43], coracoclavicular stabilization was performed on a total of 100 patients demonstrating a nonunion rate of 1% and a complication rate of 4.8%. Intramedullary fixation and interfragmentary plating or suturing (Fig. 11.3) was found to have no occurrences of nonunion and similarly low overall complication rates as compared to CC stabilization [43]. Although these favored methods led to bony union, when comparing outcome scores including UCLA, Constant, and American Shoulder and Elbow scores to those of nonoperative treatment, they found no significant differences in final outcomes.

As newer techniques and implants are developed, surgical results may continue to improve and the outcomes of these studies may change over time. The introduction of pre-contoured, locking plates specifically designed to address distal clavicle fractures has already led to improved fixation and may lower complications compared to previous plating methods. Interfragmentary fixation with either plating or suture fixation in combination with coracoclavicular stabilization may also provide a more ideal construct, leading to less failures and potentially fewer complications.

Many surgical options exist for the management of displaced distal clavicle fractures but a review of the current evidence shows unpredictable benefit from surgical management. Nonunion is frequent with nonsurgical treatment of these injuries but despite high rates of bony union and deformity correction after surgical treatment,

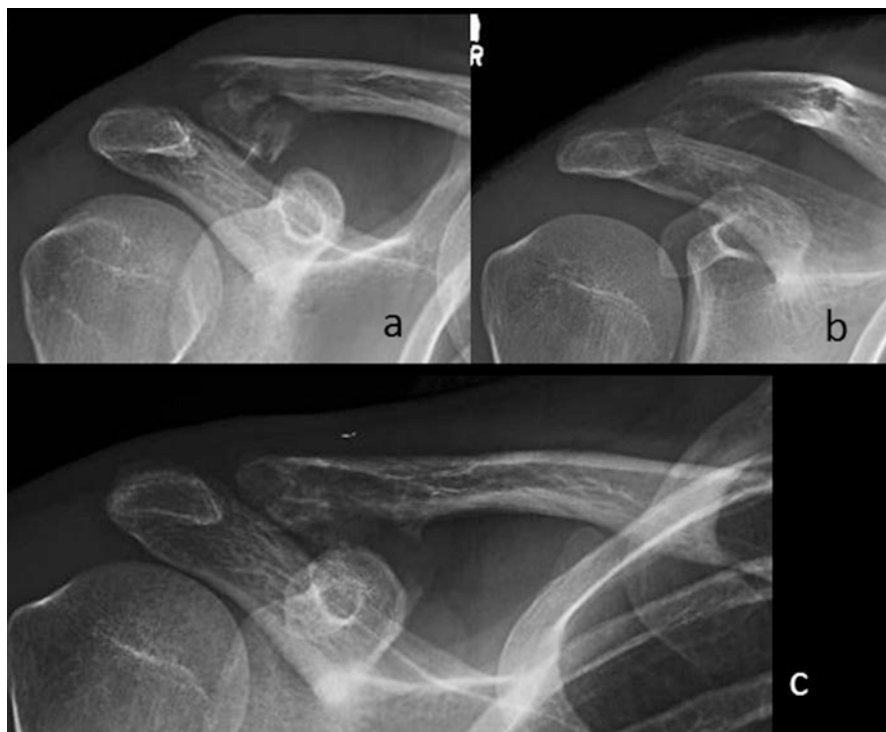


Fig. 11.3 (a and b) Plain radiographs of a displaced, comminuted Neer type II distal clavicle fracture. (c) Postoperative images demonstrating bony union and restoration of the coracoclavicular distance after suture-only interfragmentary and coracoclavicular fixation

outcomes remain similar between either method of management. Younger patients with excessive cosmetic deformity or higher demand individuals who may be more prone to continued discomfort likely represent the ideal surgical candidates. A discussion of the risks and complications specific to the chosen surgical technique for fixation is absolutely necessary.

Children and Adolescents

The distal clavicle physis is typically not completely fused until 25 years of age, and therefore distal clavicle injuries in the younger age group more commonly represent a physeal separation rather than a fracture. Due to the zone of injury being at the physis, a great potential for rapid, abundant healing and remodeling exists [55]. Functional outcomes are routinely excellent [55]. Consequently, nonoperative management should be the mainstay of treatment in the child and adolescent population. Rare exceptions for surgical intervention may present if open injury or soft-tissue compromise occurs.

Fractures of the Medial-Third

Nonoperative Treatment

Medial-third fractures of the clavicle are exceedingly rare, representing only 2–3% of all clavicle fractures [3–5, 56, 57]. They are routinely nondisplaced or minimally displaced and rarely extend to involve the sternoclavicular joint. Nonoperative treatment is the gold standard for medial-third fractures unless displacement is great enough that an open injury occurs or skin or neurovascular compromise is present. Sling or figure-of-eight bracing for comfort is initiated until pain allows for progression of activities, typically 2–6 weeks.

Surgical Management

Surgical indications for displaced medial clavicle fractures include skin tenting, open fracture, multiple trauma, “floating shoulder” injuries, and mediastinal neurovascular compromise. Plate fixation and transosseous sutures or wires have been described for treatment of these fractures [49, 58]. Kirschner wire fixation has been abandoned due to reported breakage and wire migration [59]. One of the largest studies reporting on the operative outcomes of medial clavicle fractures evaluated 24 patients after undergoing plate or transosseous suture fixation for an acute displaced medial clavicle injury [60]. At an average follow-up of 12 months, all patients obtained excellent outcomes assessed by the DASH score and all fractures united. There were no reported limitations in shoulder motion and all patients returned to preinjury levels of activity. No complications were reported.

Medial clavicle fractures are typically treated surgically only by necessity and nonoperative management is the predominant treatment of choice. The proximity of neurovascular structures to the medial clavicle make accurate diagnosis and evaluation for displacement critical. Advanced imaging such as computed tomography is indicated if there is suspicion for posterior displacement [61].

Children and Adolescents

Medial-third clavicle injuries in children and adolescents are similar to distal fractures in that they frequently represent physeal separations rather than fractures. The ossification centers at the medial clavicle rarely fuse prior to 25 years of age. It is critical, however, to differentiate between physeal separations and true sternoclavicular joint dislocations in this age group. Due to the difficulty in evaluating these injuries on plain radiographs, computed tomography should be obtained to help distinguish these entities and can also guide treatment if necessary [58, 61].

Conclusions

Clavicle fractures are common injuries that present treatment dilemmas depending on the particular fracture characteristics as well as patient's preinjury function and demands with the involved extremity. Recent literature has shown that surgical management for displaced injuries of the middle-third clavicle may improve patient's long-term pain and functional outcomes. As surgical intervention has become more prevalent, care must be taken in selecting the appropriate patients to provide maximal outcome benefits and reducing the incidence of complications. Hardware prominence and irritation are concerns for all fixation methods at any location on the clavicle due to its subcutaneous position with minimal soft-tissue coverage but low-profile implants and surgical approach may help to minimize patient complaints. Distal clavicle fractures are prone to nonunion with nonoperative treatment. However, while surgical intervention lowers this incidence, it does not appear to improve long-term outcomes and complication rates are unacceptably high with certain methods. Medial clavicle fractures are rare and as they are typically minimally displaced, are predominantly treated nonoperatively. Discussion and patient education prior to treatment is essential to achieve optimal outcomes and mitigate complications in clavicle fracture management.

References

1. Allman Jr FL. Fractures and ligamentous injuries of the clavicle and its articulation. *J Bone Joint Surg Am.* 1967;49:774–84.
2. Landin LA. Fracture patterns in children. Analysis of 8,682 fractures with special reference to incidence, etiology and secular changes in a Swedish urban population 1950-1979. *Acta Orthop Scand Suppl.* 1983;202:1–109.
3. Nordqvist A, Petersson C. The incidence of fractures of the clavicle. *Clin Orthop Relat Res.* 1994;300:127–32.
4. Postacchini F, Gumina S, De Santis P, Albo F. Epidemiology of clavicle fractures. *J Shoulder Elbow Surg.* 2002;11:452–6. doi:[10.1067/mse.2002.126613](https://doi.org/10.1067/mse.2002.126613).
5. Robinson CM. Fractures of the clavicle in the adult. Epidemiology and classification. *J Bone Joint Surg Br.* 1998;80:476–84.
6. Neer II CS. Nonunion of the clavicle. *JAMA.* 1960;172:1006–11.
7. Rowe CR. An atlas of anatomy and treatment of midclavicular fractures. *Clin Orthop Relat Res.* 1968;58:29–42.
8. Society COT. Nonoperative treatment compared with plate fixation of displaced midshaft clavicular fractures. A multicenter, randomized clinical trial. *J Bone Joint Surg Am.* 2007;89:1–10.
9. George DM, McKay BP, Jaarsma RL. The long-term outcome of displaced mid-third clavicle fractures on scapular and shoulder function: variations between immediate surgery, delayed surgery, and nonsurgical management. *J Shoulder Elbow Surg.* 2015;24:669–76. doi:[10.1016/j.jse.2014.09.037](https://doi.org/10.1016/j.jse.2014.09.037).
10. Hill JM, McGuire MH, Crosby LA. Closed treatment of displaced middle-third fractures of the clavicle gives poor results. *J Bone Joint Surg Br.* 1997;79:537–9.
11. Kulshrestha V, Roy T, Audige L. Operative versus nonoperative management of displaced midshaft clavicle fractures: a prospective cohort study. *J Orthop Trauma.* 2011;25:31–8. doi:[10.1097/BOT.0b013e3181d8290e](https://doi.org/10.1097/BOT.0b013e3181d8290e).

12. McKee MD, Pedersen EM, Jones C, Stephen DJ, Kreder HJ, Schemitsch EH, Wild LM, Potter J. Deficits following nonoperative treatment of displaced midshaft clavicular fractures. *J Bone Joint Surg Am.* 2006;88:35–40. doi:[10.2106/JBJS.D.02795](https://doi.org/10.2106/JBJS.D.02795).
13. McKee RC, Whelan DB, Schemitsch EH, McKee MD. Operative versus nonoperative care of displaced midshaft clavicular fractures: a meta-analysis of randomized clinical trials. *J Bone Joint Surg Am.* 2012;94:675–84. doi:[10.2106/JBJS.J.01364](https://doi.org/10.2106/JBJS.J.01364).
14. Nordqvist A, Petersson CJ, Redlund-Johnell I. Mid-clavicle fractures in adults: end result study after conservative treatment. *J Orthop Trauma.* 1998;12:572–6.
15. Nowak J, Holgersson M, Larsson S. Can we predict long-term sequelae after fractures of the clavicle based on initial findings? A prospective study with nine to ten years of follow-up. *J Shoulder Elbow Surg.* 2004;13:479–86. doi:[10.1016/j.jse.2004.01.026](https://doi.org/10.1016/j.jse.2004.01.026).
16. Robinson CM, Court-Brown CM, McQueen MM, Wakefield AE. Estimating the risk of non-union following nonoperative treatment of a clavicular fracture. *J Bone Joint Surg Am.* 2004;86-A:1359–65.
17. Chen CH, Chen JC, Wang C, Tien YC, Chang JK, Hung SH. Semitubular plates for acutely displaced midclavicular fractures: a retrospective study of 111 patients followed for 2.5 to 6 years. *J Orthop Trauma.* 2008;22:463–6. doi:[10.1097/BOT.0b013e31817996fc](https://doi.org/10.1097/BOT.0b013e31817996fc).
18. Zlowodzki M, Zelle BA, Cole PA, Jeray K, MD MK. Evidence-based orthopaedic Trauma Working Group. Treatment of acute midshaft clavicle fractures: systematic review of 2144 fractures: on behalf of the Evidence-Based Orthopaedic Trauma Working Group. *J Orthop Trauma.* 2005;19:504–7.
19. Böstman O, Manninen M, Pihlajamäki H. Complications of plate fixation in fresh displaced midclavicular fractures. *J Trauma.* 1997;43(5):778–83.
20. Duncan SF, Sperling JW, Steinmann S. Infection after clavicle fractures. *Clin Orthop Relat Res.* 2005;439:74–8. doi:[10.1097/01.blo.0000183088.60639.05](https://doi.org/10.1097/01.blo.0000183088.60639.05).
21. Formaini N, Taylor BC, Backes J, Bramwell TJ. Superior versus anteroinferior plating of clavicle fractures. *Orthopedics.* 2013;36:e898–904. doi:[10.3928/01477447-20130624-20](https://doi.org/10.3928/01477447-20130624-20).
22. Johnson B, Thursby P. Subclavian artery injury caused by a screw in a clavicular compression plate. *Cardiovasc Surg.* 1996;4:414–5.
23. Wang K, Dowrick A, Choi J, Rahim R, Edwards E. Post-operative numbness and patient satisfaction following plate fixation of clavicular fractures. *Injury.* 2010;41:1002–5. doi:[10.1016/j.injury.2010.02.028](https://doi.org/10.1016/j.injury.2010.02.028).
24. Andersen K, Jensen PO, Lauritzen J. Treatment of clavicular fractures. Figure-of-eight bandage versus a simple sling. *Acta Orthop Scand.* 1987;58:71–4.
25. Eskola A, Vainionpää S, Myllynen P, Päätiälä H, Rokkanen P. Outcome of clavicular fracture in 89 patients. *Arch Orthop Trauma Surg.* 1986;105:337–8.
26. Ersen A, Atalar AC, Birisik F, Saglam Y, Demirhan M. Comparison of simple arm sling and figure of eight clavicular bandage for midshaft clavicular fractures: a randomised controlled study. *Bone Joint J.* 2015;97-B:1562–6. doi:[10.1302/0301-620X.97B11.35588](https://doi.org/10.1302/0301-620X.97B11.35588).
27. Navarro RA, Gelber JD, Harrast JJ, Seiler III JG, Jackson KR, Garcia IA. Frequency and complications after operative fixation of clavicular fractures. *J Shoulder Elbow Surg.* 2016; doi:[10.1016/j.jse.2015.11.065](https://doi.org/10.1016/j.jse.2015.11.065). [Epub ahead of print]
28. Robinson CM, Goudie EB, Murray IR, Jenkins PJ, Ahktar MA, Read EO, et al. Open reduction and plate fixation versus nonoperative treatment for displaced midshaft clavicular fractures: a multicenter, randomized, controlled trial. *J Bone Joint Surg Am.* 2013;95:1576–84. doi:[10.2106/JBJS.L.00307](https://doi.org/10.2106/JBJS.L.00307).
29. Wijdicks FJ, Van der Meijden OA, Millett PJ, Verleisdonk EJ, Houwert RM. Systematic review of the complications of plate fixation of clavicle fractures. *Arch Orthop Trauma Surg.* 2012;132:617–25. doi:[10.1007/s00402-011-1456-5](https://doi.org/10.1007/s00402-011-1456-5).
30. Golish SR, Oliviero JA, Francke EI, Miller MD. A biomechanical study of plate versus intramedullary devices for midshaft clavicle fixation. *J Orthop Surg Res.* 2008;3:28. doi:[10.1186/1749-799X-3-28](https://doi.org/10.1186/1749-799X-3-28).
31. Duan X, Zhong G, Cen S, Huang F, Xiang Z. Plating versus intramedullary pin or conservative treatment for midshaft fracture of clavicle: a meta-analysis of randomized controlled trials. *J Shoulder Elbow Surg.* 2011;20:1008–15. doi:[10.1016/j.jse.2011.01.018](https://doi.org/10.1016/j.jse.2011.01.018).

32. Ferran NA, Hodgson P, Vannet N, Williams R, Evans RO. Locked intramedullary fixation vs plating for displaced and shortened mid-shaft clavicle fractures: a randomized clinical trial. *J Shoulder Elbow Surg.* 2010;19:783–9. doi:[10.1016/j.jse.2010.05.002](https://doi.org/10.1016/j.jse.2010.05.002).
33. Liu HH, Chang CH, Chia WT, Chen CH, Tarng YW, Wong CY. Comparison of plates versus intramedullary nails for fixation of displaced midshaft clavicular fractures. *J Trauma.* 2010;69:E82–7. doi:[10.1097/TA.0b013e3181e03d81](https://doi.org/10.1097/TA.0b013e3181e03d81).
34. Thyagarajan DS, Day M, Dent C, Williams R, Evans R. Treatment of mid-shaft clavicle fractures: A comparative study. *Int J Shoulder Surg.* 2009;3:23–7. doi:[10.4103/0973-6042.57895](https://doi.org/10.4103/0973-6042.57895).
35. Favre P, Kloen P, Helfet DL, Werner CM. Superior versus anteroinferior plating of the clavicle: a finite element study. *J Orthop Trauma.* 2011;25:661–5. doi:[10.1097/BOT.0b013e3182143e06](https://doi.org/10.1097/BOT.0b013e3182143e06).
36. Iannotti MR, Crosby LA, Stafford P, Grayson G, Goulet R. Effects of plate location and selection on the stability of midshaft clavicle osteotomies: a biomechanical study. *J Shoulder Elbow Surg.* 2002;11:457–62. doi:[10.1067/mse.2002.125805](https://doi.org/10.1067/mse.2002.125805).
37. Partal G, Meyers KN, Sama N, Pagenkopf E, Lewis PB, Goldman A, et al. Superior versus anteroinferior plating of the clavicle revisited: a mechanical study. *J Orthop Trauma.* 2010;24:420–5. doi:[10.1097/BOT.0b013e3181c3f6d4](https://doi.org/10.1097/BOT.0b013e3181c3f6d4).
38. Hulsmans MH, van Heijl M, Houwert RM, Timmers TK, van Olden G, Verleisdonk EJ. Anteroinferior versus superior plating of clavicular fractures. *J Shoulder Elbow Surg.* 2016;25:448–54. doi:[10.1016/j.jse.2015.09.005](https://doi.org/10.1016/j.jse.2015.09.005).
39. Calder JD, Solan M, Gidwani S, Allen S, Ricketts DM. Management of paediatric clavicle fractures--is follow-up necessary? An audit of 346 cases. *Ann R Coll Surg Engl.* 2002;84:331–3.
40. Vander Have KL, Perdue AM, Caird MS, Farley FA. Operative versus nonoperative treatment of midshaft clavicle fractures in adolescents. *J Pediatr Orthop.* 2010;30:307–12. doi:[10.1097/BPO.0b013e3181db3227](https://doi.org/10.1097/BPO.0b013e3181db3227).
41. Hagstrom LS, Ferrick M, Galpin R. Outcomes of operative versus nonoperative treatment of displaced pediatric clavicle fractures. *Orthopedics.* 2015;38:e135–8. doi:[10.3928/01477447-20150204-62](https://doi.org/10.3928/01477447-20150204-62).
42. Neer II CS. Fractures of the distal third of the clavicle. *Clin Orthop Relat Res.* 1968;58:43–50.
43. Oh JH, Kim SH, Lee JH, Shin SH, Gong HS. Treatment of distal clavicle fracture: a systematic review of treatment modalities in 425 fractures. *Arch Orthop Trauma Surg.* 2011;131:525–33. doi:[10.1007/s00402-010-1196-y](https://doi.org/10.1007/s00402-010-1196-y).
44. Deafenbaugh MK, Dugdale TW, Staeheli JW, Nielsen R. Nonoperative treatment of Neer type II distal clavicle fractures: a prospective study. *Contemp Orthop.* 1990;20:405–13.
45. Edwards DJ, Kavanagh TG, Flannery MC. Fractures of the distal clavicle: a case for fixation. *Injury.* 1992;23:44–6.
46. Nordqvist A, Petersson C, Redlund-Johnell I. The natural course of lateral clavicle fracture. 15 (11-21) year follow-up of 110 cases. *Acta Orthop Scand.* 1993;64:87–91.
47. Rokito AS, Zuckerman JD, Shaari JM, Eisenberg DP, Cuomo F, Gallagher MA. A comparison of nonoperative and operative treatment of type II distal clavicle fractures. *Bull Hosp Jt Dis.* 2002;61:32–9.
48. Klein SM, Badman BL, Keating CJ, Devinney DS, Frankle MA, Mighell MA. Results of surgical treatment for unstable distal clavicular fractures. *J Shoulder Elbow Surg.* 2010;19:1049–55. doi:[10.1016/j.jse.2009.11.056](https://doi.org/10.1016/j.jse.2009.11.056).
49. Flinkkilä T, Ristiniemi J, Hyvönen P, Hämäläinen M. Surgical treatment of unstable fractures of the distal clavicle: a comparative study of Kirschner wire and clavicular hook plate fixation. *Acta Orthop Scand.* 2002;73:50–3.
50. Kona J, Bosse MJ, Staeheli JW, Rosseau RL. Type II distal clavicle fractures: a retrospective review of surgical treatment. *J Orthop Trauma.* 1990;4:115–20.
51. Haidar SG, Krishnan KM, Deshmukh SC. Hook plate fixation for type II fractures of the lateral end of the clavicle. *J Shoulder Elbow Surg.* 2006;15:419–23. doi:[10.1016/j.jse.2005.11.012](https://doi.org/10.1016/j.jse.2005.11.012).
52. Kashii M, Inui H, Yamamoto K. Surgical treatment of distal clavicle fractures using the clavicular hook plate. *Clin Orthop Relat Res.* 2006;447:158–64. doi:[10.1097/01.blo.0000203469.66055.6a](https://doi.org/10.1097/01.blo.0000203469.66055.6a).

53. Muramatsu K, Shigetomi M, Matsunaga T, Murata Y, Taguchi T. Use of the AO hook-plate for treatment of unstable fractures of the distal clavicle. *Arch Orthop Trauma Surg.* 2007;127:191–4. doi:[10.1007/s00402-006-0284-5](https://doi.org/10.1007/s00402-006-0284-5).
54. Renger RJ, Roukema GR, Reurings JC, Raams PM, Font J, Verleisdonk EJ. The clavicle hook plate for Neer type II lateral clavicle fractures. *J Orthop Trauma.* 2009;23:570–4. doi:[10.1097/BOT.0b013e318193d878](https://doi.org/10.1097/BOT.0b013e318193d878).
55. Bishop JY, Flatow EL. Pediatric shoulder trauma. *Clin Orthop Relat Res.* 2005;432:41–8. doi:[10.1097/01.blo.0000156005.01503.43](https://doi.org/10.1097/01.blo.0000156005.01503.43).
56. O'Neill BJ, Hirpara KM, O'Briain D, McGarr C, Kaar TK. Clavicle fractures: a comparison of five classification systems and their relationship to treatment outcomes. *Int Orthop.* 2011;35:909–14. doi:[10.1007/s00264-010-1151-0](https://doi.org/10.1007/s00264-010-1151-0).
57. Stanley D, Trowbridge EA, Norris SH. The mechanism of clavicular fracture. A clinical and biomechanical analysis. *J Bone Joint Surg Br.* 1988;70:461–4.
58. Lewonowski K, Bassett GS. Complete posterior sternoclavicular epiphyseal separation. A case report and review of the literature. *Clin Orthop Relat Res.* 1992;281:84–8.
59. Hegemann S, Kleining R, Schindler HG, Holthusen H. Kirschner wire migration in the contralateral lung after osteosynthesis of a clavicular fracture. *Unfallchirurg.* 2005;108:991–3.
60. Sidhu VS, Hermans D, Duckworth DG. The operative outcomes of displaced medial-end clavicle fractures. *J Shoulder Elbow Surg.* 2015;24:1728–34. doi:[10.1016/j.jse.2015.04.011](https://doi.org/10.1016/j.jse.2015.04.011).
61. Hanby CK, Pasque CB, Sullivan JA. Medial clavicle physis fracture with posterior displacement and vascular compromise: the value of three-dimensional computed tomography and duplex ultrasound. *Orthopedics.* 2003;26:81–4. doi:[10.3928/0147-7447-20030101-20](https://doi.org/10.3928/0147-7447-20030101-20).

Chapter 12

Pediatric Clavicle Injuries

Katherine C. Faust, Robert K. Lark, and Fraser J. Leversedge

Growth of the Clavicle

The clavicle and mandible are the first bones to ossify in utero, occurring through a process of membranous ossification. The clavicle may be identified as early as when the embryo reaches 11 mm in length. It develops as two precartilaginous masses within perichondrium that fuse by the time the embryo is approximately 18–19 mm in length [1], or 45 days gestational age [2]. The lateral ossification center matures at a faster rate than its medial counterpart; these centers subsequently fuse to form the central clavicle. Cells on both the acromial and sternal ends remain chondroblastic [3]. Longitudinal growth is greater at the sternal compared to the acromial end, and a secondary ossification center appears on the sternal side at approximately 18 years of age although this can occur as early as 11 years old in females and 16 years old in males [4]. Studies evaluating serial postnatal radiographs have determined that the average growth is 8.4 mm per year (mm/y) for males and females up to age 12 years, at which time the growth rate slows to 5.4 mm/year for males and 2.6 mm/year for females [5]. Complete fusion of the secondary ossification center with the rest of the clavicle occurs by 21–22 years of age, occasionally as late as 25–26 years of age. This medial secondary ossification center is the last physis to achieve maturity in humans [4].

Anatomic Detail of the Clavicle

The clavicle develops as a double curve which is convex anterior throughout the medial two-thirds and concave anterior in the lateral one-third. The transition between these two curves has been demonstrated as a focal area of weakness when

K.C. Faust, M.D. • R.K. Lark, M.D. • F.J. Leversedge, M.D. (✉)
Department of Orthopaedic Surgery, Duke University, DUMC Box 2836, Durham,
NC 27710, USA
e-mail: fraser.leversedge@duke.edu

stress is applied to the bone [4]. Anatomic landmarks on the surface of the bone include the deltoid tuberosity (sometimes referred to as a “tubercle”), the conoid tubercle, the trapezoid line, and the subclavian groove. The deltoid tuberosity is palpable on the lateral aspect of clavicle, located laterally at a length 35–37% of the clavicle’s length [6]. The conoid tubercle and trapezoid lines are the origins of the conoid and trapezoid ligaments, respectively, which together comprise the coracoclavicular ligament that connects the clavicle and coracoid process of the scapula. The origin of the conoid ligament is more medial than that of the trapezoid ligament. The acromioclavicular ligament runs from the lateral clavicle to the medial acromion to support the acromioclavicular joint. The subclavian groove serves as the insertion of the subclavius muscle, which depresses and pulls the clavicle forward. The clavicle is an origin or insertion for numerous muscles of the shoulder girdle including the deltoid, pectoralis major, sternocleidomastoid, sternohyoid, subclavius, sternocleidomastoid, sternohyoid, and trapezius muscles. The clavicle articulates with the sternum at the manubrium (clavicular notch); this articulation is notable for its articular disc and its strong restraining ligaments. The vascular supply to the clavicle is predominantly periosteal from the suprascapular, thoracoacromial, and internal thoracic arteries and it is essentially without nutrient arteries [7].

Clavicle Fractures

The clavicle is the most frequently fractured bone of newborns and in children [8–11]. The overall incidence of clavicle fractures during the birthing process is 0.41%, but is higher with vaginal deliveries (0.65%) compared to cesarean sections (0.05%) [12]. The diagnosis of a fracture may be difficult [8] but increased suspicion is warranted in the presence of a complicated birth such as involving increased maternal age, larger infant birth weight, meconium passage, maternal diabetes, and other neonatal abnormalities [13]. Shoulder dystocia and vaginal delivery have not been shown statistically to be risk factors for clavicle fracture in some studies [13] although maneuvers during delivery may contribute to clavicle fracture. Other studies suggest there is a statistical relationship between shoulder dystocia and clavicle fracture [14]. In fact, in the algorithm for managing shoulder dystocia, iatrogenic clavicular fracture is listed, though sources repeatedly caution its use or cite it for historical purposes only [11, 15–17]. A combination of crepitus, deformity, localized tenderness, and a “palpable spongy mass sign” are highly sensitive and predictive of fracture [18]. Some neonates with a clavicle fracture will have a normal Moro reflex, and there may be no swelling or bruising. Interestingly, nearly half (43.6%) of clavicle fractures in newborns are incidental findings on chest radiographs obtained to evaluate respiratory compromise [8]. Although user dependent, ultrasound has become a useful diagnostic tool for the evaluation of a potential clavicle fracture; a recent study demonstrated 95% sensitivity and 96% specificity, a 95% positive predictive value, a 96% negative predictive value, and an overall accuracy of 96% [19]. Infants with clavicle fractures are readmitted or placed in

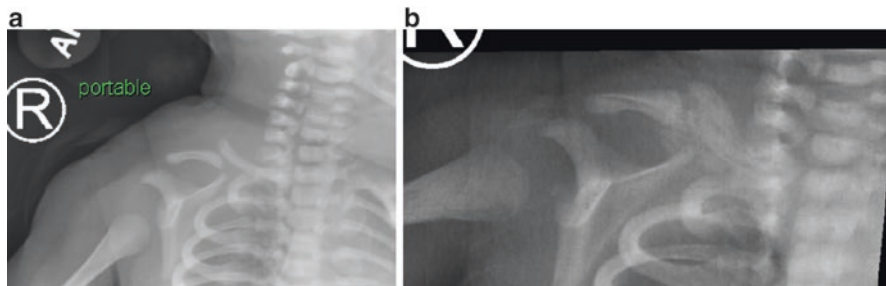


Fig. 12.1 Newborn with shoulder dystocia during delivery sustained a closed right clavicle fracture (a). There was no clinical evidence of birth brachial plexus injury with normal neurologic examination at 2 weeks and 1 year. Follow-up radiograph of the infant at 2 weeks of age demonstrated abundant callous formation (b)

special care units associated with other diagnoses at a higher rate than infants without clavicle fractures.

Perinatal clavicle fractures heal rapidly with subperiosteal new bone formation appearing between 7 and 10 days, its presence potentially aiding in the diagnostic evaluation. The new bone increases in thickness and transitions from single- to multilayered over time. Maturation of the callus involves matrix remodeling from soft to intermediate to hard callous [20]. Often, a conspicuous bony exuberance in the area of the fracture is present for months as the fracture remodels (Fig. 12.1). Refracture through the zone of injury can occur; a case report described a 9-month-old whose original injury occurred at 2 weeks of age [21].

Clavicle fractures in older children are commonly the result of injuries associated with trauma, play, or sports. In a retrospective study of 3666 pediatric patients involved in road traffic accidents, 17% of upper extremity fractures involved the clavicle [22]. The Robinson classification for clavicle fractures considers the anatomical location of the fracture, and classification subtypes denote the presence of fracture displacement and whether there is intra-articular involvement [23]. (Table 12.1.) Medial physeal fractures, often misdiagnosed as sternoclavicular (SC) dislocations in younger adult patients, occur because the physis fails before the stronger sternoclavicular ligaments. A Type 1 Salter–Harris fracture is the most common injury associated with substantial trauma [24]. Acromioclavicular (AC) dislocations in children are generally metaphyseal or physeal injuries with accompanying periosteal sleeve avulsions. Importantly, this distinction influences treatment principles and outcomes, as pediatric AC and SC fractures do not cause ligamentously unstable joints when the fractures heal.

Typically, closed pediatric clavicle fractures are diagnosed with radiographs (primarily anteroposterior and cephalic tilt) and treated conservatively through a strategy of protective immobilization in a sling and early controlled range of motion of the involved limb. For midshaft clavicular fractures in neonates, nonoperative management with arm immobilization using a stockinet or long sleeved shirt safety pinned to the torso portion of the shirt is indicated for 1–2 weeks. Reassurance and counseling of the parents to avoid motion of the extremity that causes pain is beneficial; controlled

Table 12.1. Robinson classification of clavicle fractures (modified from: Robinson 1998) [23]

Type 1: medial one-fifth
Type 1A: nondisplaced
Type 1A1: nondisplaced, extra-articular
Type 1A2: nondisplaced, intra-articular
Type 1B: displaced
Type 1B1: displaced, extra-articular
Type 1B2: displaced, intra-articular
Type 2: middle three-fifths
Type 2A: cortical alignment
Type 2A1: nondisplaced
Type 2A2: angulated
Type 2B: displaced
Type 2B1: simple or wedge-comminuted
Type 2B2: comminuted, segmental
Type 3: lateral one fifth
Type 3A: nondisplaced
Type 3A1: nondisplaced, extra-articular
Type 3A2: nondisplaced, intra-articular
Type 3B: displaced
Type 3B1: displaced, extra-articular
Type 3B2: displaced, intra-articular

and protected motion of the involved limb will be tolerated generally when bridging callous is identified on plain radiographs. In older children, nonoperative management with a sling for 3–6 weeks is preferred. Indications for surgical management include open fracture, impending open fracture (due to soft tissue compromise), and neurologic or vascular compromise requiring exploration. Athletic children may benefit from fixation of displaced fractures similar to the indications in adults (kickstand fragment, fractures with >2 cm shortening). Surgical options include periosteal sleeve suturing in young children and plating or intramedullary fixation in older children. Lateral clavicular fractures without disruption of the acromioclavicular and coracoclavicular generally heal well with nonoperative management although surgical fixation and suture repair of the periosteal sleeve is an option for intra-articular and displaced fractures (Robinson type 3B). Surgical reduction and repair of medial clavicular fractures are indicated generally for posteriorly displaced fractures due to the risk of compression of the great vessels and/or other mediastinal structures. Preoperatively, a computed tomography (CT) study can be beneficial. A cardiothoracic surgeon should be consulted and on standby if operative fixation is performed based on the proximity of the fracture and relative risk to vital structures and to the pleura. Initial management of displaced fractures involves closed reduction under anesthesia in the OR. A posteriorly directed force is exerted on the shoulder with the arm adducted to the body; if stable reduction is obtained, a figure-of-eight harness or sling can be utilized for 3–6 weeks. If the fracture remains unstable or unacceptably displaced despite attempts at closed reduction, open reduction and stabilization using suture fixation through bone tunnels in the sternum and clavicle is recommended [25].

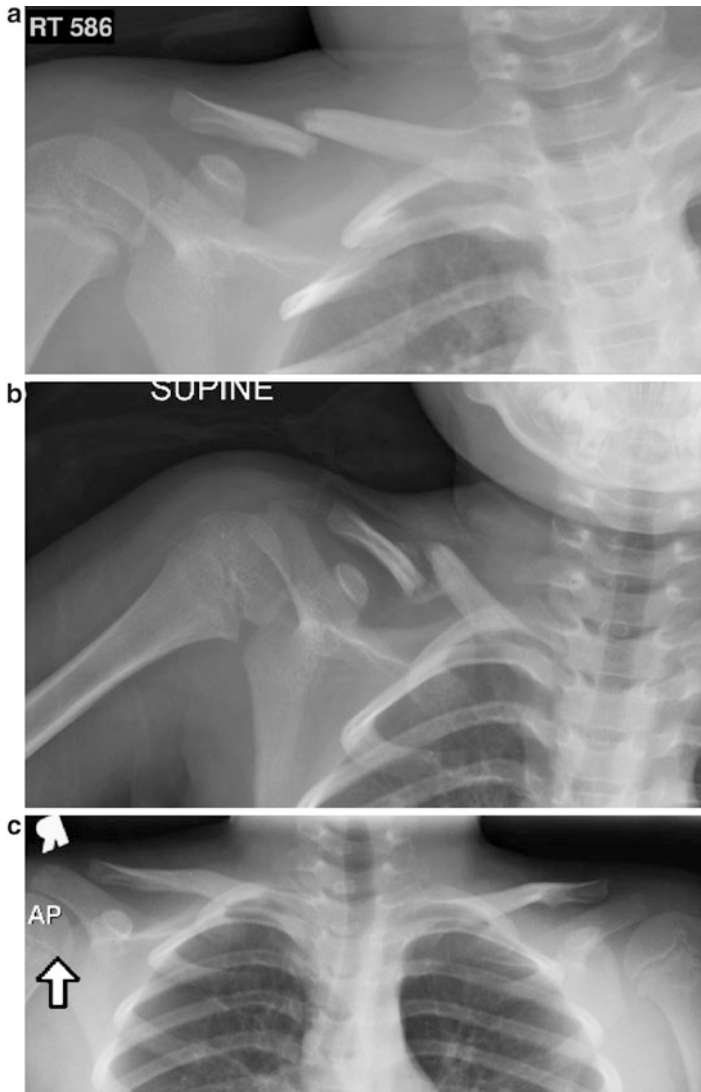


Fig. 12.2 A displaced, minimally shortened, mid-diaphyseal right clavicle in a 7-year-old male who fell while playing football (a). The fracture was treated nonoperatively with a sling immobilization and protected activity and at 4 weeks following injury, early callous was identified radiographically (b). Gradually advancing controlled range of motion in the absence of symptoms was advised from 4 to 8 weeks from injury, and return to unrestricted activity was permitted at 12 weeks. A 1-year follow-up radiograph (c) demonstrates fracture union and remodeling

Outcomes of nonoperative management of pediatric clavicle fractures are generally good to excellent (Fig. 12.2) [26]. Complications of nonoperative treatment include nonunion, malunion, refracture, pain, loss of motion, weakness, and cosmetic deformity. Osteomyelitis in the setting of previously undiagnosed closed clavicle fracture

has been described in the neonatal population [27]. Confounding injuries involving the brachial plexus of vascular structures associated with the index trauma likely correlate with the increasing energy imparted to the region during injury (Fig. 12.3). Previous authors have proposed that failure of the clavicle is protective of the plexus in the setting of ipsilateral clavicle fracture and brachial plexus palsy, as these palsies tend to be less severe and resolve without intervention compared to those injuries to the brachial plexus that are not associated with a clavicle fracture [28]. Wu et al. reported on an arteriovenous fistula discovered at time of surgical fixation of posttraumatic nonunion in an adolescent initially treated nonoperatively for 6 months [29].

Open treatment of fractures can be complicated by adverse events associated with wound healing, neurovascular injury, and infection, as well as those issues associated with closed treatment. To our knowledge, the rare injuries that indicate operative fixation (Robinson 1B and 3B fractures) have limited outcomes reporting based on a review of the literature. A comparison of adolescents treated surgically to adolescents treated nonsurgically revealed a complication rate of 21.7% for surgical patients: refracture, need for plate removal secondary to hardware prominence, and nonunion. In comparison, no refractures nor malunions necessitating surgery occurred in the nonoperative group. Selection bias was unavoidable; however, adolescents treated surgically were more likely to have fractures with greater displacement and comminution compared to the nonsurgical group [30]. Li et al. reported complications in 86% of patients with midshaft clavicle fractures treated with surgical plate and screw fixation [31]. Complications included hardware prominence, chest wall numbness, wound healing complications, secondary fracture around the plate or following plate removal. Danisman et al. described a brachial plexus palsy and concomitant ipsilateral clavicle fracture [14, 15]. Patient satisfaction has been reported high at 1 year for 10–15-year-olds treated with intramedullary nailing of clavicle fractures [32]. When time to return to full activity is compared for operatively versus nonoperatively treated clavicle fractures in the pediatric population, no statistical difference has been reported between these two groups. Time to full shoulder range of motion was 7.85 weeks in the nonoperative group versus 8.74 weeks in the operative cohort. Time to radiographic healing, and DASH scores were not statistically different between operatively and nonoperatively treated fractures [33].

Refracture of the clavicle is not uncommon. Matey et al. reported 21% refracture rates (defined as 1 year or more after initial fracture) in patients treated nonoperatively. All refractures occurred during trauma, sports, or play. Interestingly, fractures that were less angulated were more likely to refracture than those with 100% or more displacement. Angulation inversely correlated with fracture risk, hypothesized due to the direct correlation between amount of angulation and amount of callus [34].

The adverse structural influences of clavicle malunion on function in pediatric patients have been debated. Waters et al. found 100% union rate in a group of patients with >2 cm displacement of midshaft clavicle fractures. In comparing the injured to the noninjured side, there was <8° loss of motion in forward flexion and abduction of the shoulder, but no difference in strength testing. One patient required corrective osteotomy following initial fracture union [35]. McGraw et al. demonstrated that girls older than 9 and boys older than 12 years of age have less than 20%

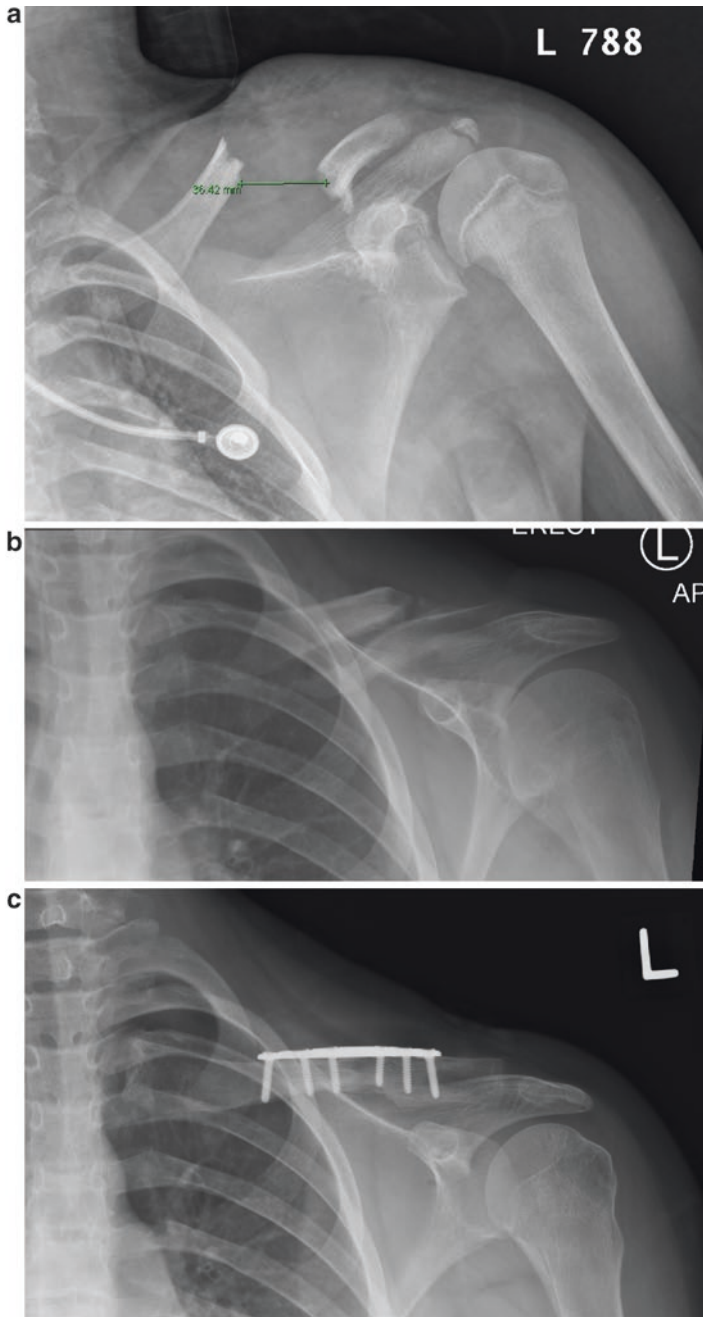


Fig. 12.3 A high-energy injury mechanism raises the concern for associated brachial plexus and/or vascular injury, and a scapulothoracic dissociation. This 10-year-old male, restrained passenger, sustained a closed, displaced left clavicle fracture in a motor vehicle accident (a). A brachial plexus neuropraxia resolved by 4 months from injury; however, substantial overlap of the fracture segments was noted (b). Surgical open reduction and internal fixation was performed with return to full, unrestricted activity at 9 months from injury (c)

of growth remaining and concluded that for this group, surgical consideration should be included for length-unstable fractures [5]. This is supported by the observation that if there is 10% relative shortening of the clavicle, posterior tilting and loss of scapula external rotation occurs [36]. The change in scapulothoracic dynamics could impact shoulder endurance and overhead activities.

Pseudarthrosis of the Clavicle

One unique congenital birth difference involving the shoulder girdle is pseudarthrosis of the clavicle. This is a benign condition that occurs on the right side and in the middle third of the clavicle, except in the presence of situs inversus when it occurs on the left side. This variation associated with situs inversus led to the hypothesis that pseudarthrosis is caused by palpations of the subclavian artery [37]. Initially described in 1910, it involves a failure of ossification between the two precartilaginous masses in utero, and is not associated with a syndrome such as cleidocranial dysplasia [1]. It is bilateral in 10% and is more common in females than in males [2]. There is no known association of pseudarthrosis with trauma. A ligamentous structure connects the broad ends of the medial and lateral clavicular segments (unlike a narrow, atrophic nonunion). The natural history includes increasing deformity of the clavicle that can cause secondary and local effects. Although functional deficit or neurovascular compromise (thoracic outlet syndrome) is rare, outcomes of pseudarthrosis repair are improved when bone grafting is used as part of the reconstruction strategy [1]. Nonsurgical treatment may leave the affected arm in an inferiorly directed position and can be painful, possibly associated with altered shoulder mechanics. Thoracic outlet syndrome has been reported in conjunction with clavicle pseudarthrosis, but is rare [2]. Shalom et al. reported a case of a 45-year-old right-hand-dominant ear, nose, and throat surgeon with pseudarthrosis treated conservatively with a cosmetic defect only and no limitations in motion nor activity compared to the other arm [38].

Conclusion

Clavicle injuries in children are not uncommon and should be considered in the neonatal/perinatal, childhood, and adolescent age groups. Management strategies differ from those injuries in adults due to the skeletal immaturity and remodeling potential. Fractures are classified by their location based on AP and cephalic tilt radiographs: medial, middle, or lateral. Most fractures are treated nonoperatively with a sling or figure-of-eight brace with good to excellent results. Surgical intervention is recommended for open fractures or for impending open fractures, and when neurovascular or mediastinal structure compromise exists. Many displaced pediatric clavicle fractures can be treated with periosteal suturing as opposed to

hardware fixation. Surgical repair of displaced fractures may be recommended in certain patients if there is >2 cm of displacement or a classic “kickstand” fragment. Ultimately, treatment should be individualized; however, increased risks of surgery, general functional tolerance of mild malunion, and remodeling potential of the immature skeleton often support nonoperative fracture management. In both surgical and nonsurgical cases, refracture rates are not insignificant and, therefore, patient and family education is essential regarding outcomes.

References

1. Alldred AJ. Congenital pseudoarthrosis of the clavicle. *J Bone Joint Surg Br.* 1963;45B(2):312–9.
2. Currarino G, Herring JA. Congenital pseudarthrosis of the clavicle. *Pediatr Radiol.* 2009;39:1343–9.
3. Gardner E. The embryology of the clavicle. *Clin Orthop Relat Res.* 1968;58:9–16.
4. Ogden JA, Conlogue GJ, Bronson MB. Radiology of postnatal skeletal development. *Skeletal Radiol.* 1979;4:196–203.
5. McGraw MA, Mehlman CT, Lindsell CJ, Kirby CL. Postnatal growth of the clavicle: birth to eighteen years of age. *J Pediatr Orthop.* 2009;29(8):937–43.
6. Lirk P, von Goedecke A, Keller C, Moriggl B, Wenzel V, Bale R, et al. An anatomic landmark to simplify subclavian vein cannulation: the “deltoid tuberosity.” *Anesth Analg.* 2005;100:623–628.
7. Knudsen FW, Andersen M, Krag C. The arterial supply of the clavicle. *Surg Radiol Anat.* 1989;11(3):211–4.
8. Ahn ES, Jung MS, Lee YK, Ko SY, Shin SM, Hahn MH. Neonatal clavicular fracture: recent 10 year study. *Pediatr Int.* 2015;57(1):60–3.
9. Curtis RJ Jr. Operative management of children’s fractures of the shoulder region. *Orthop Clin North Am.* 1990;21(2):315–24.
10. Kubiak R, Slongo T. Operative treatment of clavicle fractures in children: a review of 21 years. *J Pediatr Orthop.* 2002;22(6):736–9.
11. Stitely ML, Gherman RB. Shoulder dystocia: management and documentation. *Semin perinatol.* 2014;38(4):194–200.
12. Gherman RB, Ouzounian JG, Miller DA, Kwok L, Goodwin TM. Spontaneous vaginal delivery: a risk factor for Erb’s palsy? *Am J Obstet Gynecol.* 1998;178(3):423–7.
13. Beall MH, Ross MG. Clavicle fracture in labor: risk factors and associated morbidities. *J Perinatol.* 2001;21(9):513–5.
14. Iskender C, Kaymak O, Erkenekli K, Ustunvurt E, Uygur D, Yakut HI, Danisman N. Neonatal injury at cephalic vaginal delivery: a retrospective analysis of extent of association with shoulder dystocia. *PLoS One.* 2014;9(8):1–6.
15. American College of Obstetricians and Gynecologists. Shoulder dystocia; ACOG practice bulletin No.40. *Obstet Gynecol.* 2002;100:1045–1050.
16. Gottlieb AG, Galan HL. Shoulder dystocia: an update. *Obstet Gynecol Clin North Am.* 2007;34(3):501–31, xii.
17. Politi S, D’emidio L, Cignini P, Giorlandino M, Giorlandino C. Shoulder dystocia: an evidence-based approach. *J Prenat Med.* 2010;4(3):35–42.
18. Reiners CH, Souid A, Oliphant M, Newman N. Palpable spongy mass over the clavicle, an underutilized sign of clavicular fracture in the newborn. *Clin Pediatr.* 2000;39:695–8.

19. Cross KP, Warkentine FH, Kim IK, Gracely E, Paul RI. Bedside ultrasound diagnosis of clavicle fractures in the pediatric emergency department. *Acad Emerg Med.* 2010;17(7):687–93.
20. Walters MM, Forbes PW, Carlo B, Kleinman PK. Healing patterns of clavicular birth injuries as a guide to fracture dating in cases of possible infant abuse. *Pediatr Radiol.* 2014;44:1224–9.
21. Nield LS, Kamat D. Refracture of the clavicle in an infant: case report and review of clavicle fractures in children. *Clin Pediatr.* 2005;44:77–83.
22. Rubin G, Peleg K, Givon A. Israel Trauma Group, Rozen N. Upper extremity fractures among hospitalized road traffic accident pediatrics. *Am J Emerg Med.* 2015;33(2):250–3.
23. Robinson CM. Fractures of the clavicle in the adult: epidemiology and classification. *J Bone Joint Surg Br.* 1998;80(3):476–84.
24. Koch MJ, Wells L. Proximal clavicle physeal fracture with posterior displacement: diagnosis, treatment, and prevention. *Orthopedics.* 2012;35(1):e108–11. doi:10.3928/01477447-20111122-39.
25. Sarwark JF, King EC, Janicki JA. Proximal humerus, scapula, and clavicle. In: Beaty JH, Kasser JR, editors. *Rockwood and Wilkins' Fractures in Children.* 7th ed. Philadelphia: Wolters Kluwer/LWW; 2010. p. 620–9.
26. Strauss BJ, Carey TP, Seabrook JA, Lim R. Pediatric clavicular fractures: assessment of fracture patterns and predictors of complicated outcome. *J Emerg Med.* 2012;43(1):29–35.
27. Wang AG, Hyang RC, Chu ML. Neonatal group B streptococcal osteomyelitis: report of a case. *Zhonghua Min Guo Xiao Er Ke Yi Xue Hui Za Zhi.* 1989;30(1):66–70.
28. Wall LB, Mills JK, Leveno K, Jackson G, Wheeler LC, Oishi SN, Ezaki M. Incidence and prognosis of neonatal brachial plexus palsy with and without clavicle fractures. *Obstet Gynecol.* 2014;123(6):1288–93.
29. Wu F, Marriage N, Ismael A, Smyth V, Kaleem M, Khan T. Posttraumatic nonunion of the clavicle in a 13-year-old boy causing an arteriovenous fistula. *North Am J Med Sci.* 2013;5(11):663–5.
30. Luo TD, Ashraf A, Larson N, Stans AA, Shaughnessy WJ, McIntosh AL. *SLACK* 2015;38(4):e287–91.
31. Li Y, Helvie P, Farley FA, Abbott MD, Caird MS. Complications after plate fixation of displaced pediatric midshaft clavicle fractures. *J Pediatr Orthop.* Epub 2016 Jul 2.
32. Rapp M, Prinz K, Kaiser MM. Elastic stable intramedullary nailing for displaced pediatric clavicle midshaft fractures: a prospective study of the results and patient satisfaction in 24 children and adolescents aged 10 to 15 years. *J Pediatr Orthop.* 2013;33(6):608–13.
33. Hagstrom LS, Ferrick M, Galpin R. Outcomes of Operative Versus Nonoperative Treatment of Displaced Pediatric Clavicle Fractures. *Orthopedics.* 2015;38(2):e135–8.
34. Masnovi ME, Mehlman CT, Eismann EA, Matey DA. Pediatric refracture rates after angulated and completely displaced clavicle shaft fractures. *J Orthop Trauma.* 2014;28(11):648–52.
35. Bae DS, Shah AS, Kalish LA, Kwon JY, Waters PM. Shoulder motion, strength, and functional outcomes in children with established malunion of the clavicle. *J Pediatr Orthop.* 2013;33(5):544–50.
36. Matsumura N, Ikegami H, Nakamichi N, Nakamura T, Nagura T, et al. Effect of shortening deformity of the clavicle on scapular kinematics: a cadaveric study. *Am J Sports Med.* 2010;38(5):1000–6.
37. Lloyd-Roberts GC, Apley AG, Owen R. Reflections upon the aetiology of congenital pseudarthrosis of the clavicle. With a note on cranio-cleido dysostosis. *J Bone Joint Surg Br.* 1975;57(1):24–9.
38. Shalom A, Khermosh O, Wientroub S. The natural history of congenital pseudarthrosis of the clavicle. *J Bone Joint Surg Br.* 1994;76B(5):846–7.

Chapter 13

Sports-Related Clavicle Injuries

G. Bradley Bookatz and Spero G. Karas

Intro and Background

Clavicle fractures account for 4–6% of all fractures, and the majority of these occur in the midshaft [1, 2]. Much like the general population, clavicle fractures in athletes have traditionally been treated with nonoperative methods. The main impetus for this approach has been the overall good outcomes and minimal complications afforded with nonoperative treatment. At our institution we treat these with plate fixation, but use of intramedullary nailing has also been reported with similar outcomes [1, 3]. Clavicular malunion has been described as being primarily a radiographic phenomenon, and midshaft clavicle fractures “generally did well with non-operative care.” [2] Surgical fixation of clavicle fractures has traditionally been reserved for open fractures, skin tenting, floating shoulder, and cases of symptomatic nonunion. However, more recent literature suggests that operative fixation of these injuries may be superior to nonoperative treatment with lower nonunion and malunion rates, improved patient satisfaction, better functional outcomes, and improved cosmesis [4–8]. Hill et al. [5] found a 15% nonunion rate, and 31% of patients reporting unsatisfactory results in 52 displaced fractures that were treated nonoperatively. Shortening of greater than 18–20 mm has also been shown to be associated with unsatisfactory results [5, 9].

The most common mechanism for clavicular fracture is a fall onto the ipsilateral shoulder, thus leaving athletes highly vulnerable to this injury [10]. Kaplan et al. [11] reported there was a 2.9% prevalence of clavicle fractures among collegiate

G.B. Bookatz, M.D. (✉)
Department of Orthopaedic Surgery, Munster Community Hospital,
901 MacArthur Blvd, Munster, IN 46321, USA
e-mail: gbbookatz@gmail.com

S.G. Karas, M.D.
Division of Sports Medicine, Department of Orthopedic Surgery, Emory University,
59 Executive Park South, Atlanta, GA 30329, USA

football athletes at the 2004 NFL Invitational Combine. Given this common mechanism of injury and nature of contact athletics, prompt return to play may be problematic for these athletes. With traditional, nonoperative treatment, return to play is typically allowed anywhere from 1 to 6 weeks after radiologic evidence of healing, or 6–12 weeks after the initial injury [12–14]. Two recent studies by Meisterling et al. [15] and Morgan et al. [16] examined management and return to play after midshaft clavicle injury. Morgan et al. reviewed 19 clavicle fractures sustained in National Football League players over a 5 year time frame, with 13 of these being classified as 100% displaced. Of the displaced injuries, six were treated operatively and healed at an average of 8.8 weeks (range 6–12 weeks). The other seven were initially treated nonoperatively, and three healed with no sequelae but at an average of 13.3 weeks. The remaining four sustained a refracture within 1 year of injury. Meisterling et al. followed 30 clavicle fractures that were treated with plate fixation and found an average return to play of 83 days, with two-thirds of these returning to play at less than 12 weeks, including seven who returned to play at less than 6 weeks. Both authors noted that surgical fixation of displaced midshaft clavicle fractures provided improved stability, fewer complications, and earlier return to play when compared to nonoperative treatment. Despite these recent studies, there still exists no consensus recommendations for type or timing of treatment, and each case must be considered on an individual basis, inclusive of but not limited to the athlete's physical demands, sport, and time left in the season.

Surgical Technique

The senior author's preferred technique for operative fixation of displaced midshaft clavicle fractures is rigid fixation with anatomically pre-contoured 3.5 mm dynamic compression plates and interfragmentary compression screws, similar to the technique described by Kim [12]. Standard indications for surgery include open fractures, those producing neurovascular or skin compromise, and fractures at high risk for nonunion or malunion (>100% displacement, shortening >1.5 cm, and significant comminution) [4–9, 12, 17]. The decision for operative fixation in an athlete may include any of these, or be based on an athlete's unique characteristics such as a more prompt return to play, increased early fracture stability, and the potential for superior functional outcomes.

Surgery is performed in the beach chair position, with the shoulder girdle supported by the table. A transverse incision with full thickness skin flaps is developed superficial to the platysma fascia, followed by subperiosteal dissection creating a second layer of myofascial flaps. Care is taken to identify and preserve branches of the supraclavicular nerve whenever possible. After anatomic reduction, lag screws are placed across the fracture site when possible. Comminution fragments should also be fixed to the larger clavicle segments. The plate is then placed on the superior aspect of the clavicle for maximum biomechanical stability. In athletes requiring shoulder pads for their sport (football, lacrosse, motocross, or hockey), anterior

placement of the plate is also an option, in an attempt to avoid hardware irritation over the superior aspect of the clavicle. Furthermore, in collision athletes, the senior author will frequently utilize a longer plate to limit the amount of clavicle that is exposed to a stress riser at the margins of the plate. We prefer to have three bicortical screws on each side of the fracture; however, comminution extending to the far lateral or medial clavicle may uncommonly impede this. A three-layer closer is completed to minimize the risk for infection and hardware irritation, using an #0 vicryl for the myofascial layer and #2-0 vicryl subcutaneous followed by a #3-0 monocryl subcuticular layer. The patient is placed in a simple sling.

Other authors and studies have investigated the use of intramedullary fixation for clavicle fractures. While plate fixation is considered the “gold standard” for operative treatment, proponents of intramedullary fixation devices cite smaller incisions, shorter operative times, preservation of soft tissues, and ease of hardware removal. Smith et al. [18] examined the biomechanical stability of composite clavicles without fracture, with pre-contoured plating, with locked intramedullary fixation and after hardware removal of both. They found no significant difference between the two types of fixation with hardware intact, however did find that those with intramedullary fixation were stronger after hardware removal than those who had plate fixation removed. It should be noted that these studies lacked the biologic healing that would typically occur, but they do offer compelling evidence for further studies into intramedullary fixation versus plate fixation. Regardless of sport, the senior author recommends interfragmentary lag fixation with plate osteosynthesis as the most secure and anatomic early fixation, especially in cases where there is significant comminution. Plate fixation also provides dependable clinical outcomes in returning the athlete to high impact sports.

Our current recommendations are for plate fixation without routine hardware removal except in cases of significant pain due to the hardware. To our knowledge, there are no studies that review return to play following hardware removal. However, should hardware removal be necessary, our recommendations would be for this to be performed early in the off-season to allow for additional remodeling and healing.

Rehabilitation

Rehabilitation and return to play recommendations vary by author. Kim et al. [12] recommended placing the patient in a sling for 10–14 days but allowed immediate shoulder range of motion. Strengthening exercises may begin at 6 weeks and full contact activities resumed at 12 weeks. Basamania and Rockwood [19] limited initial range of motion to less than 90 degrees following operative fixation. They conceded that return to play is a judgment call and based on many factors. For noncontact athletes, they advised return to play when complete, painless, active range of motion and normal strength returned, and evidence of bridging callus is present, typically at approximately 6 weeks. For athletes in collision sports, they recommend return to play at 2–3 months post-op.

At our institution, the patient is placed in a simple sling and shoulder range of motion is limited to pendulum exercises and elbow/wrist active motion for 4 weeks. Use of the sling is typically discontinued at 4 weeks, and physical therapy is initiated. Athletes are typically released for full activity at 8 weeks if follow-up radiographs demonstrate adequate early healing. Complete union is not necessary, however, by this time many athletes have achieved adequate callus formation for return to sport.

Outcomes

A 2005 meta-analysis of clavicle fractures performed by Zlowodzki et al. [9] revealed a nonunion rate of 2.2% after plate fixation compared with 15.1% following nonoperative treatment. This was an 86% relative risk reduction for clavicle nonunion when comparing rigid plate fixation with nonoperative treatment. Another multicenter, randomized trial comparing plate fixation with nonoperative treatment of 132 displaced midshaft clavicle fractures revealed significantly improved outcomes scores, shorter time to union, earlier return to normal function, and a lower rate of malunion and nonunion at 1 year in the plate fixation group [20]. Both Morgan et al. [16] and Meisterling et al. [15] reported case series of successful treatment of displaced midshaft clavicle fracture with surgical fixation in the athlete. Morgan et al. also found that those treated nonoperatively missed more time due to longer time to union and refracture. Given the time constraints specific to the in-season and preseason athlete, there is a solid body of evidence supporting operative fixation of displaced clavicle fractures in the athletic population. Furthermore, the training requirements of the off-season athlete would still bias our decision-making toward surgery in the appropriate fracture type.

Traditionally, operative treatment of midshaft clavicular fractures has been reserved for open fracture, neurovascular compromise, floating shoulder, skin tenting, and significant shortening. More recently, studies have shown that operative treatment results in significant increases in postoperative strength, outcome scores, lower refracture rates, and quicker return to sport [4–6, 9, 11, 13, 15, 16, 20, 21]. Fanter et al. recently conducted a literature review on the management of clavicle fractures in the adolescent athlete. Despite the infrequent use of surgical repair in the amateur adolescent population, there was evidence that surgical management may prevent malunion, nonunion, and poor outcomes while permitting earlier return to activities [22]. Given the increased demands of athletes—and the potential loss of opportunity and income—there has been a growing trend towards operative treatment of midshaft clavicle fractures. Ranalletta et al. [23] recently published a case series of 54 athletes treated with plate fixation whose return to sport time averaged 68 days, with only one athlete not returning to sport due to a secondary injury. Golish et al. [24] showed that plate fixation provided superior biomechanical fixation compared with intramedullary nails and thus may provide a more rigid construct for early rehabilitation. Additionally, proponents of intramedullary nailing often cite benefits of smaller incisions, fewer complications, and easier hardware

removal as reasons to use intramedullary nails over plate fixation; however, Frigg et al. [25] reported the need for open reduction in 62% of patients and 70% reported complications after intramedullary fixation. Because of these findings we treat these injuries with plate osteosynthesis. We agree with the authors above that plate fixation provides more anatomic and secure reduction in most cases. While the treating surgeon must weigh the clinical factors of the injury along with the personal goals of the athlete when deciding which treatment to employ, recent studies support surgical fixation for displaced clavicle fractures in athletes.

Illustrative Case

A 20-year-old Division-I wide receiver suffered a displaced, segmentally comminuted fracture of the midshaft clavicle during spring football practice (Fig. 13.1). Lag screw fixation of the segmental fragment (Fig. 13.2a) and locking plate

Fig. 13.1 Treatment of a displaced, segmentally comminuted fracture of the midshaft clavicle

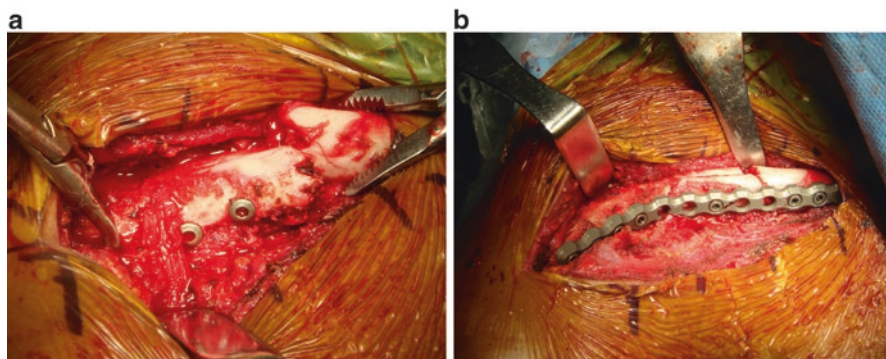
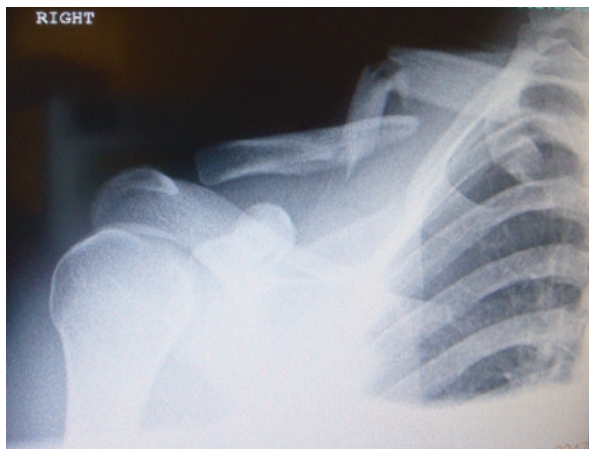
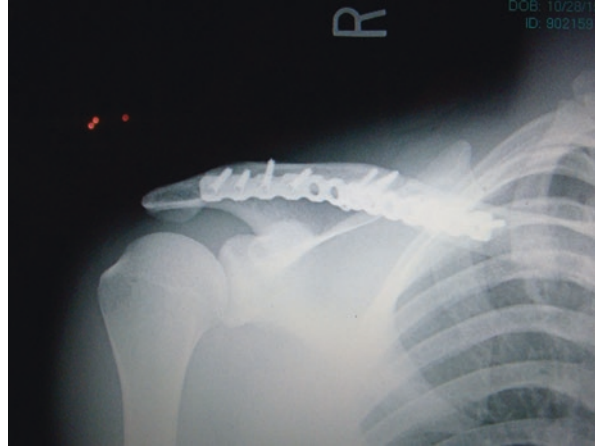
Fig. 13.2 Lag screw fixation of the segmental fragment (a) and locking plate osteosynthesis were performed, with anterior plate placement (b)

Fig. 13.3 The longer plate will limit the area available for a stress riser at the plate margins



osteosynthesis were performed. Note the plate was placed anterior rather than superior, to avoid irritation from the athlete's shoulder pads (Fig. 13.2b). A long plate was used to span the relatively large area of comminution. Furthermore, a longer plate will limit the area available for a stress riser at the margins of the plate (Fig. 13.3). The athlete performed our standard rehabilitation protocol, healed uneventfully, and was released to return to play 8 weeks postoperatively.

References

1. Neer C. Nonunion of the clavicle. *JAMA*. 1960;172:1006–11.
2. Neer C. Fractures of the clavicle. In: Rockwood Jr CA, Green DP, editors. *Fractures in adults*. 2nd ed. Philadelphia: Lippincott; 1984. p. 707–13.
3. Rowe CR. An atlas of anatomy and treatment of midclavicular fractures. *Clin Orthop Relat Res*. 1968;58:29–42.
4. Canadian Orthopaedic Trauma Society. Nonoperative treatment compared with plate fixation of displaced midshaft clavicular fractures. *J Bone Joint Surg Am*. 2007;89(1):1–10.
5. Hill J, McGuire M, Crosby L. Closed treatment of displaced middle- third fractures of the clavicle gives poor results. *J Bone Joint Surg Br*. 1997;79:537–9.
6. McKee M, Pendersen E, Jones C, et al. Deficits following nonoperative treatment of displaced midshaft clavicular fractures. *J Bone Joint Surg Am*. 2006;88:35–40.
7. Nowak J, Holgersson M, Larsson S. Can we predict long-term sequelae after fractures of the clavicle based on initial findings? A prospective study with nine to ten years of follow-up. *J Shoulder Elbow Surg*. 2004;13:479–86.
8. Robinson C, Court-Brown C, McQueen M, Wakefield A. Estimating the risk of nonunion following nonoperative treatment of a clavicular fracture. *J Bone Joint Surg Am*. 2004;86:1359–65.
9. Zlowodzki M, Zelle BA, Cole PA, Jeray K, MD MK, Evidence- Based Orthopedic Trauma Working Group. Treatment of midshaft clavicle fractures: systematic review of 2144 fractures. On behalf of the Evidence-Based Orthopaedic Trauma Working Group. *J Orthop Trauma*. 2005;19:504–7.

10. Stanley D, Trowbridge EA, Norris SH. The mechanism of clavicle fracture: a clinical and biomechanical analysis. *J Bone Joint Surg Br.* 1988;70:461–4.
11. Kaplan LD, Flanigan DC, Norwig J, Jost P, Bradley J. Prevalence and variance of shoulder injuries in elite collegiate football players. *Am J Sports Med.* 2005;33:1142–6.
12. Kim W, McKee MD. Management of acute clavicle fractures. *Orthop Clin North Am.* 2008;39:491–505.
13. Pujalte GGA, Housner JA. Management of clavicle fractures. *Curr Sports Med Rep.* 2008;7(5):275–80.
14. Jeray KJ. Acute midshaft clavicular fracture. *J Am Acad Orthop Surg.* 2007;15:139–48.
15. Meisterling SW, Cain EL, Fleisig GS, Hartzell JL, Dugas JR. Return to athletic activity after plate fixation of displaced midshaft clavicle fractures. *Am J Sports Med.* 2013;41:2632–6.
16. Morgan RJ, Bankston LS, Hoenig MP, Connor PM. Evolving management of middle-third clavicle fracture in the national football league. *Am J Sports Med.* 2010;38:2092–6.
17. Murray IR, Foster CJ, Eros A, Robinson CM. Risk factors for nonunion after nonoperative treatment of displaced midshaft fractures of the clavicle. *J Bone Joint Surg Am.* 2013;95:1153–8.
18. Smith SD, Wijdicks CA, Jansson KS, Boykin RE, Martetschlaeger F, de Meijer PP, Millet PJ, Hackett TR. Stability of mid-shaft clavicle fractures after plate fixation versus intramedullary repair and after hardware removal. *Knee Surg Sports Traumatol Arthrosc.* 2014;22:448–55.
19. Basamania CJ, Rockwood CA. Fracture of the clavicle. In: Rockwood CA, Matsen 3rd FA, editors. *The shoulder.* 4th ed. Philadelphia, PA: Saunders; 2009. p. 381–452.
20. Altamimi A, McKee M. Nonoperative treatment compared with plate fixation of displaced midshaft clavicular fractures. *J Bone Joint Surg Am.* 2008;90(Suppl 2):1–8.
21. Jubel A, Andermahr J, Bergmann H, Prokop A, Rehm KE. Elastic stable intramedullary nailing of midclavicular fractures in athletes. *Br J Sports Med.* 2003;37:480–4.
22. Fanter NJ, Kenny RM, Baker 3rd CL, Baker CL. Surgical treatment of clavicle fractures in the adolescent athlete. *Sports Health.* 2015;7(2):137–41.
23. Ranalletta M, Rossi LA, Piuze NS, Bertona A, Bongiovanni SL, Maignon G. Return to sports after plate fixation of displaced midshaft clavicular fracture in athletes. *Am J Sports Med.* 2015;43:565–9.
24. Golish SR, Oliviero JA, Francke EI, Miller MD. A biomechanical study of plate versus intramedullary devices for midshaft clavicle fixation. *J Orthop Surg Res.* 2008;3:28.
25. Frigg A, Rillmann P, Perren T, Gerber M, Ryf C. Intramedullary nailing of clavicular midshaft fractures with the titanium elastic nail: problems and complications. *Am J Sports Med.* 2009;37(2):352–9.

Chapter 14

Complications of Clavicle Fractures

Scott P. Stephens and Michael A. Wirth

Introduction

Clavicle fractures are relatively common injuries, representing between 3 and 10% of adult fractures and approximately 35% of fractures involving the shoulder girdle [1, 2]. The highest incidences of these injuries are encountered in young, active males and predominantly involve the middle third of the bone. Historically, authors have advocated against surgical intervention due to reliable fracture union and successful clinical outcomes reported with conservative management, even in the presence of substantial displacement. Early studies reported a higher incidence of fracture nonunion with surgical fixation as compared to conservative treatment and was attributed to the surgical exposure, periosteal stripping, and inadequate fixation techniques. These studies though lacked subjective outcome scores and were comprised of a heterogeneous population that included adolescents, who have improved remodeling potential. Current studies with improved methodology though have demonstrated increased shoulder function, diminished pain, and improved complication and union rates with operative treatment [3–5]. A recent multicenter randomized controlled clinical study demonstrated decreased time to union, improved patient satisfaction, higher objective functional scores, and diminished symptomatic malunions with primary operative fixation [6]. Mckee et al. reported significant residual deficits in shoulder strength as well as loss of endurance in patients treated nonoperatively [7]. Studies highlighting the improved functional outcomes with operative fixation have resulted in a dramatic increase in surgical treatment of clavicle fractures [6, 8]. Although the majority of clavicle fractures progress to union

S.P. Stephens, M.D. (✉)
OrthoNeuro, 5040 Forest Dr, New Albany, OH 43054, USA
e-mail: Scott.stephens31@gmail.com

M.A. Wirth, M.D.
University of Texas Health Science Center at San Antonio, San Antonio, TX, USA

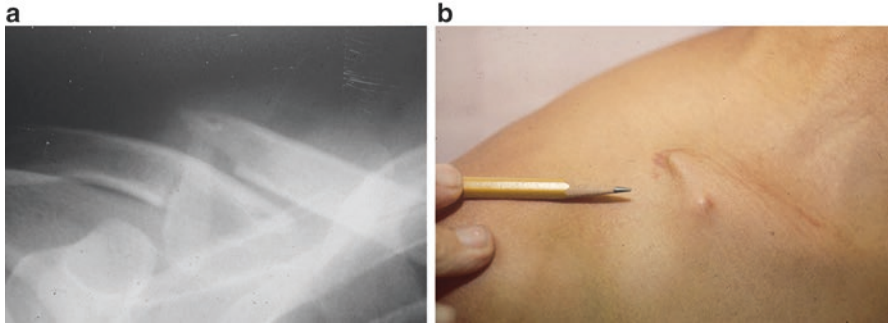


Fig. 14.1 (a) Radiograph of displaced midshaft clavicle fracture. (b) Prominence of medial fragment underneath the skin

with minimal functional limitations and the ability to return to daily activities, recent studies have highlighted the potential complications with both nonoperative and operative treatment of these injuries.

Skin Compromise

The prevention of complications associated with clavicle fractures begins with the initial clinical assessment, especially in patients who have suffered injuries through high energy mechanisms. The subcutaneous position of the clavicle places the local soft tissue at risk for disruption following either direct trauma or indirectly by fracture displacement. The deforming forces placed on the medial fracture fragment can result in either an open fracture or delayed skin breakdown due to tenting of the skin [9] (Fig. 14.1a, b). Although an open fracture is an indication for urgent surgical intervention, these fractures are rare, accounting for only 3.2% of clavicle fractures [9]. Prominent bone fragments that are left untreated can compromise the skin by causing secondary ulceration that requires urgent irrigation and debridement, fracture fixation, and postoperative antibiotics if infection is present [10, 11]. The choice of implant used for surgical fixation can also have an effect on the surrounding soft tissue. Plate fixation requires a larger, more invasive surgical approach that can result in hypertrophic scarring, infection, and plate prominence [12, 13]. The thin soft tissue envelope surrounding the clavicle places the patient at risk for wound dehiscence in the presence of a prominent plate. This can typically be treated with local wound care, antibiotics, and eventual removal of the implant, and highlights the importance of careful soft tissue dissection during surgical intervention [6]. Anterior plate placement may diminish soft tissue irritation but contemporary superiorly oriented plates offer a precontoured, low profile option that diminishes the necessity of implant removal [14, 15]. Intramedullary clavicle fixation provides a less invasive surgical technique that limits surgical dissection and soft tissue stripping. The use of this implant though may require intraoperative conversion to plate

fixation to maintain reduction and frequently requires a secondary procedure for removal of implant due to medial protrusion of the nail, lateral prominence, or routine prevention of implant migration [12, 13]. In addition to soft tissue healing, patients can also experience paresthesias or painful neuromas surrounding the incision.

Nonunion

Clavicle fractures nonunions were traditionally considered to be rare, with prevalence rates reported to be less than 1% by both Neer and Rowe [16, 17]. Surgical intervention at that time was believed to place patients at a greater risk of nonunion due to periosteal soft tissue stripping [16]. Fractures that have stable alignment and minimal soft tissue disruption typically progress to union and a normal return of function. A variety of techniques have been described for closed reduction of displaced clavicle fractures, but these have not demonstrated reliability in counteracting the deforming forces present and maintaining reduction [4, 18]. Recent studies have demonstrated a nonunion rate of 25%, which is higher than previously reported [3] (Fig. 14.2a–d).

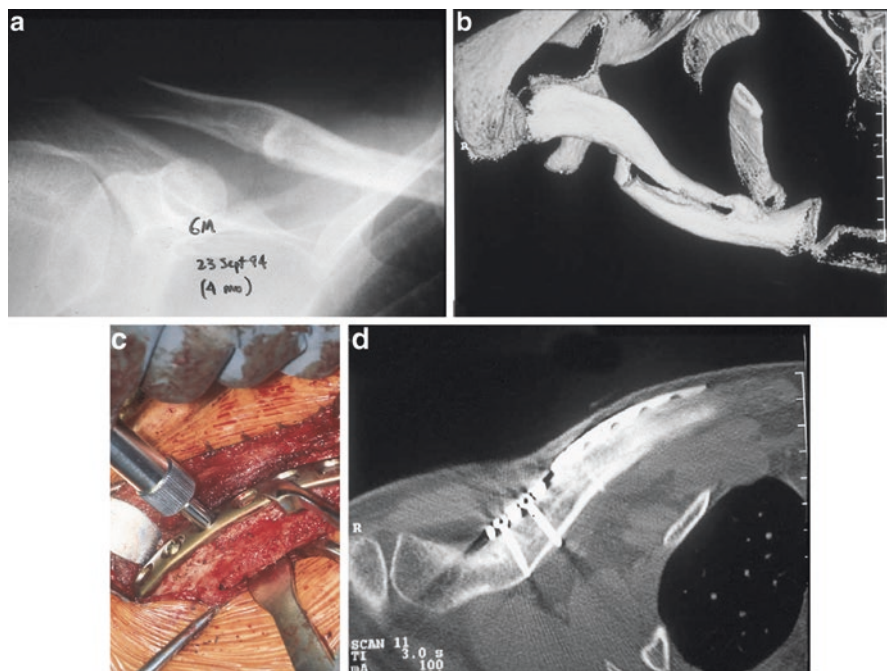


Fig. 14.2 (a) Radiographs 6 months after a police officer experienced a high energy injury. Patient continued to have pain and discomfort. (b) Computed tomography demonstrates nonunion at fracture site. (c) Intraoperative picture of open reduction and internal fixation of fracture nonunion. (d) Computed tomography demonstrating fracture union

A variety of risk factors can inhibit clavicle healing but typically involve high energy mechanisms in a young active population. These fractures are typically comminuted and displaced, which are risk factors associated with the development of nonunion, and can result in the disruption and possible interposition of surrounding soft tissues [3, 9, 18]. Zlowodzki et al. performed a systemic review on acute mid-shaft clavicle fractures and reported an overall nonunion rate of 5.9%; in the subset of clavicle fractures with displacement, the risk of nonunion increased nearly three-fold to 15.1% [19]. Operative treatment of these fractures with either plate osteosynthesis or intramedullary fixation resulted in a reduction in relative risk of fracture nonunion. Robinson et al. found that patients with displaced, comminuted midshaft clavicle fractures had a nonunion rate of 21% in young males [9]. The risk of nonunion has been demonstrated by meta-analysis to be reduced with the use of plate fixation for primary treatment (15.1% vs. 2.2%) and the higher incidence in nonunion from earlier studies may have been the result of improper fixation techniques and selection of operative intervention on more severe fracture patterns [19]. Both plate fixation and intramedullary fixation have demonstrated improved union rates as compared to nonoperative management of clavicle fractures [20, 21]. Studies comparing these fixation techniques though have not demonstrated any difference in both short- and long-term functional outcomes, as well as no difference in the ability to obtain union for displaced, non-comminuted fractures [13].

The location of clavicle fractures can also affect bone healing with a higher incidence of nonunions reported in distal third clavicle fractures [22]. Distal clavicle fractures typically occur as the result of high energy trauma in a younger population or a fall from height in elderly patients. These fractures were originally classified by Neer into three types by the relationship of the fracture line to the coracoclavicular (CC) ligaments. Type I and III fractures are lateral to these ligaments, typically involve only minimal displacement, and are treated conservatively with a sling. Type II fractures though leave the ligaments attached to the distal fragment and result in an unopposed trapezial muscle force displacing the medial fragment proximally while the distal fragment is counteracted by the weight of the arm [23]. Indications for surgical treatment are based on stability of CC ligaments, fracture displacement, and patient age. Although elderly patients are at risk for nonunion, they are typically asymptomatic and do not require treatment. Injuries in younger patients though are the result of severe trauma and reduction can be difficult to maintain without surgical intervention. This can result in pain and reported rates of nonunion following conservative treatment as high as 44% [22]. If sufficient bone is present laterally, then fixation can be accomplished with plate fixation. If the fracture pattern or bone quality precludes distal fixation, then fracture stability can be obtained with concurrent CC ligament fixation. Hook plates have also been described as a possible fixation option but have been associated with subacromial erosion, rotator cuff tears, periprosthetic fractures, implant failure and require a secondary procedure for removal following bony union [24, 25].

Nonunions can be confirmed by failure to show radiographic progression of healing at 4–6 months. The ends of the bone may demonstrate atrophic, eutrophic, or hypertrophic changes that are confirmed by computed tomography to lack

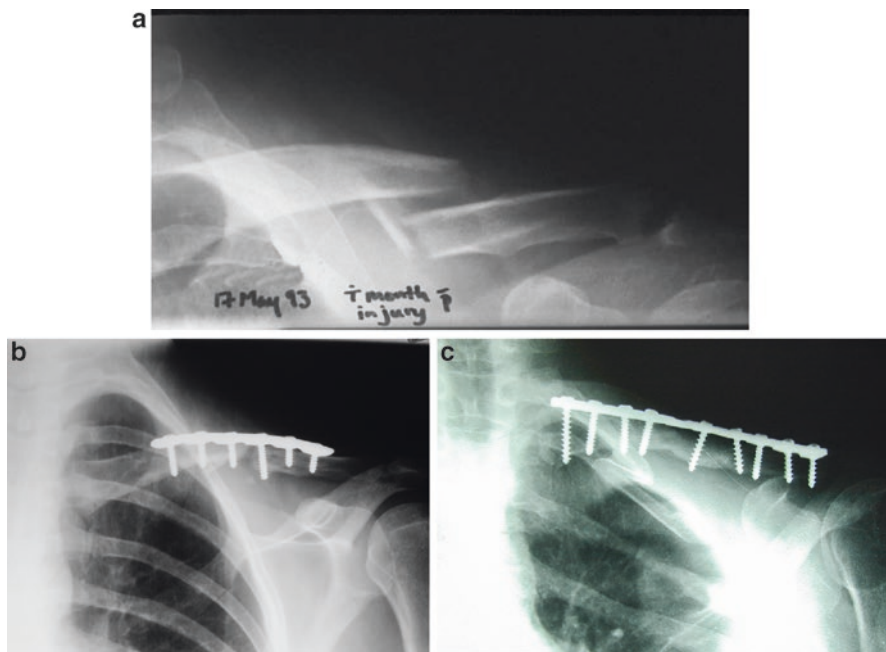


Fig. 14.3 (a) Displaced midshaft clavicle fracture with comminution. (b) Nonunion of fracture following open reduction and internal fixation. (c) 6 months after revision surgery with bone grafting and plate fixation showing bony healing

bridging callous. Clinically, nonunions can result in pain, restriction of movement, weakness, cosmetic deformity, neurologic symptoms, and thoracic outlet syndrome. The patients may have crepitus or prominence at the fracture site and neurovascular symptoms of the ipsilateral extremity due to abundant callous formation or fracture displacement. Fracture nonunion can have a significant effect on quality of life and daily activities and can be treated with internal fixation and bone grafting (Fig. 14.3a–c).

Malunions

Maintaining reduction of clavicle fractures through conservative management can be difficult and a certain amount of deformity is to be expected due to the unequal distribution of forces placed on the fracture fragments. Patients who are skeletally mature are unable to remodel these deformities and the final fracture reduction will remain unchanged. Depending on the amount of displacement of the fracture, varying degrees of shortening and angulation can be visualized on radiographs but was originally thought to be of radiographic interest only with no major residual impairment [4]. The typical malunion pattern can be complex, effecting the clavicle three

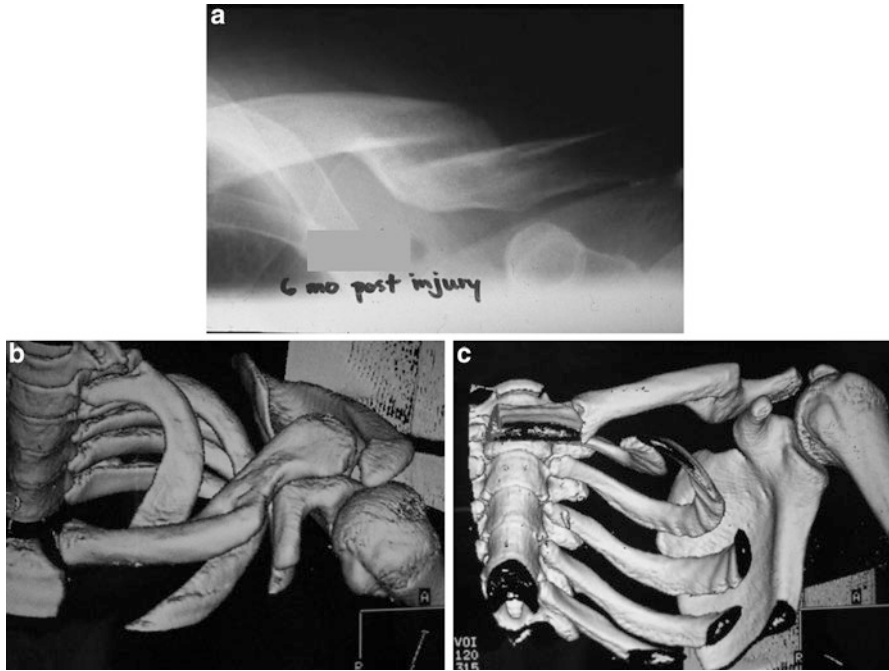


Fig. 14.4 (a) Midshaft clavicle following healing with shortening. (b and c) Computed tomography demonstrating characteristic malunion deformity of clavicle with the lateral fracture fragment lying inferior and medialized to corresponding fragment

dimensionally and resulting in the lateral fragment being inferior, medially translated, and anteriorly rotated in relation to the medial shaft [26] (Fig. 14.4a–d).

Recent studies have countered conventional opinion and have demonstrated that functional outcomes may be adversely impacted by a malunion [27]. Specifically, long-term follow-up studies have revealed complications such as chronic pain, brachial plexus impingement, weakness, and cosmetic dissatisfaction [3, 4, 28]. Hill et al. reported that 31% of 52 patients had unsatisfactory results following evaluation of clavicular malunions and that fractures with greater than 2 cm of shortening were more likely to have a poor outcome [3]. Mckee et al. reported diminished patient-reported outcome scores, as well as significant reduction in strength with objective muscle strength testing, most notably arm abduction, and increased fatigability following nonoperative treatment when clavicle fractures healed with shortening [4]. Clavicle shortening can alter the scapular–humeral relationship, resulting in a decrease in the length–tension relationship of the muscle-tendon unit and producing scapular dyskinesia with diminished mechanical efficiency of the shoulder girdle muscles [3] (Fig. 14.5a–d). This has been correlated by increased displacement or shortening demonstrating worse subjective outcome scores and a higher prevalence of patient dissatisfaction [3, 4, 6]. Corrective osteotomy with internal fixation and bone grafting can restore clavicular length and result in improvement of

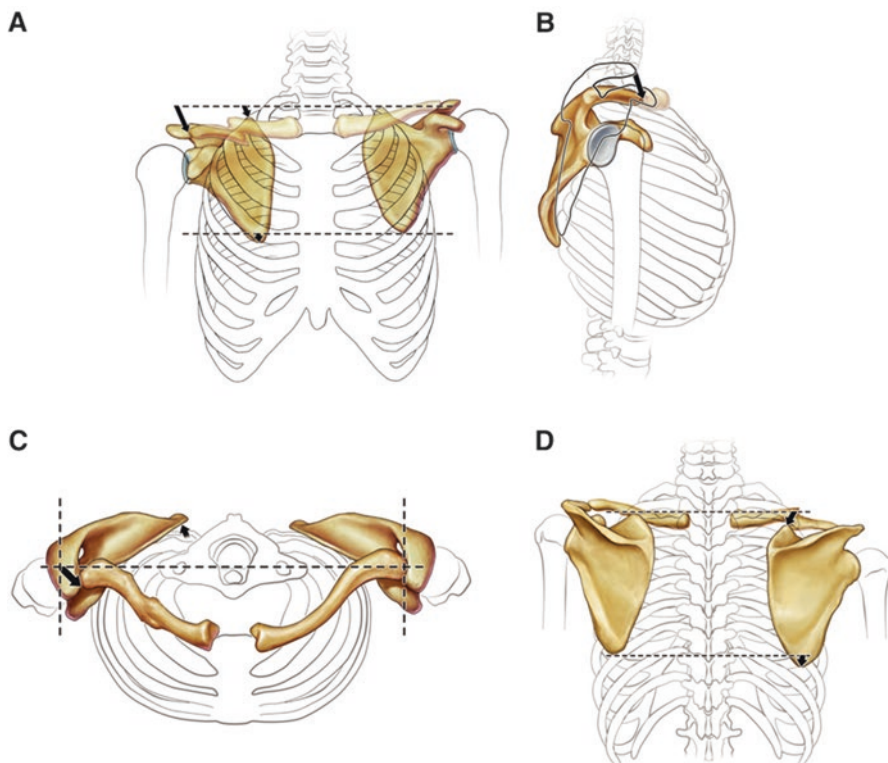


Fig. 14.5 Schema of mean displacement of the scapula due to a malunited midshaft clavicle fracture. The characteristic translation of the acromion inferiorly (**a** and **b**) and anteriorly and medially (**c**) is shown. (**d**) The posterior elements of the scapula translate as well but to a much lesser degree because of compensation through the sternoclavicular, AC, and scapulothoracic articulations. (Reproduced with permission from Risteovski B, et al. The radiographic quantification of scapular malalignment after malunion of displaced clavicular shaft fractures. *J Shoulder Elbow Surg.* 2013; 22: 240–246)

subjective outcome scores and patient satisfaction (Fig. 14.6) [7, 18, 23, 29]. Due to the complex deformity that may be present and proximity to vascular structures, preoperative evaluation of vascular structures with imaging should be considered and the presence of a vascular or thoracic surgeon should be requested.

Neurovascular Sequelae

The proximity of the clavicle to neurovascular structures makes a thorough examination of the affected extremity necessary to rule out additional injuries [30, 31]. Fractures that result in posterior displacement of the medial aspect of the clavicle can injure the major vessels located posterior to the mediastinum. Computed tomography of the chest should be obtained to evaluate traumatic medial clavicle injuries

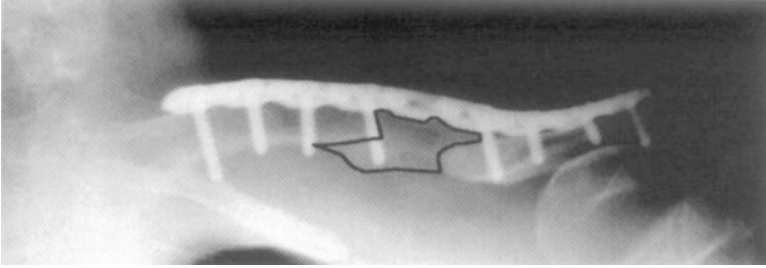


Fig. 14.6 Standard anteroposterior radiograph after restoration of clavicular length by interposition of autogenous iliac crest-bone graft and plate fixation. Well-incorporated bone graft is outlined. (Reproduced with permission from Bosch U, et al. Extension osteotomy in malunited clavicular fractures. *J Shoulder Elbow Surg.* 7;4: 402–405)

due to its rapid availability. This situation is rare but does require urgent operative intervention with the assistance of a cardiothoracic surgeon [32, 33]. For patients who are under the age of 21 or still skeletally immature, an MRI should be obtained to distinguish between a physeal injury and sternoclavicular dislocation [45].

Fractures of the shaft that have significant deformity or abundant callous formation can place pressure on either the brachial plexus or subclavian vessels in the costoclavicular space [10, 30]. The subclavian vessels can be compressed between the clavicle and the first rib, resulting in thoracic outlet syndrome. Injuries to the brachial plexus can occur from early traction injuries or develop from late compression neuropathies from atrophic nonunion. Intraoperative neurologic injury can also result from drill penetration, retractors, excessive fracture mobilization or with intramedullary fixation [11]. The diagnosis of neurovascular injury can be identified by physical examination and history and aided by electromyography, nerve conduction velocities, and advanced imaging such as MRI.

Implant Complications

Various techniques have been reported for clavicle fracture fixation but the most common surgical options currently utilized are either plate or intramedullary fixation [34]. Intramedullary fixation was developed as an alternative to traditional plate fixation and offers several advantages including a cosmetically favorable incision, minimal disruption of the periosteum, and diminished hardware prominence [35, 36]. Various intramedullary implants have been described, including pins (Hagie, Knowles, Rockwood) and titanium elastic nails [16, 37]. Despite the proposed advantages, these implants have been associated with pin migration, pin breakage, cortical perforation, superficial and deep infections, refracture following pin removal, hardware prominence, and skin erosion from pin exposure [16]. Studies have also demonstrated inferior biomechanical properties for rotational and torsional strength with intramedullary fixation when

compared to plate fixation which can potentially result in hardware failure, nonunion, or malunion [33, 37, 38]. These complications have been reduced with improved modern implant designs that allow load sharing fixation and promotion of callous formation, as well as increased surgeon experience with these implants.

Plate osteosynthesis provides a rigid construct that has demonstrated improved patient and surgeon oriented outcomes, earlier return to function, and decreased rates of nonunion and malunion [6] (Fig. 14.7a–d). Plate fixation has also demonstrated improved biomechanics and lower rates of fixation failure as compared to intramedullary nails [33]. Despite the development of low profile precontoured clavicle plates, the subcutaneous location of the implant can result in prominent plate hardware, scar or neuroma related pain, and cosmetic complaints [39]. Studies have demonstrated reoperation rates as high as 25% for plate fixation of clavicle fractures, with the predominant surgery being hardware removal [40]. Despite the increased use of precontoured titanium plates that can prevent stress shielding and improve fracture union rates, a high percentage of implant removal is still reported and can be associated with lower functional outcomes and diminished patient satisfaction [40]. Removal of the plate has demonstrated increased refracture rate as compared to intramedullary fixation and has been potentially attributed to stress risers at vacated holes, stress shielding of the plate, or possibly unrecognized nonunion and requires restrictions on activities for a time period following plate removal [13]. Reinjury prior to fracture healing or in the presence of a nonunion can result in failure of fixation or a fracture adjacent to the implant. Plate fixation has also been associated with pneumothorax, vascular injury, brachial plexus palsy, regional pain syndrome as well as increased economic cost [41, 42].

Distal Clavicle Fractures

Fractures of the distal clavicle are not as prevalent as midshaft clavicle fracture but still comprise as much as 30% of clavicle fractures. These injuries occur with direct trauma to the arm in an adducted position and can be the result of high energy mechanisms associated with injuries to the ribs, ipsilateral upper extremity, and spine. The complex anatomy of the lateral clavicle consists of the acromioclavicular articular surface, acromioclavicular ligaments and is the attachment and origin of muscles of the shoulder girdle. Severe displacement of the fracture due to the deforming muscle forces can result in tenting of the skin and potential compromise (Fig. 14.8a, b) [43]. Due to the proximity of the acromioclavicular joint, posttraumatic arthropathy can develop from either damage to the articular surface at the time of injury from the transmission of force or from intra-articular fracture patterns. Acromioclavicular joint degeneration can manifest clinically by direct tenderness over the joint as well as symptoms being reproduced with cross body adduction. Radiographically these changes can be demonstrated by acromioclavicular joint space narrowing, spur formation, and cystic changes in the distal clavicle. Treatment options include intra-articular steroid injection as well as either arthroscopic or

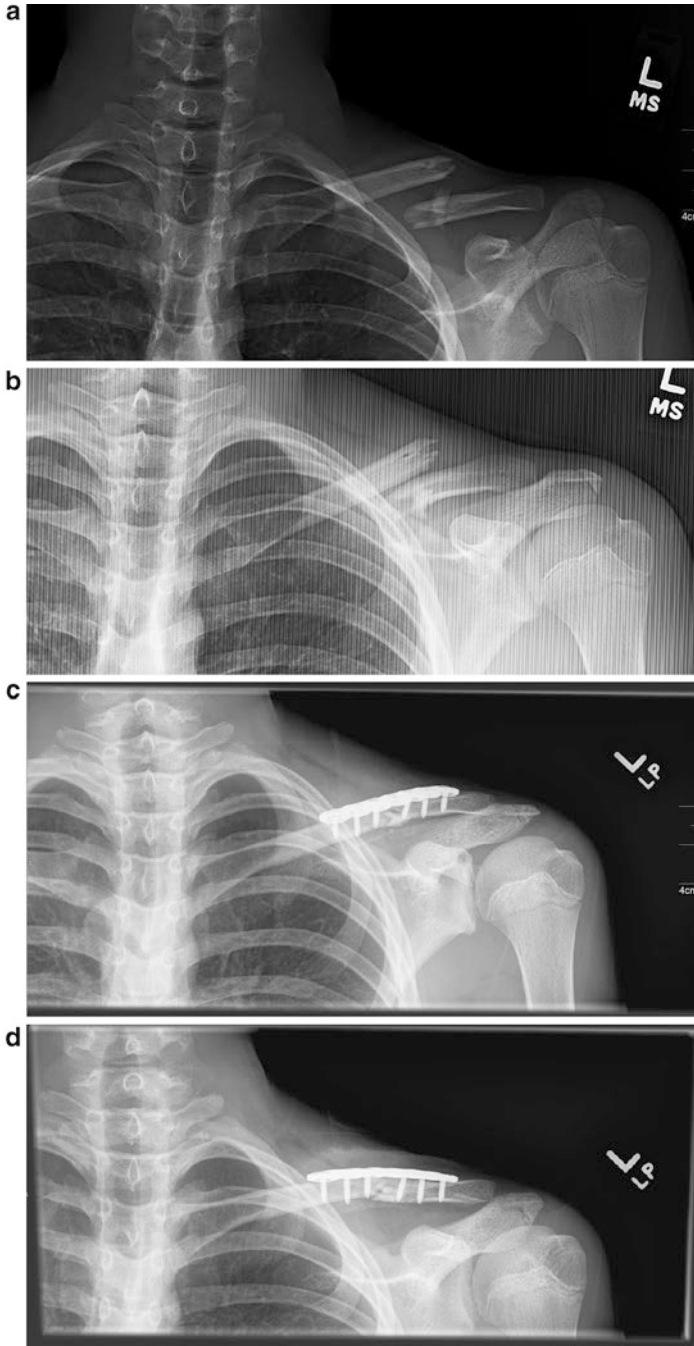


Fig. 14.7 (a) 17-year-old male with clavicle fracture from high energy injury resulting in fracture displacement, comminution, and pressure placed on skin from medial fragment. (b) Cephalic view demonstrates shortening of fracture. (c and d) Restoration of length and alignment obtained with open reduction and internal fixation with a precontoured titanium clavicle plate

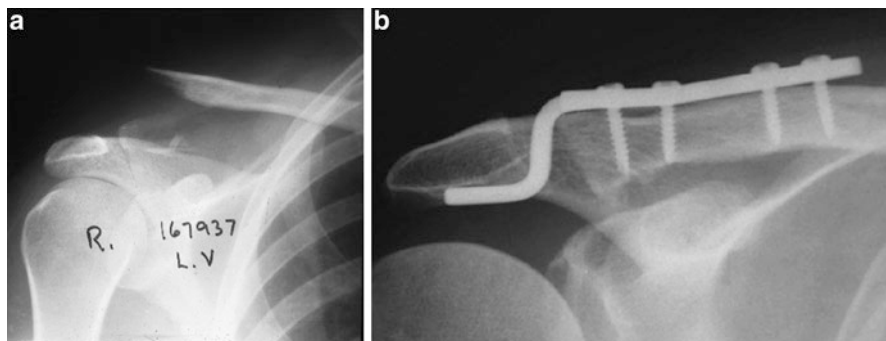


Fig. 14.8 (a) Distal clavicle fracture with the medial fragment being displaced by the deforming force of the trapezius. (b) Fracture was treated with hook plate that was removed after fracture union

open excision of the distal clavicle after failed conservative treatment, making sure to maintain the integrity of the acromioclavicular and coracoclavicular ligament. Neurologic injuries involving these injuries are rare but suprascapular nerve injury has been described and can be associated with external rotation weakness on physical examination [44].

References

1. Nordqvist A, Petersson C. The incidence of fractures of the clavicle. *Clin Orthop Relat Res.* 1994;300:127–32.
2. Postacchini F, Gumina S, De Santis P, Albo F. Epidemiology of clavicle fractures. *J Shoulder Elbow Surg.* 2002;11:452–6.
3. Hill JM, McGuire MH, Crosby LA. Closed treatment of displaced middle-third fractures of the clavicle gives poor results. *J Bone Joint Surg Br.* 1997;79:537–9.
4. McKee MD, Wild LM, Schemitsch EH. Midshaft malunions of the clavicle. Surgical technique. *J Bone Joint Surg Am.* 2004;86(Suppl 1):37–43.
5. Vanbeek C, Boselli KJ, Cadet ER, Ahmad CS, Levine WN. Precontoured plating of clavicle fractures: decreased hardware-related complications? *Clin Orthop Relat Res.* 2011; 469(12):3337–43.
6. Canadian Orthopaedic Trauma Society. Nonoperative treatment compared with plate fixation of displaced midshaft clavicle fractures. A multicenter, randomized clinical trial. *J Bone Joint Surg Am.* 2007;89:1–10.
7. McKee MD, Pedersen EM, Jones C, Stephen DJ, Kreder HJ, Schemitsch EH, et al. Deficits following nonoperative treatment of displaced midshaft clavicular fractures. *J Bone Joint Surg Am.* 2006;88:35–40. doi:10.2106/JBJS.D.02795.
8. Nowak J, Mallmin H, Larsson S. The aetiology and epidemiology of clavicular fractures. A prospective study during a two-year period in Uppsala, Sweden. *Injury.* 2000;31:353–8.
9. Robinson CM. Fractures of the clavicle in the adult. Epidemiology and classification. *J Bone Joint Surg Br.* 1998;80:476–84.
10. Chalmers PN, Van Thiel GS, Ferry ST. Is skin tenting secondary to displaced clavicle fractures more than a theoretical risk? A report of 2 adolescent cases. *Am J Orthop.* 2015;44(10):E414–6.

11. Strauss EJ, Egol KA, France MA, Koval KJ, Zuckerman JD. Complications of intramedullary Hagie pin fixation for acute midshaft clavicle fractures. *J Shoulder Elbow Surg.* 2007;16:280–4.
12. Andrade-Silva FB, Kojima KE, Joeris A, Santos Silva J, Mattar Jr R. Single, superiorly placed reconstruction plate compared with flexible intramedullary nailing for midshaft clavicular fractures: a prospective, randomized controlled trial. *J Bone Joint Surg Am.* 2015;97(8):620–6.
13. Houwert RM, Smeeing DP, Ahmed Ali U, Hietbrink F, Kruyt MC, van der Meijden OA. Plate fixation or intramedullary fixation for midshaft clavicle fractures: a systematic review and meta-analysis of randomized controlled trials and observational studies. *J Shoulder Elbow Surg.* 2016;25(7):1195–203.
14. Formaini N, Taylor BC, Backes J, Bramwell TJ. Superior versus anteroinferior plating of clavicle fractures. *Orthopedics.* 2013;36(7):e898–904.
15. VanBeek C, Boselli KJ, Cadet ER, Ahmad CS, Levine WN. Precontoured plating of clavicle fractures: decreased hardware-related complications? *Clin Orthop Relat Res.* 2011;469(12):3337–43.
16. Neer CS. Fractures of the clavicle. In: Rockwood Jr CA, Green DP, editors. *Fractures in adults.* 2nd ed. Philadelphia: Lippincott; 1984. p. 707–13.
17. Rowe CR. An atlas of anatomy and treatment of midclavicular fractures. *Clin Orthop Relat Res.* 1968;58:29–42.
18. Basamania CJ. “Claviculoplasty” and intramedullary fixation of malunited, shortened clavicle fractures. *J Shoulder Elbow Surg.* 1999;8:540.
19. Zlowodzki M, Zelle BA, Cole PA, Jeray K, MD MK, Evidence-Based Orthopaedic Trauma Working Group. Treatment of midshaft clavicle fractures: systemic review of 2144 fractures: on behalf of the Evidence-Based Orthopaedic Trauma Working Group. *J Orthop Trauma.* 2005;19:504–7.
20. Chan KY, Jupiter JB, Leffert RD, Marti R. Clavicle malunion. *J Shoulder Elbow Surg.* 1999;8:287–90.
21. Smekal V, Irenberger A, Struve P, Wambacher M, Krappinger D, Kralinger FS. Elastic stable intramedullary nailing versus nonoperative treatment of displaced midshaft clavicular fractures—a randomized, controlled, clinical trial. *J Orthop Trauma.* 2009;23:106–12.
22. Banerjee R, Waterman B, Padalecki J, Robertson W. Management of distal clavicle fractures. *J Am Acad Orthop Surg.* 2011;19:392–401.
23. Basamania CJ, Rockwood CA. Fractures of the clavicle. In: Rockwood CA, Matsen FA, Wirth MA, Lippitt SB, editors. *The shoulder.* Philadelphia: Elsevier; 2009. p. 406–13.
24. Hoffler CE, Karas SG. Transacromial erosion of a locked subacromial hook plate: case report and review of literature. *J Shoulder Elbow Surg.* 2010;19:12–5.
25. Kashii M, Inui H, Yamamoto K. Surgical treatment of distal clavicle fractures using the clavicular hook plate. *Clin Orthop Relat Res.* 2006;447:158–64. doi:[10.1097/01.blo.0000203469.66055.6a](https://doi.org/10.1097/01.blo.0000203469.66055.6a).
26. Edelson JG. The bony anatomy of clavicular malunions. *J Shoulder Elbow Surg.* 2003;12:173–8.
27. Nordqvist A, Redlund-Johnell I, von Scheele A, Petersson CJ. Shortening of clavicle after fracture. Incidence and clinical significance, a 5-year follow-up of 85 patients. *Acta Orthop Scand.* 1997;68:349–51.
28. Ledger M, Leeks N, Ackland T, Wang A. Short malunions of the clavicle: an anatomic and functional study. *J Shoulder Elbow Surg.* 2005;14:349–54.
29. Bosch U, Skutek M, Peters G, Tscherne H. Extension osteotomy in malunited clavicular fractures. *J Shoulder Elbow Surg.* 1998;7:402–5.
30. Barbier O, Malgheem J, Delaere O, Vande Berg B, Rombouts JJ. Injury to the brachial plexus by a fragment of bone after fracture of the clavicle. *J Bone Joint Surg Br.* 1997;79:534–6.
31. Chen CE, Liu HC. Delayed brachial plexus neurapraxia complicating malunion of the clavicle. *Am J Orthop.* 2000;29:321–2.
32. Eskola A. Sternoclavicular dislocation. A plea for open treatment. *Acta Orthop Scand.* 1986;57:227–8.

33. Golish SR, Oliviero JA, Francke EI, Miller MD. A biomechanical study of plate versus intramedullary devices for midshaft clavicle fixation. *J Orthop Surg Res.* 2008;3:28.
34. Van der Meijden OA, Houwert RM, Hulsmans M, Wijdicks FJ, Dijkgraaf MG, Meylaerts SA, Hammacher ER, Verhofstad MH, Verleisdonk EJ. Operative treatment of dislocated midshaft clavicular fractures: plate or intramedullary nail fixation? A randomized controlled trial. *J Bone Joint Surg Am.* 2015;97(8):613–9.
35. Kleweno CP, Jawa A, Wells JH, O'Brien TG, Higgins LD, Harris MB, et al. Midshaft clavicular fractures: comparison of intramedullary pin and plate fixation. *J Shoulder Elbow Surg.* 2011;20:1114–7.
36. Narsaria N, Singh AK, Arun GR, Seth RR. Surgical fixation of displaced midshaft clavicle fractures: elastic intramedullary nailing versus precontoured plating. *J Orthop Traumatol.* 2014;15:165–71.
37. Millett PJ, Hurst JM, Horan MP, et al. Complications of clavicle fractures treated with intramedullary fixation. *J Shoulder Elbow Surg.* 2011;20:86–91.
38. Renfree T, Conrad B, Wright T. Biomechanical comparison of contemporary clavicle fixation devices. *J Hand Surg Am.* 2010;35:639–44.
39. Wijdicks FJ, Van der Meijden OA, Millett PJ, Verleisdonk EJ, Houwert RM. Systematic review of the complications of plate fixation of clavicle fractures. *Arch Orthop Trauma Surg.* 2012;132(5):617–25. Epub 2012 Jan 10
40. Naimark M, Dufka FL, Han R, Sing DC, Toogood P, Ma B, Zhang AL, Feeley BT. Plate fixation of midshaft clavicular fractures: patient-reported outcomes and hardware-related complications. *J Shoulder Elbow Surg.* 2015;25(5):739–46.
41. Leroux T, Wasserstein D, Henry P, Khoshbin A, Dwyer T, Ogilvie-Harris D, et al. Rate of and risk factors for reoperation after open reduction and internal fixation of midshaft clavicle fractures: a population-based study in Ontario, Canada. *J Bone Joint Surg Am.* 2014;96:1119–25.
42. Robinson CM, Cairns DA. Primary nonoperative treatment of displaced lateral fractures of the clavicle. *J Bone Joint Surg Am.* 2004;86(4):778–82.
43. Strauss EJ, Kaplan KM, Paksima N, Bosco JA. Treatment of an open infected type IIB distal clavicle fracture: case report and review of the literature. *Bull NYU Hosp Jt Dis.* 2008;66(2):129–33.
44. Huang KC, Tu YK, Huang TJ, Hsu RW. Suprascapular neuropathy complicating a Neer type I distal clavicular fracture: a case report. *J Orthop Trauma.* 2005;19(5):343–5.
45. Hanby CK, Pasque CB, Sullivan JA. Medial clavicle physis fracture with posterior displacement and vascular compromise: the value of three-dimensional computed tomography and duplex ultrasound. *Orthopedics.* 2003;26:81–4.

Index

A

AC injuries

- arthroscopic-assisted techniques, 135
- athletic population, 123
- contact athletes, 123
- CT, MRI and US, 129
- distal clavicle resection, 135
- dynamic lateral radiographs, 128
- indirect mechanism, 124
- NFLISS and NCAAISS, 124
- nonsurgical treatment, 129–131
- orthogonal plain radiographs, 128
- over-aggressive distal clavicle resection, 125
- patho anatomy, 125, 126
- physical examination, 128
- rehabilitation, 135
- Rockwood classification, 126, 127
- sternoclavicular, 126
- superior labral tears, 126
- surgeons, 135
- surgical treatment
 - biologic CC ligament reconstruction, 132–135
 - primary acromioclavicular fixation, 131
 - primary coracoclavicular fixation, 132, 133

Acromioclavicular (AC) dislocation, 207

- advanced imaging, 49
- CT, 49
- description, 45–49
- history, 47
- physical examination, 47–48

plain radiography, 48–49

Rockwood classification, 46

Acromioclavicular (AC) joint

- capsuloligamentous stabilizers, 10
- CC ligament complex, 61
- CT, 64, 65
- deltoid, pectoralis major and trapezius muscles, 62
- description, 9
- diarthrodial articulations, 23
- during trauma, 11
- intra-articular disk morphology, 9, 10
- ligaments and capsules, 9
- ligaments, types, 61
- meniscoid fibrocartilaginous disk, 9
- MRI, 64–72
- Mumford procedure, 10
- radiography, 62–64
- scapular clearance, arm elevation, 11
(*see also* Neurovascular anatomy)
- synovial diarthrodial, 9
- ultrasound-guided injection, 72–73
- upper-extremity function, 61
- width and depth of, 9, 10

Acute displaced mid-shaft clavicle

fracture, 114

Anatomic and hook plate fixation, 179

Arthroscopic-assisted treatments, 179

Atraumatic SCJ subluxation/dislocation, 147

B

Biologic CC ligament reconstruction, 132, 134

Birth brachial plexus injury, 207

C

- CC screw fixation, 179
 - Clavicle, 9–15, 27, 28, 206
 - anatomy and muscle attachments, 20
 - bony anatomic landmarks, 1, 2
 - brachial plexus palsy, 22
 - classification, 20
 - coracoclavicular ligaments, 24
 - curvature and standard deviation, 20, 21
 - description, 1
 - distal excision, 24
 - 3-D morphometric analysis, 22
 - fracture (*see* Clavicle fractures)
 - fractures, 24
 - functions, 1
 - hourglass morphology, 2
 - IM canal diameter, 21
 - IM canal eccentricity, 21, 22
 - joints (*see* Joints)
 - ligamentous, 3–4
 - malunion, 19, 24, 25
 - medial and lateral ends, 21
 - membranous ossification, 205
 - muscular attachments, 2–3
 - neurovascular structures, 22, 23
 - nonoperative treatment, 25–26
 - patients with total claviclectomy, 19
 - pseudarthrosis, 212
 - scapula, 22
 - secondary ossification center, 205 (*see also*
 - Computed tomography (CT);
 - Embryology; Magnetic resonance imaging (MRI); Midshaft clavicular fractures; Neurovascular anatomy; Radiography)
 - S-shaped bone, 19
 - stabilizing muscles recruitment, 7
 - strut, role of, 7
 - subcutaneous bone, 1
 - surgical techniques
 - intramedullary fixation, 27
 - malunion/nonunion, 28
 - plate fixation, 27
 - surgical treatment, 26
 - total clavicular resection, 7
 - Clavicle fractures
 - AC dislocations, 207
 - brachial plexus, 210, 211
 - complications
 - hardware failure, 231
 - implant complications, 231
 - malunions, 227, 228
 - neurovascular sequelae, 230
 - nonunions, 225, 226
 - skin compromise, 224
 - CT scans, 45
 - CT study, 208
 - description, 41–45
 - distal, 231–233
 - grading, 41–42
 - history, 42–43
 - infants, 206
 - ipsilateral, 210
 - midshaft, 224, 227
 - open treatment, 210
 - physical examination, 43–44
 - plain radiography, 44–45
 - refracture, 210
 - Robinson classification, 207, 208
 - and shoulder dystocia, 206, 207
 - surgical management, 208
 - Clavicle injuries, 190
 - middle-third (*see* Middle-third clavicle fractures)
 - operative treatment, 189
 - Closed reduction technique, 152
 - Computed tomography (CT)
 - AC joint, 64, 65
 - bone resorption, 57, 58
 - comminuted fracture, 56
 - coronal reformatted, 59
 - displaced fracture, 57
 - medial clavicular fractures, 57
 - normal rhomboid fossa, 56
 - SC joint, 76–78
 - sclerosis, 57, 58
 - suspected neurovascular and/or visceral injury, 55
 - Coracoclavicular stabilization, 197
- D**
- Displaced mid-shaft clavicle fractures, 115, 116
 - Distal clavicle fractures, 232, 233
 - applied anatomy, 174, 175
 - CC ligaments, 178, 179
 - classification, 175, 177
 - clinical evaluation, 177
 - Neer classification, 176, 178
 - nonunion, 178
 - open reduction, 181
 - radiographic assessment, 178
 - Robinson classification, 177
 - shoulder ROM, 183
 - surgical technique, 179–181
 - Zanca radiographic view, 178

- Distal clavicle resection, 135
- Distal clavicular osteolysis, 72
- Distal-third fracture, 195–197
 - children and adolescents, 198
 - nonoperative treatment
 - acromioclavicular articulation, 195
 - CC ligaments, 195
 - outcomes, 196
 - surgical management
 - coracoclavicular stabilization, 197
 - Hook-plate fixation, 197
 - indications, 196
 - interfragmentary fixation, 197
 - intramedullary fixation, 197
 - Kirschner wire fixation, 197

E

Embryology

- post-natal development, 8–9
- prenatal development, 8

F

- Figure of eight brace treatment, 99

G

General anesthesia

- cardiac bypass, 88
- case study, 91–92
- chest ultrasonography, 87
- complications, 87
- invasive hemodynamic monitoring, 87
- ISBs (*see* Interscalene block (ISBs))
- nitrous oxide, use of, 88
- pain control improvement, 88
- pneumothorax, 87
- SCBPs (*see* Superficial cervical plexus block (SCBPs))

H

- Hook plate fixation, 181, 197
- Hourglass morphology, 2

I

- IDEAL method, 59
- Implant complications, 231
- Implant prominence, 193, 194
- Interfragmentary fixation, 197
- Interscalene block (ISBs)

- ambulatory interscalene nerve catheter
 - infusions, 90
- complex and time-consuming, 91
- extrafascial injection, 90
- high-frequency ultrasound probe, 90
- nerve stimulation/ultrasound, 89
- opioids, 91
- placement of, 90
- post-operative pain relief, 89
- sensory innervation, 91
- Intramedullary clavicle fixation, 224
- Intramedullary fixation, 27, 117, 197
- Intramedullary nailing
 - clavicles, features of, 28
 - description, 28
 - implant types, 28
 - TEN within clavicular canal, 28, 29

J

- Joints, 9–11, 13
 - acromioclavicular (*see* Acromioclavicular (AC) joint)
 - SC (*see* Sternoclavicular (SC) joint)

K

- Kirschner wire fixation, 197

L

- Low-intensity pulsed ultrasound (LIPUS), 100

M

Magnetic resonance imaging (MRI)

- AC joint
 - axial proton density-weighted image, 64, 66
 - distal clavicular osteolysis, 71, 72
 - failed reconstruction, 67, 70, 71
 - normal anatomy, 64, 65
 - normal reconstruction, 67, 69
 - type II, III, IV and V injuries, 66–69
- callus formation, 60, 61
- coronal and axial planes, 60
- IDEAL, 59
- osseous structures, 59
- patient's bone age determination, 59
- SC joint, 78–80
- STIR image, 59
- TOS, 60
- Malunion, 189, 191, 195, 227, 228

- MDCT. *See* Multi-detector row CT (MDCT)
- Medial clavicle fractures
 anterior fracture, 171
 applied anatomy, 166
 clinical evaluation, 166
 management, 169, 170
 open reduction and internal fixation, 171, 173
 physeal fracture, 168
 physeal separation, 174
 radiographic evaluation, 167, 168
 surgical technique
 fracture pattern and size, 170
 patient positioning, 170
 postoperative care, 171
 SC joint, 170, 171
- Medial physeal fractures, 207
- Middle-third clavicle fractures, 191–194
 children and adolescents, 195, 199
 figure-of-eight brace, 190
 nonoperative management, 190
 nonoperative vs. operative treatment, 191, 192
 open reduction and plating, 191
 simple arm sling, 190
 surgical management, 191, 199
 clavicle plate position, 193, 194
 intramedullary fixation, 192, 193
 plate fixation, 192, 193
- Midshaft clavicle injuries
 distal third (AO/OTA 15-C), 117–118
 fracture-specific characteristics, 116
 intramedullary fixation, 117
 malunion and symptomatic nonunion, 118–119
 medial third (AO/OTA 15-A), 118
 operative and non-operative treatment, 111
 operative vs. non-operative management, 114–115
 orthopedic literature, 111
 patient-specific characteristics, 116
 plating, 116–117
 Quesana view, 112, 113
 Robinson's classification, 112, 113
 Zanca view, 112
- Midshaft clavicular fractures, 26, 207
- Multi-detector row CT (MDCT), 57
- N**
- NCAA Injury Surveillance System (NCAAISS), 124
- Neer classification, 176, 178
- Neurovascular anatomy
 AC joints
 conoid and trapezoid ligaments, 11, 12
 modified Weaver–Dunn procedure, 13
 Rockwood classification, 11, 12
 neurological structure, 5, 6
 periosteal, blood supply, 7
 sagittal cadaveric sections, 4
 SC joints, 15
 supraclavicular nerves, 5–7
 at thoracic outlet, 4
 vascular structures, 4–5
- NFL Injury Surveillance System (NFLISS), 124
- Nonoperative clavicle fractures
 anatomy, 96
 case study, 103, 105–107
 complications, 101, 102
 cost, 102, 103
 LIPUS, 100
 medical comorbidities, 98
 midshaft, 97
 nonunions, risk factors, 98
 operative management, 98
 orthopedic practitioners, 96
 outcomes, 100
 patient evaluation, 96–97
 patient satisfaction and functional outcomes, 95
 smoking cessation, 98
 treatment, 99, 100
- Nonunion/malunion, clavicle fractures, 28
- Nonunions, 169, 173, 183
 CC ligament fixation, 226
 fixation and intramedullary fixation, 226
 periosteal soft tissue stripping, 225
 risk factors, 226
 type II fractures, 226
- O**
- Open reduction treatment, 154, 155, 159
- P**
- Pediatric clavicle fractures, 207
 complication rate, 210
 malunion, 210
 outcomes, 209
- Periosteal bone formation, 8
- Physis, 205, 207
- Plate fixation, 27, 224, 231

Plate osteosynthesis, 231
 Plate vs. intramedullary fixation, 192–193
 Plating
 hardware, secondary removal of, 29
 vs. nails, 30
 superior vs. anterior, 29
 surgeons, 29
 Primary acromioclavicular fixation, 131
 Primary coracoclavicular fixation, 132, 133
 Pseudarthrosis, 212

R

Radiography
 Allman classification, 54
 comminuted fracture, 54
 normal left clavicle, 55
 scapula and ribs, 55
 synovial articulations, 53
 therapeutic and/or diagnostic injections, 53
 Randomized controlled trial (RCT), 26
 Refracture, 210
 Robinson classification, 177, 207, 208

S

SC. *See* Sternoclavicular (SC) joint
 SCBPs. *See* Superficial cervical plexus block (SCBPs)
 Short-inversion-time inversion-recovery (STIR) image, 59
 Shoulder dystocia, 206, 207
 Sports-related clavicle injuries
 case study, 219, 220
 clavicular malunion, 215
 lag screw fixation, 219
 midshaft clavicle fractures, 216
 nonoperative methods, 215
 outcomes, 218
 rehabilitation, 217, 218
 surgical technique
 indications, 216
 intramedullary fixation, 217
 plate fixation, 217
 Sternoclavicular joint (SC) injuries,
 150, 151
 anatomy, 145–146
 atraumatic subluxation and
 dislocation, 147
 case studies, 156, 159
 classification, 146
 closed reduction, 152, 156
 complications, surgical management, 156

 dislocations, 149
 mechanism, 146
 open reduction, 154, 155, 159
 physcal injury, 156
 posterior dislocation, 152
 postoperative imaging, 160
 radiographic examination,
 148–150, 161
 strains and subluxations, 149
 surgical technique, 151, 152
 traction techniques, 153
 treatment, 148
 anterior dislocation, 150, 151
 anterior strain/subluxation, 150
 Sternoclavicular (SC) dislocation
 anterior, 36–37, 150, 151
 closed reduction, 153
 CT scans, 40
 description, 34
 direct force, 35
 grading, 34
 history, 34–36
 indirect force, 35–36
 MRI, 40
 physical examination, 36–37
 plain radiography, 37–40
 posterior, 37, 38, 152, 158, 160
 open reduction, 154, 155
 Sternoclavicular (SC) joint
 anterior and posterior dislocations, 74
 axial and coronal planes, 14
 components, 75
 contrast-enhanced CT scans, 14
 CT, 76–78
 description, 13
 diarthrodial articulations, 23
 diarthrodial synovial joint, 75
 healthy asymptomatic volunteers
 documents, 23
 interclavicular ligament, 14
 intra-articular disk, 13–14
 ligamentous stabilizers, 73
 medial clavicle, anatomy of, 3, 13
 MRI, 78–80
 neurovascular anatomy, 15
 orthopaedic surgeons, 74
 physcal shear fracture
 with displacement, 74
 meniscal transection, 74, 75
 radiography, 76
 ultrasound-guided injection, 80–82
 STIR. *See* Short-inversion-time inversion-recovery (STIR) image

Superficial cervical plexus block (SCBPs)
 C1–C4 spinal nerves, 88
 nerve block placement, 89
 physician, 88
 real-time continuous needle
 visualization, 89
 SCP block placement, 89
Supraclavicular nerves
 branches preservation, 7
 medial, intermediate and lateral rami, 5
 midshaft clavicle fractures, 6
Suture and graft sling techniques, 179
Symptomatic malunion, 118, 119
Symptomatic nonunion, 118, 119

T

Thoracic outlet syndrome (TOS), 59
Traction techniques, 153
Transacromial wire fixation, 179
Type I Salter–Harris fracture, 207
Type II distal clavicle fractures, 195

W

Weaver-Dunn procedure, 179, 181

Z

Zanca view, 45, 48–49, 112, 128, 178