

The Role of Surgery in Chronic Pancreatitis

Miloš Kňazovický, Veronika Roškovičová, Tomáš Gajdzik, Tomáš Hildebrand, Jana Kaťuchová, Jozef Radoňák

1st Department of Surgery, Louis Pasteur University Hospital, Košice, Slovakia

Article history: Received: 22.05.2023 Accepted: 13.11.2023 Published: 16.11.2023

ABSTRACT:

Chronic pancreatitis is an inflammatory disease characterized by the progressive replacement of the functional pancreatic parenchyma with fibrotic tissue. This leads to exocrine and endocrine insufficiency. A typical clinical feature is recurrent, severe upper abdominal pain, which negatively affects the patient's quality of life. Conservative treatment as the method of first choice does not prevent irreversible changes in the pancreatic tissue. While endoscopic drainage can have some benefits in the early stages of the disease, it is generally unsuccessful in the long term. Based on recent studies, surgical intervention appears to be the most suitable treatment option for improving the patient's quality of life. It currently includes a wide range of effective, proven drainage and resection procedures. Advances in surgical techniques and postsurgical intensive care have increased the frequency of pancreatic surgeries, while improvements in diagnostic methods have increased the number of patients who meet the indications for such surgery, including elderly and chronically ill patients. However, despite mortality rates decreasing, high morbidity rates remain a problem. Currently, in patients with an inflammatory mass in the head of the pancreas, pyloric and duodenal-preserving resection offers the best results. Different variants of these techniques appear to produce similar results. Various techniques have shown similar outcomes in terms of mortality, morbidity, pain relief, life expectancy and improved quality of life. The optimal timing of surgery has been addressed by several studies and most surgeons now favor early surgical intervention in order to prevent extensive destruction of pancreatic tissue.

KEYWORDS:

chronic pancreatitis, endoscopy, resection techniques, surgical procedures

ABBREVIATIONS

CP – chronic pancreatitis

DPPHR – duodenum-preserving pancreatectomy

HaPanEU – Harmonizing Diagnosis and Treatment of Chronic Pancreatitis Across Europe

PPPD – preserving pancreatic head resection

TPIAT – total pancreatectomy with islet autotransplantation

INTRODUCTION

Chronic pancreatitis (CP) is an inflammatory disease characterized by fibrosis and irreversible morphological changes in the pancreatic tissue. The inflammatory process leads to significant complications, including disabling pain and endocrine and exocrine dysfunctions. The incidence of CP varies between countries. European studies commonly report incidence rates of around 5 per 100,000 [1, 2]. The main cause of CP in Western countries is excessive alcohol consumption (accounting for 65–90% of cases). This is followed by idiopathic cases (20–25%) and other causes (5%) [1–3]. Chronic pain is the most common symptom, varying greatly between patients in both frequency and severity, which may range from mild to unrelenting, uncontrollable pain. Other symptoms can develop due to fibrosis of adjacent organs and vascular structures, leading to stenosis of the bile ducts and duodenum and a gradual loss of endocrine and exocrine function, resulting in maldigestion and diabetes mellitus [4]. The primary goals of surgical intervention are pain relief, long-term pain control, and prevention of complications in the surrounding tissues and organs. So far, several effective surgical drainage and resection techniques have been proven effective. Surgical procedures for CP include resection of the pancreatic tissue, pancreatic duct drainage, or a combination of the two. The choice of surgery depends primarily on the morphological changes of the pancreas and the location of the inflammatory process [5].

Chronic pancreatitis with Pancreatic Ductal Dilatation

Drainage procedures with pancreatic duct drainage to the jejunum are indicated in patients with both chronic pain and a dilated main pancreatic duct (≥ 7 mm) [6, 7]. Ductal dilatation can be diffused over the entire pancreas or, more often, specific to the region behind the stricture. In many patients, pancreaticoliths can be found in the main or secondary ducts [5].

In 1954, first Zollinger and then DuVal described internal retrograde drainage of the pancreas by pancreaticojejunostomy, performing a distal pancreatectomy with splenectomy. Improving this procedure, Puestow and Gillesby introduced a lateral (longitudinal) opening of the pancreatic duct, including removal of the pancreatic tail and spleen [8]. Subsequently, Partington and Rochelle presented a modification of the Puestow-Gillesby approach in 1960.

The Partington-Rochelle procedure (lateral pancreatojejunostomy)

The Partington-Rochelle procedure is the surgery of choice for a dilated main pancreatic duct with no inflammatory process in the head of the pancreas and no signs of biliary obstruction [9]. During this procedure, the head of the pancreas and the duodenum are fully mobilized by the Kocher maneuver. The anterior surface of the pancreas is exposed after cutting the gastrocolic ligament through the omental bursa (Fig. 1.). The enlarged duct can be found macroscopically by palpation, intraoperative ultrasound, or fine-needle aspiration of the pancreatic fluid. The duct is then incised along its entire length to remove stones and leaving all strictures open. The spleen is preserved during this procedure. The operation is completed by creating a pancreatojejunostomy using Roux-en-Y anastomosis.

Chronic pancreatitis With an Enlarged Pancreatic Head

The surgical outcomes of pancreatic duct drainage procedures fail in the long-term because they do not address the inflammatory mass

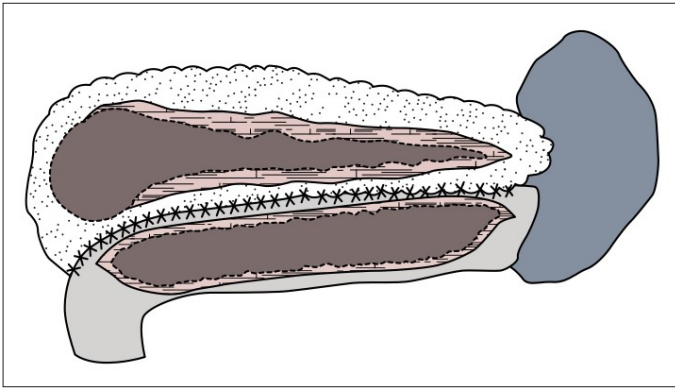


Fig. 1. The Partington-Rochelle procedure (lateral pancreateojejunostomy).

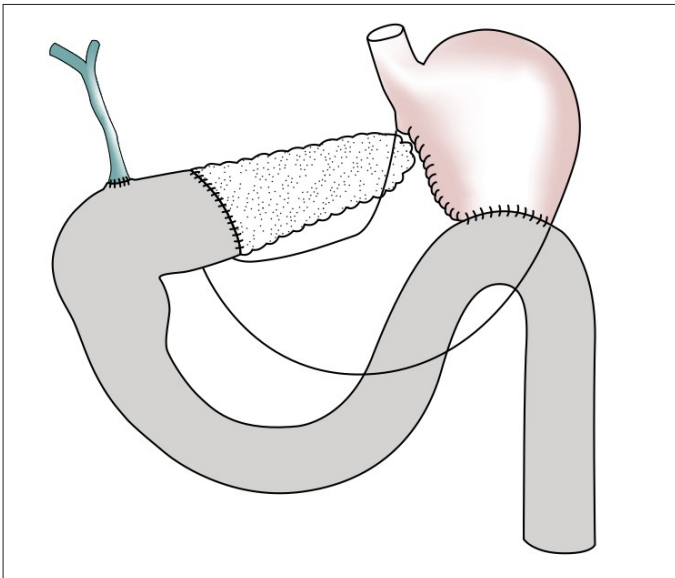


Fig. 2. The Kausch-Whipple procedure.

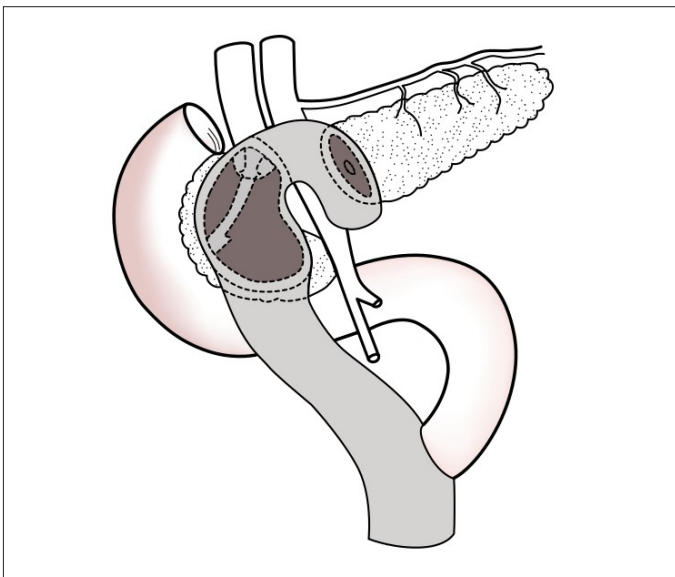


Fig. 3. The Beger procedure.

in the head of the pancreas, which is thought to be the pacemaker of pain in chronic pancreatitis [10]. Over the years, the Kausch-Whipple procedure and other procedures for removing a portion of the head of the pancreas have been the surgical standard in the treatment of patients with chronic pancreatitis and an enlarged pancreatic head (Fig. 2.) [11]. Patients with an isolated inflammatory mass without dilatation of the main duct benefit from either

resection alone or a hybrid procedure that combines resection and drainage.

Partial Pancreatoduodenectomy

One of the advantages of partial pancreatoduodenectomy compared to duodenum-preserving techniques is the potential it offers for radical oncological procedures in cases where malignancy is suspected. Another advantage of this technique is that it allows for the resolution of simultaneous obstruction of the duodenum and the common bile duct, if necessary. The major disadvantage of this procedure is the need to resect the duodenum, pylorus, and common bile duct, which is associated with considerable side effects and reduced quality of life [12].

The Beger Procedure

To avoid some of the adverse consequences of pancreatoduodenectomy, Beger developed a procedure that allows duodenum-preserving resection of the head of the pancreas in patients suffering from intractable pain [13]. Using this method, only a small part of the pancreatic tissue is left on the duodenum. The stomach and common bile duct are not resected. Bilateral pancreateojejunostomy is performed on a small part of the remaining pancreatic tissue attached to the duodenum and distal pancreas (Fig. 3.). The Beger procedure's advantage over pancreatoduodenectomy is the preservation of the duodenum and the need to perform only anastomosis on both sides of the pancreas. The Beger procedure is known to reduce postoperative morbidity and mortality [14].

The Frey Procedure

In patients with both chronic pain and a dilated main pancreatic duct (≥ 7 mm), the procedure introduced by Frey and Izbicky is indicated [15]. This comprises limited anterior pancreatic head resection and drainage of the main duct. In this procedure, the distal part of the pancreatic head is left in place and the pancreatic duct is drained longitudinally along its entire length (Fig. 4.). Drainage is achieved using a lateral pancreateojejunostomy. An advantage of the Frey procedure over complete pancreatic head resection is that it allows the ductal lesions in the remaining pancreatic tissue to be therapeutically affected. A disadvantage of leaving a margin of pancreatic tissue in place is the possibility of leaving traces of the active disease with it.

The Berne Procedure

In patients with an inflammatory mass in the pancreatic head but no duct dilatation, the Berne procedure – a modification of the Beger procedure described in 2001 by Büchler – may be performed [16]. In principle, this is a limited anterior resection of the pancreatic head with a pancreateojejunostomy without transection over the portal vein and mesenteric vessels (Fig. 5.). Unlike the Frey technique, no longitudinal incision of the gland is performed and only one anastomosis is used for reconstruction.

CP With Diffuse Sclerosis or Involvement of the Small Ducts

In patients without dominant ductal involvement, CP is characterized by atrophy of the parenchyma and diffuse pancreatic fibrosis with calcifications. In these patients, total or subtotal pancreatectomy is

indicated, making treatment challenging. However, these surgeries have previously been abandoned because of the significant mortality associated with endocrine and exocrine insufficiencies.

Longitudinal V-Shaped Excision of the Ventral Pancreas

CP of the small ducts used to be considered a classic indication for more extensive resection. This surgical choice balanced the therapeutic benefits of successful pain relief against the loss of most pancreatic functions and the significant risk of perioperative mortality and morbidity. To bypass these detrimental effects in patients with small duct involvement, Izbicky developed the ventral pancreas V-shaped excision (Fig. 6.) [17]. This protects patients from unnecessary resections. In this form of CP, longitudinal V-shaped excision of the ventral pancreas is a safe and effective alternative to resection procedures. The resected part of the pancreas is closed with anterolateral pancreatojejunostomy.

The Hamburg Procedure

For patients with small duct diseases with an enlarged head of the pancreas or a dilated duct, the Hamburg procedure, also presented by Izbicky, is suitable. It combines the advantages of the Beger and Frey procedures with a radical resection of the head and a V-shaped excision of the body of the pancreas along the pancreatic duct. With this modification, the transection of the pancreas above the portal vein and the superior mesenteric vein is avoided and the risk of bleeding is reduced [18].

DISCUSSION

Pain is the most disabling symptom of CP; it can vary widely between patients based on pancreatic damage. Pain is divided into two types, based on intensity and duration. Type A is intermittent pain with long pain-free intervals that can be managed conservatively. Meanwhile, Type B is constant pain with severe exacerbations, which are a manifestation of complications, such as pseudocyst or ductal obstruction of the pancreas [19].

In the current literature and guidelines for the treatment of Type B CP, there are discrepancies regarding the timing and choice of treatment (surgical intervention or endoscopy) [20–22]. In 2017, the guidelines “Harmonizing Diagnosis and Treatment of Chronic Pancreatitis Across Europe” (HaPanEU) were published [23]. This document outlines a multidisciplinary step-up approach in the treatment of chronic pain. The first step includes dietary measures, lifestyle management (alcohol and smoking cessation), and analgesic administration. If pain persists despite this conservative treatment, an endoscopic approach is recommended as the next step. If sufficient pain relief is not achieved one year after endoscopic treatment, surgery should be proposed to the patient. In recent years, however, several studies have compared the step-up procedure with early surgery and found early surgical treatment superior to conservative endoscopic measures in terms of pain and improved quality of life [23–25]. Delayed surgical treatment was associated with prolonged opioid overuse, multiple endoscopic interventions, and repeated episodes of severe pain [26].

To address the issue of optimal timing of surgical interventions for CP, a Dutch research group conducted the ESCAPE trial [27]. This was a multicenter, randomized clinical trial involving 30 Dutch

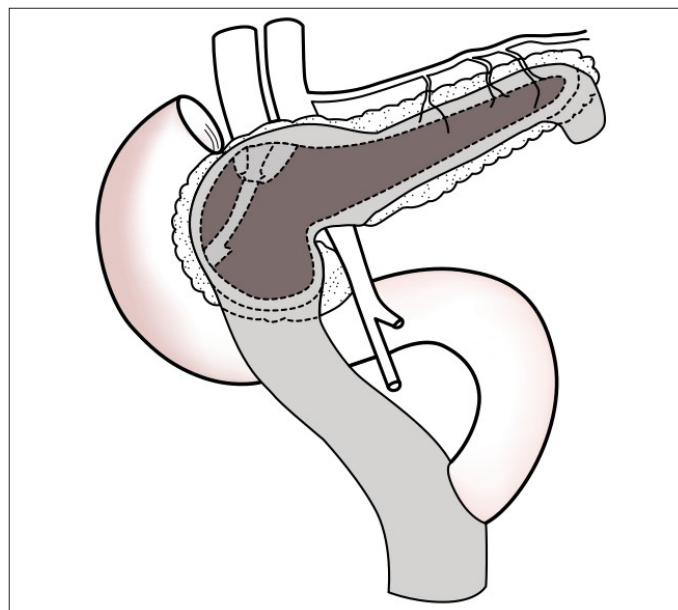


Fig. 4. The Frey procedure.

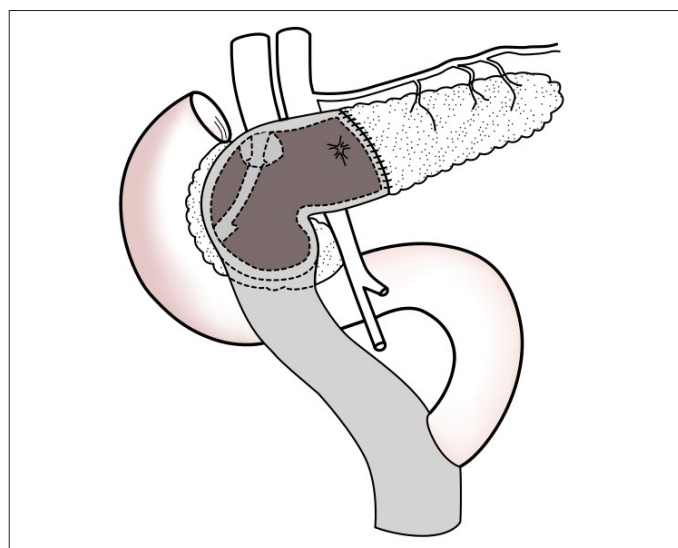


Fig. 5. The Berne procedure.

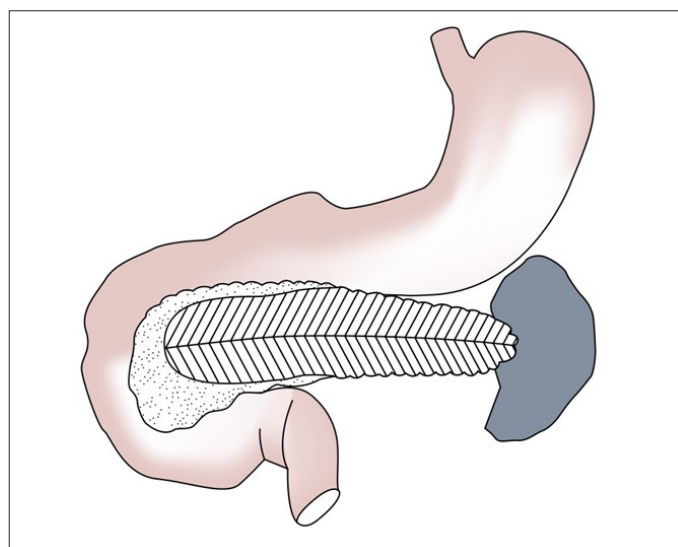


Fig. 6. Longitudinal V-Shaped Excision of the Ventral Pancreas.

hospitals. From April 2011 to September 2016, 88 patients with Type B CP were controlled. The inclusion criteria were dilatation of the

main pancreatic duct and recent initiation of analgesic treatment with opioids. The patients were randomized to either the step-up protocols or surgery within 6 weeks. Izbicky pain score was used as the primary evaluation method [28]. The total cohort consisted of 88 patients (mean age, 52 years; 21 [24%] women), of whom 85 (97%) completed the 18-month follow-up. During this period, the patients who underwent surgical procedures showed a lower average Izbicky pain score (37 vs. 49). At the end of follow-up, complete or partial pain relief was achieved in 58% of the patients who had undergone early surgery vs. 39% of the patients in the step-up group. The total number of interventions was also lower in the group of early surgery patients. Mortality, the length and frequency of hospitalizations, pancreatic function, and quality of life did not differ significantly between the two groups (27% vs. 25%) [27]. The results of the ESCAPE study have confirmed the importance of early surgical intervention to prevent extensive destruction of the pancreatic parenchyma.

Today, the choice of surgery depends primarily on the morphological changes and the location of inflammatory processes. Surgeries with pancreatic ducts draining to the jejunum are indicated in patients with both chronic pain and dilatation of the main pancreatic duct [7, 29]. These drainage surgeries aim to preserve the maximum amount of pancreatic tissue. However, there is often an inflammatory mass in the pancreatic head. In such cases, this approach does not address the underlying cause of the disease. Nowadays, the only appropriate indication for such a drainage operation is an isolated pathology in the ductal system, without an inflammatory mass in the head of the pancreas. In such selected patients, pain relief was shown to be around 60–70% with a low mortality rate [30]. However, it is rarely possible to achieve long-term pain relief with drainage procedures.

Following the Partington-Rochelle procedure, about 25–45% of patients have satisfactory long-term pain relief [31]. Subsequent surgery in those whose pain returns usually reveals an enlarged pancreatic head, with an inflammatory mass as the source of the pain. These patients experience long-term pain relief only after resection of the pancreatic head. Therefore, resection procedures have become a standard surgical approach. When malignancy is suspected, early radical surgery is standard practice. This may be either the classic Whipple procedure or pylorus-preserving resection. After previously falling into disfavor, this type of surgery has been revived in recent years in some centers with total pancreatectomy with islet autotransplantation (TPIAT). In this procedure, the pancreas is removed, as the source of pain, while islet cell function is preserved by their reimplantation into the portal circulation [32]. TPIAT is considered most effective in patients with hereditary pancreatitis and small duct involvement. Previous pancreatic surgery is a contraindication for performing TPIAT in some centers because the intervention significantly reduces islet mass. In expert centers, there are strict criteria for TPIAT suitability. A study of TPIAT effectiveness found sustained pain relief in 82% of patients 10 years after surgery and in up to 90% after 15 years. Among the studied TPIAT patients, 26–55% were not dependent on insulin [33].

Since many patients develop exocrine insufficiency and/or diabetes mellitus after Whipple surgery, less radical resections are preferred, the most common of which are pylorus-preserving pancreatic head resection (PPPD) and duodenum-preserving pancreatectomy (DPPHR) [34]. The aim of all duodenum-preserving pancreatectomies

is to remove the inflammatory mass and leave as much intact pancreatic parenchyma as possible, while the gastroduodenal passage and the continuity of the common bile duct remain intact.

A major advantage of DPPHR is that in addition to preserving the duodenum, stomach, and gallbladder, it also preserves the endocrine system. DPPHR is a demanding surgical technique, but its superiority over PPPD has been demonstrated by several randomized studies [35–37]. In patients with an inflammatory mass in the head of the pancreas, DPPHR results are favorable in up to 90% of patients [38]. A meta-analysis of several randomized clinical trials comparing pancreatoduodenectomy and DPPHR concluded that the two procedures are equally effective in terms of pain relief, overall morbidity, and the occurrence of postoperative endocrine and exocrine insufficiency. However, DPPHR was found to produce better outcomes in terms of postoperative weight gain and long-term quality of life [39]. Moreover, consistently shorter operative times were observed in DPPHR. In 2010, Diener et al. published the ChroPac-Trial protocol, the results of which were published in 2017 [40]. This was the first large, multicenter randomized controlled trial to compare DPPHR with pancreatoduodenectomy. The study included 250 CP patients with inflammatory masses. The primary goal was to evaluate the patients' quality of life 24 months after surgery. The study showed significant improvements in the quality of life and pain scores of all the patients, regardless of which surgery they had received, with no significant differences between the groups [41].

Another topic that has been the subject of recent debate is the need for drainage after pancreatic resection. Despite some studies favoring pancreatic resection without intra-abdominal drainage [42], routine elimination of drains has not yet been proven [43]. The majority of pancreatic surgeons still consider routine insertion of intra-abdominal drains necessary [44, 45]. The DRAPA study compared two types of intra-abdominal drains after pancreatic resection and their effect on pancreatic fistulas and postoperative complications. Patients undergoing pancreatic resection were randomized to either a group with closed vacuum drains or a group with closed passive drainage. The study concluded that the type of drain did not affect the number of postoperative pancreatic fistulas. Passive drainage was found to carry a higher risk of obstruction, whereas closed vacuum drainage systems maintained patency for longer with no increase in the rate of postoperative complications [46].

CONCLUSION

Long-term pain relief, resolution of associated complications, and improvement of the patient's quality of life remain the primary goals in the treatment of CP. This is best achieved by an interdisciplinary team of radiologists, pain management specialists, gastroenterologists, and surgeons. Endoscopic drainage may be important especially in the earlier stages of the disease. However, the available evidence suggests that in advanced CP, surgery is the most beneficial treatment option, providing better overall outcomes and longer-lasting results than interventional endoscopy.

Until recently, the optimal timing of surgery was uncertain. The previous practice of delaying surgery until all other options have failed has been abandoned, because the advantages of early

surgical intervention have been demonstrated – particularly its minimization of pancreatic tissue destruction. It has been shown that in patients without pancreatic head enlargement, drainage procedures are safe and effective, especially for short-term pain relief, though they often fail in the long-term. When a pancreatic head inflammatory mass is present, pylorus- and duodenum-preserving procedures currently offer the best outcomes for patients with intractable pain. Therefore, these should be adopted as the

standard of care. Variations of these techniques appear to yield similar results.

Appropriate selection of patients and optimal timing of surgical intervention seems to be the key to successful treatment of CP. The future of CP surgery should consist of thorough screening and early differentiation of malignant tumors from any chronic inflammatory processes in the head of the pancreas.

REFERENCES

- Beyer G., Habtezion A., Werner J., Lerch M.M., Mayerle J.: Chronic pancreatitis. *Lancet*, 2020; 396 (10249): 499–512. doi: 10.1016/S0140-6736(20)31318-0.
- Hart P.A., Conwell D.L.: Chronic Pancreatitis: Managing a Difficult Disease. *Am J Gastroenterol.*, 2020; 115(1): 49–55. doi: 10.14309/ajg.0000000000000421.
- Otsuki M., Tashiro M.: Chronic pancreatitis and pancreatic cancer, lifestyle-related diseases. *Intern Med.*, 2007; 46(2): 109–113. doi: 10.2169/internalmedicine.46.1787.
- Ammann R.W., Akovbiantz A., Largiader F., Schouler G.: Course and outcome of chronic pancreatitis. Longitudinal study of a mixed medical-surgical series of 245 patients. *Gastroenterology*, 1984; 86(5): 820–828.
- Bouwense S.A.W., Kempeneers M.A., van Santvoort H.C. et al.: Surgery in Chronic Pancreatitis: Indication, Timing and Procedures. *Visc. Med.*, 2019; 35(2): 110–118. doi: 10.1159/000499612.
- Frey C.F., Smith G.J.: Description and rationale of a new operation for chronic pancreatitis. *Pancreas*, 1987; 2(6): 701–707.
- Yekebas E.F., Bogoevski D., Honarpisheh H. et al.: Long-term follow-up in small duct chronic pancreatitis: A plea for extended drainage by V-shaped excision; of the anterior aspect of the pancreas. *Ann Surg.*, 2006; 244(6): 940–946; discussion 946–948. doi: 10.1097/01.sla.0000246914.25884.e9.
- Puestow C.B., Gillesby W.J.: Retrograde surgical drainage of pancreas for chronic relapsing pancreatitis. *AMA Arch Surg.*, 76(6): 898–907, 1958. PMID: 13532132.
- Mullady D.K., Yadav D., Amann S.T. et al.: Type of pain, pain-associated complications, quality of life, disability and resource utilisation in chronic pancreatitis: a prospective cohort study. *Gut*, 2011; 60(1): 77–84. doi: 10.1136/gut.2010.213835.
- Kemper M., Izbicki J.R., Bachmann K.: Surgical Treatment of Chronic Pancreatitis: The state of the Art. *Chirurgia (Bucur)*, 2018; 113(3): 300–306. doi: 10.21614/chirurgia.113.3.300.
- Parekh D., Nararajan S.: Surgical Management of Chronic Pancreatitis. *JIPS*, 2015; 77(5): 453–456. doi: 10.1007/s12262-015-1362-0.
- Königer J., Seiler C.H., Sauerland S. et al.: Duodenum-preserving pancreatic head resection—a randomized controlled trial comparing the original Beger procedure with the Berne modification. *J. Surg.*, 2008; 143(4): 490–498. doi: 10.1016/j.j.surg.2007.12.002.
- Beger H.G., Büchler M., Bittner R.R., Oettinger W., Roscher R.: Duodenum-preserving resection of the head of the pancreas in severe chronic pancreatitis. Early and late result. *Ann Surg.*, 1989; 209(3): 273–278. doi: 10.1097/0000658-198903000-00004.
- Keck T., Wellner U.F., Riediger H. et al.: Long-term outcome after 92 duodenum-preserving pancreatic head resections for chronic pancreatitis: comparison of Beger and Frey procedures. *J. Gastrointest. Surg.*, 2010; 14(3): 549–556. doi: 10.1007/s11605-009-1119-9.
- Ray S., Basu C., Dhali A., Dhali G.K.: Frey procedure for chronic pancreatitis: A narrative review. *Ann Med Surg (Lond)*, 2022; 80: e104299. doi: 10.1016/j.amsu.2022.104229.
- Gloor B., Friess H., Uhl W., Büchler M.W.: A modified technique of the Beger and Frey procedure in patients with chronic pancreatitis. *Dig. Surg.*, 2001; 18(1): 21–25. doi: 10.1159/000050092.
- Izbicki J.R., Bloechle C., Broering D.C., Kuechler T., Broelsch C.E.: Longitudinal V-shaped excision of the ventral pancreas for small duct disease in severe chronic pancreatitis: prospective evaluation of a new surgical procedure. *Ann. Surg.*, 1998; 227(2): 213–219. doi: 10.1097/0000658-199802000-00010.
- Plagemann S., Welte M., Izbicki J.R., Bachmann K.: Surgical Treatment for Chronic Pancreatitis: Past, Present, and Future. *Gastroenterol Res Pract.*, 2017; 2017: 8418372. doi: 10.1155/2017/8418372.
- Machicado J.D., Chari S.T., Timmons L., Tang G., Yadav D.: A population-based evaluation of the natural history of chronic pancreatitis. *PANC*, 2017; 18(1): 39–45. doi: 10.1016/j.pan.2017.11.012.
- Löhr J.M., Dominguez-Munoz E., Rosendahl J. et al.: United European Gastroenterology evidence-based guidelines for the diagnosis and therapy of chronic pancreatitis (HaPanEU). *UEG Journal.*, 2017; 5(2): 153–199. doi: 10.1177/2050640616684695.
- Drewes A.M., Bouwense S.A.W., Campbell C.M. et al.: Guidelines for the understanding and management of pain in chronic pancreatitis. *PANC.*, 2017; 17(5): 720–731. doi: 10.1016/j.pan.2017.07.006.
- Dumonceanu J.M., Delhaye M., Tringali A. et al.: Endoscopic treatment of chronic pancreatitis: European Society of Gastrointestinal Endoscopy ESGE Guideline – Updated August 2018. *Endoscopy*, 2019; 51(2): 179–193. doi: 10.1055/a-0822-0832.
- Yang C.J., Bliss L.A., Schapira E.F. et al.: Systematic review of early surgery for chronic pancreatitis: impact on pain, pancreatic function, and re-intervention. *J Gastrointest Surg.*, 2014; 18(10): 1863–1869. doi: 10.1007/s11605-014-2571-8.
- Ke N., Jia D., Huang W. et al.: Earlier surgery improves outcomes from painful chronic pancreatitis. *Medicine (Baltimore)*, 2018; 97(19): e0651. doi: 10.1097/MD.0000000010651.
- Sugumar K., Deshpande A.: Outcomes of pain management in chronic pancreatitis: experience from a tertiary care hospital in India. *Turk J Surg.*, 2020; 36(4): 359–367. doi: 10.47717/turkjsurg.2020.4924.
- Ahmed Ali U., Nieuwanhuijs V.B., van Eijck C.H. et al.: Clinical outcome in relation to timing of surgery in chronic pancreatitis: a nomogram to predict pain relief. *Arch Surg.*, 2012; 147(10): 925–932. doi: 10.1001/archsurg.2012.1094.
- Ahmed Ali U., Issa Y., Bruno M.J. et al.: Early surgery versus optimal current step-up practice for chronic pancreatitis (ESCAPE): design and rationale of a randomized trial. *BMC Gastroenterol.*, 2013; 13: 49. doi: 10.1186/1471-230X-13-49.
- Bloechle C., Izbicki J.R., Knoefel W.T., Kuechler T., Broelsch C.E.: Quality of life in chronic pancreatitis—results after duodenum-preserving resection of the head of the pancreas. *Pancreas*, 1995; 11(1): 77–85. doi: 10.1097/00006676-199507000-00008.
- Usenko O., Khomiak I., Khomiak A. et al.: Duodenum-preserving pancreatic head resection or panreatoduodenectomy for the surgical treatment of paraduodenal pancreatitis: a retrospective cohort study. *Langenbercks Arch Surg.*, 2023; 408: 178. doi: 10.1007/s00423-023-02917-1.
- van der Gaag N.A., van Gulik T.M., Busch O.R.C. et al.: Functional and medical outcomes after tailored surgery for pain due to chronic pancreatitis. *Ann Surg.*, 2012; 255(4): 763–770. doi: 10.1097/SLA.0b013e31824b7697.
- Perbtani Y., Forskmark C.E.: Update on the diagnosis and management of exocrine pancreatic insufficiency. *F1000Res.*, 2019; 8: F1000. doi: 10.12688/f1000research.20779.1.
- Bellin M.D., Beilman G.J., Sutherland D.E. et al.: How Durable Is Total Pancreatectomy and Intraportal Islet Cell Transplantation for Treatment of Chronic Pancreatitis? *J Am Coll Surg.*, 2019; 228(4): 329–339. doi: 10.1016/j.amcollsurg.2018.12.019.
- Tillou J.D., Tatum J.A., Jolissaint J.S. et al.: Operative management of chronic pancreatitis: A review. *Am J Surg.*, 2017; 214(2): 347–357. doi: 10.1016/j.amjurg.2017.03.004.
- Kempeneers M.A., Issa Y., Ahmed Ali U. et al.: International consensus guidelines for surgery and the timing of intervention in chronic pancreatitis. *PANC*, 2020; 20(2): 149–157. doi: 10.1016/j.pan.2019.12.005.
- Büchler M.W., Friess H., Müller M.W., Wheatley A.M., Beger H.G.: Randomized trial of duodenum-preserving pancreatic head resection versus pylorus-preserving Whipple in chronic pancreatitis. *Am J Surg.*, 1995; 169(1): 65–69; discussion 69–70. doi: 10.1016/s002-9610(99)80111-1.
- Klempa I., Spatny M., Menzel J. et al.: Pancreatic function and quality of life after resection of the head of the pancreas in chronic pancreatitis. A prospective, randomized comparative study after duodenum preserving resection of the head of the pancreas versus Whipple's operation. *Chirurg.*, 1995; 66(4): 350–359.

37. Witzigmann H., Max D., Uhlmann D. et al.: Outcome after duodenum-preserving pancreatic head resection is improved compared with classic Whipple procedure in the treatment of chronic pancreatitis. *Surgery*, 2003; 134(1): 53–62. doi: 10.1067/msy.2003.170.
38. Beger H.G., Büchler M., Bittner R.R., Oettinger W., Roscher R.: Duodenum-preserving resection of the head of the pancreas in severe chronic pancreatitis. Early and late results. *Ann Surg.*, 1989; 209(3): 273–278. doi: 10.1097/00000658-198903000-0004.
39. Diener M.K., Rahbari N.N., Fischer L.: Duodenum-preserving pancreatic head resection versus pancreatoduodenectomy for surgical treatment of chronic pancreatitis: a systematic review and meta-analysis. *Ann Surg.*, 2008; 247(6): 950–961. doi: 10.1097/SLA.0b013e3181724ee7.
40. Diener M.K., Brucker T., Contin P. et al.: ChroPac-trial: duodenum-preserving pancreatic head resection versus pancreatoduodenectomy for chronic pancreatitis. Trial protocol of a randomised controlled multicentre trial. *Trials*, 2010; 11: 47. doi: 10.1186/1745-6215-11-47.
41. Diener M.K., Hüttner F.J., Kieser M. et al.: Partial pancreatoduodenectomy versus duodenum-preserving pancreatic head resection in chronic pancreatitis: the multicentre, randomised, controlled, double-blind ChroPac trial. *Lancet*, 2017; 390(10099): 1027–1037. doi: 10.1016/S0140-6736(17)31960-8.
42. Wang Q., Jiang Y.J., Li J. et al.: Is routine drainage necessary after pancreaticoduodenectomy? *World J Gastroenterol.*, 2014; 20(25): 8110–8118. doi: 10.3748/wjg.v20.i25.8110.
43. Van Buren G., Bloomston M., Hughes S.J. et al.: A randomized prospective multicenter trial of pancreaticoduodenectomy with and without routine intraperitoneal drainage. *Ann Surg.*, 2014; 259(4): 605–612. doi: 10.1097/SLA.00000000460.
44. Bassi C., Molinari E., Malleo G. et al.: Early versus late drain removal after standard pancreatic resections: results of a prospective randomized trial. *Ann Surg.*, 2010; 252(2): 207–214. doi: 10.1097/SLA.0b013e3181e61e88.
45. Shrikhande S.V., Barreto S.G., Shetty G. et al.: Post-operative abdominal drainage following major upper gastrointestinal surgery: single drain versus two drains. *J Cancer Res Ther.*, 2013; 9(2): 267–271. doi: 10.4103/0973-1482.113380.
46. Čečka F., Jon B., Skalický P. et al.: Results of a randomized controlled trial comparing closed-suction drains versus passive gravity drains after pancreatic resection. *Surgery*, 2018; 164(5): 1057–1063. doi: 10.1016/j.surg.2018.05.030.

Table of content: <https://ppch.pl/issue/16065> Page of count: 6 Tables: – Figures: 6 References: 46

Copyright: Some right reserved: Fundacja Polski Przegląd Chirurgiczny. Published by Index Copernicus Sp. z o. o.

Competing interests: The authors declare that they have no competing interests.



The content of the journal „Polish Journal of Surgery” is circulated on the basis of the Open Access which means free and limitless access to scientific data.



This material is available under the Creative Commons – Attribution-NonCommercial 4.0 International (CC BY-NC 4.0). The full terms of this license are available on: <https://creativecommons.org/licenses/by-nc/4.0/legalcode>

Corresponding author: Veronika Roškovičová MD; 1st Department of Surgery, Louis Pasteur University Hospital; Trieda SNP 1, 04001 Košice, Slovakia; Phone: +42 1944631163; E-mail: vroskovicova@gmail.com

Cite this article as: Knazovicky M., Roskovicova V., Gajdzik T., Hildebrand T., Katuchova J., Radonak J.; The Role of Surgery in Chronic Pancreatitis; *Pol Przegl Chir* 2024; 96 (Supl. 1): 97–102; DOI: 10.5604/01.3001.0053.9841