

Laparoscopic Pancreatic Necrosectomy: Single Port Use

Alban Zarzavadjian Le Bian, MD, MPh

Service de Chirurgie Digestive, Hépato-biliaire et pancréatique, Hôpital Simone Veil, Eaubonne, France.

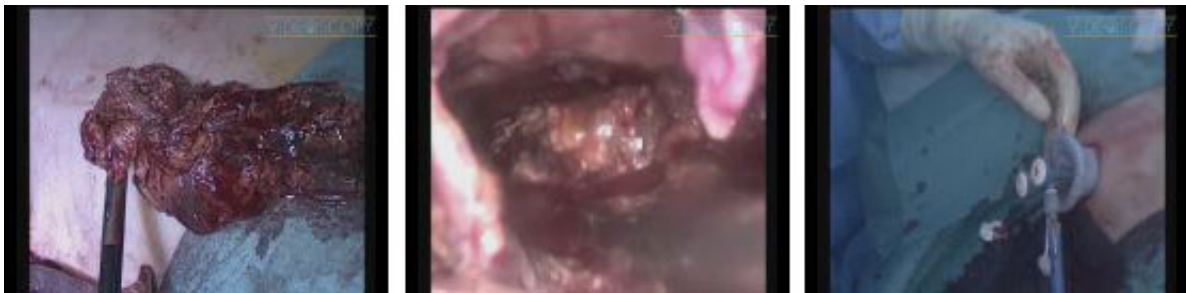
Laboratoire d'Éthique Médicale et de Médecine Légale, Université Paris V, Paris, France.

E-mail: spleen2008@live.fr

Frédéric Borie, MD, PhD

Service de Chirurgie Digestive, Hépato-biliaire et pancréatique, CHU Carémeau, Nîmes, France.

© Mary Ann Liebert, Inc. DOI: 10.1089/vor.2014.0207



Abstract

Currently, acute pancreatitis associated with pancreatic necrosis (or extra-pancreatic necrosis) presents with poor outcomes, with mortality reaching up to 20%.¹ During the last decade, the management of this dreadful condition has changed through the development of medical resuscitation, computed tomography (CT)-guided or ultrasound (US)-guided drainages.² Indeed, open surgical necrosectomy is not anymore a first-line treatment, while the percutaneous catheter drainage³ and the endoscopic transluminal drainage (with or without necrosectomy)⁴ have been demonstrated as safe and effective. Yet, a minimally invasive surgical approach may be required when the noninvasive drainage is inefficient or inaccessible. In this video, we show a reproducible pancreatic necrosectomy using a single port.

No funding has been received for this work from any of the following organizations: National Institutes of Health (NIH); Wellcome Trust; Howard Hughes Medical Institute (HHMI); or any others.

No competing financial interests exist.

Runtime of video: 3 mins 48 secs

Cite this video

Alban Zarzavadjian Le Bian, Frédéric Borie, Laparoscopic Pancreatic Necrosectomy: Single Port Use, *J Laparoendosc Adv Surg Tech Part B Videosc.* 2014, DOI: 10.1089/vor.2014.0207.

References

1. Bakker OJ, van Santvoort H, Besselink MG, Boermeester MA, van Eijck C, Dejong K, et al. Dutch Pancreatitis Study Group. Extrapancreatic necrosis without pancreatic parenchymal necrosis: A separate entity in necrotising pancreatitis? *Gut* 2012;10:1475–1480.
2. Frossard JL, Steer ML, Pastor CM. Acute pancreatitis. *Lancet* 2008;371:143–152.

3. van Santvoort HC, Besselink MG, Bakker OJ, Hofker HS, Boermeester MA, Dejong CH, et al. Dutch Pancreatitis Study Group. A step-up approach or open necrosectomy for necrotizing pancreatitis. *N Engl J Med* 2010;362:1491–1502.
4. Haghshenas Kashani A, Laurence JM, Kwan V, Johnston E, Hollands MJ, Richardson AJ, et al. Endoscopic necrosectomy of pancreatic necrosis: A systematic review. *Surg Endosc* 2011;25:3724–3730.

Original Publication Date: 2014